



## Protocol for the Examination of Specimens from Patients with Carcinoma of the Ampulla of Vater

Version: 4.3.0.0

Protocol Posting Date: June 2025

CAP Laboratory Accreditation Program Protocol Required Use Date: March 2026

The changes included in this current protocol version affect accreditation requirements. The new deadline for implementing this protocol version is reflected in the above accreditation date.

For accreditation purposes, this protocol should be used for the following procedures AND tumor types:

Procedure	Description
Resection	Includes specimens designated ampullectomy and pancreaticoduodenectomy (Whipple Resection)
Tumor Type	Description
Carcinoma	Includes all intra-ampullary, peri-ampullary duodenal, and mixed intra- and peri-ampullary duodenal carcinomas

This protocol is NOT required for accreditation purposes for the following:

Procedure
Biopsy
Intra-ampullary papillary-tubular neoplasms without invasive carcinoma
Primary resection specimen with no residual cancer (e.g., following neoadjuvant therapy)
Cytologic specimens

The following tumor types should NOT be reported using this protocol:

Tumor Type
Lymphoma (consider the Precursor and Mature Lymphoid Malignancies protocol)
Sarcoma (consider the Soft Tissue protocol)
Well-differentiated neuroendocrine tumor (consider the Duodenum and Ampullary NET protocol)

### Version Contributors

**Cancer Committee Authors:** Yue Xue, MD, PhD\*, Rondell P. Graham, MBBS\*, William V. Chopp, MD\*, Dhanpat Jain, MD\*

\* Denotes primary author.

For any questions or comments, contact: [cancerprotocols@cap.org](mailto:cancerprotocols@cap.org).

### Glossary:

**Author:** Expert who is a current member of the Cancer Committee, or an expert designated by the chair of the Cancer Committee.

**Expert Contributors:** Includes members of other CAP committees or external subject matter experts who contribute to the current version of the protocol.

### Accreditation Requirements

Synoptic reporting with core and conditional data elements for designated specimen types\* is required for accreditation.

- Data elements designated as core must be reported.
- Data elements designated as conditional only need to be reported if applicable.
- Data elements designated as optional are identified with "+". Although not required for accreditation, they may be considered for reporting.

This protocol is not required for recurrent or metastatic tumors resected at a different time than the primary tumor. This protocol is also not required for pathology reviews performed at a second institution (i.e., second opinion and referrals to another institution).

Full accreditation requirements can be found on the CAP website under [Accreditation Checklists](#).

A list of core and conditional data elements can be found in the Summary of Required Elements under Resources on the CAP Cancer Protocols [website](#).

*\*Includes definitive primary cancer resection and pediatric biopsy tumor types.*

### Synoptic Reporting

All core and conditionally required data elements outlined on the surgical case summary from this cancer protocol must be displayed in synoptic report format. Synoptic format is defined as:

- Data element: followed by its answer (response), outline format without the paired Data element: Response format is NOT considered synoptic.
- The data element should be represented in the report as it is listed in the case summary. The response for any data element may be modified from those listed in the case summary, including "Cannot be determined" if appropriate.
- Each diagnostic parameter pair (Data element: Response) is listed on a separate line or in a tabular format to achieve visual separation. The following exceptions are allowed to be listed on one line:
  - Anatomic site or specimen, laterality, and procedure
  - Pathologic Stage Classification (pTNM) elements
  - Negative margins, as long as all negative margins are specifically enumerated where applicable
- The synoptic portion of the report can appear in the diagnosis section of the pathology report, at the end of the report or in a separate section, but all Data element: Responses must be listed together in one location
- Organizations and pathologists may choose to list the required elements in any order, use additional methods in order to enhance or achieve visual separation, or add optional items within the synoptic report. The report may have required elements in a summary format elsewhere in the report IN ADDITION TO but not as replacement for the synoptic report i.e., all required elements must be in the synoptic portion of the report in the format defined above.

**Summary of Changes**

**v 4.3.0.0**

- Updates to cover page
- Updates to content and explanatory notes including modifications to Tumor Site, Histologic Type, Tumor Size, Tumor Extent, and Margin Status for Dysplasia and Intraepithelial Neoplasia questions
- Lymphovascular Invasion question updated to Lymphatic and / or Vascular Invasion
- Perineural Invasion question updated from optional to required
- Added required Treatment Effect question
- Updates to pTNM Classification

## Reporting Template

---

**Protocol Posting Date:** June 2025

**Select a single response unless otherwise indicated.**

**CASE SUMMARY: (AMPULLA OF VATER)**

**Standard(s):** AJCC 8

### SPECIMEN

#### Procedure

- ☐ Ampullectomy
- ☐ Pancreaticoduodenectomy (Whipple resection)
- ☐ Other (specify): \_\_\_\_\_
- ☐ Not specified

### TUMOR

#### Tumor Site (Note [A](#))

- ☐ Intra-ampullary: \_\_\_\_\_
- + ☐ Intra-ampullary papillary-tubular neoplasm (IAPN)-associated (arising from a preinvasive mass lesion within the ampulla)
- + ☐ Ampullary ductal origin (arising from the walls or mucosa of the ducts without a mass-forming preinvasive lesion)
- ☐ (Peri-) Ampullary-duodenal (arising from duodenal surface of the papilla): \_\_\_\_\_
- ☐ Mixed intra-ampullary and (peri-) ampullary-duodenal, NOS: \_\_\_\_\_
- ☐ Other (specify): \_\_\_\_\_
- ☐ Cannot be determined: \_\_\_\_\_
- ☐ Not specified

#### Histologic Type (Note [B](#))

- ☐ Adenocarcinoma, pancreaticobiliary-type
- ☐ Adenocarcinoma, intestinal-type
- ☐ Adenocarcinoma with mixed features (pancreaticobiliary- and intestinal-type)
- ☐ Adenocarcinoma, NOS
- ☐ Adenocarcinoma arising in intra-ampullary papillary-tubular neoplasm (IAPN)
- ☐ Mucinous adenocarcinoma
- ☐ Poorly cohesive carcinoma
- ☐ Signet-ring cell carcinoma
- ☐ Medullary carcinoma
- ☐ Adenosquamous carcinoma
- ☐ Large cell neuroendocrine carcinoma
- ☐ Small cell neuroendocrine carcinoma
- ☐ Undifferentiated carcinoma, NOS
- ☐ Mixed neuroendocrine-non-neuroendocrine neoplasm (MiNEN) (specify components): \_\_\_\_\_
- ☐ Other histologic type not listed (specify): \_\_\_\_\_

\_\_\_ Carcinoma, NOS

**+Histologic Type Comment:** \_\_\_\_\_

**Histologic Grade (Note C)**

\_\_\_ G1, well-differentiated

\_\_\_ G2, moderately differentiated

\_\_\_ G3, poorly differentiated

\_\_\_ Other (specify): \_\_\_\_\_

\_\_\_ GX, cannot be assessed: \_\_\_\_\_

\_\_\_ Not applicable: \_\_\_\_\_

**Tumor Size (Note D)**

\_\_\_ Unifocal invasive carcinoma

\_\_\_ Greatest dimension in Centimeters (cm): \_\_\_\_\_ cm

**+Additional Dimension in Centimeters (cm):** \_\_\_ x \_\_\_ cm

\_\_\_ Cannot be determined (explain): \_\_\_\_\_

\_\_\_ Multifocal invasive carcinoma in association with intra-ampullary papillary-tubular neoplasm

\_\_\_ Size of the largest focus of invasive carcinoma in Centimeters (cm): \_\_\_\_\_ cm

**Aggregate Size that Combines Sizes of all Foci of Invasive Carcinoma in Centimeters (cm)**  
**(specify, if known):** \_\_\_\_\_ cm

**Invasive Component as a Percentage of Entire Tumor (specify, if known):**

\_\_\_\_\_ %

\_\_\_ Cannot be determined (explain): \_\_\_\_\_

**Tumor Extent (select all that apply)**

\_\_\_ Carcinoma in situ / high-grade dysplasia including intra-ampullary papillary tubular neoplasm with high-grade dysplasia

\_\_\_ Limited to ampulla of Vater or sphincter of Oddi

\_\_\_ Invades beyond sphincter of Oddi (perisphincteric invasion)

\_\_\_ Invades into duodenal submucosa

\_\_\_ Invades into muscularis propria of duodenum

\_\_\_ Directly invades pancreas (up to 0.5 cm)

\_\_\_ Extends more than 0.5 cm into pancreas

\_\_\_ Extends into peripancreatic soft tissues

\_\_\_ Extends into periduodenal tissue

\_\_\_ Extends into duodenal serosa

\_\_\_ Invades other adjacent organ(s) or structure(s) other than pancreas

*Select all that apply*

\_\_\_ Stomach

\_\_\_ Gallbladder

\_\_\_ Omentum

\_\_\_ Celiac axis

\_\_\_ Superior mesenteric artery

\_\_\_ Common hepatic artery

\_\_\_ Other (specify): \_\_\_\_\_

\_\_\_ Cannot be determined: \_\_\_\_\_

\_\_\_ No evidence of primary tumor

**Lymphatic and / or Vascular Invasion (Note [E](#))**

\_\_\_ Not identified  
\_\_\_ Present  
\_\_\_ Cannot be determined: \_\_\_\_\_

**Perineural Invasion (Note [E](#))**

\_\_\_ Not identified  
\_\_\_ Present  
\_\_\_ Cannot be determined: \_\_\_\_\_

**Treatment Effect (Note [F](#))**

\_\_\_ No known presurgical therapy  
\_\_\_ Present, with no viable cancer cells (complete response, score 0)  
\_\_\_ Present, with single cells or rare small groups of cancer cells (near complete response, score 1)  
\_\_\_ Present, with residual cancer showing evident tumor regression, but more than single cells or rare small groups of cancer cells (partial response, score 2)  
\_\_\_ Present, NOS  
\_\_\_ Absent, with extensive residual cancer and no evident tumor regression (poor or no response, score 3)  
\_\_\_ Cannot be determined: \_\_\_\_\_

**+Tumor Comment:** \_\_\_\_\_

**MARGINS (Note [G](#))**

**Margin Status for Invasive Carcinoma**

\_\_\_ All margins negative for invasive carcinoma

**+Closest Margin(s) to Invasive Carcinoma (select all that apply)**

\_\_\_ Deep (radial): \_\_\_\_\_  
\_\_\_ Duodenal mucosal: \_\_\_\_\_  
\_\_\_ Pancreatic duct: \_\_\_\_\_  
\_\_\_ Bile duct: \_\_\_\_\_  
\_\_\_ Pancreatic neck / parenchymal: \_\_\_\_\_  
\_\_\_ Uncinate (retroperitoneal / superior mesenteric artery): \_\_\_\_\_  
\_\_\_ Proximal (gastric or duodenal): \_\_\_\_\_  
\_\_\_ Distal (duodenal or jejunal): \_\_\_\_\_  
\_\_\_ Other (specify): \_\_\_\_\_  
\_\_\_ Cannot be determined: \_\_\_\_\_

**+Distance from Invasive Carcinoma to Closest Margin**

*Specify in Centimeters (cm)*

\_\_\_ Exact distance in cm: \_\_\_\_\_ cm  
\_\_\_ Greater than 1 cm

*Specify in Millimeters (mm)*

\_\_\_ Exact distance in mm: \_\_\_\_\_ mm

\_\_\_ Greater than 10 mm

*Other*

\_\_\_ Other (specify): \_\_\_\_\_

\_\_\_ Cannot be determined: \_\_\_\_\_

\_\_\_ Not applicable: \_\_\_\_\_

\_\_\_ Invasive carcinoma present at margin

**Margin(s) Involved by Invasive Carcinoma (select all that apply)**

\_\_\_ Deep (radial): \_\_\_\_\_

\_\_\_ Duodenal mucosal: \_\_\_\_\_

\_\_\_ Pancreatic duct: \_\_\_\_\_

\_\_\_ Bile duct: \_\_\_\_\_

\_\_\_ Pancreatic neck / parenchymal: \_\_\_\_\_

\_\_\_ Uncinate (retroperitoneal / superior mesenteric artery): \_\_\_\_\_

\_\_\_ Proximal (gastric or duodenal): \_\_\_\_\_

\_\_\_ Distal (duodenal or jejunal): \_\_\_\_\_

\_\_\_ Other (specify): \_\_\_\_\_

\_\_\_ Cannot be determined (explain): \_\_\_\_\_

\_\_\_ Other (specify): \_\_\_\_\_

\_\_\_ Cannot be determined (explain): \_\_\_\_\_

\_\_\_ Not applicable

**Margin Status for Dysplasia and Intraepithelial Neoplasia (select all that apply)**

\_\_\_ All margins negative for high-grade dysplasia and / or high-grade intraepithelial neoplasia

\_\_\_ High-grade dysplasia and / or high-grade intraepithelial neoplasia present at margin

**Margin(s) Involved by High-Grade Dysplasia and / or High-Grade Intraepithelial Neoplasia (select all that apply)**

\_\_\_ Pancreatic neck / parenchymal margin: \_\_\_\_\_

\_\_\_ Bile duct margin: \_\_\_\_\_

\_\_\_ Proximal (gastric or duodenal): \_\_\_\_\_

\_\_\_ Distal (duodenal or jejunal): \_\_\_\_\_

\_\_\_ Other (specify): \_\_\_\_\_

\_\_\_ Cannot be determined (explain): \_\_\_\_\_

\_\_\_ Other (specify): \_\_\_\_\_

\_\_\_ Cannot be determined (explain): \_\_\_\_\_

\_\_\_ Not applicable

**+Margin Comment:** \_\_\_\_\_

**REGIONAL LYMPH NODES**

**Regional Lymph Node Status**

\_\_\_ Not applicable (no regional lymph nodes submitted or found)

\_\_\_ Regional lymph nodes present

\_\_\_ All regional lymph nodes negative for tumor

\_\_\_ Tumor present in regional lymph node(s)

**Number of Lymph Nodes with Tumor**

- ☐ Exact number (specify): \_\_\_\_\_
- ☐ At least (specify): \_\_\_\_\_
- ☐ Other (specify): \_\_\_\_\_
- ☐ Cannot be determined (explain): \_\_\_\_\_
- ☐ Other (specify): \_\_\_\_\_
- ☐ Cannot be determined (explain): \_\_\_\_\_

**Number of Lymph Nodes Examined**

- ☐ Exact number: \_\_\_\_\_
- ☐ At least (specify): \_\_\_\_\_
- ☐ Other (specify): \_\_\_\_\_
- ☐ Cannot be determined (explain): \_\_\_\_\_

**+Regional Lymph Node Comment:** \_\_\_\_\_

**DISTANT METASTASIS**

**Distant Site(s) Involved, if applicable (select all that apply)**

- ☐ Not applicable
- ☐ Non-regional lymph node(s): \_\_\_\_\_
- ☐ Liver: \_\_\_\_\_
- ☐ Other (specify): \_\_\_\_\_
- ☐ Cannot be determined: \_\_\_\_\_

**pTNM CLASSIFICATION (AJCC 8th Edition) (Note [H](#))**

*Reporting of pT, pN, and (when applicable) pM categories is based on information available to the pathologist at the time the report is issued. As per the AJCC (Chapter 1, 8th Ed.) it is the managing physician's responsibility to establish the final pathologic stage based upon all pertinent information, including but potentially not limited to this pathology report.*

**Modified Classification (required only if applicable) (select all that apply)**

- ☐ Not applicable
- ☐ y (post-neoadjuvant therapy)
- ☐ r (recurrence)

**pT Category**

- ☐ pT not assigned (cannot be determined based on available pathological information)
- ☐ pT0: No evidence of primary tumor
- ☐ pTis: Carcinoma in situ

*pT1: Tumor limited to ampulla of Vater or sphincter of Oddi or tumor invades beyond the sphincter of Oddi (perisphincteric invasion) and / or into the duodenal submucosa*

- ☐ pT1a: Tumor limited to ampulla of Vater or sphincter of Oddi
- ☐ pT1b: Tumor invades beyond the sphincter of Oddi (perisphincteric invasion) and / or into the duodenal submucosa
- ☐ pT1 (subcategory cannot be determined)

☐ pT2: Tumor invades into the muscularis propria of the duodenum

*pT3: Tumor directly invades the pancreas (up to 0.5 cm) or tumor extends more than 0.5 cm into the pancreas, or extends into peripancreatic or periduodenal tissue or duodenal serosa without involvement of the celiac axis or superior mesenteric artery*

- ☐ pT3a: Tumor directly invades pancreas (up to 0.5 cm)



- ☐ pT3b: Tumor extends more than 0.5 cm into the pancreas, or extends into peripancreatic tissue or periduodenal tissue or duodenal serosa without involvement of the celiac axis or superior mesenteric artery
- ☐ pT3 (subcategory cannot be determined)
- ☐ pT4: Tumor involves the celiac axis, superior mesenteric artery, and / or common hepatic artery, irrespective of size

**T Suffix (required only if applicable)**

- ☐ Not applicable
- ☐ (m) multiple primary synchronous tumors in a single organ

**pN Category**

- ☐ pN not assigned (no nodes submitted or found)
- ☐ pN not assigned (cannot be determined based on available pathological information)
- ☐ pN0: No regional lymph node metastasis
- ☐ pN1: Metastasis to one to three regional lymph nodes
- ☐ pN2: Metastasis to four or more regional lymph nodes

**pM Category (required only if confirmed pathologically)**

- ☐ Not applicable - pM cannot be determined from the submitted specimen(s)
- ☐ pM1: Distant metastasis

**ADDITIONAL FINDINGS (Note [I](#))**

**+Additional Findings (select all that apply)**

- ☐ None identified
- ☐ Dysplasia / adenoma
- ☐ Other (specify): \_\_\_\_\_

**SPECIAL STUDIES**

**+Ancillary Studies (Note [J](#))**

- ☐ Specify: \_\_\_\_\_
- ☐ Not performed

**COMMENTS**

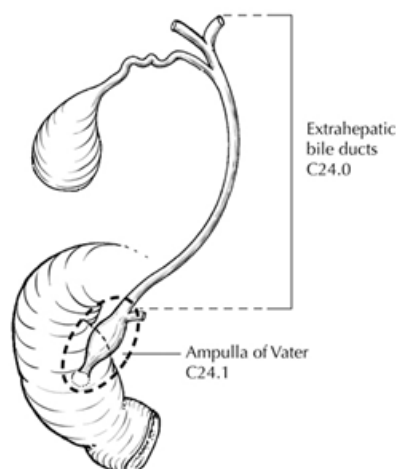
Comment(s): \_\_\_\_\_

## Explanatory Notes

---

### A. Anatomical Considerations

The ampulla of Vater is a complex structure where the distal common bile duct and main pancreatic duct (also known as the duct of Wirsung) converge (Figure 1). The ampulla, encompassing the Wirsung and common bile duct, opens into the duodenal lumen through a small mucosal elevation known as the duodenal papilla (papilla of Vater) (Figure 1). These ducts typically form a common channel in about two-thirds of the population, merge at the orifice of the ampulla in 30%, and rarely (2%) open separately, yet still within the Vaterian complex. The inner surface of the ampulla, composed of the intra-Oddi tips of the Wirsung and common bile duct, is lined with pancreaticobiliary-type ductal epithelium, while the duodenal-facing surface (duodenal papilla) is covered by small intestinal epithelium. At the transitional area of the junction, transitional epithelium, including gastric-like cells, is also observed. The sphincter of Oddi is a smooth muscle band encircling the distal end of the merged ducts.



**Figure 1.** Anatomy of the ampulla of Vater. From Greene et al.<sup>1</sup> Used with permission of the American Joint Committee on Cancer (AJCC), Chicago, Illinois. The original source for this material is the *AJCC Cancer Staging Atlas* (2006) published by Springer Science and Business Media LLC, [www.springerlink.com](http://www.springerlink.com).

Proper examination and dissection are crucial for staging tumors in the region of the ampulla that include distal common bile duct (CBD) and pancreatic ductal adenocarcinomas.<sup>2</sup> Ampullary carcinoma is primarily defined by the bulk of the tumor (>75%) being located in the ampulla.<sup>3</sup> Classification of a carcinoma based on CBD origin relies mainly on the tumor's growth pattern observed grossly. A lesion should be classified as a primary CBD carcinoma, rather than pancreatic ductal carcinoma, only if the bulk of the lesion encircles the CBD, as documented grossly and confirmed microscopically with proper sampling.

Tumors of ampullary-duodenal origin typically form a visible lesion from the duodenal-lumen perspective of the ampulla. These often, but not always, arise from ampullary-duodenal surface adenomas. In contrast, intra-ampullary tumors are characterized by relatively minimal changes in the duodenal surface of the ampulla, and instead most of the pathology occurs inside the ampulla, i.e., the walls and/or lumina of intra-Oddi segments of the Wirsung and CBD, while mostly sparing the duodenal surface. Those intra-ampullary tumors that have prominent mass-forming preinvasive component are classified as intra-ampullary papillary neoplasm-associated. From the duodenal perspective, these typically lead to an

elevated ampulla covered by stretched but relatively normal mucosa, and a patulous orifice of the ampulla from within which some granular material protrude. In contrast, those intra-ampullary tumors without an overt mass-forming preinvasive component are (i.e., the ampullary-ductal group) typically present as subtle sclerotic lesions constricting the duct walls and forming only minimal puckering or erosion of the ampullary-duodenal surface.<sup>3,4</sup>

This strictly anatomic site (and origin)-based classification, which is mostly determined by gross/radiologic/endoscopic examination (and verified by microscopic findings) should not be confused with histologic (microscopic) typing of the tumor. On the other hand, not surprisingly, ampullary-duodenal origin cancers more commonly prove to be intestinal-type by microscopic examination and ampullary-ductal origin ones are much more often pancreatobiliary histologic type.

#### References

1. Greene FL, Compton, CC, Fritz AG, et al, eds. *AJCC Cancer Staging Atlas*. New York, NY: Springer; 2006.
2. Adsay NV, Basturk O, Saka B, et al. Whipple made simple for surgical pathologists: orientation, dissection, and sampling of pancreaticoduodenectomy specimens for a more practical and accurate evaluation of pancreatic, distal common bile duct, and ampullary tumors. *Am J Surg Pathol*. 2014; 38(4): 480-93.
3. Adsay V, Ohike N, Tajiri T, et al. Ampullar region carcinomas: definition and site specific classification with delineation of four clinicopathologically and prognostically distinct subsets in an analysis of 249 cases. *Am J Surg Pathol*. 2012; 36(11): 1592-608.
4. Amin MB, Edge SB, Greene FL, et al, eds. *AJCC Cancer Staging Manual*. 8th ed. New York, NY: Springer; 2017.

#### B. Histologic Type

The staging and subtyping should be done only based on the invasive component which can be pancreaticobiliary-type or intestinal-type or mixed type.<sup>1,2,3</sup> This distinction can be aided by immunohistochemistry for CK20, CDX2, MUC2 and MUC1, but many cases remain ambiguous.<sup>4</sup> While some studies indicate that this distinction is prognostically significant, the issue remains unresolved<sup>5</sup> and more research on true ampullary carcinomas with long-term follow-up is needed to clarify the role of histotyping and immunohistochemistry as theranostic tools.

Pre-invasive mass forming ampullary neoplasms are similar to their pancreatic and bile duct counterparts and the term “intra-ampullary papillary-tubular neoplasm” (IAPN) has been proposed for these tumors.<sup>6</sup> These can be associated with an invasive component. IAPN with an invasive component exhibits aggressive features and lymph node metastasis even when minimally invasive. However, its prognosis is still better than that of the “ampullary-ductal” carcinoma.<sup>7</sup> Report the size of pre-invasive and invasive components separately. T-stage, grade, histologic typing, and other parameters should be determined based solely on the invasive component.

#### References

1. WHO Classification of Tumours Editorial Board. *Digestive system tumours*. Lyon (France): International Agency for Research on Cancer; 2019. (WHO classification of tumours series, 5th ed.; vol. 1).

2. Westgaard A, Tafford S, Farstad IN, et al. Pancreatobiliary versus intestinal histologic type of differentiation is an independent prognostic factor in resected perampullary adenocarcinoma. *BMC Cancer*. 2008; 8:170.
3. Reid MD, Balci S, Ohike N, et al. Ampullary carcinoma is often of mixed or hybrid histologic type: an analysis of reproducibility and clinical relevance of classification as pancreatobiliary versus intestinal in 232 cases. *Mod Pathol*. 2016; 29(12): 1575-1585.
4. Ang DC, Shia J, Tang LH, Katabi N, Klimstra DS. The utility of immunohistochemistry in subtyping adenocarcinoma of the ampulla of vater. *Am J Surg Pathol*. 2014;38(10):1371-1379.
5. Xue Y, Reid MD, Balci S, et al. Immunohistochemical Classification of Ampullary Carcinomas: Critical Reappraisal Fails to Confirm Prognostic Relevance for Recently Proposed Panels, and Highlights MUC5AC as a Strong Prognosticator. *Am J Surg Pathol*. 2017; 41(7): 865-876,
6. Ohike N, Kim GE, Tajiri T, et al. Intra-ampullary papillary-tubular neoplasm (IAPN): characterization of tumoral intraepithelial neoplasia occurring within the ampulla: a clinicopathologic analysis of 82 cases. *Am J Surg Pathol*. 2010;34(12):1731-48.
7. Tarcan ZC, Esmer R, Akar KE, et al. Intra-ampullary papillary tubular neoplasm (IAPN): clinicopathologic analysis of 72 cases highlights the distinctive characteristics of a poorly recognized entity. *Am J Surg Pathol*. 2024; 48(9): 1093-1107.

### C. Histologic Grade

For adenocarcinomas, the following grading system is suggested:

GX Grade cannot be assessed

G1 Well-differentiated (greater than 95% of tumor composed of glands)

G2 Moderately differentiated (50% to 95% of tumor composed of glands)

G3 Poorly differentiated (49% or less of tumor composed of glands)

Poor differentiation has been shown to be an adverse prognostic factor on univariate analysis in some, but not all, series.<sup>1,2</sup>

Signet-ring cell carcinomas are assigned grade 3 by convention. Undifferentiated carcinomas lack morphologic and immunohistochemical evidence of glandular, squamous, or neuroendocrine differentiation. This grading scheme is not applicable to poorly differentiated neuroendocrine carcinomas.

### References

1. Hsu HP, Yang TM, Hsieh YH, Shan YS, Lin PW. Predictors for patterns of failure after pancreaticoduodenectomy in ampullary cancer. *Ann Surg Oncol*. 2007;14(1):50-60.
2. Kim RD, Kundhal PS, McGilvray ID, et al. Predictors of failure after pancreaticoduodenectomy for ampullary carcinoma. *J Am Coll Surg*. Jan 2006;202(1):112-119.

#### D. Tumor Size Evaluation of Invasive Carcinoma Associated with Intra-ampullary Papillary-tubular Neoplasm

The invasive component in intra-ampullary papillary-tubular neoplasm may be unifocal or multifocal. In multifocal invasive carcinoma, it is recommended to include the size of the largest focus, the combined size of all invasive foci, and/or the percentage of invasive tumor relative to the gross tumor size (See also Note H).

#### E. Non-TNM Prognostic Factors

Although not included in the TNM staging system for tumors of the ampulla of Vater, independent prognostic factors include patient age, perineural and vascular invasion, margin status, and tumor budding; size of invasive carcinoma, histologic type, and grade appear to play a lesser role.<sup>1,2,3,4</sup>

#### References

1. WHO Classification of Tumours Editorial Board. *Digestive system tumours*. Lyon (France): International Agency for Research on Cancer; 2019. (WHO classification of tumours series, 5th ed.; vol. 1).
2. Ohike N, Coban I, Kim GE, et al. Tumor budding as a strong prognostic indicator in invasive ampullary adenocarcinoma. *Am J Surg Pathol*. 2010; 34(10): 1417-1424.
3. Bouvet M, Gamagami RA, Gilpin EA, et al. Factors influencing survival after resection for periampullary neoplasms. *Am J Surg*. 2000;180(1):13-17.
4. Bettschart V, Rahman MQ, Engelken FJ, Madhavan KK, Parks RW, Garden OJ. Presentation, treatment and outcome in patients with ampullary tumours. *Br J Surg*. 2004;91(12):1600-1607.

#### F. Treatment Effect

Response of tumor to previous chemotherapy or radiation therapy should be reported. Several scoring systems have been described, and a modified Ryan scheme<sup>1</sup> is recommended, as below:

#### Modified Ryan Scheme for Tumor Regression Score

Description	Tumor Regression Score
No viable cancer cells (complete response)	0
Single cells or rare small groups of cancer cells (near complete response)	1
Residual cancer with evident tumor regression, but more than single cells or rare small groups of cancer cells (partial response)	2
Extensive residual cancer with no evident tumor regression (poor or no response)	3

Sizable pools of acellular mucin may be present after chemoradiation but should not be interpreted as representing residual tumor. It is suggested that to estimate the approximate size of the tumor by adding the size of all the viable tumor foci within the tumor mass based on the histologic evaluation. Only the extent or the size of the viable tumor should be used to assign the ypT category as site appropriate, and this requires a combined assessment of both gross and microscopic findings.

This protocol does not preclude the use of other systems for assessment of tumor response.<sup>2,3,4,5,6</sup> A modification of the above scoring scheme into a 3-tier scheme has been shown to correlate better with outcome: no residual carcinoma (grade 0), minimal residual carcinoma defined as single cells or small groups of cancer cells, <5% residual carcinoma (grade 1), 5% or more residual carcinoma (grade 2).<sup>7,8</sup>

## References

1. Ryan R, Gibbons D, Hyland JMP, et al. Pathological response following long-course neoadjuvant chemoradiotherapy for locally advanced rectal cancer. *Histopathology*. 2005; 47:141-146.
2. Evans DB, Rich TA, Byrd DR, et al. Preoperative chemoradiation and pancreaticoduodenectomy for adenocarcinoma of the pancreas. *Arch Surg*. 1992; 127:1335-1339.
3. Breslin TM, Hess KR, Harbison DB, et al. Neoadjuvant chemoradiotherapy for adenocarcinoma of the pancreas: treatment variables and survival duration. *Ann Surg Oncol*. 2001;8(2):123-132.
4. Wang H, Chetty R, Hosseini M, et al. Pathologic Examination of Pancreatic Specimens Resected for Treated Pancreatic Ductal Adenocarcinoma: Recommendations from the Pancreatobiliary Pathology Society. *Am J Surg Pathol*. 2022;46(6):754-764.
5. Janssen BV, Tutucu F, Roessel S, et al. Amsterdam International Consensus Meeting: Tumor Response Scoring in the Pathology Assessment of Resected Pancreatic Cancer After Neoadjuvant Therapy. *Mod Pathol*. 2021;34(1):4-12.
6. Janssen BV, Roessel S, Dieren S, et al. Histopathological Tumor Response Scoring in Resected Pancreatic Cancer Following Neoadjuvant Therapy: International Interobserver Study (ISGPP-1). *Br J Surg*. 2022;110(1):67-75.
7. Chatterjee D, Katz MH, Rashid A, et al. Histologic grading of the extent of residual carcinoma following neoadjuvant chemoradiation in pancreatic ductal adenocarcinoma: a predictor for patient outcome. *Cancer*. 2012;118(12):3182-3190.
8. Lee SM, Katz MH, Liu L, et al. Validation of a proposed tumor regression grading scheme for pancreatic ductal adenocarcinoma after neoadjuvant therapy as a prognostic indicator for survival. *Am J Surg Pathol*. 2016;40(12):1653-1660.

## G. Margins

Local recurrence from invasive carcinoma in the region of the pancreatic head, including ampullary cancers invading the pancreas, most often occurs at the uncinate margin (retroperitoneal or superior mesenteric artery margin) of the pancreatic head. Because this is a critical margin, inking the uncinate margin and submitting sections through the tumor at its closest approach to this margin is recommended. Complete en face sections of the pancreatic neck/parenchymal resection margin and the resection margin of the common bile duct should also be taken. Microscopically positive margins of resection (R1) have been shown to have an adverse impact on prognosis in ampullary carcinoma.<sup>1</sup>

## References

1. Todoroki T, Koike N, Morishita Y, et al. Patterns and predictors of failure after curative resections of carcinoma of the ampulla of Vater. *Ann Surg Oncol*. 2003;10(10):1176-1183.

## H. pTNM Classification

The TNM staging system for tumors of the ampulla of Vater of the American Joint Committee on Cancer (AJCC) and the International Union Against Cancer (UICC) is recommended and shown below.<sup>1</sup> The postresection prognosis of a patient with ampullary carcinoma is primarily determined by the anatomic extent of disease as defined by the TNM classification and stage groupings.

By AJCC/UICC convention, the designation “T” refers to a primary tumor that has not been previously treated. The symbol “p” refers to the pathologic classification of the TNM, as opposed to the clinical classification, and is based on gross and microscopic examination. pT entails a resection of the primary

tumor or biopsy adequate to evaluate the highest pT category, pN entails removal of nodes adequate to validate lymph node metastasis, and pM implies microscopic examination of distant lesions. Clinical classification (cTNM) is usually carried out by the referring physician before treatment during initial evaluation of the patient or when pathologic classification is not possible.

Pathologic staging is usually performed after surgical resection of the primary tumor. Pathologic staging depends on pathologic documentation of the anatomic extent of disease, whether or not the primary tumor has been completely removed. If a biopsied tumor is not resected for any reason (e.g., when technically infeasible) and if the highest T and N categories or the M1 category of the tumor can be confirmed microscopically, the criteria for pathologic classification and staging have been satisfied without total removal of the primary cancer.

#### TNM Descriptors

For identification of special cases of TNM or pTNM classifications, the “m” suffix and “y” and “r” prefixes are used. Although they do not affect the stage grouping, they indicate cases needing separate analysis.

The “m” suffix indicates the presence of multiple primary tumors in a single site and is recorded in parentheses: pT(m)NM.

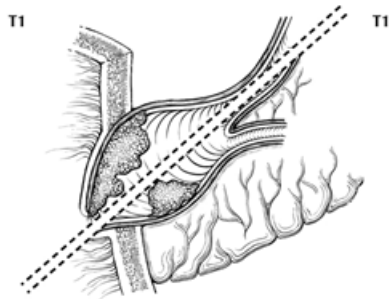
The “y” prefix indicates those cases in which classification is performed during or after initial multimodality therapy (i.e., neoadjuvant chemotherapy, radiation therapy, or both chemotherapy and radiation therapy). The cTNM or pTNM category is identified by a “y” prefix. The ycTNM or ypTNM categorizes the extent of tumor actually present at the time of that examination. The “y” categorization is not an estimate of tumor before multimodality therapy (i.e., before initiation of neoadjuvant therapy).

The “r” prefix indicates a recurrent tumor when staged after a documented disease-free interval and is identified by the “r” prefix: rTNM.

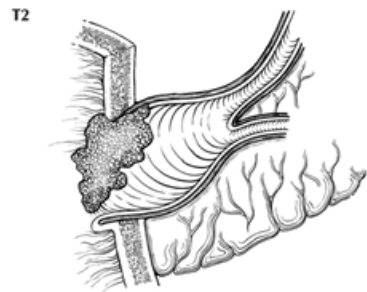
#### T Category Considerations

For ampullary carcinomas, carcinoma in situ (pTis) as a staging term includes cancer cells confined within the glandular basement membrane (high-grade dysplasia). The term carcinoma in situ is not widely applied to glandular neoplastic lesions in the gastrointestinal tract but is retained for tumor registry reporting purposes as specified by law in many states. Non-invasive ampullary carcinomas with a papillary growth pattern (intra-ampullary papillary-tubular neoplasms) are classified as pTis. The revised T categories in the AJCC 8<sup>th</sup> edition address the discrepancies in the previous definitions and correlate better with outcome.<sup>2,3</sup> A synoptic report is required only for invasive tumors, but not Tis, i.e. intra-ampullary papillary-tubular neoplasm (IAPN) in the absence of an invasive component for accreditation purposes. For invasive carcinoma associated with intra-ampullary papillary-tubular neoplasm only the invasive component should be used to determine the T category. The invasive portion in these cases can be multifocal and the deepest focus of invasion should be used for T staging.

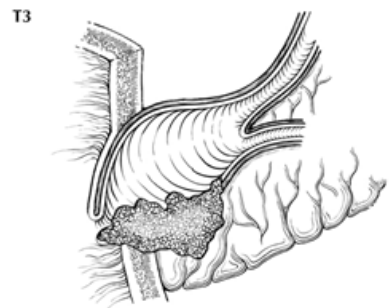
T categories are illustrated in Figures 2-5.



**Figure 2.** T1a tumors are limited to the ampulla of Vater (below the dotted line) or sphincter of Oddi (above the dotted line). From Greene et al.<sup>4</sup> Used with permission of the American Joint Committee on Cancer (AJCC), Chicago, Illinois. The original source for this material is the *AJCC Cancer Staging Atlas* (2006) published by Springer Science and Business Media LLC, [www.springerlink.com](http://www.springerlink.com).

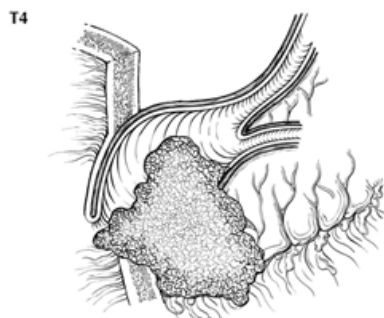


**Figure 3.** T1b tumors invade beyond the sphincter of Oddi or into duodenal submucosa. From Greene et al.<sup>4</sup> Used with permission of the American Joint Committee on Cancer (AJCC), Chicago, Illinois. The original source for this material is the *AJCC Cancer Staging Atlas* (2006) published by Springer Science and Business Media LLC, [www.springerlink.com](http://www.springerlink.com).



**Figure 4.** T3a tumors directly invade pancreas up to 0.5 cm. From Greene et al.<sup>4</sup> Used with permission of the American Joint Committee on Cancer (AJCC), Chicago, Illinois. The original source for this material is the *AJCC Cancer Staging Atlas* (2006) published by Springer Science and Business Media LLC, [www.springerlink.com](http://www.springerlink.com).



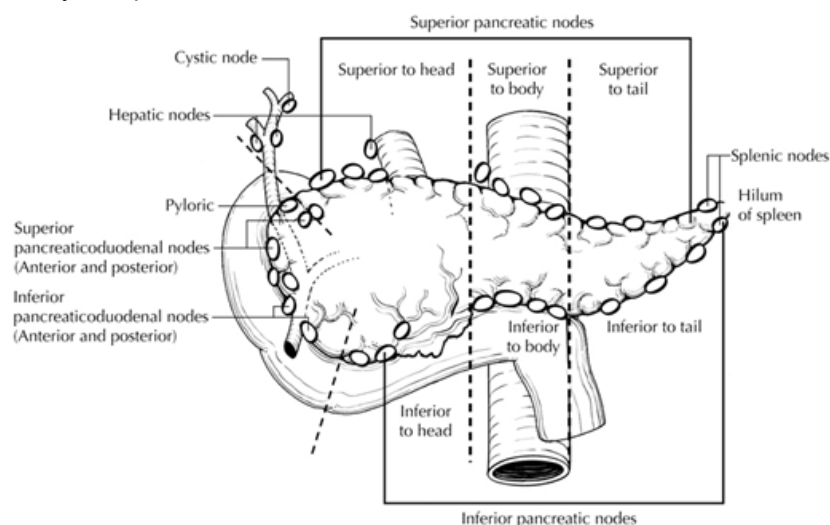


**Figure 5.** T3b tumors extend more than 0.5 cm into pancreas, peripancreatic fat (shown) or duodenal serosa From Greene et al.<sup>4</sup> Used with permission of the American Joint Committee on Cancer (AJCC), Chicago, Illinois. The original source for this material is the *AJCC Cancer Staging Atlas* (2006) published by Springer Science and Business Media LLC, [www.springerlink.com](http://www.springerlink.com).

#### N Category Considerations

Regional lymph node metastases have been shown to have independent significance as an adverse prognostic factor in multiple series.<sup>5,6,7</sup> Evaluation of a minimum of 12 lymph nodes in Whipple resections is recommended for optimal staging.<sup>2,8,9</sup>

The regional nodes (Figure 6) include peripancreatic lymph nodes as well as lymph nodes along hepatic artery and portal vein.



**Figure 6.** Regional lymph nodes of the ampulla of Vater. From Greene et al.<sup>4</sup> Used with permission of the American Joint Committee on Cancer (AJCC), Chicago, Illinois. The original source for this material is the *AJCC Cancer Staging Atlas* (2006) published by Springer Science and Business Media LLC, [www.springerlink.com](http://www.springerlink.com).

Tumor involvement of other nodal groups is considered distant metastasis. Anatomic division of regional lymph nodes is not necessary, but separately submitted lymph nodes should be individually reported as received.

Routine assessment of regional lymph nodes is limited to conventional pathologic techniques (gross assessment and histologic examination), and data are currently insufficient to recommend special measures to detect micrometastasis or isolated tumor cells. Thus, neither multiple levels of paraffin blocks nor the use of special/ancillary techniques such as immunohistochemistry are recommended for routine examination of regional lymph nodes.

#### Vessel Invasion

By AJCC convention, vessel invasion (small vessel or venous) does not affect the T category indicating local extent of tumor unless specifically included in the definition of a T category.

#### References

1. Amin MB, Edge SB, Greene FL, et al, eds. *AJCC Cancer Staging Manual*. 8th ed. New York, NY: Springer; 2017.
2. Adsay NV, Bagci P, Tajiri T, et al. Pathologic staging of pancreatic, ampullary, biliary, and gallbladder cancers: pitfalls and practical limitations of the current AJCC/UICC TNM staging system and opportunities for improvement. *Semin Diagn Pathol*. 2012; 29(3):127-41.
3. You D, Heo J, Choi S, Choi D, Jang K-T. Pathologic T1 subclassification of ampullary carcinoma with perisphincteric or duodenal submucosal invasion: is it T1b? *Arch Pathol Lab Med*. 2014;138(8):1072.
4. Greene FL, Compton CC, Fritz AG, et al, eds. *AJCC Cancer Staging Atlas*. New York, NY: Springer; 2006.
5. Hsu HP, Yang TM, Hsieh YH, Shan YS, Lin PW. Predictors for patterns of failure after pancreaticoduodenectomy in ampullary cancer. *Ann Surg Oncol*. 2007;14(1):50-60.
6. Riall TS, Cameron JL, Lillemoe KD, et al. Resected periampullary adenocarcinoma: 5-year survivors and their 6- to 10-year follow-up. *Surgery*. 2006;140(5):764-772.
7. Sakata J, Shirai Y, Wakai T, et al. Number of positive lymph nodes independently affects long-term survival after resection in patients with ampullary carcinoma. *Eur J Surg Oncol*. 2007;33(3):346-351.
8. Partelli S, Crippa S, Capelli P, et al. Adequacy of lymph node retrieval for ampullary cancer and its association with improved staging and survival. *World J Surg*. 2013; 37(6):1397-1404.
9. Balci S, Basturk O, Saka B, et al. Substaging nodal status in ampullary carcinomas has significant prognostic value: proposed revised staging based on an analysis of 313 well-characterized cases. *Ann Surg Oncol*. 2015:1-10.

#### **I. Additional Findings**

Ampullary adenomas are common in patients with familial adenomatous polyposis coli, and such patients are at increased risk for ampullary adenocarcinomas. Estimated lifetime incidence is roughly 12% for ampullary carcinoma in this population.<sup>1</sup> Ampullary adenocarcinoma can also occur in patients with Lynch syndrome.

#### References

1. Partelli S, Crippa S, Capelli P, et al. Adequacy of lymph node retrieval for ampullary cancer and its association with improved staging and survival. *World J Surg*. 2013; 37(6):1397-1404.

## J. Ancillary Studies

Immunohistochemistry (MMR IHC) and/or microsatellite instability (MSI) testing are now essential not only for identifying Lynch syndrome but also for detecting mismatch repair deficient (dMMR) tumors because FDA approved immune checkpoint inhibitors are now available for any malignancy irrespective of histologic type or location.<sup>1,2</sup> Now NCCN also suggests considering testing it for adenocarcinomas of the small intestine, stomach, pancreas, and biliary tract.<sup>3</sup> Absence of DNA mismatch repair (MMR) proteins by immunohistochemistry has been described in 5-10% of ampullary adenocarcinomas.<sup>4,5</sup> Similarly, targeted therapies for HER2 have expanded beyond non-breast and non-gastric gastrointestinal cancers.<sup>6,7</sup> HER2 testing for advanced gastrointestinal cancers (stage IV, recurrent, or unresectable) is becoming more common, although standardized reporting guidelines for non-gastric gastrointestinal cancers are still lacking. While criteria applicable for colorectal cancer have been developed,<sup>8,9</sup> the ASCO/College of American Pathology guidelines for gastric cancer HER2 scoring have been applied in recent clinical trials for other gastrointestinal cancers.<sup>10</sup> It is suggested that while reporting HER2 it is a good practice to indicate the criteria used. Further details about mismatch repair enzyme immunohistochemistry and PCR for MSI testing, as well as other ancillary molecular testing, can be found in the CAP Biomarkers protocol.

## References

1. Bartley AN, Mills AM, Konnick E, et al. Mismatch Repair and Microsatellite Instability Testing for Immune Checkpoint Inhibitor Therapy: Guideline from the College of American Pathologists in Collaboration with the Association for Molecular Pathology and Fight Colorectal Cancer. *Arch Pathol Lab Med*. 2022, 146(10):1194-1210.
2. Abrha A, Shukla ND, Hodan R, et al. Universal Screening of Gastrointestinal Malignancies for Mismatch Repair Deficiency at Stanford. *JNCI Cancer Spectr*. 2020, 19; 4(5): pkaa054.
3. Weiss JM, Gupta S, Burke CA, et al. NCCN Guidelines® Insights: Genetic/Familial High-Risk Assessment: Colorectal, Version 1.2021. *J Natl Compr Canc Netw*. 2021, 15; 19(10):1122-1132.
4. Agaram NP, Shia J, Tang LH, et al. DNA mismatch repair deficiency in ampullary carcinoma: a morphologic and immunohistochemical study of 54 cases. *Am J Clin Pathol*. 2010;133:772-780.
5. Xue Y, Balci S, Mericcoz A, et al. Frequency and clinicopathologic associations of DNA mismatch repair protein deficiency in ampullary carcinoma: routine testing is indicated. *Cancer* 2020; 126:4788-4799.
6. Yoon J and Do-Youn Oh DY. HER2-targeted therapies beyond breast cancer - an update. *Nat Rev Clin Oncol*. 2024, 21(9):675-700.
7. <https://www.fda.gov/drugs/resources-information-approved-drugs/fda-grants-accelerated-approval-fam-trastuzumab-deruxtecan-nxki-unresectable-or-metastatic-her2>
8. Valtorta E, Martino C, Sartore-Bianchi A, et al. Assessment of a HER2 scoring system for colorectal cancer: results from a validation study. *Mod Pathol*. 2015, 28(11):1481-91.
9. Meric-Bernstam F, Hurwitz H, Raghav KPS, et al. Pertuzumab plus trastuzumab for HER2-amplified metastatic colorectal cancer (MyPathway): an updated report from a multicentre, open-label, phase 2a, multiple basket study. *Lancet Oncol*. 2019, 20 (4): 518-530.
10. Meric-Bernstam F, Makker V, Oaknin A, et al. Efficacy and Safety of Trastuzumab Deruxtecan in Patients with HER2-Expressing Solid Tumors: Primary Results from the DESTINY-PanTumor02 Phase II Trial. *J Clin Oncol*. 2024, 42(1):47-58.