



Protocol for the Examination of Biopsy Specimens from Pediatric Patients with Ewing Sarcoma

Version: 5.0.0.1

Protocol Posting Date: June 2025

CAP Laboratory Accreditation Program Protocol Required Use Date: June 2024

The changes included in this current protocol version do not affect the prior accreditation date.

For accreditation purposes, this protocol should be used for the following procedures AND tumor types:

Procedure	Description
Biopsy	Includes specimens designated core needle biopsy, incisional biopsy, excisional biopsy, or other
Tumor Type	Description
Ewing sarcoma	Includes pediatric patients with osseous and extraosseous Ewing sarcoma family of tumors

The following should NOT be reported using this protocol:

Procedure
Resection (consider Pediatric Ewing Sarcoma Resection protocol)
Tumor Type
Adult Ewing sarcoma# (consider using bone or soft tissue protocols) Round cell sarcoma with EWSR1-non ETS fusions, CIC-rearranged sarcoma, or sarcoma with BCOR-genetic alterations (consider using Bone or Soft Tissue protocols)

#Ewing sarcoma in adults may be treated differently than pediatric Ewing sarcoma and use of the AJCC TNM staging system remains appropriate for adult patients.

Version Contributors

Cancer Committee Authors: Jessica L. Davis, MD*

Other Expert Contributors: Erin Rudzinski, MD, Archana Shenoy, MD, Lea Surrey, MD, Alyaa Al-Ibraheemi, MD, Katherine Janeway, MD, Elyssa Rubin, MD

* Denotes primary author.

For any questions or comments, contact: cancerprotocols@cap.org.

Glossary:

Author: Expert who is a current member of the Cancer Committee, or an expert designated by the chair of the Cancer Committee.

Expert Contributors: Includes members of other CAP committees or external subject matter experts who contribute to the current version of the protocol.

Accreditation Requirements

Synoptic reporting with core and conditional data elements for designated specimen types* is required for accreditation.

- Data elements designated as core must be reported.
- Data elements designated as conditional only need to be reported if applicable.
- Data elements designated as optional are identified with "+". Although not required for accreditation, they may be considered for reporting.

This protocol is not required for recurrent or metastatic tumors resected at a different time than the primary tumor. This protocol is also not required for pathology reviews performed at a second institution (i.e., second opinion and referrals to another institution).

Full accreditation requirements can be found on the CAP website under [Accreditation Checklists](#).

A list of core and conditional data elements can be found in the Summary of Required Elements under Resources on the CAP Cancer Protocols [website](#).

**Includes definitive primary cancer resection and pediatric biopsy tumor types.*

Synoptic Reporting

All core and conditionally required data elements outlined on the surgical case summary from this cancer protocol must be displayed in synoptic report format. Synoptic format is defined as:

- Data element: followed by its answer (response), outline format without the paired Data element: Response format is NOT considered synoptic.
- The data element should be represented in the report as it is listed in the case summary. The response for any data element may be modified from those listed in the case summary, including "Cannot be determined" if appropriate.
- Each diagnostic parameter pair (Data element: Response) is listed on a separate line or in a tabular format to achieve visual separation. The following exceptions are allowed to be listed on one line:
 - Anatomic site or specimen, laterality, and procedure
 - Pathologic Stage Classification (pTNM) elements
 - Negative margins, as long as all negative margins are specifically enumerated where applicable
- The synoptic portion of the report can appear in the diagnosis section of the pathology report, at the end of the report or in a separate section, but all Data element: Responses must be listed together in one location
- Organizations and pathologists may choose to list the required elements in any order, use additional methods in order to enhance or achieve visual separation, or add optional items within the synoptic report. The report may have required elements in a summary format elsewhere in the report IN ADDITION TO but not as replacement for the synoptic report i.e., all required elements must be in the synoptic portion of the report in the format defined above.

CAP
Approved

PNET_Ewing.Bx_5.0.0.1.REL_CAPCP

Summary of Changes

v 5.0.0.1

- Accreditation statement update
- eCP explanatory note electronic link updates
- Lymphovascular Invasion question updated to Lymphatic and / or Vascular Invasion

Reporting Template

Protocol Posting Date: June 2025

Select a single response unless otherwise indicated.

CASE SUMMARY: (EWING SARCOMA: Biopsy)

EXPERT CONSULTATION

+Expert Consultation (Note [A](#))

- ☐ Pending - Completion of this CAP Cancer Protocol is awaiting expert consultation
- ☐ Completed - This CAP Cancer Protocol or some elements have been performed following expert consultation
- ☐ Not applicable

SPECIMEN (Note [B](#))

Procedure (Note [C](#))

- ☐ Core needle biopsy
- ☐ Incisional biopsy
- ☐ Excisional biopsy
- ☐ Other (specify): _____
- ☐ Not specified

TUMOR

Tumor Site

- ☐ Osseous
 - ☐ Long bones of upper limb, scapula and associated joints (specify): _____
 - ☐ Short bones of upper limb and associated joints (specify): _____
 - ☐ Long bones of lower limb and associated joints (specify): _____
 - ☐ Short bones of lower limb and associated joints (specify): _____
 - ☐ Overlapping lesion of bones, joints and articular cartilage of limbs (specify): _____
 - ☐ Bone of limb, NOS (specify): _____
 - ☐ Bones of skull and face and associated joints (excluding mandible C41.1) (specify): _____
 - ☐ Mandible (specify): _____
 - ☐ Vertebral column (excluding sacrum and coccyx C41.4) (specify): _____
 - ☐ Rib, sternum, clavicle and associated joints (specify): _____
 - ☐ Pelvic bones, sacrum, coccyx and associated joints (specify): _____
 - ☐ Overlapping lesion of bones, joints and articular cartilage (specify): _____
 - ☐ Bone, NOS: _____
- ☐ Extraosseous
 - ☐ Heart / mediastinum
 - ☐ Heart (specify): _____
 - ☐ Anterior mediastinum (specify): _____
 - ☐ Posterior mediastinum (specify): _____
 - ☐ Mediastinum, NOS: _____

- ☐ Overlapping lesion of heart, mediastinum and pleura (specify): _____
- ☐ Peritoneum and / or retroperitoneum
- ☐ Retroperitoneum: _____
- ☐ Peritoneum, including omentum and mesentery (specify parts): _____
- ☐ Peritoneum, NOS: _____
- ☐ Other soft tissue
- ☐ Head, face, and neck (specify): _____
- ☐ Upper limb and shoulder (specify): _____
- ☐ Lower limb and hip (specify): _____
- ☐ Thorax (specify): _____
- ☐ Abdomen (specify): _____
- ☐ Pelvis (specify): _____
- ☐ Trunk (specify): _____
- ☐ Overlapping lesion (specify): _____
- ☐ Other, NOS: _____
- ☐ Not specified

Tumor Size (for excisional biopsy only)

- ☐ Not applicable
- ☐ Greatest dimension in Centimeters (cm): _____ cm
- +Additional Dimension in Centimeters (cm): _____ x _____ cm**
- ☐ Cannot be determined (explain): _____

Lymphatic and / or Vascular Invasion (Note [D](#))

- ☐ Not identified
- ☐ Present
- ☐ Cannot be determined: _____

MARGINS

Margin Status (for excisional biopsy only) (Note [E](#))

- ☐ Not applicable (not an excisional biopsy)
- ☐ All margins negative for tumor
- Closest Margin(s) to Tumor**
- ☐ Specify closest margin(s): _____
- ☐ Cannot be determined (explain): _____
- Distance from Tumor to Closest Margin**
- Specify in Centimeters (cm)*
- ☐ Exact distance: _____ cm
- ☐ Greater than: _____ cm
- ☐ Other (specify): _____
- ☐ Cannot be determined: _____
- ☐ Tumor present at margin
- Margin(s) Involved by Tumor**
- ☐ Specify involved margin(s): _____
- ☐ Cannot be determined (explain): _____

CAP
Approved

PNET_Ewing.Bx_5.0.0.1.REL_CAPCP

___ Cannot be determined (explain): _____

+Margin Comment: _____

SPECIAL STUDIES (Note [F](#))

Results of these studies may not be available at the time of the final report

+Immunohistochemistry (specify): _____

Cytogenetic Findings

- ___ Not performed
- ___ Pending
- ___ EWSR1 rearrangement, fusion partner not known
- ___ EWSR1-FLI1 gene rearrangement
- ___ EWSR1-ERG gene rearrangement
- ___ Other EWSR1 gene rearrangement (specify): _____
- ___ Non-EWSR1 variant translocation (specify): _____
- ___ Other (specify): _____
- ___ No rearrangement identified
- ___ Not known

Method for Cytogenetic Studies

- ___ Not applicable (Cytogenetic Studies not performed)
- ___ Conventional karyotyping
- ___ Fluorescent in situ hybridization (FISH)
- ___ Reverse transcriptase polymerase chain reaction (RT-PCR)
- ___ Other (specify): _____
- ___ Not known

ADDITIONAL FINDINGS

+Additional Findings (specify): _____

COMMENTS

Comment(s): _____

Explanatory Notes

A. Expert Consultation

Expert consultation is not required. This question has been added to annotate, if so desired, that the case has been sent out for consultation and thus items of the CAP protocol could not be completed pending expert consultation. Completion of the CAP protocol will then be performed following consultation.

B. Tissue Handling

Tissue specimens optimally are received fresh/unfixed because of the importance of ancillary studies, such as cytogenetics and molecular testing, which may prefer fresh tissue. First priority should always be given to formalin-fixed tissues (FFPE) for morphologic evaluation. Ideally, some tissue can be submitted for FFPE without decalcification or following decalcification in EDTA or EDTA+acid decalcification solutions to preserve nucleic acids for molecular testing, to including FISH, RT-PCR, and/or next generation sequencing (NGS). Decalcification in pure acid decalcification solutions degrade nucleic acids and limit molecular testing. Following submission of FFPE, submission of fresh tissue for cytogenetics and/or snap freezing a minimum of 100 mg of viable tumor may be needed potential molecular studies and/or COG study purposes.¹ Molecular testing on formalin-fixed paraffin-embedded tissue may be performed for FISH evaluation of *EWSR1* rearrangement, for RT-PCR evaluation of *EWSR1-FLI1*, *EWSR1-ERG*, and other ES translocations, or NGS. When the amount of tissue is limited, the pathologist can keep the frozen tissue aliquot used for frozen section (usually done to determine sample adequacy and viability) in a frozen state (-70°C is preferable). Translocations may be detected using RT-PCR on frozen or fixed paraffin-embedded tissue, or FISH on touch preparations made from fresh tissue or formalin-fixed paraffin-embedded tissue.

Note that classification of many subtypes of sarcoma is not always dependent upon special studies, such as cytogenetics or molecular genetics, but frozen tissue may be required to enter patients into treatment protocols. Discretion should be used in triaging tissue from sarcomas. Adequate tissue should be submitted for conventional light microscopy before tissue has been taken for cytogenetics, electron microscopy, or molecular analysis.

References

1. Qualman SJ, Morotti RA. Risk assignment in pediatric soft-tissue sarcoma: an evolving molecular classification. *Curr Oncol Rep*. 2002;4:123-130.

C. Procedures

Cytologic Material

Cytological material is usually sufficient to diagnose ES (with supportive immunostains) (Note E). An important limitation of fine-needle aspiration is the limited amount of tissue for additional molecular diagnostic studies¹ and tissue banking (see Note A). Evaluation by a pathologist at the time of the fine-needle biopsy procedure is important to assess the adequacy of the specimen for routine histomorphologic diagnosis and for ancillary studies.²

If cytologic material includes fluid, such as pleural effusions or fluid from a liquefactive tumor, the fluid should be centrifuged and the resulting pellet fixed with formalin prior to making a paraffin cell block. The

resulting cell block allows for histopathologic examination, immunohistochemical, and/or molecular analysis.

Biopsy (Needle, Incisional, Excisional)

An open incisional biopsy consistently provides a larger sample of tissue and maximizes the opportunity for a specific pathologic diagnosis.³ However, image guided needle core biopsies are now being performed with greater frequency. Sampling of multiple lesional cores can provide sufficient material for special studies and histomorphologic diagnosis. Excisional biopsy may not include an adequate margin of normal tissue, even with an operative impression of total gross removal.³

In cases of non-excisional biopsy (e.g., core biopsy, incisional biopsy), the tumor size cannot be determined on pathologic grounds; therefore, imaging data (computed tomography [CT], magnetic resonance imaging [MRI], etc.) can be used instead.

References

1. Qualman SJ, Morotti RA. Risk assignment in pediatric soft-tissue sarcoma: an evolving molecular classification. *Curr Oncol Rep*. 2002; 4:123-130.
2. Patel K, Kinnear D, Quintanilla NM, Hicks J, Castro E, Curry C, Dormans J, Ashton DJ, Hernandez JA, Wu H. Optimal Diagnostic Yield Achieved with On-site Pathology Evaluation of Fine-Needle Aspiration-Assisted Core Biopsies for Pediatric Osseous Lesions: A Single-Center Experience. *Arch Pathol Lab Med*. 2017 May;141(5):678-683. doi: 10.5858/arpa.2016-0269-OA. Epub 2017 Mar 16. PMID: 28301225.
3. Coffin CM, Dehner LP. Pathologic evaluation of pediatric soft tissue tumors. *Am J Clin Pathol*. 1998;109(suppl 1): S38-S52.

D. Lymphovascular Invasion (LVI)

Lymphovascular invasion (LVI) indicates whether microscopic lymphovascular invasion is identified in the pathology report. LVI includes lymphatic invasion, vascular invasion, or lymphovascular invasion. Evaluation of LVI may require immunohistochemical staining for endothelial markers (CD31, CD34, D240, etc.). By American Joint Committee on Cancer (AJCC) and International Union Against Cancer (UICC) convention, LVI does not affect the T category indicating local extent of tumor unless specifically included in the definition of the T category.

E. Margins

The extent of resection (i.e., gross residual disease versus complete resection with negative margins) has the strongest influence on local control of malignancy.¹ The definition of what constitutes a sufficiently “wide” margin of normal tissue in the management of ES and the significance of reactive and/or necrotic tissue at the margin are current study questions for the Children’s Oncology Group, and may evolve in the future. Currently, any tumor at the margin, whether viable, nonviable, or treated, is considered positive. The significance of treated tumor at the margin when there has been an excellent chemotherapeutic response (i.e., greater than 90% tumor necrosis) remains unclear. There is currently no consensus as to whether margins involved by treated tumor require further treatment, and this is considered a negative margin on some studies. The presence of treated tumor at the margin should be reported, however, and can be included in the comment section of the checklist. The following margins are considered adequate:

Cortical bone margin: 2 to 5 cm

Fascia, periosteum, and intermuscular septa: 2 mm

Fat, muscle, and medullary bone: 5 mm

With Ewing sarcoma involving an encapsulated organ, surgical margins are considered to be negative if the organ's capsule is not surgically violated or breached by the tumor.

References

1. Fletcher C, Kempson RL, Weiss S. Recommendations for reporting soft tissue sarcomas. *Am J Clin Pathol*. 1999; 111:594-598.

F. Ancillary Studies

Immunohistochemistry

Immunohistochemistry with monoclonal antibodies against the cell surface glycoprotein CD99 is positive in virtually all cases of ES.¹ This glycoprotein is diffusely expressed in the vast majority of cases in a membranous pattern (Figure 2). The results of staining using monoclonal antibodies O13, HBA71, and 12E7 are similar, but individual tumors may exhibit better staining with one of these antibodies versus other antibodies.

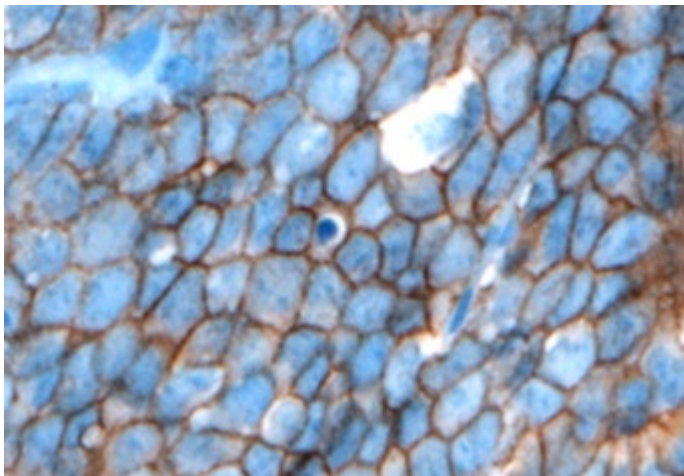


Figure 2. CD99 staining in Ewing sarcoma shows strong, diffuse, membranous staining. (CD99 antibody O13 with hematoxylin counterstain.)

Lymphoblastic lymphomas/leukemias, rhabdomyosarcomas, synovial sarcomas, solitary fibrous tumors, rhabdoid tumors, neuroendocrine tumors, desmoplastic small round cell tumors, and mesenchymal chondrosarcomas may also demonstrate immunoreactivity to CD99. In some of these tumors, CD99 immunostaining is often weakly granular and intracytoplasmic; in others (lymphoblastic lymphoma/leukemia, occasional cases of poorly differentiated synovial sarcoma, alveolar

rhabdomyosarcoma), distinct membrane staining is present, as seen in ES. Because these other tumors with small round cell morphology can exhibit CD99 expression, it is very important to consider including other immunohistochemical stains such as muscle markers (desmin, muscle-specific actin, myoD1, myogenin), S-100, epithelial markers (epithelial membrane antigen, cytokeratin), INI-1, and lymphoid markers (CD45, CD30, TdT, T-cell and/or B-cell markers) when CD99 is performed to properly exclude CD99-expressing tumors. Cytokeratin positivity may be seen in ES and may be diffusely positive in the adamantinoma-like variant of Ewing sarcoma.^{2,3} Newer immunohistochemical antibodies, such as NKX2.2, may also be useful for the diagnosis of ES, although NKX2.2 staining may rarely be seen in other small round cell tumors.⁴ The value of other immunohistochemical markers for diagnosis, such as Ki-67, p53, and C-kit (CD117), has not been established.

Chromosomal Translocations

The 2020 World Health Organization (WHO) classification of bone and soft tissue tumors defines *Ewing sarcoma* as a round cell sarcoma harboring a FET-ETS gene fusion. FET represents a family of genes to include *FUS*, *EWSR1*, and *TAF15*; whereas the ETS gene family is a large family of transcription factors involved in cell cycle regulation, cellular differentiation, among other functions. In relation to Ewing sarcoma, the characteristic translocations involve the *EWSR1* gene at 22q12, most often either the *FLI1* gene at 11q24 (90-95%) or the *ERG* gene at 21q22 (5-10%). These two fusions account for the vast majority of genetic alterations in ES. It should be emphasized that there are numerous other *EWSR1* or *FUS* gene partners that occur in a minority (5%-10%) of ES. The failure to identify an *EWSR1-FLI1* or *EWSR1-ERG* translocation by RT-PCR or cytogenetics does not exclude ES from the diagnosis. If RT-PCR is negative, in the context of a tumor suspicious for ES, other molecular studies (cytogenetics, NGS) may be important for identification of the less common ES translocations and for discovering novel *EWSR1* translocations in ES. Some of the less common ES translocations involve *FUS* (ch16) rather than *EWSR1*, or involve other ETS partners including *ETV1*, *ETV4*, or *FEV*. FISH analysis for *EWSR1* (or *FUS*) is helpful as a first step and may confirm the diagnosis in those tumors with histomorphologic features and immunohistochemical phenotypes of ES. Because other small round cell tumors of childhood can have *EWSR1* rearrangements with specific tumor-defining partners, *EWSR1* FISH positivity alone is not diagnostic of ES. Some of these tumors with *EWSR1* rearrangement include angiomatoid fibrous histiocytoma, clear cell sarcoma of soft parts, desmoplastic round cell tumor, and extraskeletal myxoid chondrosarcoma, as well as a subset of myxoid liposarcomas and myoepithelial carcinoma.

Therefore, considerations when choosing testing methodologies may include, classic versus non-classic histomorphology, immunophenotype, need to confirm translocation partner, turnaround time, cost, and ultimately may be depend on the availability of testing modalities at each institution. While obtaining evidence of a diagnostic fusion is recommended, it should be noted that absence of a fusion can either result from 1) true lack of fusion, 2) test failure (eg. FISH for *EWSR1-ERG* fusions can miss rearrangements) or 3) mismatch between the testing approach and the fusion present (eg. *EWSR1-ERG* present and test is for RT-PCR for *EWSR1-FLI1*). This underscores the necessity for histologic and immunohistochemical correlation with any molecular testing result.⁵

Of note, the specific *EWSR1* translocation and subtype based upon exon fusion type do not influence treatment, prognosis, or outcome.⁶

References

1. Collini P, Sampietro G, Bertulli R, et al. Cytokeratin immunoreactivity in 41 cases of Ewing sarcoma/primitive neuroectodermal tumor confirmed by molecular diagnostic studies. *Am J Surg Pathol*. 2001; 25:273-274.
2. Ambros IM, Ambros PF, Strehl S, Kovar H, Gadner H, Salzer-Kuntschik M. MIC2 is a specific marker for Ewing's sarcoma and peripheral primitive neuroectodermal tumor: evidence for a common histogenesis of Ewing's sarcoma and peripheral neuroectodermal tumors from MIC2 expression and specific chromosome aberration. *Cancer*. 1992; 67:1886-1893.
3. Folpe AL, Goldblum JR, Rubin BP, Shehata BM, Liu W, Dei Tos AP, Weiss SW. Morphologic and immunophenotypic diversity in Ewing family tumors: a study of 66 genetically confirmed cases. *Am J Surg Pathol*. 2005; 29:1025-1033.
4. Machado I, Yoshida A, Lopez-Guerrero JA, Nieto MG, Navarro S, Picci P, Llombart-Bosch A. Immunohistochemical analysis of NKX2.2, ETV4 and BCOR in a large series of genetically confirmed Ewing sarcoma family tumors. *Pathol Res Pract* 2017;213(9):1048-1053.
5. Antonescu C. Round cell sarcomas beyond Ewing: emerging entities. *Histopathology*. 2014; 64:26-37.
6. Van Doorninck JA, Ji L, Schaub B, et al. Current treatment protocols have eliminated the prognostic advantage of Type 1 fusions in Ewing sarcoma: a report from the Children's Oncology Group. *J Clin Oncol*. 2010; 28:1989-1994.