



Protocol for the Examination of Specimens From Patients With Carcinoma of the Ampulla of Vater

Version: 4.2.0.0

Protocol Posting Date: June 2021

CAP Laboratory Accreditation Program Protocol Required Use Date: March 2022

The changes included in this current protocol version affect accreditation requirements. The new deadline for implementing this protocol version is reflected in the above accreditation date.

For accreditation purposes, this protocol should be used for the following procedures AND tumor types:

| Procedure | Description |
|------------|--|
| Resection | Includes specimens designated ampullectomy and pancreaticoduodenectomy (Whipple Resection) |
| Tumor Type | Description |
| Carcinoma | Includes all intra-ampullary, peri-ampullary, and mixed intra- and peri-ampullary carcinomas. Low-grade neuroendocrine tumors (carcinoids) are not included. |

This protocol is NOT required for accreditation purposes for the following:

| Procedure |
|--|
| Biopsy |
| Primary resection specimen with no residual cancer (eg, following neoadjuvant therapy) |
| Cytologic specimens |

The following tumor types should NOT be reported using this protocol:

| Tumor Type |
|---|
| Lymphoma (consider the Hodgkin or non-Hodgkin Lymphoma protocols) |
| Sarcoma (consider the Soft Tissue protocol) |

Authors

Lawrence J. Burgart, MD*; William V. Chopp, MD*; Dhanpat Jain, MD*.

With guidance from the CAP Cancer and CAP Pathology Electronic Reporting Committees.

* Denotes primary author.

Accreditation Requirements

This protocol can be utilized for a variety of procedures and tumor types for clinical care purposes. For accreditation purposes, only the definitive primary cancer resection specimen is required to have the core and conditional data elements reported in a synoptic format.

- Core data elements are required in reports to adequately describe appropriate malignancies. For accreditation purposes, essential data elements must be reported in all instances, even if the response is “not applicable” or “cannot be determined.”
- Conditional data elements are only required to be reported if applicable as delineated in the protocol. For instance, the total number of lymph nodes examined must be reported, but only if nodes are present in the specimen.
- Optional data elements are identified with “+” and although not required for CAP accreditation purposes, may be considered for reporting as determined by local practice standards.

The use of this protocol is not required for recurrent tumors or for metastatic tumors that are resected at a different time than the primary tumor. Use of this protocol is also not required for pathology reviews performed at a second institution (ie, secondary consultation, second opinion, or review of outside case at second institution).

Synoptic Reporting

All core and conditionally required data elements outlined on the surgical case summary from this cancer protocol must be displayed in synoptic report format. Synoptic format is defined as:

- Data element: followed by its answer (response), outline format without the paired Data element: Response format is NOT considered synoptic.
- The data element should be represented in the report as it is listed in the case summary. The response for any data element may be modified from those listed in the case summary, including “Cannot be determined” if appropriate.
- Each diagnostic parameter pair (Data element: Response) is listed on a separate line or in a tabular format to achieve visual separation. The following exceptions are allowed to be listed on one line:
 - Anatomic site or specimen, laterality, and procedure
 - Pathologic Stage Classification (pTNM) elements
 - Negative margins, as long as all negative margins are specifically enumerated where applicable
- The synoptic portion of the report can appear in the diagnosis section of the pathology report, at the end of the report or in a separate section, but all Data element: Responses must be listed together in one location

Organizations and pathologists may choose to list the required elements in any order, use additional methods in order to enhance or achieve visual separation, or add optional items within the synoptic report. The report may have required elements in a summary format elsewhere in the report IN ADDITION TO but not as replacement for the synoptic report ie, all required elements must be in the synoptic portion of the report in the format defined above.

Summary of Changes

v 4.2.0.0

- General Reformatting
- Reformatted Tumor Extent
- Revised Margins Section
- Revise Lymph Nodes Section
- Added Distant Metastasis Section
- Removed pTX and pNX Staging Classification

Reporting Template

Protocol Posting Date: June 2021

Select a single response unless otherwise indicated.

CASE SUMMARY: (AMPULLA OF VATER)

Standard(s): AJCC-UICC 8

SPECIMEN

Procedure

- Ampullectomy
 Pancreaticoduodenectomy (Whipple resection)
 Other (specify): _____
 Not specified

TUMOR

Tumor Site (Note A)

- Intra-ampullary: _____
 Arising from intra-ampullary papillary-tubular neoplasm (IAPN)
 Ampullary ductal (pancreaticobiliary-type)
 Peri-ampullary / ampullary duodenal (arising from duodenal surface of the papilla):

 Intra-ampullary and peri-ampullary (mixed type): _____
 Other (specify): _____
 Cannot be determined: _____
 Not specified

Histologic Type (Note B)

Adenocarcinomas

- Adenocarcinoma, pancreaticobiliary type
 Adenocarcinoma, intestinal type
 Tubular adenocarcinoma with mixed features

Non-tubular patterns

- Mucinous adenocarcinoma
 Signet-ring cell carcinoma (poorly cohesive cell carcinoma)
 Medullary carcinoma
 Invasive papillary adenocarcinoma
 Adenosquamous carcinoma
 Large cell neuroendocrine carcinoma
 Small cell neuroendocrine carcinoma
 Undifferentiated carcinoma
 Mixed neuroendocrine-non-neuroendocrine tumor (mixed adenoneuroendocrine carcinoma)
 Other histologic type not listed (specify): _____
 Carcinoma, not otherwise specified

+Histologic Type Comment: _____

Histologic Grade (Note C)

- G1, well differentiated

- G2, moderately differentiated
- G3, poorly differentiated
- Other (specify): _____
- GX, cannot be assessed: _____
- Not applicable

Tumor Size (Note D)

- Greatest dimension in Centimeters (cm): _____ cm
- +Additional Dimension in Centimeters (cm): _____ x _____ cm**
- Cannot be determined (explain): _____

Tumor Extent (select all that apply)

- Carcinoma in situ / high-grade dysplasia
- Limited to ampulla of Vater or sphincter of Oddi
- Invades beyond sphincter of Oddi (perisphincteric invasion)
- Invades into duodenal submucosa
- Invades into muscularis propria of duodenum
- Directly invades pancreas (up to 0.5 cm)
- Extends more than 0.5 cm into pancreas
- Extends into peripancreatic soft tissues
- Extends into periduodenal tissue
- Extends into duodenal serosa
- Invades other adjacent organ(s) or structure(s) other than pancreas
 - Stomach
 - Gallbladder
 - Omentum
 - Celiac axis
 - Superior mesenteric artery
 - Common hepatic artery
 - Other (specify): _____
- Cannot be determined: _____
- No evidence of primary tumor

Lymphovascular Invasion (Note D)

- Not identified
- Present
- Cannot be determined: _____

+Perineural Invasion (Note D)

- Not identified
- Present
- Cannot be determined: _____

+Tumor Comment: _____

MARGINS (Note E)

Margin Status for Invasive Carcinoma

- All margins negative for invasive carcinoma
- +Closest Margin(s) to Invasive Carcinoma (select all that apply)**

- Deep (radial): _____
- Duodenal mucosal: _____
- Pancreatic duct: _____
- Bile duct: _____
- Pancreatic neck / parenchymal: _____
- Uncinate (retroperitoneal / superior mesenteric artery): _____
- Proximal (gastric or duodenal): _____
- Distal (duodenal or jejunal): _____
- Other (specify): _____
- Cannot be determined: _____

+Distance from Invasive Carcinoma to Closest Margin

Specify in Centimeters (cm)

- Exact distance in cm: _____ cm
- Greater than 1 cm

Specify in Millimeters (mm)

- Exact distance in mm: _____ mm
- Greater than 10 mm

Other

- Other (specify): _____
- Cannot be determined: _____
- Not applicable

Invasive carcinoma present at margin

Margin(s) Involved by Invasive Carcinoma (select all that apply)

- Deep (radial): _____
- Duodenal mucosal: _____
- Pancreatic duct: _____
- Bile duct: _____
- Pancreatic neck / parenchymal: _____
- Uncinate (retroperitoneal / superior mesenteric artery): _____
- Proximal (gastric or duodenal): _____
- Distal (duodenal or jejunal): _____
- Other (specify): _____
- Cannot be determined (explain): _____
- Other (specify): _____
- Cannot be determined (explain): _____
- Not applicable

Margin Status for Dysplasia and Intraepithelial Neoplasia (select all that apply)

- All margins negative for dysplasia and intraepithelial neoplasia
- Pancreatic high-grade intraepithelial neoplasia present at pancreatic neck / parenchymal margin: _____
- High-grade intraepithelial neoplasia present at bile duct margin: _____
- High-grade dysplasia present at margin

Margin(s) Involved by High-Grade Dysplasia (select all that apply)

- Proximal (gastric or duodenal): _____
- Distal (duodenal or jejunal): _____
- Other (specify): _____
- Cannot be determined (explain): _____
- Other (specify): _____
- Cannot be determined (explain): _____
- Not applicable

+Margin Comment: _____

REGIONAL LYMPH NODES

Regional Lymph Node Status

- ___ Not applicable (no regional lymph nodes submitted or found)
- ___ Regional lymph nodes present
 - ___ All regional lymph nodes negative for tumor
 - ___ Tumor present in regional lymph node(s)

Number of Lymph Nodes with Tumor

- ___ Exact number (specify): _____
- ___ At least (specify): _____
- ___ Other (specify): _____
- ___ Cannot be determined (explain): _____
- ___ Other (specify): _____
- ___ Cannot be determined (explain): _____

Number of Lymph Nodes Examined

- ___ Exact number: _____
- ___ At least (specify): _____
- ___ Other (specify): _____
- ___ Cannot be determined (explain): _____

+Regional Lymph Node Comment: _____

DISTANT METASTASIS

Distant Site(s) Involved, if applicable (select all that apply)

- ___ Not applicable
- ___ Non-regional lymph node(s): _____
- ___ Liver: _____
- ___ Other (specify): _____
- ___ Cannot be determined: _____

PATHOLOGIC STAGE CLASSIFICATION (pTNM, AJCC 8th Edition) (Note F)

Reporting of pT, pN, and (when applicable) pM categories is based on information available to the pathologist at the time the report is issued. As per the AJCC (Chapter 1, 8th Ed.) it is the managing physician's responsibility to establish the final pathologic stage based upon all pertinent information, including but potentially not limited to this pathology report.

TNM Descriptors (select all that apply)

- ___ Not applicable
- ___ m (multiple primary tumors)
- ___ r (recurrent)
- ___ y (post-treatment)

pT Category

- ___ pT not assigned (cannot be determined based on available pathological information)
- ___ pT0: No evidence of primary tumor
- ___ pTis: Carcinoma *in situ*

pT1: Tumor limited to ampulla of Vater or sphincter of Oddi or tumor invades beyond the sphincter of Oddi (perisphincteric invasion) and / or into the duodenal submucosa

- pT1a: Tumor limited to ampulla of Vater or sphincter of Oddi
- pT1b: Tumor invades beyond the sphincter of Oddi (perisphincteric invasion) and / or into the duodenal submucosa
- pT1 (subcategory cannot be determined)
- pT2: Tumor invades into the muscularis propria of the duodenum
- pT3: Tumor directly invades the pancreas (up to 0.5 cm) or tumor extends more than 0.5 cm into the pancreas, or extends into peripancreatic or periduodenal tissue or duodenal serosa without involvement of the celiac axis or superior mesenteric artery*
- pT3a: Tumor directly invades pancreas (up to 0.5 cm)
- pT3b: Tumor extends more than 0.5 cm into the pancreas, or extends into peripancreatic tissue or periduodenal tissue or duodenal serosa without involvement of the celiac axis or superior mesenteric artery
- pT3 (subcategory cannot be determined)
- pT4: Tumor involves the celiac axis, superior mesenteric artery, and / or common hepatic artery, irrespective of size

pN Category

- pN not assigned (no nodes submitted or found)
- pN not assigned (cannot be determined based on available pathological information)
- pN0: No regional lymph node metastasis
- pN1: Metastasis to one to three regional lymph nodes
- pN2: Metastasis to four or more regional lymph nodes

pM Category (required only if confirmed pathologically)

- Not applicable - pM cannot be determined from the submitted specimen(s)
- pM1: Distant metastasis

ADDITIONAL FINDINGS (Note [G](#))

+Additional Findings (select all that apply)

- None identified
- Dysplasia / adenoma
- Other (specify): _____

SPECIAL STUDIES

+Ancillary Studies (Note [G](#))

- Specify: _____
- Not performed

COMMENTS

Comment(s): _____

Explanatory Notes

A. Anatomical Considerations

The ampulla of Vater is a complex structure that usually represents the confluence of the distal common bile duct and main pancreatic duct (Figure 1). In some individuals the ampulla includes only the distal common bile duct, with the pancreatic duct entering the duodenum elsewhere. The ampulla traverses the duodenal wall and opens into the duodenal lumen through a small mucosal elevation, the duodenal papilla (papilla of Vater) (Figure 1). The ampulla is lined by pancreaticobiliary type ductal epithelium, whereas the duodenal papilla is covered by small intestinal epithelium. The sphincter of Oddi is part of the ampulla and consists of smooth muscle fibers that surround the distal end of the merged ducts.

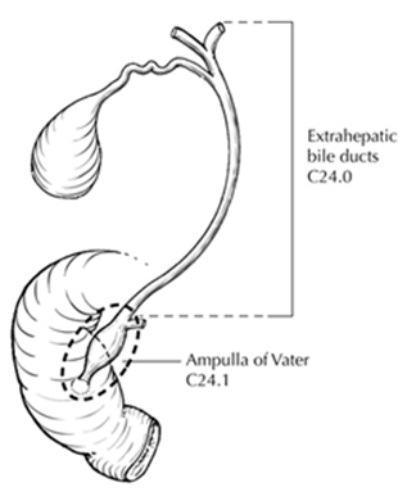


Figure 1. Anatomy of the ampulla of Vater. From Greene et al.¹ Used with permission of the American Joint Committee on Cancer (AJCC), Chicago, Illinois. The original source for this material is the *AJCC Cancer Staging Atlas* (2006) published by Springer Science and Business Media LLC, www.springerlink.com.

Tumors of the ampulla of Vater may arise in the ampulla (intra-ampullary type) or on the duodenal surface of the papilla (peri-ampullary type),² or may involve both the intra-ampullary and peri-ampullary regions (mixed type). Thus, ampullary tumors may show biliary and/or intestinal features. The origin of the tumor may be difficult, and occasionally impossible, to determine; the differential diagnosis includes carcinoma of the distal common bile duct, main pancreatic duct, and duodenum. Tumors may be exophytic or ulcerated.

References

1. Greene FL, Compton, CC, Fritz AG, et al, eds. *AJCC Cancer Staging Atlas*. New York, NY: Springer; 2006.
2. Amin MB, Edge SB, Greene FL, et al, eds. *AJCC Cancer Staging Manual*. 8th ed. New York, NY: Springer; 2017.

B. Histologic Type

This protocol uses modified classification of carcinomas of the gallbladder and extrahepatic bile ducts published by the World Health Organization (WHO) that is applicable to the ampulla of Vater.¹

The pancreaticobiliary-type adenocarcinomas are more aggressive compared to the intestinal type.² Since morphologic distinction can be challenging, immunohistochemistry has been advocated to make this distinction as the histologic subtype (intestinal vs pancreaticobiliary) can help in the choice of

adjuvant therapy.^{3,4,5} Intestinal-type tumors are typically positive for CK20 or CDX2 or MUC2 with negative MUC1, or are positive for CK20, CDX2, and MUC2, irrespective of the MUC1 staining. Pancreatobiliary-type tumors are positive for MUC1 and negative for CDX2 and MUC2, irrespective of CK20 staining. This panel was able to classify 92% of cases in 1 study.⁴ A two-tiered approach has also been advocated based on which all tumors with pancreaticobiliary histology, MUC1 positivity and CDX2 negativity are classified as pancreaticobiliary, while the rest are considered as intestinal-type.^{5,6} Most mucinous adenocarcinomas exhibit intestinal subtype.

Pre-invasive mass forming ampullary neoplasms are similar to their pancreatic and bile duct counterparts and the term “intra-ampullary papillary-tubular neoplasm” (IAPN) has been proposed for these tumors.⁷ These can be associated with an invasive component (invasive papillary adenocarcinoma by WHO terminology). IAPN with invasive component have a favorable outcome compared to other invasive ampullary carcinomas.⁷

References

1. WHO Classification of Tumours Editorial Board. *Digestive system tumours*. Lyon (France): International Agency for Research on Cancer; 2019. (WHO classification of tumours series, 5th ed.; vol. 1).
2. Westgaard A, Tafford S, Farstad IN, et al. Pancreatobiliary versus intestinal histologic type of differentiation is an independent prognostic factor in resected periampullary adenocarcinoma. *BMC Cancer*. 2008;8:170.
3. Kumari N, Prabha K, Singh RK, Baitha DK, Krishnani N. Intestinal and pancreaticobiliary differentiation in periampullary carcinoma: the role of immunohistochemistry. *Hum Pathol*. 2013;44(10):2213-9.
4. Ang DC, Shia J, Tang LH, Katabi N, Klimstra DS. The utility of immunohistochemistry in subtyping adenocarcinoma of the ampulla of vater. *Am J Surg Pathol*. 2014;38(10):1371-1379.
5. Chang DK, Jamieson NB, Johns AL. Histomolecular phenotypes and outcome in adenocarcinoma of the ampulla of vater. *J Clin Oncol*. 2013;31:1348–1356.
6. Schueneman A, Goggins M, Ensor J, et al. Validation of histomolecular classification utilizing histological subtype, MUC1, and CDX2 for prognostication of resected ampullary adenocarcinoma. *Br J Cancer*. 2015;113(1):64-8.
7. Ohike N, Kim GE, Tajiri T, et al. Intra-ampullary papillary-tubular neoplasm (IAPN): characterization of tumoral intraepithelial neoplasia occurring within the ampulla: a clinicopathologic analysis of 82 cases. *Am J Surg Pathol*. 2010;34(12):1731-48.

C. Histologic Grade

For nonpapillary adenocarcinomas, the following grading system is suggested:

| | |
|----|--|
| GX | Grade cannot be assessed |
| G1 | Well differentiated (greater than 95% of tumor composed of glands) |
| G2 | Moderately differentiated (50% to 95% of tumor composed of glands) |
| G3 | Poorly differentiated# (49% or less of tumor composed of glands) |

Poor differentiation has been shown to be an adverse prognostic factor on univariate analysis in some, but not all, series.^{1,2}

Signet-ring cell carcinomas are assigned grade 3 by convention. Undifferentiated carcinomas lack morphologic and immunohistochemical evidence of glandular, squamous, or neuroendocrine differentiation. This grading scheme is not applicable to poorly differentiated neuroendocrine carcinomas.

References

1. Hsu HP, Yang TM, Hsieh YH, Shan YS, Lin PW. Predictors for patterns of failure after pancreaticoduodenectomy in ampullary cancer. *Ann Surg Oncol.* 2007;14(1):50-60.
2. Kim RD, Kundhal PS, McGilvray ID, et al. Predictors of failure after pancreaticoduodenectomy for ampullary carcinoma. *J Am Coll Surg.* Jan 2006;202(1):112-119.

D. Non-TNM Prognostic Factors

Although not included in the TNM staging system for tumors of the ampulla of Vater, tumor size has been shown to have independent prognostic significance for local recurrence.¹ In some series, pancreatic invasion, not tumor size, appears to be the more important prognostic factor.²

Lymphovascular invasion³ and perineural invasion⁴ have also been shown to be adverse prognostic factors.

References

1. Hsu HP, Yang TM, Hsieh YH, Shan YS, Lin PW. Predictors for patterns of failure after pancreaticoduodenectomy in ampullary cancer. *Ann Surg Oncol.* 2007;14(1):50-60.
2. Beger HG, Treitschke F, Gansuage F, Harada N, Hiki N, Mattfeldt T. Tumor of the ampulla of Vater: experience with local or radical resection in 171 consecutively treated patients. *Arch Surg.* 1999;134:526-532.
3. Bouvet M, Gamagami RA, Gilpin EA, et al. Factors influencing survival after resection for periampullary neoplasms. *Am J Surg.* 2000;180(1):13-17.
4. Bettschart V, Rahman MQ, Engelken FJ, Madhavan KK, Parks RW, Garden OJ. Presentation, treatment and outcome in patients with ampullary tumours. *Br J Surg.* 2004;91(12):1600-1607.

E. Margins

Local recurrence from invasive carcinoma in the region of the pancreatic head, including ampullary cancers invading the pancreas, most often occurs at the uncinate margin (retroperitoneal or superior mesenteric artery margin) of the pancreatic head. Because this is a critical margin, inking the uncinated margin and submitting sections through the tumor at its closest approach to this margin is recommended. Complete en face sections of the pancreatic neck/parenchymal resection margin and the resection margin of the common bile duct should also be taken. Microscopically positive margins of resection (R1) have been shown to have an adverse impact on prognosis in ampullary carcinoma.¹

References

1. Todoroki T, Koike N, Morishita Y, et al. Patterns and predictors of failure after curative resections of carcinoma of the ampulla of Vater. *Ann Surg Oncol.* 2003;10(10):1176-1183.

F. Pathologic Stage Classification

The TNM staging system for tumors of the ampulla of Vater of the American Joint Committee on Cancer (AJCC) and the International Union Against Cancer (UICC) is recommended and shown below.¹ The postresection prognosis of a patient with ampullary carcinoma is primarily determined by the anatomic extent of disease as defined by the TNM classification and stage groupings.

By AJCC/UICC convention, the designation “T” refers to a primary tumor that has not been previously treated. The symbol “p” refers to the pathologic classification of the TNM, as opposed to the clinical classification, and is based on gross and microscopic examination. pT entails a resection of the primary tumor or biopsy adequate to evaluate the highest pT category, pN entails removal of nodes adequate to validate lymph node metastasis, and pM implies microscopic examination of distant lesions. Clinical classification (cTNM) is usually carried out by the referring physician before treatment during initial evaluation of the patient or when pathologic classification is not possible.

Pathologic staging is usually performed after surgical resection of the primary tumor. Pathologic staging depends on pathologic documentation of the anatomic extent of disease, whether or not the primary tumor has been completely removed. If a biopsied tumor is not resected for any reason (eg, when technically infeasible) and if the highest T and N categories or the M1 category of the tumor can be confirmed microscopically, the criteria for pathologic classification and staging have been satisfied without total removal of the primary cancer.

TNM Descriptors

For identification of special cases of TNM or pTNM classifications, the “m” suffix and “y” and “r” prefixes are used. Although they do not affect the stage grouping, they indicate cases needing separate analysis.

The “m” suffix indicates the presence of multiple primary tumors in a single site and is recorded in parentheses: pT(m)NM.

The “y” prefix indicates those cases in which classification is performed during or after initial multimodality therapy (ie, neoadjuvant chemotherapy, radiation therapy, or both chemotherapy and radiation therapy). The cTNM or pTNM category is identified by a “y” prefix. The ycTNM or ypTNM categorizes the extent of tumor actually present at the time of that examination. The “y” categorization is not an estimate of tumor before multimodality therapy (ie, before initiation of neoadjuvant therapy).

The “r” prefix indicates a recurrent tumor when staged after a documented disease-free interval and is identified by the “r” prefix: rTNM.

T Category Considerations

For ampullary carcinomas, carcinoma in situ (pTis) as a staging term includes cancer cells confined within the glandular basement membrane (high-grade dysplasia). The term carcinoma in situ is not widely applied to glandular neoplastic lesions in the gastrointestinal tract but is retained for tumor registry reporting purposes as specified by law in many states. Noninvasive ampullary carcinomas with a papillary growth pattern (intra-ampullary papillary-tubular neoplasms) are classified as pTis. The revised T categories in the AJCC 8th edition address the discrepancies in the previous definitions and correlate better with outcome.^{2,3}

T categories are illustrated in Figures 2-5.

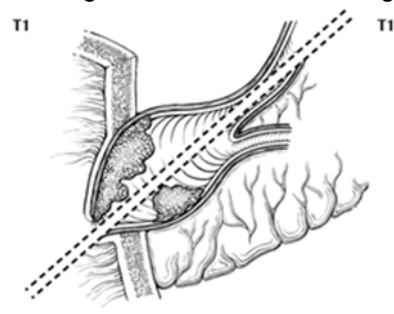


Figure 2. T1a tumors are limited to the ampulla of Vater (below the dotted line) or sphincter of Oddi (above the dotted line). From Greene et al.⁴ Used with permission of the American Joint Committee on Cancer (AJCC), Chicago, Illinois. The original source for this material is the *AJCC Cancer Staging Atlas* (2006) published by Springer Science and Business Media LLC, www.springerlink.com.

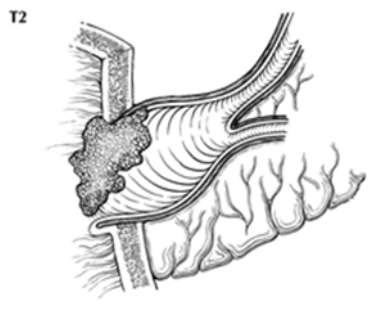


Figure 3. T1b tumors invade beyond the sphincter of Oddi or into duodenal submucosa. From Greene et al.⁴ Used with permission of the American Joint Committee on Cancer (AJCC), Chicago, Illinois. The original source for this material is the *AJCC Cancer Staging Atlas* (2006) published by Springer Science and Business Media LLC, www.springerlink.com.

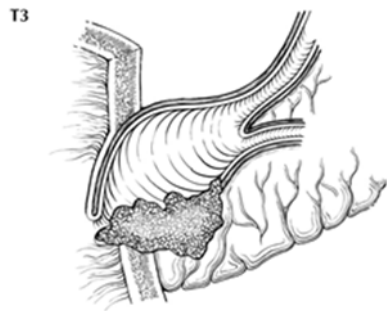


Figure 4. T3a tumors directly invade pancreas up to 0.5 cm. From Greene et al.⁴ Used with permission of the American Joint Committee on Cancer (AJCC), Chicago, Illinois. The original source for this material is the *AJCC Cancer Staging Atlas* (2006) published by Springer Science and Business Media LLC, www.springerlink.com.

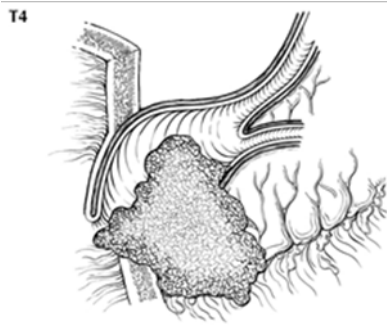


Figure 5. T3b tumors extend more than 0.5 cm into pancreas, peripancreatic fat (shown) or duodenal serosa From Greene et al.⁴ Used with permission of the American Joint Committee on Cancer (AJCC), Chicago, Illinois. The original source for this material is the *AJCC Cancer Staging Atlas* (2006) published by Springer Science and Business Media LLC, www.springerlink.com.

N Category Considerations

Regional lymph node metastases have been shown to have independent significance as an adverse prognostic factor in multiple series.^{5,6,7} Evaluation of a minimum of 12 lymph nodes in Whipple resections is recommended for optimal staging.^{2,8,9}

The regional nodes (Figure 6) include peripancreatic lymph nodes as well as lymph nodes along hepatic artery and portal vein.

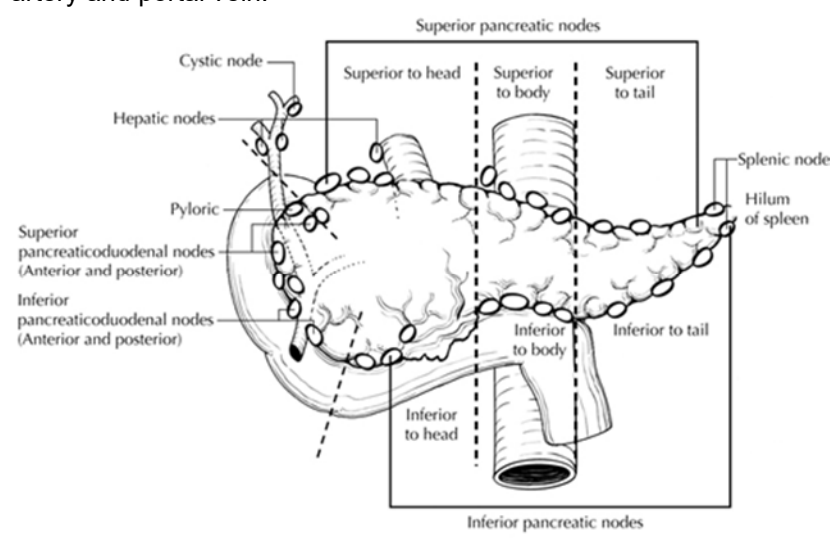


Figure 6. Regional lymph nodes of the ampulla of Vater. From Greene et al.⁴ Used with permission of the American Joint Committee on Cancer (AJCC), Chicago, Illinois. The original source for this material is the *AJCC Cancer Staging Atlas* (2006) published by Springer Science and Business Media LLC, www.springerlink.com.

Tumor involvement of other nodal groups is considered distant metastasis. Anatomic division of regional lymph nodes is not necessary, but separately submitted lymph nodes should be reported as submitted.¹

Routine assessment of regional lymph nodes is limited to conventional pathologic techniques (gross assessment and histologic examination), and data are currently insufficient to recommend special measures to detect micrometastasis or isolated tumor cells. Thus, neither multiple levels of paraffin blocks nor the use of special/ancillary techniques such as immunohistochemistry are recommended for routine examination of regional lymph nodes.

Vessel Invasion

By AJCC convention, vessel invasion (small vessel or venous) does not affect the T category indicating local extent of tumor unless specifically included in the definition of a T category

References

1. Amin MB, Edge SB, Greene FL, et al, eds. *AJCC Cancer Staging Manual*. 8th ed. New York, NY: Springer; 2017.
2. Adsay NV, Bagci P, Tajiri T, et al. Pathologic staging of pancreatic, ampullary, biliary, and gallbladder cancers: pitfalls and practical limitations of the current AJCC/UICC TNM staging system and opportunities for improvement. *Semin Diagn Pathol*. 2012;29(3):127-41.
3. You D, Heo J, Choi S, Choi D, Jang K-T. Pathologic t1 subclassification of ampullary carcinoma with perisphincteric or duodenal submucosal invasion: is it t1b? *Arch Path Lab Med*. 2014;138(8):1072.
4. Greene FL, Compton, CC, Fritz AG, et al, eds. *AJCC Cancer Staging Atlas*. New York, NY: Springer; 2006.
5. Hsu HP, Yang TM, Hsieh YH, Shan YS, Lin PW. Predictors for patterns of failure after pancreaticoduodenectomy in ampullary cancer. *Ann Surg Oncol*. 2007;14(1):50-60.
6. Riall TS, Cameron JL, Lillemoe KD, et al. Resected periampullary adenocarcinoma: 5-year survivors and their 6- to 10-year follow-up. *Surgery*. 2006;140(5):764-772.

7. Sakata J, Shirai Y, Wakai T, et al. Number of positive lymph nodes independently affects long-term survival after resection in patients with ampullary carcinoma. *Eur J Surg Oncol.* 2007;33(3):346-351.
8. Partelli S, Crippa S, Capelli P, et al. Adequacy of lymph node retrieval for ampullary cancer and its association with improved staging and survival. *World J Surg.* 2013;37(6):1397-1404.
9. Balci S, Basturk O, Saka B, et al. Substaging nodal status in ampullary carcinomas has significant prognostic value: proposed revised staging based on an analysis of 313 well-characterized cases. *Ann Surg Oncol.* 2015:1-10.

G. Additional Findings and Ancillary Studies

Ampullary adenomas are common in patients with familial adenomatous polyposis coli, and such patients are at increased risk for ampullary adenocarcinomas. Estimated lifetime incidence is roughly 12% for ampullary carcinoma in this population.¹

Ampullary adenocarcinoma can occur in patients with Lynch syndrome. Absence of DNA mismatch repair (MMR) proteins by immunohistochemistry has been described in 5-10% of ampullary adenocarcinomas.^{2,3,4} These tumors tend to be of the intestinal type. Histologic features associated with microsatellite instability (MSI) such as tumor-infiltrating lymphocytes and mucinous subtype may be present, but the association is not as strong as in colorectal adenocarcinomas.^{2,4} Currently, there are no formal recommendations for MMR or MSI testing in ampullary adenocarcinoma, but this practice has been adopted in some centers.

References

1. Partelli S, Crippa S, Capelli P, et al. Adequacy of lymph node retrieval for ampullary cancer and its association with improved staging and survival. *World J Surg.* 2013;37(6):1397-1404.
2. Sessa F, Furlan D, Zampatti C, et al. Prognostic factors for ampullary adenocarcinomas: tumor stage, tumor histology, tumor location, immunohistochemistry and microsatellite instability. *Virchows Arch.* 2007;451:649-657.
3. Ruemmele P, Dietmaier W, Terracciano L, et al. Histopathologic features and microsatellite instability of cancers of the papilla of Vater and their precursor lesions. *Am J Surg Pathol.* 2009;33:691-704.
4. Agaram NP, Shia J, Tang LH, et al. DNA mismatch repair deficiency in ampullary carcinoma: a morphologic and immunohistochemical study of 54 cases. *Am J Clin Pathol.* 2010;133:772-780.