



## Protocol for the Examination of Resection Specimens From Patients With Primary Tumors of Bone

**Version:** 4.1.1.0

**Protocol Posting Date:** July 2021

**CAP Laboratory Accreditation Program Protocol Required Use Date:** March 2022

The changes included in this current protocol version affect accreditation requirements. The new deadline for implementing this protocol version is reflected in the above accreditation date.

**For accreditation purposes, this protocol should be used for the following procedures and tumor types:**

Procedure	Description
Resection	Includes specimens designated intralesional resection, marginal resection, segmental/wide resection, or radical resection
Tumor Type	Description
Primary malignant bone tumors	Includes chondrogenic tumors, osteogenic tumors, fibrogenic tumors, osteoclastic giant cell rich tumors, notochordal tumors, vascular tumors, myogenic tumors, lipogenic tumors, undifferentiated small round cell sarcomas and other mesenchymal tumors arising in bone.

**This protocol is NOT required for accreditation purposes for the following:**

Procedure
Biopsy (includes core needle biopsy, curettage, or excisional biopsy)
Primary resection specimen with no residual cancer (eg, following neoadjuvant therapy)
Cytologic specimens

**The following tumor types should NOT be reported using this protocol:**

Tumor Type
Plasma cell neoplasms (consider the Plasma Cell Neoplasms protocol)
Lymphoma (consider the Hodgkin or non-Hodgkin Lymphoma protocols)
Pediatric Ewing sarcoma (consider the Ewing Sarcoma protocol)
Soft tissue sarcoma (consider the Soft Tissue protocol)

### Authors

Javier A. Laurini\*

With guidance from the CAP Cancer and CAP Pathology Electronic Reporting Committees.

\* Denotes primary author.

### **Accreditation Requirements**

This protocol can be utilized for a variety of procedures and tumor types for clinical care purposes. For accreditation purposes, only the definitive primary cancer resection specimen is required to have the core and conditional data elements reported in a synoptic format.

- Core data elements are required in reports to adequately describe appropriate malignancies. For accreditation purposes, essential data elements must be reported in all instances, even if the response is “not applicable” or “cannot be determined.”
- Conditional data elements are only required to be reported if applicable as delineated in the protocol. For instance, the total number of lymph nodes examined must be reported, but only if nodes are present in the specimen.
- Optional data elements are identified with “+” and although not required for CAP accreditation purposes, may be considered for reporting as determined by local practice standards.

The use of this protocol is not required for recurrent tumors or for metastatic tumors that are resected at a different time than the primary tumor. Use of this protocol is also not required for pathology reviews performed at a second institution (ie, secondary consultation, second opinion, or review of outside case at second institution).

### **Synoptic Reporting**

All core and conditionally required data elements outlined on the surgical case summary from this cancer protocol must be displayed in synoptic report format. Synoptic format is defined as:

- Data element: followed by its answer (response), outline format without the paired Data element: Response format is NOT considered synoptic.
- The data element should be represented in the report as it is listed in the case summary. The response for any data element may be modified from those listed in the case summary, including “Cannot be determined” if appropriate.
- Each diagnostic parameter pair (Data element: Response) is listed on a separate line or in a tabular format to achieve visual separation. The following exceptions are allowed to be listed on one line:
  - Anatomic site or specimen, laterality, and procedure
  - Pathologic Stage Classification (pTNM) elements
  - Negative margins, as long as all negative margins are specifically enumerated where applicable
- The synoptic portion of the report can appear in the diagnosis section of the pathology report, at the end of the report or in a separate section, but all Data element: Responses must be listed together in one location

Organizations and pathologists may choose to list the required elements in any order, use additional methods in order to enhance or achieve visual separation, or add optional items within the synoptic report. The report may have required elements in a summary format elsewhere in the report IN ADDITION TO but not as replacement for the synoptic report ie, all required elements must be in the synoptic portion of the report in the format defined above.

### **Summary of Changes**

#### **v 4.1.1.0**

- Fixed incorrect staging classification for pT1 under pT Category for Appendicular Skeleton, Trunk, Skull, and Facial Bones
  - Changed “*Tumor greater than or equal...*” to “*Tumor less than or equal...*”
- Fixed incorrect staging classification for pT1a under pT Category for Pelvis
  - Changed to “*Tumor less than or equal to...*”

#### **v 4.1.0.0**

- General Reformatting
- Revised Margins Section
- Revised Lymph Nodes Section
- Added Distant Metastasis Section
- Removed pTX and pNX Staging Classification
- New WHO 5th Edition Histological Updates

## Reporting Template

---

**Protocol Posting Date: July 2021**

**Select a single response unless otherwise indicated.**

**CASE SUMMARY: (BONE: Resection)**

**Standard(s):** AJCC-UICC 8

**CLINICAL (Note [A](#))**

**+Radiographic Findings (Note [B](#))**

Specify: \_\_\_\_\_

Not available

**+Preresection Treatment (select all that apply)**

No known preresection therapy

Chemotherapy performed

Radiation therapy performed

Therapy performed, type not specified

Not specified

**SPECIMEN**

**Procedure (Note [C](#))**

Intralesional resection

Marginal resection

Segmental / wide resection

Radical resection

Other (specify): \_\_\_\_\_

Not specified

**TUMOR**

**Multiple Sites**

Not applicable

Multifocal tumor / discontinuous tumor at primary bone site

Additional primary bone site(s) present

*Please complete a separate checklist for each primary bone site*

**Tumor Site (Note [D](#))**

Appendicular skeleton (specify bone, if known): \_\_\_\_\_

Spine (specify bone, if known): \_\_\_\_\_

Pelvis (specify bone, if known): \_\_\_\_\_

Not specified

**Tumor Size**

Greatest dimension in Centimeters (cm): \_\_\_\_\_ cm

**+Additional Dimension in Centimeters (cm):** \_\_\_\_ x \_\_\_\_ cm

Cannot be determined: \_\_\_\_\_

**Tumor Location and Extent (Note B) (select all that apply)**

- Epiphysis or apophysis
- Metaphysis
- Diaphysis
- Cortex
- Medullary cavity
- Surface
- Involves joint
- Extends into soft tissue
- Cannot be determined: \_\_\_\_\_

**Histologic Type (World Health Organization [WHO] Classification of Malignant Bone Tumors) (Note E)**

- Chondrogenic Tumors
  - Chondrosarcoma
  - Dedifferentiated chondrosarcoma
  - Periosteal chondrosarcoma
  - Clear cell chondrosarcoma
  - Mesenchymal chondrosarcoma
- Osteogenic Tumors
  - Low grade central osteosarcoma
  - Osteosarcoma NOS
  - Conventional osteosarcoma
  - Telangiectatic osteosarcoma
  - Small cell osteosarcoma
  - Parosteal osteosarcoma
  - Periosteal osteosarcoma
  - High grade surface osteosarcoma
  - Secondary osteosarcoma
  - +Precipitating Factor for Secondary Osteosarcoma: \_\_\_\_\_**
- Undifferentiated Small Round Cell Sarcomas
  - Ewing sarcoma
  - Round cell sarcoma with EWSR1-non ETS fusions
  - CIC-rearranged sarcoma
  - Sarcoma with BCOR genetic alterations
- Fibrogenic Tumors - Fibrosarcoma of bone
- Malignancy in giant cell tumor of bone
- Notochordal Tumors
  - Chordoma NOS
  - Chondroid chordoma
  - Poorly differentiated chordoma
  - Dedifferentiated chordoma
- Vascular Tumors
  - Epithelioid hemangioendothelioma
  - Angiosarcoma

- Other Mesenchymal Tumors
  - Leiomyosarcoma of bone
  - Adamantinoma
  - Dedifferentiated adamantinoma
  - Undifferentiated high-grade pleomorphic sarcoma

Cannot be determined: \_\_\_\_\_

Other histologic type not listed (specify): \_\_\_\_\_

**+Histologic Type Comment:** \_\_\_\_\_

**Histologic Grade (Note F)**

- G1, well differentiated, low grade
- G2, moderately differentiated, high grade
- G3, poorly differentiated, high grade
- GX, cannot be assessed: \_\_\_\_\_
- Not applicable

**+Mitotic Rate (Note G)**

- Specify mitotic rate per mm<sup>2</sup>: \_\_\_\_\_ mitoses per mm<sup>2</sup>
- Specify mitotic rate per 10 high-power fields (HPF): \_\_\_\_\_ mitoses per 10 high-power fields (HPF)
- Cannot be determined (explain): \_\_\_\_\_

**Necrosis (macroscopic or microscopic) (Note C)**

- Not identified
- Present

**Extent of Necrosis**

- Specify percentage: \_\_\_\_\_ %
- Cannot be determined (explain): \_\_\_\_\_
- Cannot be determined

**Treatment Effect (Note H)**

- No known presurgical therapy
- Not identified
- Present

**Extent of Treatment Effect (compared with pretreatment biopsy, if available)**

- Specify percentage of non-viable tumor: \_\_\_\_\_ %
- Cannot be determined (explain): \_\_\_\_\_

Cannot be determined

**+Lymphovascular Invasion (Note I)**

- Not identified
- Present
- Cannot be determined: \_\_\_\_\_

**+Tumor Comment:** \_\_\_\_\_

**MARGINS (Note J)**

**Margin Status**

All margins negative for tumor

**Closest Margin(s) to Tumor**

Specify closest margin(s): \_\_\_\_\_

Cannot be determined (explain): \_\_\_\_\_

**Distance from Tumor to Closest Margin**

*Specify in Centimeters (cm)*

Exact distance: \_\_\_\_\_ cm

Greater than: \_\_\_\_\_ cm

At least: \_\_\_\_\_ cm

Less than: \_\_\_\_\_ cm

Less than 2 cm

Other (specify): \_\_\_\_\_

Cannot be determined: \_\_\_\_\_

**Other Close Margin(s) to Tumor (less than 2 cm)**

Specify other close margin(s): \_\_\_\_\_

Cannot be determined (explain): \_\_\_\_\_

Not applicable

Tumor present at margin

**Margin(s) Involved by Tumor**

Specify involved margin(s): \_\_\_\_\_

Cannot be determined: \_\_\_\_\_

Other (specify): \_\_\_\_\_

Cannot be determined (explain): \_\_\_\_\_

Not applicable

**+Margin Comment:** \_\_\_\_\_

**REGIONAL LYMPH NODES (Note K)**

**Regional Lymph Node Status**

Not applicable (no regional lymph nodes submitted or found)

Regional lymph nodes present

All regional lymph nodes negative for tumor

Tumor present in regional lymph node(s)

**Number of Lymph Nodes with Tumor**

Exact number (specify): \_\_\_\_\_

At least (specify): \_\_\_\_\_

Other (specify): \_\_\_\_\_

Cannot be determined (explain): \_\_\_\_\_

Other (specify): \_\_\_\_\_

Cannot be determined (explain): \_\_\_\_\_

**Number of Lymph Nodes Examined**

- Exact number (specify): \_\_\_\_\_
- At least (specify): \_\_\_\_\_
- Other (specify): \_\_\_\_\_
- Cannot be determined (explain): \_\_\_\_\_

**+Regional Lymph Node Comment:** \_\_\_\_\_

**DISTANT METASTASIS**

**Distant Site(s) Involved, if applicable (select all that apply)**

- Not applicable
- Lung: \_\_\_\_\_
- Bone: \_\_\_\_\_
- Other (specify): \_\_\_\_\_
- Cannot be determined: \_\_\_\_\_

**PATHOLOGIC STAGE CLASSIFICATION (pTNM, AJCC 8th Edition) (Note [L](#))**

*Reporting of pT, pN, and (when applicable) pM categories is based on information available to the pathologist at the time the report is issued. As per the AJCC (Chapter 1, 8th Ed.) it is the managing physician's responsibility to establish the final pathologic stage based upon all pertinent information, including but potentially not limited to this pathology report.*

**TNM Descriptors (select all that apply)**

- Not applicable
- m (multiple)
- r (recurrent)
- y (post-treatment)

**pT Category**

Appendicular Skeleton, Trunk, Skull, and Facial Bones

**pT Category**

- pT not assigned (cannot be determined based on available pathological information)
- pT0: No evidence of primary tumor
- pT1: Tumor less than or equal to 8 cm in greatest dimension
- pT2: Tumor greater than 8 cm in greatest dimension
- pT3: Discontinuous tumors in the primary bone site

Spine

**pT Category**

- pT not assigned (cannot be determined based on available pathological information)
- pT0: No evidence of primary tumor
- pT1: Tumor confined to one vertebral segment or two adjacent vertebral segments
- pT2: Tumor confined to three adjacent vertebral segments
- pT3: Tumor confined to four or more adjacent vertebral segments, or any nonadjacent vertebral segments

*pT4: Extension into the spinal canal or great vessels*

- pT4a: Extension into the spinal canal
- pT4b: Evidence of gross vascular invasion or tumor thrombus in the great vessels
- pT4 (subcategory cannot be determined)



\_\_\_ Pelvis

**pT Category**

\_\_\_ pT not assigned (cannot be determined based on available pathological information)

\_\_\_ pT0: No evidence of primary tumor

*pT1: Tumor confined to one pelvic segment with no extraosseous extension*

\_\_\_ pT1a: Tumor less than or equal 8 cm in greatest dimension

\_\_\_ pT1b: Tumor greater than 8 cm in greatest dimension

\_\_\_ pT1 (subcategory cannot be determined)

*pT2: Tumor confined to one pelvic segment with extraosseous extension or two segments without extraosseous extension*

\_\_\_ pT2a: Tumor less than or equal to 8 cm in greatest dimension

\_\_\_ pT2b: Tumor greater than 8 cm in greatest dimension

\_\_\_ pT2 (subcategory cannot be determined)

*pT3: Tumor spanning two pelvic segments with extraosseous extension*

\_\_\_ pT3a: Tumor less than or equal to 8 cm in greatest dimension

\_\_\_ pT3b: Tumor greater than 8 cm in greatest dimension

\_\_\_ pT3 (subcategory cannot be determined)

*pT4: Tumor spanning three pelvic segments or crossing the sacroiliac joint*

\_\_\_ pT4a: Tumor involves sacroiliac joint and extends medial to the sacral neuroforamen

\_\_\_ pT4b: Tumor encasement of external iliac vessels or presence of gross tumor thrombus in major pelvic vessels

\_\_\_ pT4 (subcategory cannot be determined)

**pN Category (Note [K](#))**

\_\_\_ pN not assigned (no nodes submitted or found)

\_\_\_ pN not assigned (cannot be determined based on available pathological information)

\_\_\_ pN0: No regional lymph node metastasis

\_\_\_ pN1: Regional lymph node metastasis

**pM Category (required only if confirmed pathologically)**

\_\_\_ Not applicable - pM cannot be determined from the submitted specimen(s)

*pM1: Distant metastasis*

\_\_\_ pM1a: Lung

\_\_\_ pM1b: Bone or other distant sites

\_\_\_ pM1 (subcategory cannot be determined)

**ADDITIONAL FINDINGS**

**+Additional Findings (specify):** \_\_\_\_\_

**SPECIAL STUDIES**

**Immunohistochemistry**

\_\_\_ Specify: \_\_\_\_\_

\_\_\_ Not performed: \_\_\_\_\_

\_\_\_ Not applicable

**Cytogenetics**

\_\_\_ Specify: \_\_\_\_\_

\_\_\_ Not performed: \_\_\_\_\_

\_\_\_ Not applicable

CAP  
Approved

Bone\_4.1.1.0.REL\_CAPCP

**Molecular Pathology**

Specify: \_\_\_\_\_  
 Not performed: \_\_\_\_\_  
 Not applicable

**COMMENTS**

Comment(s): \_\_\_\_\_

## Explanatory Notes

---

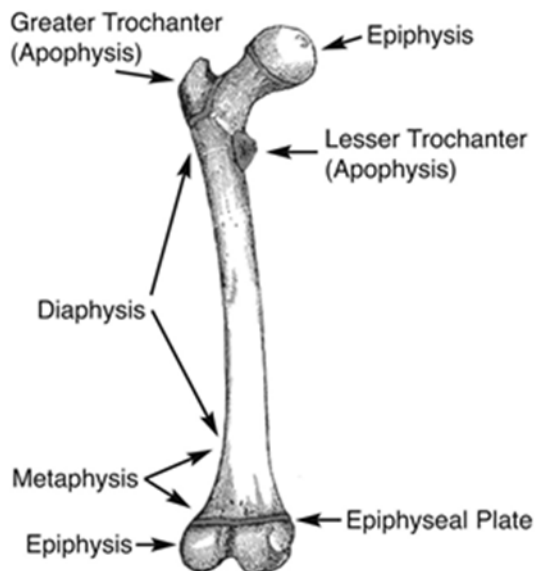
### A. Scope of Guidelines

These recommendations are used for all primary malignant tumors of bone except hematopoietic neoplasms, ie, lymphoma and plasma cell neoplasms.

### B. Tumor Location and Extent

Radiographic imaging plays an especially critical role in the diagnosis of bone tumors. Close collaboration with an experienced musculoskeletal radiologist and orthopedic surgeon is recommended.

Figure 1 is a diagrammatic representation of the “anatomic” regions of a long bone. These locations are very important in classifying bone tumors. For instance, chondroblastomas almost always arise in the epiphysis. Epiphyses and apophyses are secondary ossification centers and therefore are embryonic equivalents. The greater and lesser trochanters are apophyses, while the epiphyses are at the ends of long bones.



**Figure 1.** Important anatomic landmarks for tumor diagnosis in long bones. Adapted from *Gray's Anatomy*.<sup>1</sup>

#### References

1. Gray H, Lewis WH. *Gray's Anatomy of the Human Body*. 20th ed. Philadelphia, PA: Lea & Febiger; 1918.

### C. Procedure / Tissue Processing

The following is a list of guidelines to be used in defining what type of procedure has been performed. This is based on the surgeon's intent and not based on the pathologic assessment of the margins.

**Intralesional Resection:** Leaving gross tumor behind. Partial debulking or curettage are examples.

**Marginal Resection:** Removing the tumor and its pseudocapsule with a relatively small amount of adjacent tissue. There is no gross tumor at the margin; however, microscopic tumor may be present. Note that

occasionally, a surgeon will perform an “excisional” biopsy, which effectively accomplishes the same thing as a marginal resection.

**Segmental/Wide Resection:** An intracompartmental resection. A single piece of bone is resected, including the lesion and a cuff of normal bone.

**Radical Resection:** The removal of an entire bone, or the excision of the adjacent muscle groups if the tumor is extracompartmental

#### Fixation

Tissue specimens from bone tumors optimally are received fresh/unfixed in case fresh tissue for ancillary studies, such as cytogenetics or molecular studies, needs to be collected. All tissue should be processed in a manner that would allow molecular studies to be undertaken successfully.<sup>1,2,3</sup> Decalcification using harsh acid reagents may be detrimental for nucleic acid-based molecular studies and therefore utilization of EDTA as decalcifying agent has been recommended. Freezing a portion of the sample and/or fixing soft portions of the lesion in buffered formalin is encouraged.

#### Tissue Submission for Histologic Evaluation

One section per centimeter of maximum dimension is usually recommended, although fewer sections are needed for very large tumors, especially if they are homogeneous. Tumors known to be high grade from a previous biopsy do not require as many sections as those that were previously diagnosed as low grade, as documentation of a high-grade component will change stage and prognosis in the latter case. Sections should be taken of grossly heterogeneous areas, and there is no need to submit more than 1 section of necrotic tumor (always with a transition to viable tumor), with the exception of specimens obtained to assess chemotherapy effect on osteosarcomas and Ewing sarcoma.<sup>4,5</sup> Occasionally, gross pathology can be misleading, and areas that appear to be grossly necrotic may actually be myxoid or edematous. When this happens, additional sections of these areas should be submitted for histologic examination. When estimates of gross necrosis exceed those of histologic necrosis, the greater percentage of necrosis should be recorded on the surgical pathology report. In general, most tumors require 12 sections or fewer, excluding margins. Tumors with greater areas of heterogeneity may need to be sampled more thoroughly.

#### Molecular Studies

Additionally, it may be important to snap freeze a small portion of tissue as availability of frozen tissue may be a requirement for patient enrollment in clinical trials. Approximately 1 cm<sup>3</sup> of fresh tissue (less is acceptable for small specimens, including core biopsies) should be cut into small, 0.2-cm fragments, reserving sufficient tissue for histologic examination. This frozen tissue should ideally be stored at minus (-)70°C and can be shipped on dry ice to facilities that perform molecular analysis. Discretion should be used in triaging tissue from bone sarcomas. Adequate tissue should be submitted for conventional light microscopy before tissue has been taken for cytogenetics, electron microscopy, or molecular analysis.

#### References

1. Taylor BS, Barretina J, Maki RG, Antonescu CR, Singer S, Ladanyi M. Advances in sarcoma genomics and new therapeutic targets. *Nat Rev Cancer*. 2011;11(8):541-547.
2. Rubin BP, Lazar JF, Oliveira AM. Molecular pathology of bone and soft tissue tumors. In: Tubbs R, Stoler M. *Cell and Tissue Based Molecular Pathology*. Philadelphia, PA: Churchill Livingstone; 2009.
3. WHO Classification of Tumours Editorial Board. Soft Tissue and Bone Tumors. Lyon (France): International Agency for Research on Cancer; 2020. (WHO classification of tumours series, 5th ed.; vol. 3)

4. Amin MB, Edge SB, Greene FL, et al., eds. *AJCC Cancer Staging Manual*. 8th ed. New York, NY: Springer; 2017.
5. Pawel B, Bahrami A, Hicks MJ, Rudzinski E. Protocol for the Examination of Specimens From Pediatric Patients With Ewing Sarcoma (ES). 2016. Available at [www.cap.org/cancerprotocols](http://www.cap.org/cancerprotocols).

#### **D. Tumor Site**

Given the strong association between the primary anatomic site and outcome, the 8<sup>th</sup> edition of the *AJCC Cancer Staging Manual*<sup>1</sup> uses the following site groups for staging purposes:

- Appendicular skeleton, including trunk, skull, and facial bones
- Pelvis
- Spine

This site grouping is reflected by the provision of separate definitions for the primary tumor (T) for each anatomic site.

#### References

1. Amin MB, Edge SB, Greene FL, et al., eds. *AJCC Cancer Staging Manual*. 8th ed. New York, NY: Springer; 2017.

#### **E. Classification of Bone Tumors**

##### Intraoperative Consultation

Histologic classification of bone tumors is sufficiently complex that, in many cases, it is unreasonable to expect a precise classification of these tumors based on an intraoperative consultation. A complete understanding of the surgeon's treatment algorithm is recommended before rendering a frozen section diagnosis. In the case of primary bone tumors, an intraoperative diagnosis of benign versus malignant will generally guide the immediate decision to curette, excise, or wait for permanent sections, and certain therapeutic options may be lost if the wrong path is pursued. Intraoperative consultation is useful in assessing if "lesional" tissue is present and whether or not this tissue is necrotic, and in constructing a differential diagnosis that can direct the proper triage of tissue for flow cytometry (lymphoma), electron microscopy, and molecular studies/cytogenetics. Tissue triage optimally is performed at the time of frozen section. In many cases, it is important that a portion of tissue be submitted for ancillary studies, even from fine-needle aspiration (FNA) and core needle biopsy specimens, once sufficient tissue has been submitted for histologic evaluation.

##### Histologic Classification of Treated Lesions

Due to extensive treatment effects, such as necrosis, fibrosis, and chemotherapy-induced and radiation-induced pleomorphism, it may not be possible to classify some lesions that were either never biopsied or where the biopsy was insufficient for a precise diagnosis. In problematic cases, the grade of the pretreatment specimen (if available) should take precedence.

##### WHO Classification of Malignant Bone Tumors

Classification of tumors should be made according to the 2020 World Health Organization (WHO) classification of bone tumors.<sup>1</sup> As part of the WHO classification system, soft tissue tumors are divided into 4 categories: benign, intermediate (locally aggressive), intermediate (rarely metastasizing), and malignant. Primary malignant lymphomas and plasma cell neoplasms are not staged using the AJCC system for malignant bone tumors.

## References

1. WHO Classification of Tumours Editorial Board. Soft Tissue and Bone Tumors. Lyon (France): International Agency for Research on Cancer; 2020. (WHO classification of tumours series, 5th ed.; vol. 3)

## F. Grading

The grading of bone tumors is largely driven by the histologic diagnosis, and traditionally grading has been based on the system advocated by Broders, which assesses cellularity and nuclear features/degree of anaplasia.<sup>1</sup> The eighth edition of the *AJCC Cancer Staging Manual* recommends a 2-tiered system (low vs high grade) for recording grading.<sup>2</sup> Histologic grading uses a 3-tiered system: Grade 1 is considered low grade, and Grade 2 and Grade 3 are grouped together as high grade for biological grading. In bone sarcomas, the histologic subtype often determines the clinical behaviour and grade. Therefore, a more pragmatic approach to grading aggressive and malignant primary tumors of bone can be used.<sup>3</sup>

Two bone tumors that are locally aggressive and metastasize infrequently, and thus are usually low grade, are low-grade central osteosarcoma and parosteal osteosarcoma. Periosteal osteosarcoma is generally regarded as a grade 2 osteosarcoma. Primary bone tumors that are generally high grade include malignant giant cell tumor, Ewing sarcoma, angiosarcoma, dedifferentiated chondrosarcoma, conventional osteosarcoma, telangiectatic osteosarcoma, small cell osteosarcoma, secondary osteosarcoma, and high-grade surface osteosarcoma.

Grading of conventional chondrosarcoma is based on cellularity, cytologic atypia, and mitotic figures, following the grading system proposed by Evans et al.<sup>4</sup> Grade 1 (low-grade) chondrosarcoma is hypocellular and similar histologically to enchondroma. Grade 2 (intermediate-grade) chondrosarcoma is more cellular than grade 1 chondrosarcoma; has more cytologic atypia, greater hyperchromasia and nuclear size; or has extensive myxoid stroma. Grade 3 (high-grade) chondrosarcoma is hypercellular, pleomorphic, and contains prominent mitotic activity.

Mesenchymal chondrosarcoma, fibrosarcoma, leiomyosarcoma, liposarcoma, undifferentiated high-grade pleomorphic sarcoma of bone and other “soft tissue-type” sarcomas that rarely occur in bone can be graded according to the French Federation of Cancer Centers Sarcoma Group (FNCLCC) grading system<sup>5</sup> (see College of American Pathologists protocol for soft tissue tumors<sup>6</sup>).

Chordomas are locally aggressive lesions with a propensity for metastasis late in their clinical course and are not graded. Adamantinomas tend to have a low-grade clinical course, but this is variable. Fortunately, they are very rare. According to the 2020 WHO classification of tumors of bone, adamantinomas are not graded.<sup>2,7,3</sup>

### Bone Tumor Grades (Summary)

#### Grade 1 (Low Grade)

Low-grade intramedullary (central) osteosarcoma  
Parosteal osteosarcoma  
Grade I chondrosarcoma  
Clear cell chondrosarcoma

#### Grade 2

Periosteal osteosarcoma  
Grade II chondrosarcoma

Grade 3 (High Grade)

Ewing sarcoma  
Conventional osteosarcoma  
Telangiectactic osteosarcoma  
Mesenchymal chondrosarcoma  
Small cell osteosarcoma  
Secondary osteosarcoma  
High-grade surface osteosarcoma  
Dedifferentiated chondrosarcoma  
Dedifferentiated chordoma  
Malignancy in giant cell tumor  
Grade III chondrosarcoma  
Soft-tissue type sarcomas (eg, leiomyosarcoma)  
Undifferentiated high-grade pleomorphic sarcoma

TNM Grading

The 8<sup>th</sup> edition of the American Joint Committee on Cancer (AJCC) and International Union Against Cancer (UICC) staging system for bone tumors includes a 3-grade system but effectively collapses into high grade and low grade.<sup>2,5</sup> Grading in the TNM grading system is based on differentiation only and does not generally apply to sarcomas.

GX     Grade cannot be assessed  
G1     Well differentiated, low grade  
G2     Moderately differentiated, high grade  
G3     Poorly differentiated, high grade

For purposes of using the AJCC staging system (see note J), 3-grade systems can be converted to a 2-grade (TNM) system as follows: grade 1= low-grade; grade 2 and grade 3 = high-grade.

References

1. Inwards CY, Unni KK. Classification and grading of bone sarcomas. *Hematol Oncol Clin North Am.* 1995;9(3):545-569.
2. Amin MB, Edge SB, Greene FL, et al., eds. *AJCC Cancer Staging Manual.* 8th ed. New York, NY: Springer; 2017.
3. WHO Classification of Tumours Editorial Board. *Soft Tissue and Bone Tumors.* Lyon (France): International Agency for Research on Cancer; 2020. (WHO classification of tumours series, 5th ed.; vol. 3)
4. Evans HL, Ayala AG, Romsdahl MM. Prognostic factors in chondrosarcoma of bone: a clinicopathologic analysis with emphasis on histologic grading. *Cancer.* 1977 Aug;40(2):818-31.
5. Guillou L, Coindre JM, Bonichon F, et al. Comparative study of the National Cancer Institute and French Federation of Cancer Centers Sarcoma Group grading systems in a population of 410 adult patients with soft tissue sarcoma. *J Clin Oncol.* 1997;15(1):350-362.
6. Laurini JA. Protocol for the Examination of Specimens From Patients With Soft Tissue Tumors. 2021. Available at [www.cap.org/cancerprotocols](http://www.cap.org/cancerprotocols).
7. Brierley JD, Gospodarowicz MK, Wittekind C, et al., eds. *TNM Classification of Malignant Tumours.* 8th ed. Oxford, UK: Wiley; 2016.

**G. Mitotic Rate**

Mitotic rate is determined by counting mitotic figures in the most mitotically active area, away from areas of necrosis, in either 10 consecutive high-power fields (HPF) (use the X40 objective) (1 HPF x 400 = 0.1734 mm<sup>2</sup>) or in the appropriate number of HPF to encompass 1 mm<sup>2</sup> based on each individual microscope.

The area of 1 HPF originally used measured 0.1734 mm<sup>2</sup>. However, the area of 1 HPF using most modern microscopes with wider 40x lenses will most likely be higher. Pathologists are encouraged to determine the field area of their 40x lenses and divide 0.1734 by the obtained field area to obtain a conversion factor. The number of mitotic figures in 10 HPF multiplied by the obtained conversion factor and rounded to the nearest whole number should be used for reporting purposes.

An important change in the 5<sup>th</sup> Edition of the WHO Classification of Tumours series<sup>1</sup> is the conversion of mitotic count from the traditional denominator of 10 HPFs to a defined area expressed in mm<sup>2</sup>, as an attempt to standardize the area used for mitotic count. Table 1 shows the approximate number of fields required to encompass 1 mm<sup>2</sup> based on the field diameter and its corresponding area.

**Table 1. Approximate number of fields per 1 mm<sup>2</sup> based on field diameter and its corresponding area**

Field diameter (mm)	Area (mm <sup>2</sup> )	Approximate number of fields per 1 mm <sup>2</sup>
0.40	0.126	8
0.41	0.132	8
0.42	0.138	7
0.43	0.145	7
0.44	0.152	7
0.45	0.159	6
0.46	0.166	6
0.47	0.173	6
0.48	0.181	6
0.49	0.188	5
0.50	0.196	5
0.51	0.204	5
0.52	0.212	5
0.53	0.221	5
0.54	0.229	4
0.55	0.237	4
0.56	0.246	4
0.57	0.255	4
0.58	0.264	4
0.59	0.273	4
0.60	0.283	4
0.61	0.292	3
0.62	0.302	3
0.63	0.312	3
0.64	0.322	3
0.65	0.332	3
0.66	0.342	3
0.67	0.352	3
0.68	0.363	3
0.69	0.374	3



#### References

1. WHO Classification of Tumours Editorial Board. Soft Tissue and Bone Tumors. Lyon (France): International Agency for Research on Cancer; 2020. (WHO classification of tumours series, 5th ed.; vol. 3)

#### H. Response to Chemotherapy / Radiation Therapy Effect

It is essential to estimate neoadjuvant treatment effect in primary Ewing sarcoma and osteosarcoma of bone, as these have been shown to have prognostic significance.<sup>1,2,3,4,5</sup> An entire representative slice of the tumor taken through the long axis should be mapped using a grid pattern diagram, photocopy, or radiologic film to indicate the site for each tumor block. In addition, the remainder of the neoplasm should be sampled at the rate of 1 section per centimeter. Areas of soft tissue extension and the interface of tumor with normal tissue should also be sampled. The sum of all viable areas measured microscopically is divided by the total cross-sectional area occupied by tumor to arrive at a percentage. Prognostically significant therapy response in osteosarcoma, according to most series, is defined at 90%, with those tumors showing 90% therapy response associated with a favorable prognosis.<sup>2,3</sup> There are 2 protocols to assess response to therapy in Ewing sarcoma. Response can be assessed in the same manner as osteosarcoma or by the system of Picci, which is expressed as grade I (macroscopic viable tumor), grade II (microscopic viable tumor), or grade III (no viable tumor).<sup>4,5</sup>

#### References

1. Amin MB, Edge SB, Greene FL, et al., eds. *AJCC Cancer Staging Manual*. 8th ed. New York, NY: Springer; 2017.
2. Picci P, Sangiorgi L, Rougraff BT, et al. Relationship of chemotherapy-induced necrosis and surgical margins to local recurrence in osteosarcoma. *J Clin Oncol*. 1994;12(12):2699-2705
3. Raymond AK, Chawla SP, Carrasco CH, et al. Osteosarcoma chemotherapy effect: a prognostic factor. *Semin Diagn Pathol*. 1987;4(3):212-236.
4. Bacci G, Ferrari S, Bertoni F, et al. Prognostic factors in nonmetastatic Ewing's sarcoma of bone treated with adjuvant chemotherapy: analysis of 359 patients at the Istituto Ortopedico Rizzoli. *J Clin Oncol*. 2000;18(1):4-11.
5. Picci P, Bohling T, Bacci G, et al. Chemotherapy-induced tumor necrosis as a prognostic factor in localized Ewing's sarcoma of the extremities. *J Clin Oncol*. 1997;15(4):1553-1559.

#### I. Lymphovascular Invasion

Lymphovascular invasion (LVI) indicates whether microscopic lymphovascular invasion is identified. LVI includes lymphatic invasion, vascular invasion, or lymphovascular invasion. By AJCC/UICC convention, LVI does not affect the T category indicating local extent of tumor unless specifically included in the definition of a T category.

#### J. Margins

It has been recommended that for all margins located less than 2 cm, the distance of the tumor from the margin be reported in centimeters.<sup>1</sup> However, there is a lack of agreement on this issue. We recommend specifying the location of all margins located less than 2 cm. Margins from bone tumors should be taken as *perpendicular* margins, if possible. If the tumor is located more than 2 cm from the margin, the marrow can be scooped out and submitted as a margin.

#### References

1. Abdul-Karim FW, Bauer TW, Kilpatrick SE, et al. Recommendations for the reporting of bone tumors. Association of Directors of Anatomic and Surgical Pathology. *Hum Pathol*. 2004;35(10):1173-1178.

### **K. Regional Lymph Nodes**

Regional lymph node metastasis is extremely rare in adult bone sarcomas. Nodes are not sampled routinely, and it is not necessary to exhaustively search for nodes. When no lymph nodes are resected, the pathologic 'N' category is not assigned (pNX is not used for bone tumors).<sup>1</sup> When present, regional lymph node metastasis has prognostic importance and should be reported. Patients whose nodal status is not determined to be positive for tumor, either clinically or pathologically, should be designated as N0.

#### References

1. Amin MB, Edge SB, Greene FL, et al, eds. AJCC Cancer Staging Manual. 8th ed. New York, NY: Springer; 2017.

### **L. Pathologic Stage Classification (TNM and Stage Groupings)**

The 8<sup>th</sup> edition TNM staging system for bone tumors of the AJCC and the UICC is recommended.<sup>1,2</sup>

The classification is to be applied to all primary tumors of bone. Anatomic site is known to influence outcome; therefore, outcome data should be reported specifying site. Site groups for bone sarcomas are the following: appendicular skeleton, including trunk, skull and facial bones, pelvis, and spine. Pathologic staging includes pathologic data obtained from examination of a resected specimen sufficient to evaluate the highest T category, histopathologic type and grade, regional lymph nodes as appropriate, or distant metastasis. Because regional lymph node involvement from bone tumors is rare, the pathologic stage grouping includes any of the following combinations: pT pG pN pM, or pT pG cN cM, or cT cN pM

#### TNM Descriptors

For identification of special cases of TNM or pTNM classifications, the “m” suffix and the “y” and “r” prefixes are used. Although they do not affect the stage grouping, they indicate cases needing separate analysis.

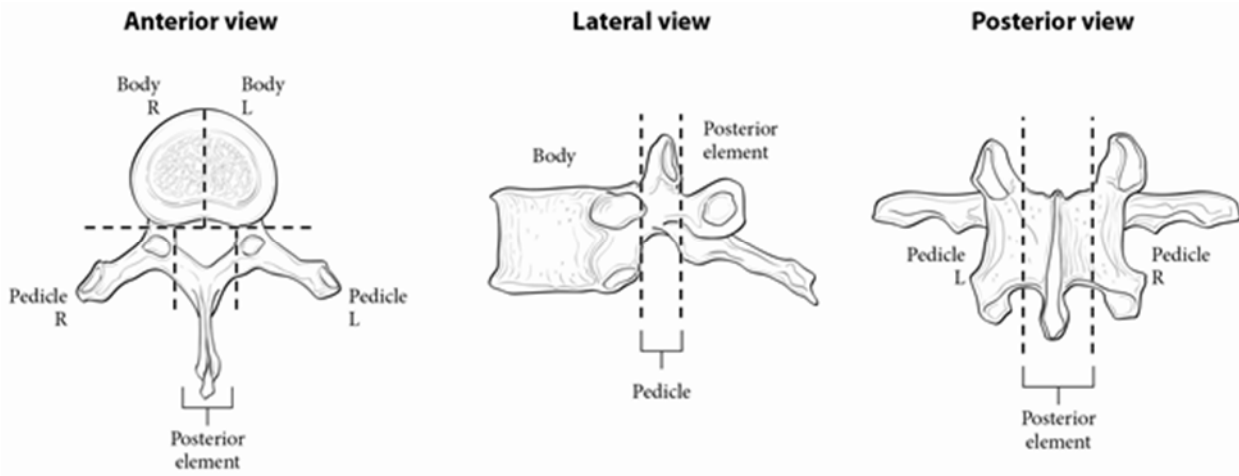
The “m” suffix indicates the presence of multiple primary tumors in a single site and is recorded in parentheses: pT(m)NM.

The “y” prefix indicates those cases in which classification is performed during or following initial multimodality therapy (ie, neoadjuvant chemotherapy, radiation therapy, or both chemotherapy and radiation therapy). The cTNM or pTNM category is identified by a “y” prefix. The ycTNM or ypTNM categorizes the extent of tumor actually present at the time of that examination. The “y” categorization is not an estimate of tumor prior to multimodality therapy (ie, before initiation of neoadjuvant therapy).

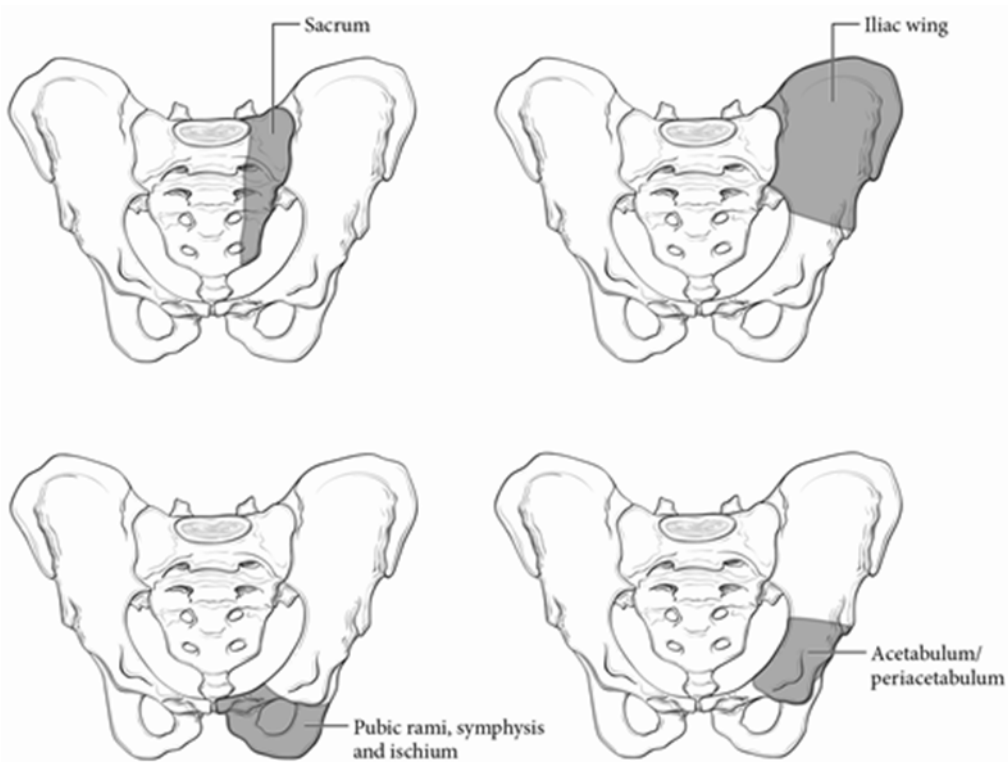
The “r” prefix indicates a recurrent tumor when staged after a documented disease-free interval, and is identified by the “r” prefix: rTNM.

T Category Considerations (Figures 2 and 3)

Spine segments for staging:



**Figure 2.** Spine segments for staging. Used with permission of the American Joint Committee on Cancer (AJCC), Chicago, Illinois. The original source for this material is the AJCC Cancer Staging Manual (2017) published by Springer Science and Business Media LLC, [www.springerlink.com](http://www.springerlink.com).



**Figure 3.** Pelvic segments for staging. Used with permission of the American Joint Committee on Cancer (AJCC), Chicago, Illinois. The original source for this material is the AJCC Cancer Staging Manual (2017) published by Springer Science and Business Media LLC, [www.springerlink.com](http://www.springerlink.com)

### N Category Considerations

Because of the rarity of lymph node involvement in sarcomas, the designation NX may not be appropriate and could be considered N0 if no clinical involvement is evident.

### References

1. Amin MB, Edge SB, Greene FL, et al., eds. *AJCC Cancer Staging Manual*. 8th ed. New York, NY: Springer; 2017.
2. Brierley JD, Gospodarowicz MK, Wittekind C, et al., eds. *TNM Classification of Malignant Tumours*. 8th ed. Oxford, UK: Wiley; 2016.