



Protocol for the Examination of Resection Specimens from Patients with Ductal Carcinoma In Situ (DCIS) of the Breast

Version: 4.5.0.0

Protocol Posting Date: June 2026

CAP Laboratory Accreditation Program Protocol Required Use Date: March 2027

The changes included in this current protocol version affect accreditation requirements. The new deadline for implementing this protocol version is reflected in the above accreditation date.

For accreditation purposes, this protocol should be used for the following procedures AND tumor types:

Procedure	Description
Excision less than total mastectomy	Includes specimens designated excision, segmental resection, lumpectomy, quadrantectomy and segmental or partial mastectomy, with or without axillary contents
Total Mastectomy	Includes skin-sparing and nipple-sparing mastectomy, with or without axillary contents
Tumor Type	Description
Ductal carcinoma in situ without invasive carcinoma or microinvasion	
Paget disease of the nipple not associated with invasive breast carcinoma	
Encapsulated papillary carcinoma without invasive carcinoma	
Solid papillary carcinoma without invasive carcinoma	

This protocol is NOT required for accreditation purposes for the following:

Procedure
Needle or skin biopsies
Primary resection specimen with no residual cancer
Additional excision performed after the definitive resection (e.g., re-excision of surgical margins)
Cytologic specimens

The following tumor types should NOT be reported using this protocol

Tumor Type
Any tumor with invasive carcinoma, including DCIS with microinvasion only or neoadjuvantly treated invasive cancer with only residual DCIS (consider Breast Invasive Carcinoma Resection protocol)

Version Contributors

Author(s): Kimberly Allison, MD, FCAP*, Uma Krishnamurti, MD, PhD, FCAP *, Hannah L Gilmore, MD, FCAP*, Michael Berman, MD, FCAP*, Veronica Klepeis, MD, PhD, FCAP*

Other Expert Contributors: Katherine Adamson, MD, Rohit Bhargava, MD, Anne Grabenstetter, MD, Melinda Sanders, MD, Patrick L. Fitzgibbons, MD, FCAP, James Connolly, MD

* Denotes primary author.

For any questions or comments, contact: cancerprotocols@cap.org.

© 2026 College of American Pathologists (CAP). All rights reserved. For Terms of Use please visit www.cap.org/cancerprotocols . 1

Glossary:

Author: Expert who is a current member of the Cancer Committee, or an expert designated by the chair of the Cancer Committee.

Expert Contributors: Includes members of other CAP committees or external subject matter experts who contribute to the current version of the protocol.

RETIRED

Accreditation Requirements

Synoptic reporting with core and conditional data elements for designated specimen types* is required for accreditation.

- Data elements designated as core must be reported.
- Data elements designated as conditional only need to be reported if applicable.
- Data elements designated as optional are identified with "+". Although not required for accreditation, they may be considered for reporting.

This protocol is not required for recurrent or metastatic tumors resected at a different time than the primary tumor. This protocol is also not required for pathology reviews performed at a second institution (i.e., second opinion and referrals to another institution).

Full accreditation requirements can be found on the CAP website under [Accreditation Checklists](#). A list of core and conditional data elements can be found in the Summary of Required Elements under Resources on the CAP Cancer Protocols [website](#).

**Includes definitive primary cancer resection and pediatric biopsy tumor types.*

Synoptic Reporting

All core and conditionally required data elements outlined on the surgical case summary from this cancer protocol must be displayed in synoptic report format. Synoptic format is defined as:

- Data element: followed by its answer (response), outline format without the paired Data element: Response format is NOT considered synoptic.
- The data element should be represented in the report as it is listed in the case summary. The response for any data element may be modified from those listed in the case summary, including "Cannot be determined" if appropriate.
- Each diagnostic parameter pair (Data element: Response) is listed on a separate line or in a tabular format to achieve visual separation. The following exceptions are allowed to be listed on one line:
 - Anatomic site or specimen, laterality, and procedure
 - Pathologic Stage Classification (pTNM) elements
 - Negative margins, as long as all negative margins are specifically enumerated where applicable
- The synoptic portion of the report can appear in the diagnosis section of the pathology report, at the end of the report or in a separate section, but all Data element: Responses must be listed together in one location
- Organizations and pathologists may choose to list the required elements in any order, use additional methods in order to enhance or achieve visual separation, or add optional items within the synoptic report. The report may have required elements in a summary format elsewhere in the report IN ADDITION TO but not as replacement for the synoptic report i.e., all required elements must be in the synoptic portion of the report in the format defined above.

Summary of Changes

v 4.5.0.0

- WHO 6th Edition updates to content and explanatory notes
- Cover page update
- Tumor Site, Size (Extent) of DCIS, and Architectural Pattern(s) question updates
- Histologic Type and Nuclear Grade questions now multi-select
- Added Additional Lesion(s) question
- MARGIN, REGIONAL LYMPH NODE, SPECIAL STUDIES section updates
- pTMN Classification updates to include Modified Classification, T Suffix, optional pN Category, and addition of N Suffix

RETIRED

Reporting Template

Protocol Posting Date: June 2026

Select a single response unless otherwise indicated.

CASE SUMMARY: (DCIS OF THE BREAST: Resection)

Standard(s): AJCC 8

SPECIMEN

Procedure (Note [A](#))

- Excision (less than total mastectomy, including lumpectomy and partial mastectomy)
 Total mastectomy (including nipple-sparing and skin-sparing mastectomy)
 Other (specify): _____
 Not specified

Specimen Laterality

- Right
 Left
 Not specified

TUMOR

+Tumor Site (Note [B](#))

Tumor Site descriptor should specify the location of the invasive cancer based on correlation with radiology designation and / or gross findings (e.g., "R1, 3:00, 2 cm from nipple" or "upper outer quadrant").

- Specify tumor site / location: _____
 Not specified

Histologic Type (Note [C](#)) (select all that apply)

- Ductal carcinoma in situ (DCIS)
 Paget disease
 Encapsulated papillary carcinoma in situ
 Solid papillary carcinoma in situ
 Other histologic type not listed (specify): _____

Size (Extent) of DCIS (Note [D](#))

The size (extent) of DCIS (greatest dimension using gross and microscopic evaluation) is an estimation of the volume of breast tissue occupied by DCIS.

- Estimated size (extent) of DCIS is at least in Millimeters (mm): _____ mm
 Cannot be determined (explain): _____

+Size of DCIS Comment (e.g., clarify aspects of extent / size, such as sizes of in situ papillary components if relevant): _____

+Architectural Pattern(s) (Note [E](#)) (select all that apply)

- Comedo
 Cribriform
 Micropapillary

- Papillary
- Solid
- Solid papillary carcinoma in situ
- Encapsulated papillary carcinoma in situ
- Paget disease (DCIS involving nipple skin)
- Other (specify): _____

Nuclear Grade (Note F) (select all that apply)

- Grade I (low)
- Grade II (intermediate)
- Grade III (high)
- Other (specify): _____
- Cannot be determined (explain): _____

+Nuclear Grade Comment: _____

Necrosis (Note G)

- Not identified
- Present, focal (small foci or single cell necrosis)
- Present, central (expansive "comedo" necrosis)
- Other (specify): _____
- Cannot be determined (explain): _____

+Additional Lesion(s) (Note H) (select all that apply)

Non-classic / variant subtypes of LCIS include: Pleomorphic LCIS (pleomorphic nuclei greater than 4 times the size of a lymphocyte or equivalent to nuclei of high-grade DCIS) and Florid LCIS (proliferation of cells cytologically similar to those of classic LCIS but expanding the acini of the involved TDLUs so that little to no residual intervening intra-lobular stroma is present, and / or an expanded acinus or duct spans approximately 40–50 cells in diameter). Comedonecrosis in classic LCIS may also be considered non-classic / variant (describe in "Other (specify)").

- Not identified
- Lobular carcinoma in situ, classic
- Lobular carcinoma in situ, pleomorphic
- Lobular carcinoma in situ (specify): _____
- Atypical lobular hyperplasia
- Atypical ductal hyperplasia
- Flat epithelial atypia
- Other (specify): _____

+Extent of LCIS: _____

+Additional Lesion(s) Comment: _____

+Microcalcifications (Note I) (select all that apply)

- Not identified
- Present in DCIS
- Present in non-neoplastic tissue
- Other (specify): _____

MARGINS (Note J)

Margin Status#

Final margin status should be determined based on findings in any additional separately submitted final margins, as well as margins that are considered final in the primary resection specimen (i.e., a final margin status summary). If the final margin status is not clear based on the specimens received (i.e., additional margins without a clear relationship to initial margins), the distances to each can be stated in the "Other (specify)" reporting section with a recommendation for surgical correlation.

- Not applicable (no residual DCIS in specimen)
- All final margins greater than 2 mm from DCIS
- DCIS present within 0-2 mm of final margins (specify specific margins below)

Margin(s) Involved by DCIS (at ink)

- None identified
- Specify involved margins: _____

Margin(s) Less than 1 mm from DCIS (but not at ink)

- None identified
- Specify: _____

Margin(s) 1 to 2 mm from DCIS

- None identified
- Specify: _____

+Margin(s) Greater than 2 mm from DCIS

- None identified
- Specify: _____
- Other (specify): _____
- Cannot be determined (explain): _____

+Margin Comment for DCIS (consider using for pleiomorphic or florid LCIS): _____

REGIONAL LYMPH NODES (Note K)

Regional Lymph Node Status

- Not applicable (no regional lymph nodes submitted or found)
- Regional lymph nodes present
 - All regional lymph nodes negative for tumor
 - Tumor present in regional lymph node(s)

Number of Lymph Nodes with Macrometastases (greater than 2 mm)

- Exact number (specify): _____
- Other (specify): _____
- Cannot be determined (explain): _____

Number of Lymph Nodes with Micrometastases (greater than 0.2 mm to 2 mm and / or greater than 200 cells)

- Exact number (specify): _____
- Other (specify): _____
- Cannot be determined (explain): _____

Number of Lymph Nodes with Isolated Tumor Cells (0.2 mm or less OR 200 cells or less) (required only if applicable)#

Reporting the number of lymph nodes with isolated tumor cells is required only in the absence of macrometastasis or micrometastasis in other lymph nodes.

- Not applicable
- Exact number (specify): _____
- Other (specify): _____
- Cannot be determined (explain): _____

+Total Number of Positive Macroscopic and Microscopic Lymph Nodes Counted Towards pN Category#

Add macrometastases and micrometastases for pN total. If only micrometastasis are present, use "Other (specify)" since they do not change the total lymph nodes counted toward the pN stage (staged as pTmi even if multiple). ITCs also do not count towards the total pN staging (staged as pN(i+) even if multiple).

- Exact number (specify): _____
- Other (specify): _____
- Cannot be determined: _____

Size of Largest Nodal Metastatic Deposit#

The size of a tumor deposit is determined by measuring the largest dimension of any group of cells that are touching one another (confluent or contiguous tumor cells), regardless of whether the deposit is confined to the lymph node, extends outside the node (extranodal extension), is totally present outside the lymph node and invading adipose tissue, or is present within a lymphatic channel adjacent to the node. Specify in Millimeters (mm)

- Exact size: _____ mm
- Other (specify): _____
- Cannot be determined (explain): _____

Extranodal Extension (ENE)#

The measurement of extranodal extent can be performed either perpendicular to the lymph node capsule or in another dimension. As a general principle, the larger measurement can be preferentially used but there is no evidence to support a specific method. It is optional to report the specific measurement of extranodal extension, which may not be feasible when extensive (details of extranodal extension can also be described in the "Regional Lymph Node Comment" or the "Other (specify)" sections).

- Not identified
- Present

+Largest Measurement of Extranodal Extension

Specify in Millimeters (mm)

- Exact measurement: _____ mm
- Other (specify): _____
- Cannot be determined: _____

+Number of Lymph Nodes with Extranodal Extension

- Exact number (specify): _____
- Other (specify): _____
- Cannot be determined: _____
- Other (specify): _____
- Cannot be determined (explain): _____
- Other (specify): _____
- Cannot be determined (explain): _____

Total Number of Lymph Nodes Examined (sentinel and non-sentinel)

- Exact number (specify): _____
- Other (specify): _____
- Cannot be determined (explain): _____

+Regional Lymph Node Comment: _____

DISTANT METASTASIS

Distant Site(s) Involved, if applicable (select all that apply)

- Not applicable
- Non-regional lymph node(s) (specify, if possible): _____
- Lung: _____
- Liver: _____
- Bone: _____
- Brain: _____
- Other (specify): _____
- Cannot be determined (explain): _____

pTNM CLASSIFICATION (AJCC 8th Edition) (Note [L](#))

Reporting of pT, pN, and (when applicable) pM categories is based on information available to the pathologist at the time the report is issued. As per the AJCC (Chapter 1, 8th Ed.) it is the managing physician's responsibility to establish the final pathologic stage based upon all pertinent information, including but potentially not limited to this pathology report.

Modified Classification (required only if applicable) (select all that apply)

- Not applicable
- y (post-neoadjuvant therapy)
- r (recurrence)

pT Category

Paget disease with underlying DCIS is classified as Tis (DCIS). Encapsulated and solid papillary carcinomas without conventional invasive carcinoma are classified as pTis (DCIS). If there has been a prior core needle biopsy, the pathologic findings from the core, if available, should be considered when determining the T category. If invasive carcinoma or microinvasion were present on the core, the protocol for invasive carcinomas of the breast should be used and should incorporate this information.

Lobular carcinoma in situ (LCIS) is removed from TNM staging in the AJCC Cancer Staging Manual, 8th Edition.

- pTis (DCIS): Ductal carcinoma in situ
- pTis (Paget): Paget disease of the nipple NOT associated with invasive carcinoma and / or DCIS in the underlying breast parenchyma#

T Suffix (required only if applicable)

- Not applicable
- (m) multiple primary synchronous tumors in a single organ

pN Category

Choose a category if lymph nodes received with the specimen; immunohistochemistry and / or molecular studies are not required

- pN not assigned (no nodes submitted or found)
- pN not assigned (cannot be determined based on available pathological information)
- # Isolated tumor cells (ITCs) are defined as small clusters of cells not larger than 0.2 mm or single tumor cells, or a cluster of fewer than 200 cells in a single histologic cross-section. ITCs may be detected by routine histology or by immunohistochemical (IHC) methods. Nodes containing only ITCs are excluded from the total positive node count when determining the N category but should be included in the total number of nodes evaluated.
- pN0: No regional lymph node metastasis identified or ITCs only#
- pN0 (i+): ITCs only (malignant cell clusters no larger than 0.2 mm) in regional lymph node(s)
- pN0 (mol+): Positive molecular findings by reverse transcriptase polymerase chain reaction (RT-PCR); no ITCs detected
- pN1mi: Micrometastases (approximately 200 cells, larger than 0.2 mm, but none larger than 2.0 mm)

Approximately 1000 tumor cells are contained in a 3-dimensional 0.2 mm cluster. Thus, if more than 200 individual tumor cells are identified as single dispersed tumor cells or as a nearly confluent elliptical or spherical focus in a single histologic section of a lymph node, there is a high probability that more than 1000 cells are present in the lymph node. In these situations, the node should be classified as containing a micrometastasis (pN1mi). Cells in different lymph node cross-sections or longitudinal sections or levels of the block are not added together; the 200 cells must be in a single node profile even if the node has been thinly sectioned into multiple slices. It is recognized that there is substantial overlap between the upper limit of the ITC and the lower limit of the micrometastasis categories due to inherent limitations in pathologic nodal evaluation and detection of minimal tumor burden in lymph nodes. Thus, the threshold of 200 cells in a single cross-section is a guideline to help pathologists distinguish between these 2 categories. The pathologist should use judgment regarding whether it is likely that the cluster of cells represents a true micrometastasis or is simply a small group of isolated tumor cells.

pN1a: Metastases in 1-3 axillary lymph nodes, at least one metastasis larger than 2.0 mm##

pN1b: Metastases in ipsilateral internal mammary sentinel nodes, excluding ITCs

pN1c: pN1a and pN1b combined

pN2a: Metastases in 4-9 axillary lymph nodes, at least one tumor deposit larger than 2.0 mm##

pN2b: Metastases in clinically detected internal mammary lymph nodes with or without microscopic confirmation; with pathologically negative axillary nodes

pN3a: Metastases in 10 or more axillary lymph nodes (at least one tumor deposit larger than 2.0 mm)##; or metastases to the infraclavicular (Level III axillary lymph) nodes

pN3b: pN1a or pN2a in the presence of cN2b (positive internal mammary nodes by imaging); or pN2a in the presence of pN1b

pN3c: Metastases in ipsilateral supraclavicular lymph nodes

N Suffix (required only if applicable) (select all that apply)

The (sn) modifier is added to the N category when a sentinel node biopsy is performed (using either dye or tracer) and fewer than six lymph nodes are removed (sentinel and nonsentinel). The (f) modifier is added to the N category to denote confirmation of metastasis by fine needle aspiration / core needle biopsy with NO further resection of nodes.

Not applicable

(sn): Sentinel node(s) evaluated. If 6 or more nodes (sentinel or nonsentinel) are removed, this modifier should not be used.

(f): Nodal metastasis confirmed by fine needle aspiration or core needle biopsy.

pM Category (required only if confirmed pathologically)

The presence of distant metastases in a case of DCIS would be very unusual. Additional sampling to identify invasive carcinoma in the breast or additional history to document a prior or synchronous invasive carcinoma is advised in the evaluation of such cases.

Not applicable - pM cannot be determined from the submitted specimen(s)

pM1: Histologically proven metastases larger than 0.2 mm

+Specify Case Number (if from a previous procedure): _____

SPECIAL STUDIES

This section is available to include prior breast cancer biomarker results on the DCIS, typically as reported on the initial core biopsy specimen(s). Specify the case number, tumor identifier (if relevant), and the available biomarker results. The CAP Breast Biomarker Template should be used for reporting biomarkers performed on samples from this resection specimen. Pending biomarker studies can be listed in the "Comments" section of this report.

+Biomarker Testing Performed on Prior Case (specify): _____

Specify Tumor Identifier (if multiple tumors are present): _____

+Breast Biomarker Testing Performed on Previous Biopsy (select all that apply)

Estrogen Receptor (ER)

Estrogen Receptor (ER) Status

Positive (greater than 10% of cells demonstrate nuclear positivity)

+Percentage of Cells with Nuclear Positivity

Specify percentage: _____ %

OR

Select range below

11-20%

21-30%

31-40%

41-50%

51-60%

61-70%

71-80%

81-90%

91-100%

Low positive (1-10% of cells with nuclear positivity)

Negative

Cannot be determined (explain): _____

Progesterone Receptor (PgR)

Progesterone Receptor (PgR) Status

Positive

+Percentage of Cells with Nuclear Positivity

Specify percentage: _____ %

OR

Select range below

1-10%

11-20%

21-30%

31-40%

41-50%

51-60%

61-70%

71-80%

81-90%

91-100%

Negative

Cannot be determined (explain): _____

COMMENTS

Comment(s): _____

Explanatory Notes

A. Breast Specimens and Breast Procedures

Breast Specimens

The following types of breast specimens and procedures may be reported with the case summary:

Excisions. Removal of breast tissue without the intent of removing the entire breast. The nipple is only rarely removed with excisions. Excisions include specimens designated biopsies, partial mastectomies, lumpectomies, and quadrantectomies.

Total Mastectomy. Removal of all breast tissue, including the nipple and areola.

- Simple mastectomy: This procedure consists of a total mastectomy without removal of axillary lymph nodes.
- Skin-sparing mastectomy: This is a total mastectomy with removal of the nipple and only a narrow surrounding rim of skin.
- Modified radical mastectomy: This procedure consists of a total mastectomy and an axillary dissection. In the case summary, the breast and lymph node specimens are documented separately.
- Radical mastectomy: This procedure consists of a total mastectomy, axillary contents, and removal of the pectoralis muscles, and currently is performed only rarely. This type of specimen and procedure can be indicated on the case summary as “Other.”

The following types of specimens should not be reported using this protocol:

- Very small incisional biopsies (including core needle biopsies).
- Excisions or mastectomies containing only residual DCIS after a core needle biopsy or other specimen showing invasive carcinoma or DCIS with microinvasion (invasion measuring ≤ 1 mm). This type of case should be reported by using the protocol for invasive carcinoma of the breast,¹ and the report should incorporate information from the prior needle biopsy.

Specimen Sampling

Specimen sampling for specimens with DCIS has the following goals:[2,3,4,5](#)

- The clinical or radiologic lesion for which the surgery was performed must be examined microscopically. If the lesion is a nonpalpable imaging finding, the specimen radiograph and/or additional radiologic studies may be necessary to identify the lesion. When practical, the entire specimen should be submitted in a sequential fashion for histologic examination. If this is not possible, at least the entire region of the targeted lesion should be examined microscopically.
- Any additional potentially clinically relevant lesions noted in the specimen must be sampled.
- The margins must be evaluated for involvement by DCIS. If the specimen is received sectioned or fragmented, this should be noted, as this will limit the ability to evaluate the size of the lesion and the status of margins. If the specimen is an incisional biopsy, margins need not be evaluated.

For specimens with a known diagnosis of DCIS (e.g., by prior core needle biopsy), it is recommended that the entire specimen be examined, if practical, using serial sequential sampling to exclude the possibility of invasion, to completely evaluate the margins, and to aid in determining extent.^{6,7,8} If an entire excisional specimen or grossly evident lesion is not examined microscopically, it is helpful to note the approximate percentage of the specimen or lesion that has been examined.

Carcinomas present in excisions removed for lesions seen best by MRI studies are generally not grossly evident and not seen on specimen radiography.

Recording the specimen size in the gross description is important, as the volume of tissue excised has been associated with the likelihood of recurrence.⁹

Tissue may be taken for research studies or assays that do not involve the histologic examination of the tissue (e.g., reverse transcriptase polymerase chain reaction [RT-PCR]) only when taken in such a way to be able to evaluate the tissue for small areas of invasion. For example, a thin slice of tissue taken for research studies should be matched with an adjacent slice of tissue that will be examined microscopically.

References

1. Krishnamurti, UG, Allison, KH, Fitzgibbons, P, Connolly, JL. Protocol for the Examination of Resection Specimens from Patients with Invasive Carcinoma of the Breast. 2024; www.cap.org/cancerprotocols, accessed March 19, 2026.
2. Owings DV, Hann L, Schnitt SJ, How thoroughly should needle localization breast biopsies be sampled for microscopic examination? A prospective mammographic/pathologic correlative study. *Am J Surg Pathol*. 1990; 14:578-583.
3. Schwartz GF, Lagios MD, Carter D, et al. Consensus conference on the classification of ductal carcinoma in situ. *Cancer*. 1997; 80:1798-1802.
4. Silverstein MJ, Lagios MD, Recht A, et al. Image-detected breast cancer: state of the art diagnosis and treatment. *J Am Coll Surg*. 2005; 201:586-597.
5. Lester SC. *Manual of Surgical Pathology*. 2nd ed. New York: Elsevier; 2006.
6. Silverstein MJ, Poller D, Craig P, et al. A prognostic index for ductal carcinoma in situ of the breast. *Cancer*. 1996; 77:2267-2274.
7. Grin A, Horne G, Ennis M, O'Malley FP. Measuring extent of DCIS in breast excision specimens: a comparison of four methods. *Arch Pathol Lab Med*. 2009; 133:31-37.
8. Dadmanesh F, Fan X, Dastane A, Amin MB, Bose S. Comparative analysis of size estimation by mapping and counting number of blocks with DCIS in breast excision specimens. *Arch Pathol Lab Med*. 2009; 133:26-30.
9. Vicini FA, Kestin LL, Goldstein NS, Baglan KL, Pettinga JE, Martinez AA. Relationship between excision volume, margin status, and tumor size with the development of local recurrence in patients with ductal carcinoma-in-situ treated with breast-conserving therapy. *J Surg Oncol*. 2001; 76:245-254.

B. Tumor Site

The site/location and lesion designation (ex. L1 mass, R2 calcifications, etc.) of DCIS is helpful to document, when provided by the surgeon, breast imaging, or previous pathology report, to correlate with prior studies (e.g., a core needle biopsy) or with future biopsies or cancer events. The site/location can be

listed as designated by the surgeon or imaging finding (ex. 9:00, 4 cm from nipple) or less specifically as a quadrant or gross specimen location. In a mastectomy specimen, it is helpful to locate the DCIS with respect to the clinical site or imaging site, when possible and to use similar designations as used in imaging for lesions (ex. L1, R3).

C. Histologic Type

This protocol applies only to cases of DCIS. The protocol for invasive carcinoma of the breast¹ applies if invasion or microinvasion (less than or equal to 1 mm) is present. Pleomorphic lobular carcinoma in situ (LCIS) has overlapping features with DCIS and may be treated similarly, but at present, there is insufficient evidence to establish definitive recommendations for treatment. Thus, pleomorphic LCIS is not currently included in the pTis classification.

When DCIS involves nipple skin only, without underlying invasive carcinoma or DCIS, the classification is DCIS (i.e., Tis [Paget]). The majority of these cases are strongly positive for HER2.

The WHO criteria for a diagnosis of Encapsulated Papillary Carcinoma and Solid Papillary Carcinoma In Situ should be used in classification.² Myoepithelial cells may be absent or attenuated, but the contours of these lesions should be circumscribed to classify them as in situ. These lesions are clinically managed like DCIS.

References

1. Krishnamurti, UG, Allison, KH, Fitzgibbons, P, Connolly, JL. Protocol for the Examination of Resection Specimens from Patients with Invasive Carcinoma of the Breast. 2024; www.cap.org/cancerprotocols, accessed March 19, 2026.
2. WHO Classification of Tumours Editorial Board. Breast *tumours*. Lyon (France): International Agency for Research on Cancer; 2026. (WHO classification of tumours series, 6th ed.).

D. Size (Extent) of DCIS

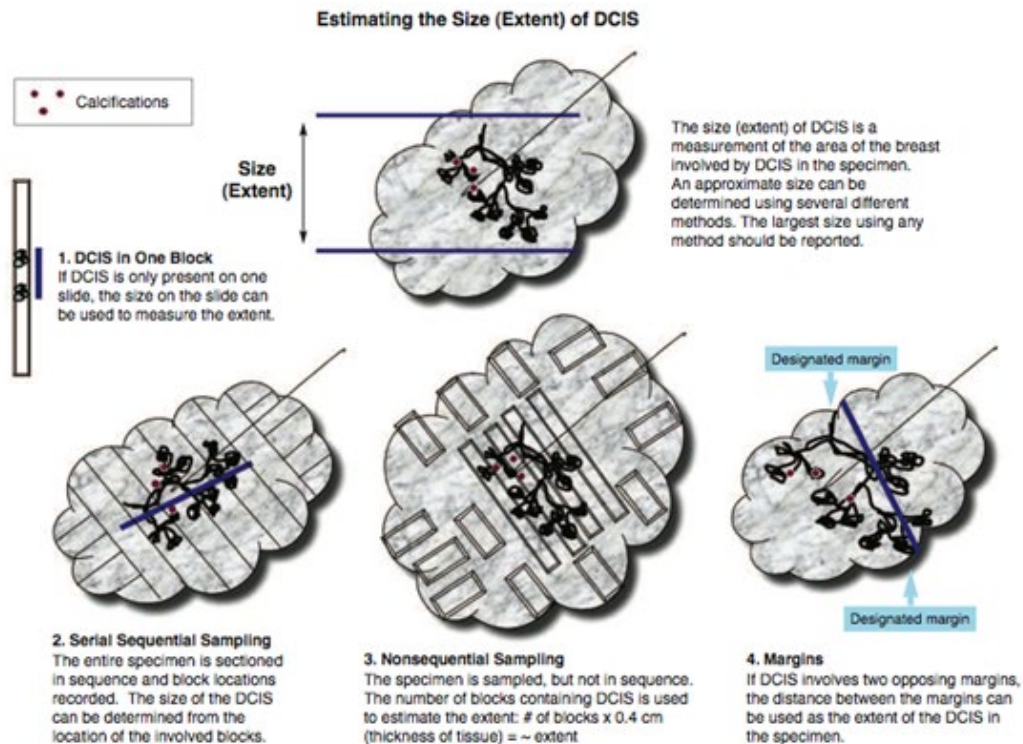
Although not required for pT classification or stage assignment, the size (extent) of DCIS is an important factor in patient management.^{1,2} Extent (as determined by a number of different methods) is correlated with the likelihood of residual disease after re-excision,^{3,4,5,6} close or positive margins, local recurrence,^{7,8,9} and the possibility of missed areas of invasion.^{10,11} Extent is not as important for predicting local recurrence when wide margins are obtained.^{7,8,12} Extent is an estimation of the volume of breast tissue involved by DCIS. Mammographic assessment of DCIS, usually based on distribution of calcifications, frequently underestimates, and sometimes overestimates, the extent of DCIS.

Although a precise measurement is often not possible, an estimate of the extent of DCIS is clinically important (Table 1).

Table 1. Extent of Ductal Carcinoma In Situ (DCIS) and Clinical Significance

Size	Extent
Up to 20 mm	Breast conservation with wide negative margins can be achieved in most women. Microscopic examination of the entire area involved by DCIS is recommended and should be possible in most cases. This will require complete microscopic examination of smaller biopsies, or sampling of large excisions or mastectomies to include all areas likely to contain DCIS (e.g., tissue with radiologic calcifications or grossly abnormal tissue).
>20-40 mm	Wide negative margins may be difficult to achieve in some women with breast-conserving surgery.

	Microscopic examination of the entire area involved by DCIS is recommended but may be difficult to achieve in some cases. This will require complete microscopic examination of smaller biopsies or sampling of large excisions or mastectomies to include all areas likely to contain DCIS (e.g., tissue with radiologic calcifications or grossly abnormal tissue).
>40 mm	Breast conservation with wide negative margins may be impossible to achieve in some women. Microscopic examination of the entire area involved by DCIS is recommended but may be impractical in some cases. This will require complete microscopic examination of smaller biopsies or selective sampling of large excisions or mastectomies to include areas likely to contain DCIS (e.g., tissue with radiologic calcifications or grossly abnormal tissue). There is a possibility of undetected areas of invasion if the area involved by DCIS is not completely examined. Lymph node sampling may be recommended.



There are multiple methods for estimating the extent of DCIS (see Figure):

- **DCIS in 1 block:** The area involved by DCIS can be measured from a single slide, if DCIS is present in only 1 block. If separate foci are present, the largest distance between foci should be reported. This method will underestimate the extent of DCIS when multiple blocks are involved and should not be used in such cases.¹³

- **Serial sequential sampling:** The entire specimen is blocked out in such a way that the location of each block can be determined. The extent of the DCIS can be calculated by using a diagram of the specimen, the thickness of the slices, and the location of the involved blocks.^{13,14,15} This method is recommended for all excisions likely to harbor DCIS or with previously diagnosed DCIS (e.g., by diagnosis on a prior core needle biopsy).
- **Nonsequential sampling:** The number of blocks involved by DCIS is not recommended as the only method of estimating DCIS extent since this is highly dependent on how many sections are taken from each slice (and therefore can both significantly over and underestimate extent). However, this information can be included in the additional extent descriptors section.
- **Edges of specimens:** If DCIS involves or is close to 2 opposing margins of a surgical excision, the distance between the margins can be used as the extent of the DCIS within the specimen.
- **Gross lesions:** In some cases of high-grade DCIS, there may be a gross lesion that can be measured. Confirmation of the gross size must be confirmed by microscopic evaluation.

The largest estimate obtained using any of these methods should be used to report the estimated size (extent) of the DCIS. Additional extent descriptors might include if multiple separate areas of DCIS are present, or other estimations of extent/volume).

References

1. Silverstein MJ, Lagios MD, Recht A, et al. Image-detected breast cancer: state of the art diagnosis and treatment. *J Am Coll Surg*. 2005; 201:586-597.
2. O'Sullivan MJ, Morrow M. Ductal carcinoma in situ: current management. *Surg Clin North Am*. 2007; 87:333-351, viii.
3. Dillon MF, McDermott EW, O'Doherty A, et al. Factors effecting successful breast conservation for ductal carcinoma in situ. *Ann Surg Oncol*. 2007;14:1618-1628.
4. Sigal-Zafrani B, Lewis JS, Clough KB, et al; on behalf of the Institut Curie Breast Study Group. Histologic margin assessment for breast ductal carcinoma in situ: precision and implications. *Mod Pathol*. 2004; 17:81-88.
5. Neuschatz AC, DiPetrillo T, Steinhoff M, et al. The value of breast lumpectomy margin assessment as a predictor of residual tumor burden in ductal carcinoma in situ of the breast. *Cancer*. 2002; 94:1917-1924.
6. Cheng L, Al-Kaisi NK, Gordon NH, Liu AY, Gebrail F, Shenk RR. Relationship between the size and margin status of ductal carcinoma in situ of the breast and residual disease. *J Natl Cancer Inst*. 1997; 89:1356-1360.
7. Di Saverio S, Catena F, Santini D, et al. 259 patients with DCIS of the breast applying USC/Van Nuys prognostic index: a retrospective review with long term follow up. *Breast Cancer Res Treat*. 2008; 109:404-416.
8. MacDonald HR, Silverstein MJ, Mabry H, et al. Local control in ductal carcinoma in situ treated by excision alone: incremental benefit of larger margins. *Am J Surg*. 2005; 190:521-525.
9. Asjoe FT, Altintas S, Huizing MT, et al. The value of the Van Nuys Prognostic Index in ductal carcinoma in situ of the breast: a retrospective analysis. *Breast J*. 2007; 13:359-367.
10. Maffuz A, Barroso-Bravo S, Najera I, Zarco G, Alvarado-Cabrero I, Roriguez-Cuevas SI. Tumor size as predictor of microinvasion, invasion, and axillary metastasis in ductal carcinoma in situ. *J Exp Clin Cancer Res*. 2006; 25:223-227.

11. Moore KH, Sweeney KJ, Wilson ME, et al. Outcomes for women with ductal carcinoma-in-situ and a positive sentinel lymph node: a multi-institutional audit. *Ann Surg Oncol.* 2007;14: 2911-2917.
12. MacDonald HR, Silverstein MJ, Lee LA, et al. Margin width as the sole determinant of local recurrence after breast conservation in patients with ductal carcinoma in situ of the breast. *Am J Surg.* 2006; 192:420-422.
13. Grin A, Horne G, Ennis M, O'Malley FP. Measuring extent of DCIS in breast excision specimens: a comparison of four methods. *Arch Pathol Lab Med.* 2009; 133:31-37.
14. Dadmanesh F, Fan X, Dastane A, Amin MB, Bose S. Comparative analysis of size estimation by mapping and counting number of blocks with DCIS in breast excision specimens. *Arch Pathol Lab Med.* 2009; 133:26-30.
15. Silverstein MJ, Poller D, Craig P, et al. A prognostic index for ductal carcinoma in situ of the breast. *Cancer.* 1996; 77:2267-2274.

E. Architectural Pattern

The architectural pattern has been reported traditionally for DCIS.¹² However, nuclear grade and the presence of necrosis are more predictive of clinical outcome. Paget's encapsulated papillary carcinoma and solid papillary carcinoma in situ can also be reported as architectural patterns, but they are also considered distinct histologic types of DCIS.

References

1. Schwartz GF, Lagios MD, Carter D, et al. Consensus conference on the classification of ductal carcinoma in situ. *Cancer.* 1997; 80:1798-1802.
2. Silverstein MJ, Lagios MD, Recht A, et al. Image-detected breast cancer: state of the art diagnosis and treatment. *J Am Coll Surg.* 2005; 201:586-597.

F. Nuclear Grade

The nuclear grade of DCIS is determined using 6 morphologic features (Table 2).^{1,2,3}

Table 2. Nuclear Grade of Ductal Carcinoma In Situ

Feature	Grade (Low) I	Grade (Intermediate) II	Grade (High) III
Pleomorphism	Monotonous (monomorphic)	Intermediate	Markedly pleomorphic
Size	1.5 to 2 x the size of a normal RBC or a normal duct epithelial cell nucleus	Intermediate	>2.5 x the size of a normal RBC or a normal duct epithelial cell nucleus
Chromatin	Usually diffuse, finely dispersed chromatin	Intermediate	Usually vesicular with irregular chromatin distribution
Nucleoli	Only occasional		Prominent, often multiple
Mitoses	Only occasional	Intermediate	May be frequent
Orientation	Polarized toward luminal spaces	Intermediate	Usually not polarized toward the luminal space

Definition: RBC, red blood cell.

References

1. Schwartz GF, Lagios MD, Carter D, et al. Consensus conference on the classification of ductal carcinoma in situ. *Cancer*. 1997; 80:1798-1802.
2. Bane A.: Ductal Carcinoma In Situ: What the Pathologist Needs to Know and Why. *Int J Breast Cancer* 2013:914053. doi: 10.1155/2013/914053.
3. Hanna WM, Parra-Herran C, Lu FI et al. Ductal carcinoma in situ of the breast: an update for the pathologist in the era of individualized risk assessment and tailored therapies. *Mod Pathol*. 2019 32 (7): 896-91.

G. Necrosis

The presence of necrosis is correlated with the finding of mammographic calcifications (i.e., most areas of necrosis will calcify). DCIS that presents as mammographic calcifications often recurs as calcifications.

Necrosis can be classified as follows:^{1,2}

- **Central (“comedo”)**: The central portion of an involved ductal space is replaced by an area of expansive necrosis that is easily detected at low magnification. Ghost cells and karyorrhectic debris are generally present. Although central necrosis is generally associated with high-grade nuclei (i.e., comedo DCIS), it can also occur with DCIS of low or intermediate nuclear grade. This type of necrosis often correlates with a linear and/or branching pattern of calcifications on mammography.
- **Focal (punctate)**: Small foci, indistinct at low magnification, or single cell necrosis (<10%).

Necrosis should be distinguished from secretory material, which can also be associated with calcifications, cytoplasmic blebs, and histiocytes, but does not include nuclear debris.

References

1. Schwartz GF, Lagios MD, Carter D, et al. Consensus conference on the classification of ductal carcinoma in situ. *Cancer*. 1997; 80:1798-1802.
2. Fox SB, Webster F, Chen CJ, et al. Dataset for pathology reporting of ductal carcinoma in situ, variants of lobular carcinoma in situ and low-grade lesions: recommendations from the International Collaboration on Cancer Reporting (ICCR). *Histopathology*. 2022 Oct;81(4):467-476. doi: 10.1111/his.14725. Epub 2022 Aug 8. PMID: 35869801.

H. Additional Lesions

In some cases, other pathologic findings are important for the clinical management of patients, such as risk lesions or non-classic/variant subtypes of lobular carcinoma in situ.

If the biopsy was performed for a benign lesion and the DCIS is an incidental finding, this should be documented. An example would be the finding of DCIS in an excision for a palpable fibroadenoma.

Peritumoral vascular invasion is a very rare finding in association with DCIS alone. Additional sampling should be considered to attempt to identify an area of invasion. If there has been prior surgery or needle biopsy, the possibility of artifactual displacement of epithelial cells into lymphatics should be considered. Lymph node biopsy may be performed in patients with DCIS and lymphovascular invasion.

If there has been a prior core needle biopsy or incisional biopsy, the biopsy site should be sampled and documented in the report. If the intention was to completely re-excite a prior surgical site, the report

should document biopsy changes at the margin that could indicate an incomplete excision. This protocol should only be used for re-excisions that reveal the largest extent of DCIS.

I. Microcalcifications

DCIS found in biopsies performed for microcalcifications will almost always be at the site of the calcifications or in close proximity.^{1,2} The presence of the targeted calcifications in the specimen should be confirmed by specimen radiography. The pathologist must be satisfied that the specimen has been sampled in such a way that the lesion responsible for the calcifications has been examined microscopically. The relationship of the radiologic calcifications to the DCIS should be indicated.

References

1. Owings DV, Hann L, Schnitt SJ, How thoroughly should needle localization breast biopsies be sampled for microscopic examination? A prospective mammographic/pathologic correlative study. *Am J Surg Pathol.* 1990; 14:578-583.
2. Silverstein MJ, Lagios MD, Recht A, et al. Image-detected breast cancer: state of the art diagnosis and treatment. *J Am Coll Surg.* 2005; 201:586-597.

J. Margins

Whenever feasible, the specimen should be oriented in order to identify specific margins.

Margins may be identified by sutures or clips placed on the specimen surface or by other means of communication between surgeon and pathologist, and should be documented in the pathology report. Margins can be identified microscopically in several ways, including the use of multiple colored inks, by submitting the margins in specific cassettes, or by the surgeon submitting each margin as a separately excised specimen. Inks should be applied to the surface of the specimen, taking care to avoid penetration into the specimen.

Margin status is considered Involved if the final margins have DCIS at ink (inclusive of any additional margins removed). If the specimen is oriented, the specific site(s) of involvement should also be reported. Additionally, margins less than 1 mm to DCIS (but not at ink), margins 1-2 mm from DCIS should be specified. Margins greater than 2 mm from DCIS can be specified if considered relevant. For ease of reporting, an option for "all final margins greater than 2 mm" is also available in the protocol. "Other" can be used for complex scenarios (such as description of the margin status of multiple specimens that require surgical correlation) and "Cannot be determined" for other uncommon scenarios with explanation. The Margin comment section can be used to clarify any additional margin details.

The deep margin may be at muscle fascia. If so, the likelihood of additional breast tissue beyond this margin (and therefore possible involvement by DCIS) is extremely small. A deep muscle fascial margin (e.g., on a mastectomy specimen) is unlikely to have clinical significance.

A superficial (generally anterior) margin may be immediately below the skin, and there may not be additional breast tissue beyond this margin. However, some breast tissue can be left in skin flaps, and the likelihood of residual breast tissue is related to the thickness of the flap.¹

Specimen radiography is important to assess the adequacy of excision. Compression of the specimen should be minimized, as it can severely compromise the ability to assess the distance of the DCIS from the surgical margin.² Mechanical compression devices should be used with caution and preferably reserved for nonpalpable lesions that require this technique for imaging (e.g., microcalcifications).

If DCIS is present at the margin, the extent of margin involvement is associated with the likelihood of residual disease:^{3,4}

- Focal: DCIS at the margin in a <1 mm area in 1 block
- Minimal/moderate: between focal and extensive
- Extensive: DCIS at the margin in an area ≥ 15 mm or in 5 or more low-power fields and/or in 8 or more blocks)

References

1. Torresan RZ, dos Santos CC, Okamura H, Alvarenga M. Evaluation of glandular tissue after skin-sparing mastectomies. *Ann Surg Oncol*. 2005; 12:1037-1044.
2. Saqi A, Osborne MP, Rosenblatt R, Shin SJ, Hoda SA, Quantifying mammary duct carcinoma in situ: a wild-goose chase? *Am J Clin Pathol*. 2000;113(suppl 1): S30-S37.
3. Dillon MF, McDermott EW, O'Doherty A, et al. Factors effecting successful breast conservation for ductal carcinoma in situ. *Ann Surg Oncol*. 2007;14:1618-1628.
4. Sigal-Zafrani B, Lewis JS, Clough KB, et al; on behalf of the Institut Curie Breast Study Group. Histologic margin assessment for breast ductal carcinoma in situ: precision and implications. *Mod Pathol*. 2004; 17:81-88.

K. Lymph Node Sampling and Reporting

Lymph Node Sampling

Patients with DCIS may have lymph nodes sampled in the following situations:

- Extensive DCIS: Patients with extensive DCIS are more likely to have areas of invasion and it may be difficult or impractical to examine all involved areas of the breast microscopically.^{1,2,3} A lymph node with a metastasis would indicate an occult area of invasion.
- Pathologic findings on a prior needle biopsy or excision raising concern for invasion or microinvasion (invasion measuring ≤ 1 mm in size): If invasion has been documented, the protocol for invasive carcinoma of the breast⁴ should be used.
- Imaging findings (e.g., an irregular mass) or clinical findings (e.g., a large palpable mass) that increase the likelihood that stromal invasion is present.²
- Planned mastectomy: The additional sampling of low lymph nodes or a sentinel lymph node does not result in increased morbidity. If the node or nodes are negative, and invasive cancer is found, another surgical procedure for node sampling can be avoided.

Most tumor cells in lymph nodes of patients with DCIS would be classified as isolated tumor cells.^{5,6} Artfactual displacement of epithelium to a lymph node(s) can occur following a core needle biopsy; this finding should not be considered isolated tumor cells or a micrometastasis.^{7,8} If a larger nodal metastasis is found and the breast tissue has not been entirely submitted for microscopic examination, additional sampling should be considered to attempt to identify invasive carcinoma.^{1,3}

Grossly uninvolved nodes should be submitted in their entirety for histologic examination, whereas a representative section of a grossly positive node may be submitted. Small nodes (e.g., 2 to 3 mm) may be

submitted intact, but larger nodes should be thinly sectioned. An accurate assessment of the number of positive lymph nodes is a critical prognostic indicator.

Sentinel lymph nodes are identified as such by the surgeon, generally by uptake of radiotracer or dye.

Reporting Lymph Nodes

The pathology report should state the total number of lymph nodes examined (including the number of sentinel nodes), the number of nodes with metastases, and the greatest dimension of the largest metastatic focus. If a patient has at least 1 macrometastasis, only nodes with micro and macrometastases are included for the total number of positive nodes for determining the N category.⁹ Nodes with isolated tumor cells are not included in this count. At least 1 node with presence or absence of cancer documented by pathologic examination is required for determining the pathologic N category.

The (sn) modifier indicates that nodal categorization is based on less than an axillary dissection. When the combination of sentinel and nonsentinel nodes removed is less than a standard low axillary dissection (fewer than six nodes), the (sn) modifier is used, e.g., pN0(i+)(sn). The (sn) modifier is not used if 6 or more lymph nodes are examined (including sentinel and nonsentinel lymph nodes).

Isolated tumor cells (ITCs) are defined as single tumor cells or small cell clusters not greater than 0.2 mm and numbering less than 200 cells.^{4,10,11,12} They may be detected by routine histologic examination or by immunohistochemical (IHC) or molecular methods. ITCs do not usually show evidence of malignant activity (e.g., proliferation or stromal reaction), but micrometastases may show these changes.

Almost all tumor cells present in lymph nodes of patients with DCIS are isolated tumor cells or the cells may be artifactually displaced from a previous procedure.^{7,8} Isolated tumor cells detected in cases of DCIS have not been shown to have prognostic importance.^{5,6} If a larger metastasis is found, additional tissue sampling and review of slides are helpful to determine if an area of invasion is present.³

References

1. Lagios MD, Westdahl PR, Margolin FR, et al. Duct carcinoma in situ: relationship of extent of noninvasive disease to the frequency of occult invasion, multicentricity, lymph node metastasis, and short-term treatment failures. *Cancer*. 1982; 50:1309-1314.
2. Maffuz A, Barroso-Bravo S, Najera I, Zarco G, Alvarado-Cabrero I, Roriguez-Cuevas SI. Tumor size as predictor of microinvasion, invasion, and axillary metastasis in ductal carcinoma in situ. *J Exp Clin Cancer Res*. 2006; 25:223-227.
3. Moore KH, Sweeney KJ, Wilson ME, et al. Outcomes for women with ductal carcinoma-in-situ and a positive sentinel lymph node: a multi-institutional audit. *Ann Surg Oncol*. 2007; 14:2911-2917.
4. Krishnamurti, UG, Allison, KH, Fitzgibbons, P, Connolly, JL. Protocol for the Examination of Resection Specimens from Patients with Invasive Carcinoma of the Breast. 2024; www.cap.org/cancerprotocols, accessed March 19, 2026.
5. Broekhuizen LN, Wijsman JH, Peterse JL, Rutgers EJT. The incidence and significance of micrometastases in lymph nodes of patients with ductal carcinoma in situ and T1a carcinoma of the breast. *Eur J Surg Oncol*. 2006; 32:502-506.

6. Lara JF, Young SM, Velilla RE, Santoro EJ, Templeton SF. The relevance of occult axillary micrometastasis in DCIS: a clinicopathologic study with long-term follow-up. *Cancer*. 2003; 98:2105-2113.
7. Carter BA, Jensen RA, Simpson JF, Page DL. Benign transport of breast epithelium into axillary lymph nodes after biopsy. *Am J Clin Pathol*. 2000; 113:259-265.
8. Bleiweiss IJ, Nagi CS, Jaffer S. Axillary sentinel lymph nodes can be falsely positive due to iatrogenic displacement and transport of benign epithelial cells in patients with breast carcinoma. *J Clin Oncol*. 2006; 24:2013-2018.
9. Amin MB, Edge SB, Greene FL, et al, eds. *AJCC Cancer Staging Manual*. 8th ed. New York, NY: Springer; 2017.
10. Connolly JL. Changes and problematic areas in interpretation of the AJCC Cancer Staging Manual, 6th Edition, for breast cancer. *Arch Pathol Lab Med*. 2006; 130:287-291.
11. Singletary SE, Connolly JL. Breast cancer staging: working with the sixth edition of the AJCC Cancer Staging Manual. *CA Cancer J Clin*. 2006; 56:37-47.
12. Singletary SE, Greene FL, Sobin LH. Classification of isolated tumor cells: clarification of the 6th edition of the American Joint Committee on Cancer Staging Manual. *Cancer*. 2003; 90:2740-2741.

L. pTNM Classification

The tumor-node-metastasis (TNM) staging system maintained collaboratively by the American Joint Committee on Cancer (AJCC) and the International Union Against Cancer (UICC) is recommended.[1,2,3,4,5](#)

Pathologic Classification

The pathologic classification of a cancer is based on information acquired before treatment supplemented and modified by the additional evidence acquired during and from surgery, particularly from pathologic examination of resected tissues. The pathologic classification provides additional precise and objective data. Reporting of T, N, and M categories by pathologic means is denoted by use of a lower case “p” prefix (pT, pN, pM).

Pathologic T. DCIS is classified as pTis (DCIS) or pTis (Paget).

Pathologic N. At least one node with presence or absence of cancer documented by pathologic examination is required for determining the pathologic N category. A tumor nodule in a regional node area is classified as a positive node. The size of the metastasis, not the size of the node, is used for the criterion for the N category.

Specialized pathologic techniques such as immunohistochemistry or molecular techniques may identify limited metastases in lymph nodes that may not have been identified without the use of the special diagnostic techniques. Single tumor cells or small clusters of cells are classified as isolated tumor cells (ITCs). The standard definition for ITC is a cluster of cells not more than 0.2 mm in greatest diameter. Cases with ITC only in lymph nodes are classified as pN0. This rule also generally applies to cases with findings of tumor cells or their components by nonmorphologic techniques such as flow cytometry or DNA analysis.

Pathologic M. The pathologic assignment of the presence of metastases (pM1) requires a biopsy positive for cancer at the metastatic site. Pathologic M0 is an undefined concept and the category pM0 may not

be used. Pathologic classification of the absence of distant metastases can only be made at autopsy. It would be extremely rare to have distant metastasis in examples of DCIS and would surely indicate an unsampled area of invasive carcinoma.

Posttherapy or Postneoadjuvant Therapy Classification (yTNM). Cases where systemic and/or radiation therapy are given before surgery (*neoadjuvant*) or where no surgery is performed may have the extent of disease assessed at the conclusion of the therapy by clinical or pathologic means (if resection performed). This classification is useful to clinicians because the extent of response to therapy may provide important prognostic information to patients and help direct the extent of surgery or subsequent systemic and/or radiation therapy. T and N are classified by using the same categories as for clinical or pathologic staging for the disease type, and the findings are recorded by using the prefix designator y (e.g., ycT; ycN; ypT; ypN). The yc prefix is used for the clinical stage after therapy, and the yp prefix is used for the pathologic stage for those cases that have surgical resection after neoadjuvant therapy. The M component should be classified by the M status defined clinically or pathologically prior to therapy.

Retreatment Classification. The retreatment classification (rTNM) is assigned when further treatment is planned for a cancer that recurs after a disease-free interval. The original stage assigned at the time of initial diagnosis and treatment does not change when the cancer recurs or progresses. The use of this staging for retreatment or recurrence is denoted with the r prefix (rTNM). All information available at the time of retreatment should be used in determining the rTNM stage. Biopsy confirmation of recurrent cancer is important if clinically feasible. However, this may not be appropriate for each component, so clinical evidence for the T, N, or M component by clinical, endoscopic, radiologic, or related methods may be used.

Multiple tumors. If there are multiple simultaneous areas of DCIS in the breast, Tis remains the appropriate choice. For simultaneous bilateral examples of DCIS, each DCIS is classified separately as independent tumors in different organs.

Metachronous primaries. Second or subsequent primary examples of DCIS occurring in the same organ or in different organs are staged as a new DCIS with the TNM system. Second DCIS examples are not staged using the y prefix unless the treatment of the second cancer warrants this use.

References

1. Amin MB, Edge SB, Greene FL, et al, eds. *AJCC Cancer Staging Manual*. 8th ed. New York, NY: Springer; 2017.
2. Connolly JL. Changes and problematic areas in interpretation of the AJCC Cancer Staging Manual, 6th Edition, for breast cancer. *Arch Pathol Lab Med*. 2006; 130:287-291.
3. Singletary SE, Connolly JL. Breast cancer staging: working with the sixth edition of the AJCC Cancer Staging Manual. *CA Cancer J Clin*. 2006; 56:37-47.
4. Singletary SE, Greene FL, Sobin LH. Classification of isolated tumor cells: clarification of the 6th edition of the American Joint Committee on Cancer Staging Manual. *Cancer*. 2003; 90:2740-2741
5. Brierley JD, Gospodarowicz MK, Wittekind CH, et al, eds. *TNM Classification of Malignant Tumours*. 8th ed. Oxford UK: Wiley; 2016.