



Protocol for the Examination of Resection Specimens from Patients with Invasive Carcinoma of the Breast

Version: 4.9.0.1

Protocol Posting Date: December 2023

CAP Laboratory Accreditation Program Protocol Required Use Date: March 2024

The changes included in this current protocol version do not affect the prior accreditation date.

For accreditation purposes, this protocol should be used for the following procedures AND tumor types:

Procedure	Description
Excision less than total mastectomy	Includes specimens designated excision, segmental resection, lumpectomy, quadrantectomy, and segmental or partial mastectomy, with or without axillary contents
Total Mastectomy	Includes skin-sparing and nipple-sparing mastectomy, with or without axillary contents
Tumor Type	Description
Invasive breast carcinoma of any type, with or without ductal carcinoma in situ (DCIS)	Includes invasive and microinvasive carcinomas

This protocol is NOT required for accreditation purposes for the following:

Procedure
Needle or skin biopsies
Primary resection specimen with no residual cancer (e.g., following neoadjuvant therapy)
Additional excision performed after the definitive resection (e.g., re-excision of surgical margins)
Cytologic specimens

The following tumor types should NOT be reported using this protocol:

Tumor Type
Ductal carcinoma in situ without invasive carcinoma (consider the Breast DCIS Resection protocol)
Paget disease of the nipple without invasive carcinoma (consider the Breast DCIS Resection protocol)
Encapsulated or solid papillary carcinoma without invasion (consider the Breast DCIS Resection protocol)
Phyllodes tumor (consider the Phyllodes tumor protocol)
Lymphoma (consider the Hodgkin or non-Hodgkin Lymphoma protocols)
Sarcoma (consider the Soft Tissue protocol)

Authors

Uma G. Krishnamurti, MD, PhD*; Patrick L. Fitzgibbons, MD, FCAP*; James L. Connolly, MD*.
With guidance from the CAP Cancer and CAP Pathology Electronic Reporting Committees.

* Denotes primary author.

Accreditation Requirements

This protocol can be utilized for a variety of procedures and tumor types for clinical care purposes. For accreditation purposes, only the definitive primary cancer resection specimen is required to have the core and conditional data elements reported in a synoptic format.

- Core data elements are required in reports to adequately describe appropriate malignancies. For accreditation purposes, essential data elements must be reported in all instances, even if the response is “not applicable” or “cannot be determined.”
- Conditional data elements are only required to be reported if applicable as delineated in the protocol. For instance, the total number of lymph nodes examined must be reported, but only if nodes are present in the specimen.
- Optional data elements are identified with “+” and although not required for CAP accreditation purposes, may be considered for reporting as determined by local practice standards.

The use of this protocol is not required for recurrent tumors or for metastatic tumors that are resected at a different time than the primary tumor. Use of this protocol is also not required for pathology reviews performed at a second institution (i.e., secondary consultation, second opinion, or review of outside case at second institution).

Synoptic Reporting

All core and conditionally required data elements outlined on the surgical case summary from this cancer protocol must be displayed in synoptic report format. Synoptic format is defined as:

- Data element: followed by its answer (response), outline format without the paired Data element: Response format is NOT considered synoptic.
- The data element should be represented in the report as it is listed in the case summary. The response for any data element may be modified from those listed in the case summary, including “Cannot be determined” if appropriate.
- Each diagnostic parameter pair (Data element: Response) is listed on a separate line or in a tabular format to achieve visual separation. The following exceptions are allowed to be listed on one line:
 - Anatomic site or specimen, laterality, and procedure
 - Pathologic Stage Classification (pTNM) elements
 - Negative margins, as long as all negative margins are specifically enumerated where applicable
- The synoptic portion of the report can appear in the diagnosis section of the pathology report, at the end of the report or in a separate section, but all Data element: Responses must be listed together in one location

Organizations and pathologists may choose to list the required elements in any order, use additional methods in order to enhance or achieve visual separation, or add optional items within the synoptic report. The report may have required elements in a summary format elsewhere in the report IN ADDITION TO but not as replacement for the synoptic report ie, all required elements must be in the synoptic portion of the report in the format defined above.

Summary of Changes

v 4.9.0.1

- Residual Cancer Burden (RCB) answer changed from “Not applicable (not reported)” to “Not reported”
- HER2 (by immunohistochemistry)/Ki-67 metadata only update

RETIRED

Reporting Template

Protocol Posting Date: December 2023

Select a single response unless otherwise indicated.

CASE SUMMARY: (INVASIVE CARCINOMA OF THE BREAST: Resection)

Standard(s): AJCC-UICC 8

If there are multiple invasive carcinomas, size, grade, histologic type, and the results of studies for estrogen receptor (ER), progesterone receptor (PR), and HER2 should pertain to the largest invasive carcinoma. If smaller invasive carcinomas differ in any of these features, this information may be included in the "Comments" section.

SPECIMEN

Procedure (Note A)

- Excision (less than total mastectomy)
 Total mastectomy (including nipple-sparing and skin-sparing mastectomy)
 Other (specify): _____
 Not specified

Specimen Laterality

- Right
 Left
 Not specified

TUMOR

+Tumor Site (Note B) (select all that apply)

- Upper outer quadrant
 Lower outer quadrant
 Upper inner quadrant
 Lower inner quadrant
 Central
 Nipple
 Clock position

Specify Clock Position (select all that apply)

- 1 o'clock
 2 o'clock
 3 o'clock
 4 o'clock
 5 o'clock
 6 o'clock
 7 o'clock
 8 o'clock
 9 o'clock
 10 o'clock
 11 o'clock
 12 o'clock
 Specify distance from nipple in Centimeters (cm): _____ cm
 Other (specify): _____

___ Not specified

Histologic Type (Note C)

Determination of histologic type is based on routine histologic examination; special stains such as e-cadherin are not required for determining histologic type. The histologic type corresponds to the largest carcinoma. If there are smaller carcinomas of a different type, this information should be included under "Additional Findings."

Special type carcinomas should consist of at least 90% pure pattern.

- ___ No residual invasive carcinoma
- ___ Invasive carcinoma of no special type (ductal)
- ___ Micro-invasive carcinoma
- ___ Invasive lobular carcinoma
- ___ Invasive carcinoma with mixed ductal and lobular features
- ___ Invasive carcinoma with features of (specify): _____
- ___ Tubular carcinoma
- ___ Invasive cribriform carcinoma
- ___ Mucinous carcinoma
- ___ Invasive micropapillary carcinoma
- ___ Apocrine adenocarcinoma
- ___ Metaplastic carcinoma
- ___ Encapsulated papillary carcinoma with invasion
- ___ Solid papillary carcinoma with invasion
- ___ Intraductal papillary adenocarcinoma with invasion
- ___ Adenoid cystic carcinoma
- ___ Neuroendocrine tumor
- ___ Neuroendocrine carcinoma
- ___ Invasive carcinoma, type cannot be determined: _____
- ___ Other histologic type not listed (specify): _____

+Histologic Type Comment: _____

Histologic Grade (Nottingham Histologic Score) (required only if applicable) (Note D)

The grade corresponds to the largest area of invasion. If there are smaller foci of invasion of a different grade, this information should be included under "Additional Findings."

- ___ Not applicable (no residual carcinoma or microinvasion only)
- ___ Nottingham Score

Glandular (Acinar) / Tubular Differentiation

- ___ Score 1 (greater than 75% of tumor area forming glandular / tubular structures)
- ___ Score 2 (10 to 75% of tumor area forming glandular / tubular structures)
- ___ Score 3 (less than 10% of tumor area forming glandular / tubular structures)
- ___ Only microinvasion present (not graded)
- ___ Score cannot be determined: _____

Nuclear Pleomorphism

- ___ Score 1 (Nuclei small with little increase in size in comparison with normal breast epithelial cells, regular outlines, uniform nuclear chromatin, little variation in size)
- ___ Score 2 (Cells larger than normal with open vesicular nuclei, visible nucleoli, and moderate variability in both size and shape)
- ___ Score 3 (Vesicular nuclei, often with prominent nucleoli, exhibiting marked variation in size and shape, occasionally with very large and bizarre forms)
- ___ Only microinvasion present (not graded)

___ Score cannot be determined: _____

Mitotic Rate

See Table 1 in Note D

___ Score 1

___ Score 2

___ Score 3

___ Only microinvasion present (not graded)

___ Score cannot be determined: _____

Overall Grade

___ Grade 1 (scores of 3, 4 or 5)

___ Grade 2 (scores of 6 or 7)

___ Grade 3 (scores of 8 or 9)

___ Only microinvasion present (not graded)

___ Score cannot be determined (explain): _____

Tumor Size (Note E)

The size of the invasive carcinoma should take into consideration the gross findings correlated with the microscopic examination. If multiple foci of invasion are present, the size listed is the size of the largest contiguous area of invasion. The size of multiple invasive carcinomas should not be added together. The size does not include adjacent ductal carcinoma in situ (DCIS). For any carcinoma larger than 1.0 mm but less than 1.5 mm, the size should not be rounded down to 1.0 mm, but rather rounded up to 2.0 mm, to ensure that the tumor is not miscategorized as pT1mi. Exception to the size rule-if two histologically similar carcinomas are within 5.0 mm of each other, measure from outer edges of the two. For staging purposes radiologic findings can be used for pT category.

If there has been a prior core needle biopsy or incisional biopsy showing a larger area of invasion than in the excisional specimen, the largest dimension of the invasive carcinoma in the prior specimen, if known, should be used for determining the T category. This also applies if the entire tumor has been removed by prior biopsy. The size of the largest foci in the two specimens should not be added together.

If there has been prior neoadjuvant treatment and no invasive carcinoma is present, the cancer is classified as ypTis if there is residual DCIS and ypT0 if there is no remaining carcinoma. A checklist is not required if no cancer is present in the specimen.

___ No residual invasive carcinoma

___ Microinvasion only (less than or equal to 1 mm)

___ Greatest dimension of largest invasive focus greater than 1 mm (specify exact measurement in Millimeters (mm)): _____ mm

+Additional Dimension in Millimeters (mm): ___ x ___ mm

___ Size of largest invasive focus cannot be determined (explain): _____

+Tumor Focality (Note E)

If there are multiple invasive carcinomas, size, grade, histologic type, and the results of studies for estrogen receptor (ER), progesterone receptor (PgR), and HER2 should pertain to the largest invasive carcinoma. If smaller invasive carcinomas differ in any of these features, this information may be included in the "Comments" section.

___ Single focus of invasive carcinoma

___ Multiple foci of invasive carcinoma

+Number of Foci

___ Specify number: _____

___ At least: _____

___ Cannot be determined

+Sizes of Individual Foci in Millimeters (mm) (values may be recorded on a single line using units (mm) and semicolons (;) as separators): _____

___ Cannot be determined: _____

Ductal Carcinoma In Situ (DCIS) (Note G)

Not identified

Present

If there has been prior neoadjuvant treatment and only residual DCIS, the cancer is classified as ypTis.

Negative for extensive intraductal component (EIC)

Positive for extensive intraductal component (EIC)

Only DCIS is present after presurgical (neoadjuvant) therapy

+Size (Extent) of DCIS

The size (extent) of DCIS (greatest dimension using gross and microscopic evaluation) is an estimation of the volume of breast tissue occupied by DCIS. This information may be helpful for cases with a predominant component of DCIS (e.g., DCIS with microinvasion) but may not be necessary for cases of EIC negative invasive carcinomas.

Estimated size (extent) of DCIS is at least in Millimeters (mm): _____ mm

+Additional Dimension in Millimeters (mm): ____ x ____ mm

Cannot be determined: _____

+Architectural Patterns (if DCIS is present in specimen select all that apply) (select all that apply)

Comedo

Paget disease (DCIS involving nipple skin)

Cribriform

Micropapillary

Papillary

Solid

Other (specify): _____

+Nuclear Grade (if DCIS is present in specimen, see Table 2 in CAP Protocol)

Grade I (low)

Grade II (intermediate)

Grade III (high)

+Necrosis (If DCIS is present in specimen)

Not identified

Present, focal (small foci or single cell necrosis)

Present, central (expansive "comedo" necrosis)

+Number of Blocks with DCIS: _____

+Number of Blocks Examined: _____

Cannot be excluded: _____

+Lobular Carcinoma In Situ (LCIS)

Not identified

Present

Tumor Extent (Note H)

Tumor Extent (required only if skin, nipple, or skeletal muscle are present and involved) (select all that apply)

Not applicable (skin, nipple, and skeletal muscle are absent OR are uninvolved)

Skin is present and involved

Skin Invasion

- Carcinoma directly invades into the dermis or epidermis without skin ulceration (this does not change the T classification)
- Carcinoma directly invades into the dermis or epidermis with skin ulceration (classified as T4b)
- Carcinoma does not directly invade into the dermis or epidermis (this does not change the T classification)

Skin Satellite Foci

Satellite skin nodules must be separate from the primary tumor and macroscopically identified to assign a category as T4b. Skin nodules identified only on microscopic examination and in the absence of epidermal ulceration or skin edema (clinical peau d'orange) do not qualify as T4b. Such tumors should be categorized based on tumor size.

- Satellite foci not identified
- Satellite skin foci of invasive carcinoma are present (i.e., not contiguous with the invasive carcinoma in the breast) (classified as T4b)

This finding does not change the T classification of invasive carcinomas.

- DCIS involves nipple epidermis (Paget disease of the nipple)#
- Skeletal muscle is present and involved

Skeletal Muscle

Invasion into pectoralis muscle is not considered chest wall invasion, and cancers are not classified as T4a unless there is invasion deeper than this muscle.

- Carcinoma invades skeletal muscle
- Carcinoma invades into skeletal muscle and into the chest wall (classified as T4a)

Lymphatic and / or Vascular Invasion (Note I)

- Not identified
- Present
 - + Focal (LVI in one block only)
 - + Extensive (LVI in two or more blocks)
- Cannot be determined: _____

+Dermal Lymphatic and / or Vascular Invasion

- No skin present
- Not identified
- Present
- Cannot be determined: _____

+Microcalcifications (Note J) (select all that apply)

- Not identified
- Present in DCIS
- Present in invasive carcinoma
- Present in non-neoplastic tissue
- Other (specify): _____

Treatment Effect in the Breast (Note K)

The largest contiguous focus of residual tumor, if present, is used to determine ypT category. Treatment-related fibrosis in the tumor bed adjacent to foci of residual invasive carcinoma is not included in determining ypT dimension.

- No known presurgical therapy
- No definite response to presurgical therapy in the invasive carcinoma
- Probable or definite response to presurgical therapy in the invasive carcinoma
- No residual invasive carcinoma is present in the breast after presurgical therapy

RETIRED

Treatment Effect in the Lymph Nodes (required if nodes are submitted and it is known that the patient had presurgical therapy)

The largest contiguous focus of residual tumor in the lymph nodes, if present, is used to determine ypN category. Treatment-related fibrosis adjacent to residual nodal deposits is not included in determining ypN dimension.

- Not applicable
- No definite response to presurgical therapy in metastatic carcinoma
- Probable or definite response to presurgical therapy in metastatic carcinoma
- No lymph node metastases. Fibrous scarring or histiocytic aggregates, possibly related to prior lymph node metastases with pathologic complete response
- No lymph node metastases and no fibrous scarring or histiocytic aggregates in the nodes

Residual Cancer Burden (RCB) Calculation (for institutions that wish to report treatment effect using the RCB calculator)# (Note [K](#))

The RCB calculator can be found at the MD Anderson website:
<http://www3.mdanderson.org/app/medcalc/index.cfm?pagename=jsconvert3>

- Not reported
- RCB reported

Primary Tumor Bed

Greatest Dimension of Primary Tumor Bed Area in Millimeters (mm) (involved by residual viable carcinoma): _____ mm

Second Greatest Dimension of Primary Tumor Bed Area in Millimeters (mm):
_____ mm

Specify Percentage of Overall Cancer Cellularity (in the area measured above):
_____ %

Specify Percentage of Cancer that is in situ Disease: _____ %

Lymph Nodes

Number of Positive Lymph Nodes: _____

Diameter of Largest Nodal Metastasis in Millimeters (mm): _____ mm

RCB Calculations

Residual Cancer Burden: _____

Residual Cancer Burden Class

- RCB-0 (pCR)
- RCB-I
- RCB-II
- RCB-III

MARGINS (Note [L](#))

Margin Status for Invasive Carcinoma (required only if residual invasive carcinoma is present in specimen)

- Not applicable (residual invasive carcinoma in specimen is absent)
- All margins negative for invasive carcinoma

Distance from Invasive Carcinoma to Closest Margin

Specify in Millimeters (mm)

- Exact distance: _____ mm
- Less than: _____ mm
- Greater than: _____ mm
- Other (specify): _____

___ Cannot be determined (explain): _____

+Closest Margin(s) to Invasive Carcinoma (select all that apply)

___ Anterior

___ Posterior

___ Superior

___ Inferior

___ Medial

___ Lateral

___ Other (specify): _____

___ Cannot be determined (explain): _____

___ Invasive carcinoma present at margin

Margin status is listed as "positive" if there is ink on invasive carcinoma (i.e., the distance is 0 mm). Extent of margin involvement may be specified as unifocal, multifocal, or extensive.

Margin(s) Involved by Invasive Carcinoma (select all that apply)

___ Anterior (specify extent): _____

___ Posterior (specify extent): _____

___ Superior (specify extent): _____

___ Inferior (specify extent): _____

___ Medial (specify extent): _____

___ Lateral (specify extent): _____

___ Other (specify margin(s) and extent): _____

___ Cannot be determined (explain): _____

___ Other (specify): _____

___ Cannot be determined (explain): _____

+Distance from Invasive Carcinoma to Anterior Margin

Specify in Millimeters (mm)

___ Exact distance: _____ mm

___ Less than: _____ mm

___ Greater than: _____ mm

___ Other (specify): _____

___ Cannot be determined (explain): _____

+Distance from Invasive Carcinoma to Posterior Margin

Specify in Millimeters (mm)

___ Exact distance: _____ mm

___ Less than: _____ mm

___ Greater than: _____ mm

___ Other (specify): _____

___ Cannot be determined (explain): _____

+Distance from Invasive Carcinoma to Superior Margin

Specify in Millimeters (mm)

___ Exact distance: _____ mm

___ Less than: _____ mm

___ Greater than: _____ mm

___ Other (specify): _____

___ Cannot be determined (explain): _____

+Distance from Invasive Carcinoma to Inferior Margin

Specify in Millimeters (mm)

___ Exact distance: _____ mm

Less than: _____ mm
 Greater than: _____ mm
 Other (specify): _____
 Cannot be determined (explain): _____

+Distance from Invasive Carcinoma to Medial Margin

Specify in Millimeters (mm)

Exact distance: _____ mm
 Less than: _____ mm
 Greater than: _____ mm
 Other (specify): _____
 Cannot be determined (explain): _____

+Distance from Invasive Carcinoma to Lateral Margin

Specify in Millimeters (mm)

Exact distance: _____ mm
 Less than: _____ mm
 Greater than: _____ mm
 Other (specify): _____
 Cannot be determined (explain): _____

+Distance from Invasive Carcinoma to Other Margin(s)

Specify in Millimeters (mm)

Other margin(s) and distance(s) (specify): _____
 Cannot be determined (explain): _____

Margin Status for DCIS (required only if DCIS is present in specimen)

For specimens in which the margin is uninvolved (no ink on carcinoma), the closest margin(s) must be specified if the distance of DCIS from the margin is less than 2 mm. Distances can be specific measurements or expressed as greater than or less than a measurement.

Not applicable (no DCIS in specimen)
 All margins negative for DCIS

Distance from DCIS to Closest Margin

Specify in Millimeters (mm)

Exact distance: _____ mm
 Less than: _____ mm
 Greater than: _____ mm
 Other (specify): _____
 Cannot be determined (explain): _____

Closest Margin(s) to DCIS (required only if less than 2mm) (select all that apply)

Not applicable
 Anterior
 Posterior
 Superior
 Inferior
 Medial
 Lateral
 Other (specify): _____
 Cannot be determined (explain): _____

DCIS present at margin

Margin status is listed as "positive" if there is ink on DCIS (i.e., the distance is 0 mm). Extent of margin involvement may be specified as unifocal, multifocal, or extensive.

Margin(s) Involved by DCIS (select all that apply)

- Anterior (specify extent, if possible): _____
- Posterior (specify extent, if possible): _____
- Superior (specify extent, if possible): _____
- Inferior (specify extent, if possible): _____
- Medial (specify extent, if possible): _____
- Lateral (specify extent, if possible): _____
- Other (specify margin(s) and, if possible, extent): _____
- Cannot be determined (explain): _____
- Other (specify): _____
- Cannot be determined (explain): _____

+Distance from DCIS to Anterior Margin

Specify in Millimeters (mm)

- Exact distance: _____ mm
- Less than: _____ mm
- Greater than: _____ mm
- Other (specify): _____
- Cannot be determined (explain): _____

+Distance from DCIS to Posterior Margin

Specify in Millimeters (mm)

- Exact distance: _____ mm
- Less than: _____ mm
- Greater than: _____ mm
- Other (specify): _____
- Cannot be determined (explain): _____

+Distance from DCIS to Superior Margin

Specify in Millimeters (mm)

- Exact distance: _____ mm
- Less than: _____ mm
- Greater than: _____ mm
- Other (specify): _____
- Cannot be determined (explain): _____

+Distance from DCIS to Inferior Margin

Specify in Millimeters (mm)

- Exact distance: _____ mm
- Less than: _____ mm
- Greater than: _____ mm
- Other (specify): _____
- Cannot be determined (explain): _____

+Distance from DCIS to Medial Margin

Specify in Millimeters (mm)

- Exact distance: _____ mm
- Less than: _____ mm
- Greater than: _____ mm
- Other (specify): _____
- Cannot be determined (explain): _____

+Distance from DCIS to Lateral Margin

Specify in Millimeters (mm)

Exact distance: _____ mm

Less than: _____ mm

Greater than: _____ mm

Other (specify): _____

Cannot be determined (explain): _____

+Distance from DCIS to Other Margin(s)

Specify in Millimeters (mm)

Other margin(s) and distance(s) (specify): _____

Cannot be determined (explain): _____

+Margin Comment: _____

REGIONAL LYMPH NODES (Note [M](#))

Regional Lymph Node Status

Not applicable (no regional lymph nodes submitted or found)

Regional lymph nodes present

All regional lymph nodes negative for tumor

Tumor present in regional lymph node(s)

Number of Lymph Nodes with Macrometastases (greater than 2 mm)

Exact number (specify): _____

At least (specify): _____

Other (specify): _____

Cannot be determined (explain): _____

Number of Lymph Nodes with Micrometastases (greater than 0.2 mm to 2 mm and / or greater than 200 cells)

Exact number (specify): _____

At least (specify): _____

Other (specify): _____

Cannot be determined (explain): _____

Number of Lymph Nodes with Isolated Tumor Cells (0.2 mm or less OR 200 cells or less) (required only if applicable)#

Reporting the number of lymph nodes with isolated tumor cells is required only in the absence of macrometastasis or micrometastasis in other lymph nodes.

Not applicable

Exact number (specify): _____

At least (specify): _____

Other (specify): _____

Cannot be determined (explain): _____

Size of Largest Nodal Metastatic Deposit

Specify in Millimeters (mm)

Exact size: _____ mm

Less than: _____ mm

Greater than: _____ mm

Other (specify): _____

Cannot be determined (explain): _____

Extranodal Extension

- Not identified
- Present, 2 mm or less
- Present, greater than 2 mm
- +Specify Amount:** _____
- Present
- Cannot be determined: _____
- Other (specify): _____
- Cannot be determined (explain): _____

Total Number of Lymph Nodes Examined (sentinel and non-sentinel)

- Exact number (specify): _____
- At least (specify): _____
- Other (specify): _____
- Cannot be determined (explain): _____

Number of Sentinel Nodes Examined (if applicable)

- Not applicable
- Exact number (specify): _____
- At least (specify): _____
- Other (specify): _____
- Cannot be determined (explain): _____

+Regional Lymph Node Comment: _____

DISTANT METASTASIS

Distant Site(s) Involved, if applicable (select all that apply)

- Not applicable
- Non-regional lymph node(s) (specify, if possible): _____
- Lung: _____
- Liver: _____
- Bone: _____
- Brain: _____
- Other (specify): _____
- Cannot be determined: _____

pTNM CLASSIFICATION (AJCC 8th Edition) (Note [N](#))

Reporting of pT, pN, and (when applicable) pM categories is based on information available to the pathologist at the time the report is issued. As per the AJCC (Chapter 1, 8th Ed.) it is the managing physician's responsibility to establish the final pathologic stage based upon all pertinent information, including but potentially not limited to this pathology report.

Modified Classification (required only if applicable) (select all that apply)

- Not applicable
- y (post-neoadjuvant therapy)
- r (recurrence)

pT Category

For the purposes of this checklist, these categories should only be used in the setting of preoperative (neoadjuvant) therapy for which a previously diagnosed invasive carcinoma is no longer present after treatment. Patients with pathological complete response

(absence of residual invasive carcinoma in both the breast and lymph nodes) should be categorized as ypT0N0 or ypTisN0, not ypTX.

___ pT not assigned (cannot be determined based on available pathological information)

___ pT0: No evidence of primary tumor#

___ pTis (DCIS): Ductal carcinoma in situ#

Carcinomas in the breast parenchyma associated with Paget disease are categorized based on the size and characteristics of the parenchymal disease, although the presence of Paget disease should still be noted.

___ pTis (Paget): Paget disease of the nipple NOT associated with invasive carcinoma and / or carcinoma in situ (DCIS) in the underlying breast parenchyma##

pT1: Tumor less than or equal to 20 mm in greatest dimension

___ pT1mi: Tumor less than or equal to 1 mm in greatest dimension

Round any measurement greater than 1.0-1.9 mm to 2 mm

___ pT1a: Tumor greater than 1 mm but less than or equal to 5 mm in greatest dimension###

___ pT1b: Tumor greater than 5 mm but less than or equal to 10 mm in greatest dimension

___ pT1c: Tumor greater than 10 mm but less than or equal to 20 mm in greatest dimension

___ pT1 (subcategory cannot be determined)

___ pT2: Tumor greater than 20 mm but less than or equal to 50 mm in greatest dimension

___ pT3: Tumor greater than 50 mm in greatest dimension

Invasion of the dermis alone does not qualify as pT4.

pT4: Tumor of any size with direct extension to the chest wall and / or to the skin (ulceration or skin nodules)####

___ pT4a: Extension to the chest wall; invasion or adherence to pectoralis muscle in the absence of invasion of chest wall structures does not qualify as T4

___ pT4b: Ulceration and / or ipsilateral satellite nodules and / or edema (including peau d'orange) of the skin which do not meet the criteria for inflammatory carcinoma

___ pT4c: Both T4a and T4b are present

Inflammatory carcinoma requires the presence of clinical findings of erythema and edema involving at least one-third or more of the skin of the breast. (Note [M](#))

___ pT4d: Inflammatory carcinoma#####

___ pT4 (subcategory cannot be determined)

T Suffix (required only if applicable)

___ Not applicable

___ (m) multiple primary synchronous tumors in a single organ

pN Category

Choose a category based on lymph nodes received with the specimen; immunohistochemistry and / or molecular studies are not required.

If internal mammary lymph nodes, infraclavicular nodes, or supraclavicular lymph nodes are included in the specimen, consult the AJCC Cancer Staging Manual for additional lymph node categories.

___ pN not assigned (no nodes submitted or found)

___ pN not assigned (cannot be determined based on available pathological information)

Isolated tumor cells (ITCs) are defined as small clusters of cells not greater than 0.2 mm or single tumor cells, or a cluster of fewer than 200 cells in a single histologic cross-section. ITCs may be detected by routine histology or by immunohistochemical (IHC) methods. Nodes containing only ITCs are excluded from the total positive node count when determining the N category but should be included in the total number of nodes evaluated.

___ pN0: No regional lymph node metastasis identified or ITCs only#

___ pN0 (i+): ITCs only (malignant cell clusters no larger than 0.2 mm) in regional lymph node(s)

___ pN0 (mol+): Positive molecular findings by reverse transcriptase polymerase chain reaction (RT-PCR); no ITCs detected

___ pN1mi: Micrometastases (approximately 200 cells, larger than 0.2 mm, but none larger than 2.0 mm)

Approximately 1000 tumor cells are contained in a 3-dimensional 0.2-mm cluster. Thus, if more than 200 individual tumor cells are identified as single dispersed tumor cells or as a nearly confluent elliptical or spherical focus in a single histologic section of a lymph node, there is a high probability that more than 1000 cells are present in the lymph node. In these situations, the node should be classified as containing a micrometastasis (pN1mi). Cells in different lymph node cross-sections or longitudinal sections or levels of the block are not added together; the 200 cells must be in a single node profile even if the node has been thinly sectioned into multiple slices. It is recognized that there is substantial overlap between the upper limit of the ITC and the lower limit of the micrometastasis categories due to inherent limitations in pathologic nodal evaluation and detection of minimal tumor burden in lymph nodes. Thus, the threshold of 200 cells in a single cross-section is a guideline to help pathologists distinguish between these 2 categories. The pathologist should use judgment regarding whether it is likely that the cluster of cells represents a true micrometastasis or is simply a small group of isolated tumor cells.

- pN1a: Metastases in 1-3 axillary lymph nodes, at least one metastasis larger than 2.0 mm##
- pN1b: Metastases in ipsilateral internal mammary sentinel nodes, excluding ITCs
- pN1c: pN1a and pN1b combined
- pN2a: Metastases in 4-9 axillary lymph nodes (at least one tumor deposit larger than 2.0 mm)##
- pN2b: Metastases in clinically detected internal mammary lymph nodes with or without microscopic confirmation; with pathologically negative axillary nodes
- pN3a: Metastases in 10 or more axillary lymph nodes (at least one tumor deposit larger than 2.0 mm)##; or metastases to the infraclavicular (Level III axillary lymph) nodes
- pN3b: pN1a or pN2a in the presence of cN2b (positive internal mammary nodes by imaging); or pN2a in the presence of pN1b
- pN3c: Metastases in ipsilateral supraclavicular lymph nodes

N Suffix (required only if applicable) (select all that apply)

The (sn) modifier is added to the N category when a sentinel node biopsy is performed (using either dye or tracer) and fewer than six lymph nodes are removed (sentinel and nonsentinel). The (f) modifier is added to the N category to denote confirmation of metastasis by fine needle aspiration / core needle biopsy with NO further resection of nodes.

- Not applicable
- (sn): Sentinel node(s) evaluated. If 6 or more nodes (sentinel or nonsentinel) are removed, this modifier should not be used
- (f): Nodal metastasis confirmed by fine needle aspiration or core needle biopsy

pM Category (required only if confirmed pathologically)

- Not applicable - pM cannot be determined from the submitted specimen(s)
 - pM1: Histologically proven metastases larger than 0.2 mm
- +Specify Case Number (if from a previous procedure):** _____

ADDITIONAL FINDINGS (Note [O](#))

+Additional Findings (specify): _____

SPECIAL STUDIES

The CAP Breast Biomarker Template should be used for reporting biomarkers requested for this resection specimen. Pending biomarker studies should be listed in the Comments section of this report.

+Breast Biomarker Testing Performed on Previous Biopsy (select all that apply)

The previously reported biopsy biomarker status may be included additionally in the resection report.

- Estrogen Receptor (ER)

Estrogen Receptor (ER) Status

- Positive (greater than 10% of cells demonstrate nuclear positivity)

+Percentage of Cells with Nuclear Positivity

Specify %: _____ %

--OR--

Select range below:

11-20%

21-30%

31-40%

41-50%

51-60%

61-70%

71-80%

81-90%

91-100%

Low Positive (1-10% of cells with nuclear positivity)

Negative

Cannot be determined (indeterminate)

Progesterone Receptor (PgR)

Progesterone Receptor (PgR) Status

Positive

+Percentage of Cells with Nuclear Positivity#

Specify %: _____ %

1-10% (specify)#: _____ %

11-20%

21-30%

31-40%

41-50%

51-60%

61-70%

71-80%

81-90%

91-100%

Negative

Cannot be determined (indeterminate)

HER2 (by immunohistochemistry)

HER2 (by immunohistochemistry)

Negative (Score 0)

Breast cancers with HER2 IHC score 1+ or HER2 IHC score 2+ and a negative ISH result are eligible for clinically appropriate HER2-targeted therapy and may be reported as "HER2 Low".

Negative (Score 1+)#

Equivocal (Score 2+)#

+Percentage of Cells with Uniform Intense Complete Membrane Staining

Specify percentage: _____ %

Other (specify): _____

Cannot be determined

Positive (Score 3+)

Percentage of Cells with Uniform Intense Complete Membrane Staining

Specify percentage: _____ %

Other (specify): _____

Cannot be determined

- Cannot be determined (indeterminate)
- HER2 (by in situ hybridization)
- HER2 (by in situ hybridization)**
- Negative (not amplified)
- Positive (amplified)
- Cannot be determined (indeterminate)
- Ki-67
- Ki-67 Percentage of Positive Nuclei: _____ %**
- +Testing Performed on Case Number: _____**

COMMENTS

Comment(s): _____

RETIRED

Explanatory Notes

A. Procedures

The following types of breast specimens and procedures may be reported with the case summary:

Excisions: These procedures resect breast tissue without the intent of removing the entire breast. The nipple is usually not included with excisions. Excisions include specimens designated “partial mastectomies,” “lumpectomies,” and “quadrantectomies.”

Total Mastectomy: Removal of all breast tissue, generally including the nipple and areola.

- **Simple mastectomy:** This procedure consists of a total mastectomy without removal of axillary lymph nodes.
- **Skin sparing mastectomy:** This is a total mastectomy with removal of the nipple and only a narrow surrounding rim of skin.
- **Nipple sparing mastectomy:** This is a total mastectomy without removal of skin or nipple. The subareolar tissue is examined and the nipple later removed if involved by carcinoma.
- **Modified radical mastectomy:** This procedure consists of a total mastectomy with an axillary dissection. In the case summary, the breast and lymph node specimens are documented separately. A small portion of pectoralis muscle is sometimes removed.
- **Radical mastectomy:** This procedure consists of a total mastectomy with removal of the pectoralis major and pectoralis minor muscles as well as axillary contents. This type of specimen and procedure can be indicated on the case summary as “Other.”

The case summary is intended for reporting the patient’s specimen with the largest focus of invasive carcinoma. If additional margin excisions are performed in the same procedure, the findings for these specimens can be included in the margin evaluation. If additional smaller foci of invasive carcinoma are present in the main excision or in margin excisions, the characteristics of these carcinomas (i.e., size, histologic type, and grade) should be recorded under “Additional Pathologic Findings.” Additional ancillary studies on smaller foci of carcinoma are recommended if the carcinomas are of different histologic type or grade. If additional margin excisions are performed in a subsequent procedure (e.g., on another day), and a larger area of invasive carcinoma is not present, the case summary need not be used.

If a patient has 2 ipsilateral invasive carcinomas removed in 2 separate excisions during the same procedure, the case summary should be used for the larger invasive carcinoma. The pathologic findings for the smaller cancer may be reported without using the case summary. If a patient has 2 ipsilateral invasive carcinomas removed in 2 separate excisions in procedures on different days, the case summary should be used for the larger carcinoma, and the American Joint Committee on Cancer (AJCC) T category will pertain to this carcinoma. If a patient has bilateral breast carcinomas, the cancers are reported in separate case summaries.

If information from other specimens is included in completing the case summary (e.g., the results of hormone receptors from a prior core needle biopsy or the finding of lymph node metastases on a previous lymph node biopsy), then this must be clearly stated in the “Comments” section, and the accession numbers of the other cases should be provided.

The following types of specimens should not be reported by using this protocol:

- Very small incisional biopsies (including core needle biopsies).

- Re-excision of a biopsy site after removal of most of the carcinoma.

Specimen sampling for specimens with invasive carcinoma has the following goals^{1,2,3,4,5}:

- The clinical or radiologic lesion for which the surgery was performed must be examined microscopically. If the lesion is a nonpalpable imaging finding, the specimen radiograph and/or additional radiologic studies may be necessary to identify the lesion. When practical, the entire lesion, or the entire area with the imaging finding, should be submitted in a sequential fashion for histologic examination.
- If the specimen consists predominantly of DCIS with microinvasion, complete submission of the entire specimen, or at a minimum the entire grossly involved area, is recommended to identify additional areas of invasion and/or lymphovascular invasion.
- All other gross lesions in the specimen must be sampled.
- Each designated margin must be evaluated for involvement by invasive carcinoma and DCIS. If the specimen is received sectioned or fragmented, this should be noted, as this will limit the ability to evaluate the status of margins.

Tissue may be taken for research studies or assays that do not involve the histologic examination of the tissue (e.g., reverse transcriptase polymerase chain reaction [RT-PCR]) only when taken in such a way as to not compromise the evaluation of the invasive carcinoma and lymph nodes for prognostic factors and margin status.

It is preferable that the area of carcinoma be removed in a single intact specimen. If the specimen has been incised or is fragmented, then it may not be possible to accurately assess margins. If invasive carcinoma is present in more than 1 fragment, it may be difficult or impossible to determine the pathologic size of the invasive carcinoma or the number of invasive carcinomas present. Breast imaging correlation is recommended for these cases and may be used for determining the pT. When specimen fragmentation limits the evaluation of tumor size and/or margins, this information should be included under “Additional Pathologic Finding.”

The size of all specimens in 3 dimensions should be documented in the gross description. It is optional to also include specimen sizes in the final diagnosis. The volume of tissue removed can be helpful in estimating the extent of carcinoma present and determining the likely volume of tissue that would need to be removed to achieve tumor-free margins.

If separate oriented margin specimens are excised, the results of the final margin status can be included under “Margins” in the case summary. If not oriented, the findings can be reported under “Additional Pathologic Findings.”

References

1. Association of Directors of Anatomic and Surgical Pathology. Immediate management of mammographically detected breast lesions. *Hum Pathol*. 1993;24:689-690.
2. Connolly JL, Schnitt SJ. Evaluation of breast biopsy specimens in patients considered for treatment by conservative surgery and radiation therapy for early breast cancer. *Pathol Annu*. 1988;23(pt 1):1-23.
3. Schnitt SJ, Wang HH. Histologic sampling of grossly benign breast biopsies: how much is enough? *Am J Surg Pathol*. 1989;13:505-512.

4. Schnitt SJ, Connolly JL. Processing and evaluation of breast excision specimens: a clinically oriented approach. *Am J Clin Pathol.* 1992;98:125-137.
5. Lester SC. *Manual of Surgical Pathology.* 3rd ed. New York, NY: Elsevier; 2010.

B. Tumor Site

The site of an invasive carcinoma is helpful to document, when provided by the surgeon, breast imaging, or previous pathology report, to correlate with prior studies (e.g., a core needle biopsy) or with future biopsies or cancer events. The site can be indicated by quadrant and/or by a clock position.

The approximate tumor site can be determined in a mastectomy. However, it is sometimes difficult to correlate exactly with the position as determined in vivo because of differences in how the specimen would be positioned on the chest wall (i.e., the skin ellipse may be horizontal or point to the axilla). It is helpful to locate the carcinoma with respect to the clinical site or imaging site, when possible.

If the patient has undergone presurgical (neoadjuvant) therapy and there is no residual invasive carcinoma, the tumor site refers to the location of the prior invasive carcinoma (ie, the tumor bed).

C. Histologic Type

This protocol applies to all invasive carcinomas of the breast. The World Health Organization (WHO)¹ classification of breast carcinoma is recommended, although the protocol does not preclude the use of other classifications or histologic types. Carcinomas may be classified based on the H&E appearance without the use of immunohistochemical studies.

A modified list is presented in the case summary based on the most frequent types of invasive carcinomas and terminology that is in widespread usage. The modified list is intended to capture the majority of tumors and reduce the frequency of tumors being reported as “other.” Choices are added for tumors with mixed features and those with some but not all features of specific histologic types.

WHO Classification of Invasive Carcinoma of the Breast¹

- No residual invasive carcinoma
- Invasive carcinoma of no special type (ductal)
- Micro-invasive carcinoma
- Invasive lobular carcinoma
- Invasive carcinoma with mixed ductal and lobular features
- Invasive carcinoma with mixed features (specify): _____
- Tubular carcinoma
- Invasive cribriform carcinoma
- Mucinous carcinoma
- Invasive micropapillary carcinoma
- Apocrine adenocarcinoma

Metaplastic Carcinoma

- Metaplastic carcinoma NOS
- Low grade adenosquamous carcinoma
- Fibromatosis-like metaplastic carcinoma
- Spindle cell carcinoma
- Squamous cell carcinoma

___ Metaplastic carcinoma with mesenchymal differentiation

Neuroendocrine Tumor

- ___ Neuroendocrine tumor NOS
- ___ Neuroendocrine tumor, grade 1
- ___ Neuroendocrine tumor, grade 2

Neuroendocrine Carcinoma

- ___ Neuroendocrine carcinoma NOS
- ___ Neuroendocrine carcinoma, small cell
- ___ Neuroendocrine carcinoma, large cell
- ___ Invasive carcinoma, type cannot be determined
- ___ Other histologic type (specify): _____
 - ___ Invasive papillary carcinoma
 - ___ Encapsulated papillary carcinoma with invasion
 - ___ Solid papillary carcinoma with invasion
 - ___ Intraductal papillary adenocarcinoma with invasion
 - ___ Oncocytic carcinoma
 - ___ Lipid-rich carcinoma
 - ___ Glycogen-rich carcinoma
 - ___ Sebaceous carcinoma
 - ___ Mucinous cystadenocarcinoma NOS
 - ___ Acinar cell carcinoma
 - ___ Classic adenoid cystic carcinoma
 - ___ Solid-basaloid adenoid cystic carcinoma
 - ___ Adenoid cystic carcinoma with high-grade transformation
 - ___ Secretory carcinoma
 - ___ Mucoepidermoid carcinoma
 - ___ Polymorphous adenocarcinoma
 - ___ Tall cell carcinoma with reversed polarity
 - ___ Adenomyoepithelioma with carcinoma
 - ___ Epithelial-myoepithelial carcinoma
 - ___ Other type not listed (specify): _____

References

1. WHO Classification of Tumours Editorial Board. *Breast tumours*. Lyon (France): International Agency for Research on Cancer; 2019. (WHO classification of tumours series, 5th ed.; vol. 2).

D. Histologic Grade

All invasive breast carcinomas should be graded.¹ The Nottingham combined histologic grade (Elston-Ellis modification of Scarff-Bloom-Richardson grading system) should be used for reporting. Within each stage grouping there is a relation between histologic grade and outcome.

The Nottingham combined histologic grade evaluates the amount of tubule formation, the extent of nuclear pleomorphism, and the mitotic count (or mitotic rate). Each variable is given a score of 1, 2, or 3, and the scores are added to produce a grade. The mitotic score is determined by the number of mitotic figures

found in 10 consecutive high-power fields (HPF) in the most mitotically active part of the tumor. Only clearly identifiable mitotic figures should be counted; hyperchromatic, karyorrhectic, or apoptotic nuclei are excluded. Because of variations in field size, the HPF size must be determined for each microscope and the appropriate point score determined accordingly. It is recommended that the size be measured by using a micrometer. However, the diameter of an HPF can also be calculated by using the method below.

Measuring the Size of a High-Power Field (HPF) With a Ruler

Use a clear ruler to measure the diameter of a low-power field. This number can be used to calculate a constant based on the following formula:

Eyepiece Magnification x Objective Magnification x Microscopic Field Diameter = A Constant

When the value of the constant is known, the diameter of an HPF can be calculated for other objectives by using the following formula:

Unknown Field Diameter = Constant / (Eyepiece Magnification x Objective Magnification)

Half of the field diameter is the radius of the field (*r*), which can then be used to calculate the area of the HPF:

$3.1416 \times r^2 = \text{Area of Microscopic Field}$

If the microscopic field diameter or the area of the field is known, Table 1 can be used to determine the number of mitoses corresponding to different scores.

Table 1. Score Categories According to Field Diameter and Mitotic Count

Scoring Categories of Mitotic Counts				
Field diameter (mm)	Area (mm ²)	Number of mitoses per 10 fields corresponding to:		
		Score 1	Score 2	Score 3
0.40	0.125	≤4	5 to 9	≥10
0.41	0.132	≤4	5 to 9	≥10
0.42	0.139	≤5	6 to 10	≥11
0.43	0.145	≤5	6 to 10	≥11
0.44	0.152	≤5	6 to 11	≥12
0.45	0.159	≤5	6 to 11	≥12
0.46	0.166	≤6	7 to 12	≥13
0.47	0.173	≤6	7 to 12	≥13
0.48	0.181	≤6	7 to 13	≥14
0.49	0.189	≤6	7 to 13	≥14
0.50	0.196	≤7	8 to 14	≥15
0.51	0.204	≤7	8 to 14	≥15
0.52	0.212	≤7	8 to 15	≥16
0.53	0.221	≤8	9 to 16	≥17
0.54	0.229	≤8	9 to 16	≥17
0.55	0.238	≤8	9 to 17	≥18
0.56	0.246	≤8	9 to 17	≥18
0.57	0.255	≤9	10 to 18	≥19
0.58	0.264	≤9	10 to 19	≥20
0.59	0.273	≤9	10 to 19	≥20
0.60	0.283	≤10	11 to 20	≥21
0.61	0.292	≤10	11 to 21	≥22

0.62	0.302	≤11	12 to 22	≥23
0.63	0.312	≤11	12 to 22	≥23
0.64	0.322	≤11	12 to 23	≥24
0.65	0.332	≤12	13 to 24	≥25
0.66	0.342	≤12	13 to 24	≥25
0.67	0.353	≤12	13 to 25	≥26
0.68	0.363	≤13	14 to 26	≥27
0.69	0.374	≤13	14 to 27	≥ 28

From Pathology Reporting of Breast Disease.² Copyright 2005 National Health Service Cancer Screening Programme and The Royal College of Pathologists. Adapted with permission.

References

1. Ellis IO, Elston CW. Histologic grade. In: O'Malley FP, Pinder SE, eds. *Breast Pathology*. Philadelphia, PA: Elsevier; 2006:225-233.
2. Royal College of Pathologists. Pathology reporting of breast disease in surgical excision specimens incorporating the dataset for histological reporting of breast cancer. June 2016. <https://www.rcpath.org/profession/publications/cancer-datasets.html>. Accessed September 18, 2018.

E. Tumor Size (Size of Invasive Carcinoma)

The size of an invasive carcinoma is an important prognostic factor. The single greatest dimension of the largest invasive carcinoma is used to determine T classification (Figure E1, A through F). The best size for AJCC T classification should use information from imaging, gross examination, and microscopic evaluation.¹ Visual determination of size is often unreliable, as carcinomas often blend into adjacent fibrous tissue. The size by palpation of a hard mass correlates better with invasion of tumor cells into stroma with a desmoplastic response. Sizes should be measured to the nearest millimeter. In some cases, the size may be difficult to determine.

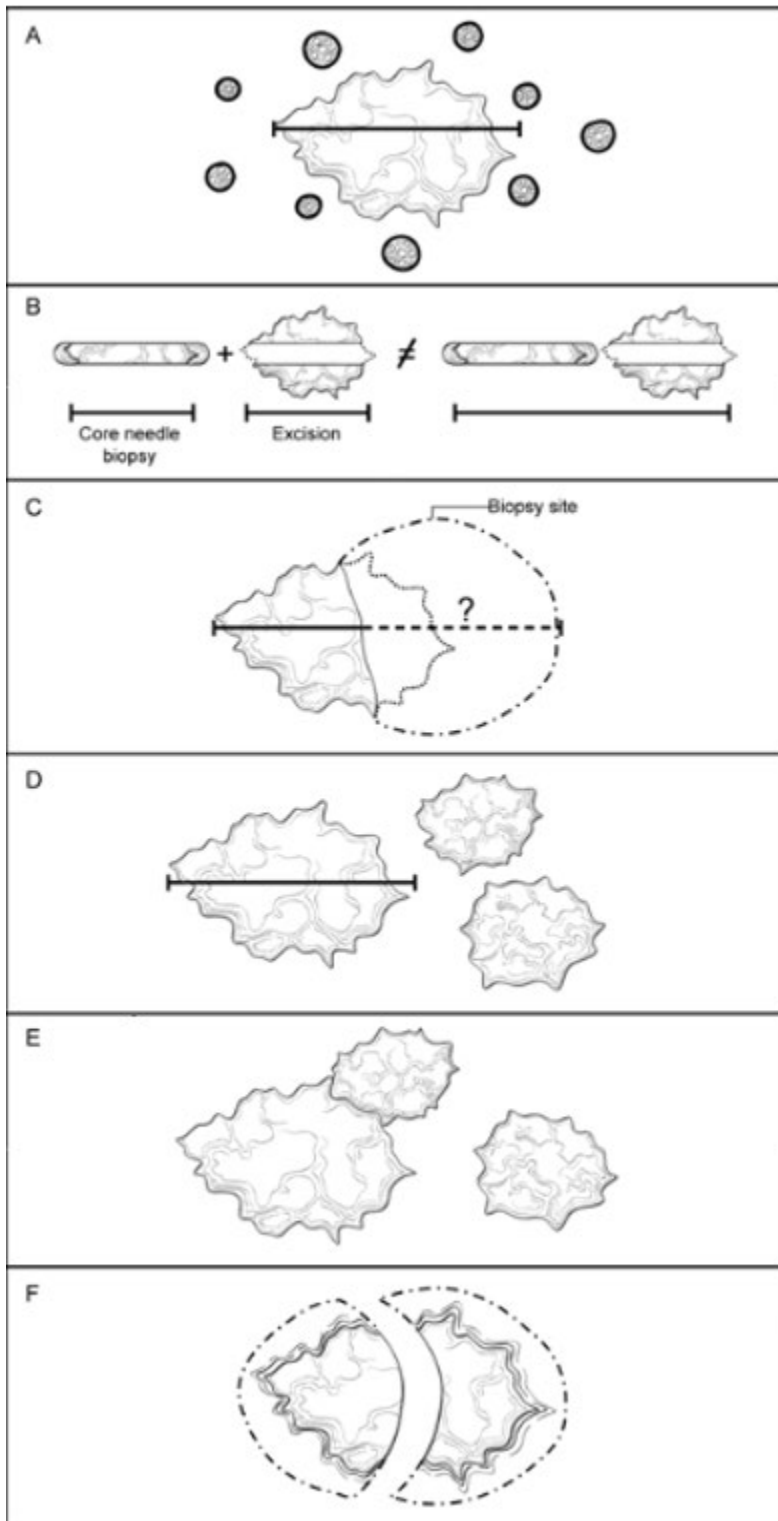


Figure E1. Determining the size of an invasive carcinoma. A. Invasive carcinoma with surrounding ductal carcinoma in situ (DCIS). The size only includes the area of the invasive carcinoma and does not include the adjacent DCIS. The size should be measured to the closest 1 mm. B. Small invasive carcinoma with prior core needle biopsy. The size of the carcinoma in the core needle biopsy should not be added to

the size of the carcinoma in the excisional specimen, as this will generally overestimate the true size. The best size for classification must take into consideration the largest dimension of the carcinoma in both specimens as well as the size by imaging before the core needle biopsy. C. Small invasive carcinomas with adjacent biopsy site changes. In some excisional specimens, a small carcinoma will be present adjacent to a relatively large area of biopsy site changes. The actual size cannot be determined with certainty. The size in the core needle biopsy, in the excisional specimen, and by imaging should be considered to determine the best size for classification. D. Multiple invasive carcinomas. If multiple carcinomas are present, the size of the largest invasive carcinoma is used for T classification. The modifier “m” is used to indicate that multiple invasive carcinomas are present. E. Multiple invasive carcinomas in close proximity. It may be difficult to distinguish multiple adjacent carcinomas from one large invasive carcinoma. Careful examination of the specimen with submission of tissue between grossly evident carcinomas is recommended. Correlation with imaging findings can be helpful. Generally, microscopic size confirmation of the largest grossly identified invasive carcinoma is used for T classification. *Exception to the size rule – if two histologically similar carcinomas are within 5.0 mm of each other, measure from outer edges of the two.* F. Invasive carcinomas that have been transected. If an invasive carcinoma has been transected and is present in more than 1 tissue fragment, the sizes in each fragment should not be added together, as this may overestimate the true size. In many cases, correlation with the size on breast imaging will be helpful to choose the best size for classification. In other cases, the pathologist will need to use his or her judgment in assigning an AJCC T category.

DCIS with microinvasion: Microinvasion is defined by the AJCC as invasion measuring 1 mm or less in size.¹ If more than 1 focus of microinvasion is present, the number of foci present, an estimate of the number, or a note that the number of foci is too numerous to quantify should be reported. In some cases, immunoperoxidase studies for myoepithelial cells may be helpful to document areas of invasion and the size of the invasive foci. Invasive tumors that are larger than 1.0 mm but less than 2.0 mm are rounded up to 2.0 mm.

References

1. Amin MB, Edge SB, Greene FL, et al, eds. *AJCC Cancer Staging Manual*. 8th ed. New York, NY: Springer; 2017.

F. Tumor Focality (Single or Multiple Foci of Invasive Carcinoma)

Focality need not be specifically stated if there is only a single area of invasive carcinoma. If multiple invasive carcinomas are present, focality should be reported. Patients with multiple foci of invasion may be divided into the following 6 groups:

- **Extensive carcinoma in situ (CIS) with multiple foci of invasion (Figure F1, A).** Extensive DCIS is sometimes associated with multiple areas of invasion. The invasive carcinomas are usually similar in histologic appearance and immunophenotype, unless the DCIS shows marked heterogeneity. This is the most common etiology of multiple invasive carcinomas.
- **Invasive carcinoma with smaller satellite foci of invasion (Figure F1, B).** A large carcinoma is sometimes surrounded by smaller adjacent foci of invasion. In such cases, the appearance of multiple foci may be due to irregular extensions of the carcinoma into stroma, which in 2 dimensions give the appearance of multiple foci. In such cases, the smaller foci are usually identical in histologic appearance and immunophenotype to the dominant carcinoma. Small microscopic satellite foci of tumor around the primary tumor do not appreciably alter tumor volume and are not added to or included in the maximum tumor size.

- **Invasive carcinoma with extensive lymphovascular invasion (LVI) (Figure F1, C).** Additional foci of invasion may arise from areas of LVI (i.e., an intramammary metastasis). The multiple carcinomas are usually identical in histologic appearance and immunophenotype. The origin of satellite skin nodules classified as T4b is generally due to invasion arising from foci of dermal lymphovascular invasion.
- **Multiple biologically separate invasive carcinomas (Figure F1, D).** Some patients have multiple, synchronous, biologically independent carcinomas. Patients with germ-line mutations are at increased risk for developing multiple carcinomas. The carcinomas may or may not be similar in appearance and immunophenotype.
- **Invasive carcinomas after neoadjuvant therapy (Figure F1, E).** Cancers with a significant response to chemotherapy typically present as multiple residual foci within a fibrotic tumor bed (see Note K). The foci of invasion are usually identical in appearance and immunophenotype.
- **Transection of a single carcinoma into multiple fragments (Figure F1, F).** If invasive carcinoma is present in multiple fragments of a fragmented specimen, transection of 1 carcinoma should be considered. Correlation with clinical and imaging findings can sometimes be helpful to determine the best size for T classification and to determine whether or not multiple foci were present.

RETIRED

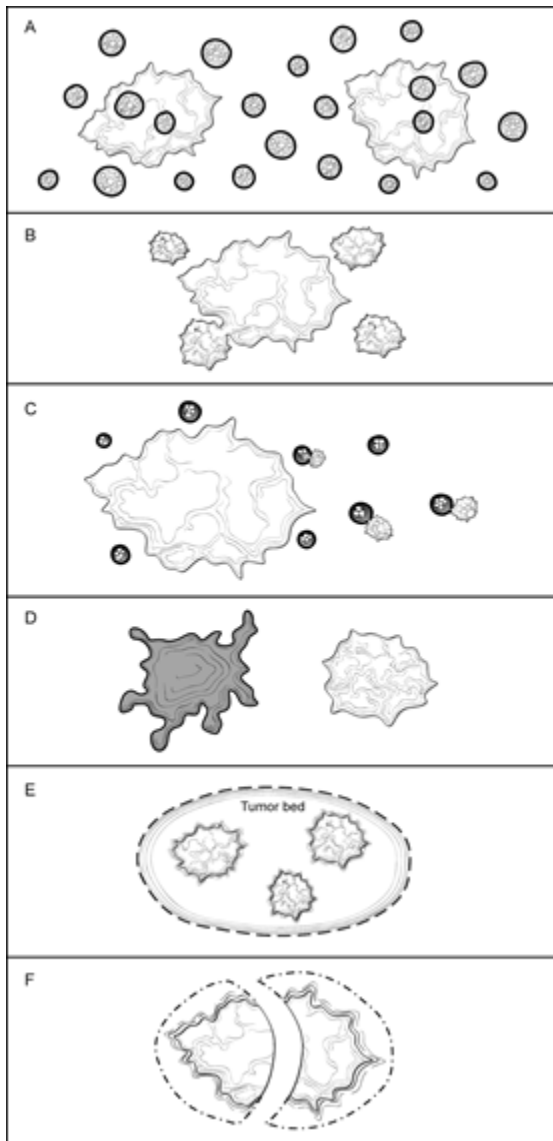


Figure F1. Multiple Invasive Carcinomas. A. Extensive carcinoma in situ with multiple foci of invasion. The invasive carcinomas are usually similar in histologic appearance and immunoprofile unless the ductal carcinoma in situ (DCIS) shows marked heterogeneity. B. Invasive carcinoma with smaller satellite foci. The smaller foci are generally within 1 to 5 mm of the main carcinoma and are most likely due to extensions of the main carcinoma that would be connected in another plane of section. The carcinomas are usually identical in appearance and immunoprofile. *Exception to the size rule – if two histologically similar carcinomas are within 5.0 mm of each other, measure from outer edges of the two.* C. Invasive carcinoma with extensive lymphovascular invasion. Areas of lymphovascular invasion can give rise to additional foci of invasive carcinoma (ie, intramammary metastasis). The carcinomas are usually identical in appearance and immunoprofile. D. Multiple biologically separate invasive carcinomas. These carcinomas are usually widely separated and may be histologically and immunophenotypically distinct. E. Invasive carcinomas after presurgical (neoadjuvant) therapy. If there is a marked response to treatment, multiple foci of carcinoma may be scattered over a fibrotic tumor bed. The residual carcinoma is usually similar in appearance and immunoprofile to the pretreatment carcinoma, but in some cases alterations due to treatment may be

present. F. Transection of a single carcinoma into multiple fragments. If a carcinoma is transected during excision, it may be difficult to determine if 1 or multiple carcinomas are present. The carcinomas should be identical in appearance and immunoprofile.

Features pertaining to a specific cancer (i.e., histologic type, grade, size, and the results of ER, PgR, and HER2 studies) should be provided for the largest invasive carcinoma in the case summary. If smaller carcinomas differ in histologic type or grade, this information should be included under “Additional Pathologic Findings,” and additional ancillary tests are recommended for these carcinomas. Features pertaining to all carcinomas (e.g., margins, lymph node status) can be reported in the body of the case summary.

Patients with multiple grossly evident invasive carcinomas have a higher risk of having lymph node metastases.¹ However, it has not been shown that multiple invasive carcinomas increase the risk of distant metastases for patients with lymph node-negative disease.

For patients with multiple ipsilateral invasive carcinomas, the T category assignment is based on the largest tumor. The “(m)” modifier is used to distinguish these cases from those with only a single invasive focus. For patients with simultaneous bilateral invasive carcinomas, each carcinoma is staged as a separate primary tumor, with independent determination of T and N categories and biomarker status.

References

1. Andea AA, Wallis T, Newman LA, Bouwman D, Dey J, Visscher DW. Pathologic analysis of tumor size and lymph node status in multifocal/multicentric breast carcinoma. *Cancer*. 2002;94:1383-1390.

G. Ductal Carcinoma in Situ

Ductal carcinoma in situ associated with invasive carcinoma increases the risk of local recurrence for women undergoing breast-conserving surgery. It is more important to report the features of DCIS when in situ disease is predominant (e.g., cases of DCIS with microinvasion or extensive DCIS associated with T1a carcinoma). If DCIS is a minimal component of the invasive carcinoma, the features of the DCIS have less clinical relevance. The extent of DCIS has no prognostic significance in mastectomy specimens. Therefore, most of the reporting elements for DCIS are optional and should be used at the discretion of the pathologist.

The pathology report should specify whether extensive DCIS is present. Extensive intraductal component (EIC)-positive carcinomas are defined in 2 ways (Figure G1, A through D)¹:

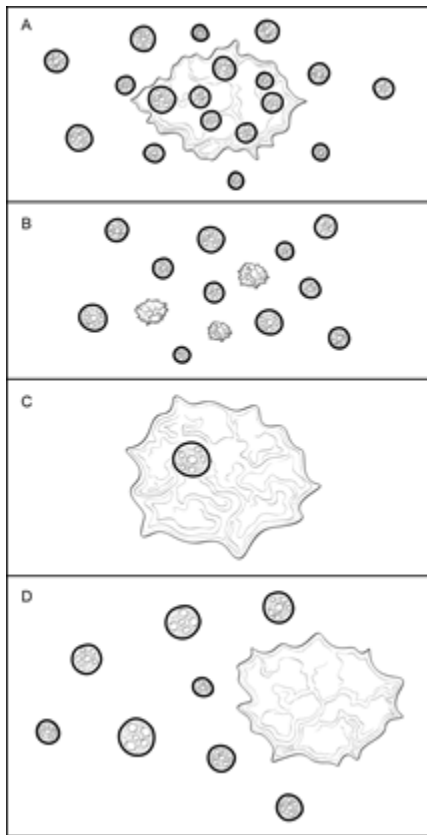


Figure G1. Extensive Intraductal Component (EIC). A. Extensive intraductal component (EIC)-positive carcinomas are defined by the following criteria: (1) Prominent DCIS within the invasive carcinoma and (2) DCIS is also present outside the area of invasive carcinoma. B. EIC-positive carcinomas also include carcinomas that are primarily DCIS in association with a “small” (approximately 10 mm or less) invasive carcinoma or carcinomas. C. EIC-negative carcinomas do not fulfill the criteria for being positive for EIC. D. Some carcinomas do not strictly fulfill the criteria for EIC but are associated with extensive DCIS in the surrounding tissue. In such cases it is helpful to provide some measure of the extent of DCIS in the specimen.

1. Ductal carcinoma in situ is a major component within the area of invasive carcinoma and DCIS is also present in the surrounding breast parenchyma.
2. There is extensive DCIS associated with an invasive carcinoma.

Extensive intraductal component-positive carcinomas are associated with an increased risk of local recurrence when the surgical margins are not evaluated or focally involved. The finding of EIC positivity has less significance when DCIS does not extend close to margins. The extent of DCIS has no local recurrence risk in patients treated with mastectomy.

In some cases, extensive DCIS can be present outside the area of invasive carcinoma although the carcinoma does not technically fulfill the criteria for EIC positivity. In such cases, quantification of the amount of DCIS present is helpful for planning radiation therapy.

The extent of DCIS will be most relevant for cases of extensive DCIS with microinvasion and least relevant for large EIC-negative invasive carcinomas. Methods for estimating the extent of DCIS include directly

measuring the lesion when confined to a single histologic slide, determining size by submitting the entire specimen in sequence and in sections of uniform thickness, or counting the number of blocks with DCIS. The College of American Pathologists (CAP) DCIS protocol² provides additional information on determining the extent of DCIS.

Architectural Pattern of DCIS

The architectural pattern has traditionally been reported for DCIS. However, nuclear grade and the presence of necrosis are more predictive of clinical outcome.

Nuclear Grade of DCIS

The nuclear grade of DCIS is determined using 6 morphologic features (Table 2).³

Table 2. Nuclear Grade of Ductal Carcinoma in Situ

Feature	Grade I (Low)	Grade II (Intermediate)	Grade III (High)
Pleomorphism	Monotonous (monomorphic)	Intermediate	Markedly pleomorphic
Size	1.5 to 2 x the size of a normal red blood cell or a normal duct epithelial cell nucleus	Intermediate	>2.5 x the size of a normal red blood cell or a normal duct epithelial cell nucleus
Chromatin	Usually diffuse, finely dispersed chromatin	Intermediate	Usually vesicular with irregular chromatin distribution
Nucleoli	Only occasional	Intermediate	Prominent, often multiple
Mitoses	Only occasional	Intermediate	May be frequent
Orientation	Polarized toward luminal spaces	Intermediate	Usually not polarized toward the luminal space

Necrosis

The presence of necrosis is correlated with the finding of mammographic calcifications (i.e., most areas of necrosis will calcify). Ductal carcinoma in situ that presents as mammographic calcifications often recurs as calcifications. Necrosis can be classified as follows:

- **Central (“comedo”)**: The central portion of an involved ductal space is replaced by an area of expansive necrosis that is easily detected at low magnification. Ghost cells and karyorrhectic debris are generally present. Although central necrosis is generally associated with high-grade nuclei (i.e., comedo DCIS), it can also occur with DCIS of low or intermediate nuclear grade.
- **Focal**: Small foci, indistinct at low magnification, or single cell necrosis.

Necrosis should be distinguished from secretory material, which can also be associated with calcifications, but does not include nuclear debris.

References

1. Morrow M, Harris JR. Local management of invasive breast cancer (chapter 33). In: Harris JR, Lippman ME, Morrow M, Osborne KE, eds. *Diseases of the Breast*. 2nd ed. Philadelphia, PA: Lippincott Williams & Wilkins; 2000:522-523.
2. Fitzgibbons PL, Bose S, Chen Y, et al. Protocol for the Examination of Specimens From Patients with Ductal Carcinoma In Situ (DCIS) of the Breast. 2019; www.cap.org/cancerprotocols.
3. Schwartz GF, Lagios MD, Carter D, et al. Consensus conference on the classification of ductal carcinoma in situ. *Cancer*. 1997;80:1798-1802.

H. Macroscopic and Microscopic Extent of Tumor

Breast cancers can invade into the overlying skin or into the chest wall, depending on their size and location. Extension into skin and muscle is used for AJCC classification, and these findings may be used for making decisions about local treatment. If skin or muscle are part of a specimen, their presence should always be included in the gross description and the relationship of these structures to the carcinoma reported in the final diagnosis. The extent of associated DCIS is important for determining the type of surgery that will be necessary to obtain free margins.

Skin

There are multiple ways that breast carcinoma can involve the skin:

- DCIS involving nipple epidermis (Paget disease of the nipple) (Figure H1, A): DCIS can extend from the lactiferous sinuses into the contiguous skin without crossing the basement membrane. This finding does not change the T classification of the invasive carcinoma.
- Invasive carcinoma invading into dermis or epidermis, without ulceration (Figure H1, B): Skin invasion correlates with the clinical finding of a carcinoma fixed to the skin and may be associated with skin or nipple retraction. This finding does not change the T classification.
- Invasive carcinoma invading into dermis and epidermis with skin ulceration (Figure H1, C): In the past, skin ulceration was associated with very large, locally advanced carcinomas. However, skin ulceration can also be associated with superficially located small carcinomas. It is unknown if skin involvement confers a worse prognosis as compared to carcinomas of similar size without skin invasion. Carcinomas with skin ulceration are classified as T4b.
- Ipsilateral satellite skin nodules (Figure H1, D): An area of invasive carcinoma within the dermis, separate from the main carcinoma, is usually associated with lymphovascular invasion. The satellite nodules should be macroscopically evident and confirmed microscopically. This finding is classified as T4b. The clinical significance of incidental microscopic satellite nodules in the dermis has not been investigated.
- Dermal lymphovascular invasion (Figure H1, E): Carcinoma present within lymphatic spaces in the dermis is often correlated with the clinical features of inflammatory carcinoma (diffuse erythema and edema involving one-third or more of the breast), and such cases would be classified as T4d. In the absence of the clinical features of inflammatory carcinoma, this finding remains a poor prognostic factor but is insufficient to classify a cancer as T4d. This finding is separately documented under “Dermal Lymphovascular Invasion.”

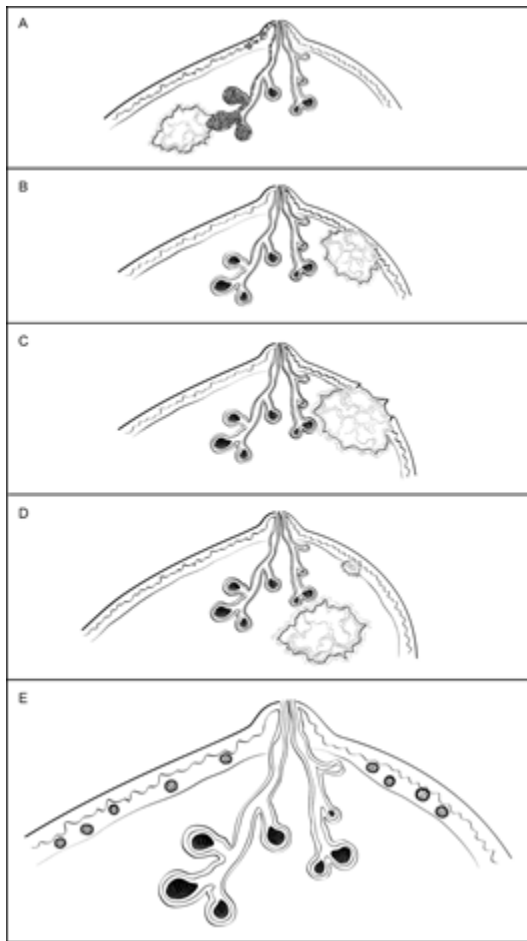


Figure H1. Invasive Carcinoma: Skin Involvement. A. Ductal carcinoma in situ (DCIS) involving nipple epidermis (Paget disease of the nipple) associated with an invasive carcinoma. DCIS can traverse the lactiferous sinuses into the epidermis without crossing a basement membrane. This finding does not change the T classification of an underlying invasive carcinoma. B. Invasive carcinoma invading into dermis or epidermis, without ulceration. This finding does not change the T classification of the invasive carcinoma. C. Invasive carcinoma invading into dermis and epidermis with skin ulceration. This carcinoma would be classified as T4b, unless additional features warrant classification as T4c (chest wall invasion) or T4d (inflammatory carcinoma). D. Ipsilateral satellite skin nodules. An area of invasive carcinoma in the skin, separate from the main carcinoma, is usually associated with lymphovascular invasion. This finding is classified as T4b, unless additional features warrant classification as T4c (chest wall invasion) or T4d (inflammatory carcinoma). E. Dermal lymphovascular invasion. If carcinoma within lymphatic spaces in the dermis is correlated with the clinical features of inflammatory carcinoma (diffuse erythema and edema involving one-third or more of the breast), the carcinoma is classified as T4d. If clinical signs are not present, this finding does not change the T classification, but is an indicator of a poor prognosis.

Muscle

Skeletal muscle may be present at the deep/posterior margin. The presence of muscle documents that the excision has extended to the deep fascia. Invasion into skeletal muscle should be reported, as this finding may be used as an indication for postmastectomy radiation therapy.

The skeletal muscle present is generally pectoralis muscle. Invasion into this muscle is not included as T4a. Invasion must extend through this muscle into the chest wall (intercostal muscles or deeper) in order to be classified as T4a. However, chest wall muscles are rarely removed in mastectomy specimens. The T4a classification is generally established with imaging of locally advanced carcinomas.

I. Lymphatic and/or Vascular Invasion

Lymphatic and/or vascular invasion (LVI) is associated with local recurrence and reduced survival.^{1,2,3} Distinguishing lymphatic channels from blood vessels is unnecessary. Documenting the presence of dermal lymphatic and/or vascular invasion is particularly important because of its strong association with the clinical findings of inflammatory breast carcinoma. Reporting the LVI status for stage IIA and IIB patients who have an axillary lymph node dissection (ALND) may influence the use of radiotherapy.⁴

Strict criteria have been proposed for the diagnosis of LVI⁵ (Table 3). Lymphatic and/or vascular invasion may be seen in stroma between uninvolved lobules and can sometimes be mistaken for DCIS if the cells completely fill the lymphatic space.

Guidelines issued by the St. Gallen International Expert Consensus Conference⁶ include recommendations based on the presence of “extensive” LVI but do not define the term “extensive”. There are conflicting results on the significance of the number of foci of LVI.^{2,3} Pathologists may report the number of foci or the number of blocks with LVI as a measure of extent.

Table 3. Criteria for Lymphatic and/or Vascular Invasion (LVI)

1.	LVI must be diagnosed outside the border of the invasive carcinoma. The most common area to find LVI is within 1 mm of the edge of the carcinoma.
2.	The tumor emboli usually do not conform exactly to the contours of the space in which they are found. In contrast, invasive carcinoma with retraction artifact mimicking LVI will have exactly the same shape.
3.	Endothelial cell nuclei should be seen in the cells lining the space.
4.	Lymphatics are often found adjacent to blood vessels and often partially encircle a blood vessel.

Data derived from Rosen.⁵

References

1. Gonzalez MA, Pinder SE. Invasive carcinoma: other histologic prognostic factors – size, vascular invasion and prognostic index. In: O’Malley FP, Pinder SE, eds. *Breast Pathology*. Philadelphia, PA: Elsevier; 2006: 235-240.
2. Colleoni M, Rotmensz N, Maisonneuve P, et al. Prognostic role of the extent of peritumoral vascular invasion in operable breast cancer. *Ann Oncol*. 2007;18:1632-1640.
3. Mohammed RA, Martin SG, Mahmmod AM, et al. Objective assessment of lymphatic and blood vessel invasion in lymph node-negative breast carcinoma: findings from a large case series with long-term follow-up. *J Pathol*. 2011;223:358-365.
4. Recht A, Comen EA, Fine RE, et al. Postmastectomy Radiotherapy: An American Society of Clinical Oncology, American Society for Radiation Oncology, and Society of Surgical Oncology Focused Guideline Update. *Journal of Clinical Oncology*. 2016 34:36, 4437. DOI: 10.1200/JCO.2016.69.1188.
5. Rosen PP. Tumor emboli in intramammary lymphatics in breast carcinoma: pathologic criteria for diagnosis and clinical significance. *Pathol Annu*. 1983;18 Pt 2:215-232.

6. Goldhirsch A, Wood WC, Coates AS, et al. Strategies for subtypes-dealing with the diversity of breast cancer: highlights of the St. Gallen International Expert Consensus on the primary therapy of early breast cancer 2011. *Ann Oncol.* 2011;22:1736-1747.

J. Microcalcifications

Cancer found in biopsies performed for microcalcifications will almost always be at the site of the calcifications or in close proximity. The presence of the targeted calcifications in the specimen should be confirmed by specimen radiography. The pathologist must be satisfied that the specimen has been sampled in such a way that the lesion responsible for the calcifications has been examined microscopically. The relationship of the radiologic calcifications to the invasive carcinoma and the DCIS should be indicated.

If calcifications can be seen in the specimen radiograph but not in the initial histologic sections, deeper levels should be examined. If needed, radiographs of the paraffin block(s) may be obtained to detect calcifications remaining in the block(s). If microcalcifications cannot be confirmed by routine microscopic evaluation, polarized light may be helpful, since calcium oxalate crystals are refractile and polarizable but usually clear or tinged yellow in H&E sections. On rare occasions, calcifications do not survive tissue processing or prolonged fixation in formalin. Foreign material can sometimes simulate calcifications (e.g., metallic fragments after surgery or trauma, ink from margin evaluation, and hemosiderin).

K. Treatment Effect

Patients may be treated with endocrine therapy or chemotherapy before surgical excision (neoadjuvant therapy). A y prefix is added when assigning AJCC T and N categories after neoadjuvant treatment (ypT and ypN). The response of the invasive carcinoma to neoadjuvant therapy is a strong predictor of disease-free and overall survival. Special attention to finding and evaluating the tumor bed is necessary for these specimens.^{1,2,3,4,5}

Numerous classification systems have been developed to evaluate treatment response and institutions or treatment protocols may require evaluation by one of these systems. For institutions that report the Residual Cancer Burden (RCB), the RCB calculator can be found at the MD Anderson website: <http://www3.mdanderson.org/app/medcalc/index.cfm?pagename=jsconvert3>. This site also includes materials and guides that explain the system.

RCB Assessment of Primary Tumor Bed

The size (area) of the primary tumor bed with residual viable invasive carcinoma and the cellularity of residual carcinoma in the tumor bed provide a reproducible estimate of the volume of residual invasive carcinoma. The residual invasive carcinoma cellularity is estimated by determining the overall cancer cellularity (invasive and in situ) and the percentage of residual in situ carcinoma. The RCB calculation subtracts the amount of in situ disease to obtain the estimate of residual invasive carcinoma cellularity used to determine the RCB. If only LVI remains after therapy, the area with LVI is used as the primary tumor bed area and the cellularity of the LVI is used as the residual cancer cellularity.

RCB Assessment of Regional Lymph Nodes

According to the AJCC 8th edition staging system, the size of the largest contiguous focus of residual metastatic carcinoma present in the lymph nodes is used to assign the pN category; intervening therapy-related fibrosis is not included in this measurement. However, when measuring the diameter of the largest lymph node metastasis for the RCB calculation, foci of residual metastatic carcinoma with intervening therapy-related fibrosis and any extracapsular extension are included in the measurement.

Lymph nodes containing only isolated tumor cells (ITCs) are not included in the number of positive lymph nodes when determining the AJCC pN category, but nodes containing only ITCs detected by routine stains are included in the RCB calculation. A size smaller than 0.2 mm (e.g., 0.05 mm) can be entered in the RCB calculator.

If there are separate metastases within the node with intervening normal nodal tissue, then these should be considered as separate foci and the largest single focus is used as the size of the largest metastatic deposit for both AJCC Staging and RCB calculation.

Invasive carcinomas with a minor response may show little or no change in size. With greater degrees of response, the carcinoma shows decreased cellularity and may be present as multiple foci of invasion scattered over a larger tumor bed. The post-neoadjuvant therapy pathologic T-category (ypT) is based on the largest single focus of residual tumor, if present. Treatment-related fibrosis adjacent to residual invasive carcinoma is not included in the ypT maximum dimension. The “m” modifier is used to indicate that multiple foci of invasive carcinoma are present. The inclusion of additional information, such as the distance over which invasive carcinoma is present, the number of foci of invasive carcinoma, or the number of slides or blocks with invasive carcinoma, may be helpful in estimating the extent of residual disease. If no residual invasive carcinoma is present in the breast, the case summary can be used to report residual DCIS and/or metastatic carcinoma in lymph nodes. If there is no residual carcinoma in the breast or in the lymph nodes, then a CAP protocol case summary need not be used for reporting. Cases with no residual invasive carcinoma after neoadjuvant therapy are categorized as ypTis if there is residual DCIS or ypT0 if there is no residual cancer (not ypTX). Cases categorized as M1 before neoadjuvant therapy stay that way (i.e., they remain Stage IV even if there is complete pathologic response).

Most carcinomas are of the same grade after treatment. In a few cases, the grade will be higher because of marked nuclear pleomorphism. In very rare cases, the carcinoma will be of lower grade. The prognostic significance of a change in grade after treatment has not been determined.

If negative prior to treatment, it is recommended that ER, PgR, and HER2 be repeated on invasive carcinomas after treatment, as significant changes may occur in a subset of carcinomas, sometimes due to tumor heterogeneity and limited sampling prior to treatment.

References

1. Sahoo S, Lester SC. Pathology of breast carcinomas after neoadjuvant chemotherapy: an overview with recommendations on specimen processing and reporting. *Arch Pathol Lab Med.* 2009;133:633-642.
2. Provenzano E, Bossuyt V, Viale G, et al. Standardization of pathologic evaluation and reporting of postneoadjuvant specimens in clinical trials of breast cancer: recommendations from an international working group. *Mod Pathol* 2015;28,1185–1201.
3. Peintinger F, Sinn B, Hatzis C. et al. Reproducibility of residual cancer burden for prognostic assessment of breast cancer after neoadjuvant chemotherapy. *Mod Pathol* 2015;28, 913–920.
4. Symmans WF, Wei C, Gould R, et al. Long-term prognostic risk after neoadjuvant chemotherapy associated with residual cancer burden and breast cancer subtype. *J Clin Oncol.* 2017;35(10):1049-1060.
5. Symmans WF, Peintinger F, Hatzis C, et al. Measurement of residual breast cancer burden to predict survival after neoadjuvant chemotherapy. *J Clin Oncol.* 2007;25(28):4414-4422.

RETIRED

L. Margins

Whenever feasible, the specimen should be oriented in order for the pathologist to identify specific margins. This is particularly important for excisions less than total mastectomy, where it may be necessary for the surgeon to excise residual tumor at a specific margin (e.g., superior, inferior, medial, lateral, anterior, or deep). Identification of surgical margins also allows measurement of the distance between the carcinoma and specific margins. All identifiable margins should be evaluated for involvement by carcinoma both grossly and microscopically.¹

Orientation may be done by sutures or clips placed on the specimen surface or by other means of communication between surgeon and pathologist and should be documented in the pathology report. Margins can be identified in several ways, including the use of multiple-colored inks, by submitting the margins in specific cassettes, or by the surgeon submitting each margin as a separately excised specimen. Inks should be applied carefully to avoid penetration deep into the specimen.

Macroscopic or microscopic involvement of surgical margins by invasive carcinoma or DCIS should be noted in the report. If the specimen is oriented, the specific site(s) of involvement should also be reported. When possible, the pathologist should report the distance from the tumor to the closest margin.¹

If margins are sampled with perpendicular sections, the pathologist should report the distance of the invasive carcinoma and DCIS to the closest margin, whenever possible. Because of the growth pattern of DCIS in the ductal system, a negative but close margin does not ensure the absence of DCIS in the adjacent tissue.

A positive margin requires ink on carcinoma. If the specimen is oriented, the specific site(s) of involvement (e.g., superior margin) should also be reported.

The deep margin may be at muscle fascia. If so, the likelihood of additional breast tissue beyond this margin (and therefore possible involvement by DCIS) is extremely small. A deep muscle fascial margin (e.g., on a mastectomy specimen) positive for DCIS is unlikely to have clinical significance. However, invasive carcinoma at the deep margin, especially if associated with muscle invasion, is often an indication for postmastectomy radiation.

A superficial (generally anterior) margin may be immediately below the skin, and there may not be additional breast tissue beyond this margin. However, some breast tissue can be left in skin flaps, and the likelihood of residual breast tissue is related to the thickness of the flap.²

Specimen radiography is important to assess the adequacy of excision. Compression of the specimen should be minimized, as it can severely compromise the ability to assess the distance of the DCIS from the surgical margin. Mechanical compression devices should be used with caution and preferably reserved for nonpalpable lesions that require this technique for imaging (e.g., microcalcifications).

It is helpful to report the approximate extent of margin involvement:

- Unifocal: 1 focal area of carcinoma at the margin, <4 mm
- Multifocal: 2 or more foci of carcinoma at the margin
- Extensive: carcinoma present at the margin over a broad front (>5 mm)

References

1. Morrow M, Van Zee KJ, Solin LJ, et al. Society of Surgical Oncology-American Society for Radiation Oncology-American Society of Clinical Oncology consensus guideline on margins for breast-conserving surgery with whole-breast irradiation in ductal carcinoma in situ. *Pract Radiat Oncol.* 2016;6(5):287-295.
2. Torresan RZ, dos Santos CC, Okamura H, Alvarenga M. Evaluation of residual glandular tissue after skin-sparing mastectomies. *Ann Surg Oncol.* 2005;12(12):1037-1044.

M. Lymph Node Sampling and Reporting

Most patients with invasive carcinoma will have lymph nodes sampled.

Types of lymph nodes:

- **Sentinel lymph nodes** are identified by the surgeon by uptake of radiotracer or dye or both. They are considered sentinel lymph nodes if less than six nodes are removed. Adjacent palpable nonsentinel nodes may also be removed.
- **Axillary lymph nodes** are removed by en bloc resection of axillary tissue. The nodes are divided into levels: I (low-axilla: lateral to the lateral border of the pectoralis minor muscle); II (mid-axilla: between the medial and lateral borders of the pectoralis minor muscle and the interpectoral [Rotter's] lymph nodes); and III (apical axilla or infraclavicular nodes: medial to the medial margin of the pectoralis minor muscle and inferior to the clavicle). A surgeon may choose to remove 1 or more of these levels. Levels I and II are typically removed in the axillary dissection, with level III nodes only removed if considered suspicious by the surgeon intraoperatively. Level III nodes must be specifically identified, as there are additional AJCC N categories for these nodes.
- **Intramammary nodes** are present within breast tissue and are most commonly found in the upper outer quadrant. Intramammary nodes may rarely be sentinel lymph nodes. These nodes are included with axillary nodes for AJCC N classification.
- **Internal mammary nodes, supraclavicular nodes, and infraclavicular nodes** are rarely removed for breast cancer staging. If metastases are present in these nodes, there are specific AJCC N categories (see *AJCC Cancer Staging Manual*¹).

Lymph node sampling:

- **Grossly positive nodes:** The size of grossly positive nodes should be recorded. One section to include any areas suggestive of extranodal invasion is sufficient. Cancerous nodules in the axillary fat adjacent to the breast, without histologic evidence of residual lymph node tissue, are classified as regional lymph node metastasis.
- **Grossly negative nodes:** Sampling must be adequate to detect all macrometastases, as they are known to have prognostic importance (i.e., all metastatic deposits >2 mm). Thus, each node should be thinly sliced along the long axis of the node at 2 mm, and all slices should be submitted for microscopic examination. At least 1 representative hematoxylin-and-eosin (H&E) level must be examined. Additional methods of sampling, such as additional H&E levels or immunohistochemical studies, may detect isolated tumor cells or micrometastases. However, the clinical impact on outcome of these small metastases is minimal.²

The nodes must be submitted in such a way that every node can be evaluated and counted separately.

Reverse transcriptase polymerase chain reaction has been developed as an alternative method for examining lymph nodes.^{3,4} The tissue used for this assay cannot be examined microscopically. All

macrometastases must be identified histologically. Therefore, nodal tissue can only be used for other assays if all macrometastases can be identified by H&E examination. False-positive and false-negative results can occur with RT-PCR. The significance of a positive RT-PCR result for a histologically negative lymph node is unknown.

Reporting lymph nodes:

- **Number of nodes examined:** The total number of nodes includes sentinel nodes, nonsentinel nodes, nodes from axillary dissections, and intramammary nodes. When the number of sentinel and nonsentinel nodes removed is less than 6 nodes, the AJCC “sn” modifier is used.
- **Size of metastases:** Metastases are classified into 3 groups:
 - Isolated tumor cell clusters (ITCs) are defined as small clusters of cells not larger than 0.2 mm, or single cells, or fewer than 200 cells in a single cross-section. ITCs may be detected by routine histology or by immunohistochemical (IHC) methods. Nodes containing only ITCs are not included in the total number of positive nodes when determining the N category.
 - Micrometastases measure more than 0.2 mm, but not more than 2 mm, and/or comprise more than 200 cells in a single cross-section. If only micrometastases are present, the N category is pN1mi. If at least 1 macrometastasis is present, nodes with micrometastases are included in the total number of positive nodes when determining the N category.
 - Macrometastases measure more than 2 mm.

In most cases, if metastases are present, the sentinel node will be involved. In rare cases, only nonsentinel nodes contain metastases. These cases can occur if the true sentinel node is completely replaced by tumor (and therefore is not detected by radioactive tracer or dye), if there is unusual lymphatic drainage, or if there is failure of the technique to identify the node. This finding should be included in the report.

In some cases, the best N category can be difficult to determine (Figure M1).

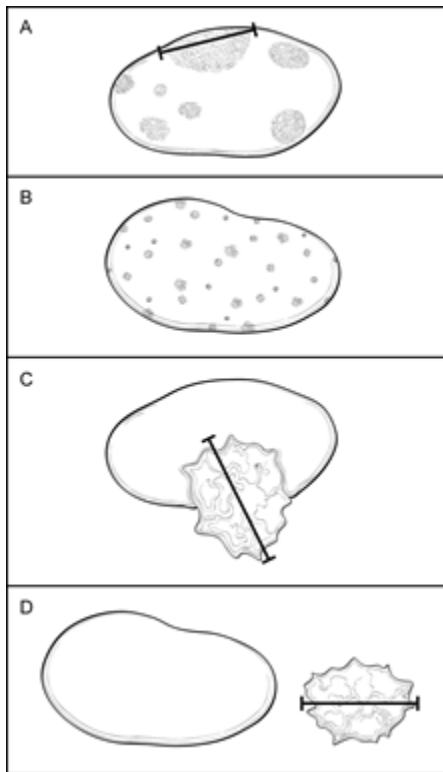


Figure M1. Classification of Lymph Node Metastases. A. Multiple clusters of tumor cells. Classification is based on the size of the largest contiguous cluster of tumor cells. The distance between clusters should not be included in the size measurement. However, if the overall volume of tumor is similar to the next highest nodal category, it is recommended that the pathologist use his or her judgment to assign the best N category and to include the reasoning in a note. B. Dispersed pattern of lymph node metastasis. Some carcinomas, in particular lobular carcinomas, metastasize as single cells and do not form cohesive clusters. In such cases, the “size” of the metastasis is difficult to determine. If more than 200 tumor cells are present in 1 cross-section of the node, then the category of isolated tumor cells should not be used. If there is difficulty in assigning the N category, it is recommended that the reason be provided in a note. C. Extranodal invasion. The area of invasion outside the lymph node capsule is included in the overall size of the lymph node metastasis. The size of the metastasis includes the tumor cells and the desmoplastic response (i.e., the cells do not need to be contiguous, but the cells plus fibrosis should be contiguous). The finding of extranodal invasion is also reported. D. Cancerous nodules in axillary fat. Areas of carcinoma invading into the stroma in axillary adipose tissue, without residual nodal tissue, are considered to be positive lymph nodes. However, if there is surrounding breast tissue or ductal carcinoma in situ, then the invasive carcinoma should be classified as an invasive carcinoma and not as a lymph node metastasis.

- **Nodes after neoadjuvant therapy:** The response of metastatic carcinoma in lymph nodes after treatment is an important prognostic factor. In addition to the information described above, evidence of treatment response (e.g., small tumor deposits within an area of fibrosis) should also be reported (see Note K). Only the largest contiguous focus of residual tumor in the node evaluation is used for classification; any treatment-associated fibrosis is not included.

References

1. Amin MB, Edge SB, Greene FL, et al, eds. *AJCC Cancer Staging Manual*. 8th ed. New York, NY: Springer; 2017.
2. Weaver DL, Ashikaga T, Krag DN, et al, Effect of occult metastases on survival in node-negative breast cancer. *N Engl J Med*. 2011;364:412-421.
3. Viale G, Dell'Orto P, Biasi MO, et al, Comparative evaluation of an extensive histopathologic examination and a real-time reverse-transcription-polymerase chain reaction assay for mammaglobin and cytokeratin 19 on axillary sentinel lymph nodes of breast carcinoma patients. *Ann Surg*. 2008;247:136-142.
4. Julian TB, Blumencranz P, Deck K, et al. Novel intraoperative molecular test for sentinel lymph node metastases in patients with early-stage breast cancer. *J Clin Oncol*. 2008;26:3338-3345.

N. Pathologic Stage Classification

The tumor-node-metastasis (TNM) staging system maintained collaboratively by the American Joint Committee on Cancer (AJCC) and the International Union Against Cancer (UICC) is recommended.¹ Assignment of Pathologic Prognostic Stage Group is the responsibility of the managing physician and not the pathologist.¹

Pathologic Classification

The pathologic classification of a cancer is based on information acquired before treatment supplemented and modified by the additional evidence acquired during and from surgery, particularly from pathologic examination of resected tissues. The pathologic classification provides additional precise and objective data. Classification of T, N, and M by pathologic means is denoted by use of a lower case "p" prefix (pT, pN, pM).

Pathologic T (pT): The pathologic assessment of the primary tumor (pT) generally is based on resection of the primary tumor generally from a single specimen. Resection of the tumor with several partial removals at the same or separate operations necessitates an effort at reasonable estimates of the size and extension of the tumor to assign the correct or highest pT category. In this situation, imaging findings can be used for determination of the pathologic size (pT). On rare occasions, the tumor size is obtained from a previous core needle biopsy specimen, as the tumor in the core may be larger than the tumor in the excision specimen.

AJCC/UICC definition of inflammatory carcinoma (T4d): Inflammatory carcinoma is a clinical-pathologic entity characterized by diffuse erythema and edema (peau d'orange) involving one-third or more of the skin of the breast. The skin changes are due to lymphedema caused by tumor emboli within dermal lymphatics, which may or may not be obvious in a small skin biopsy. However, a tissue diagnosis is still necessary to demonstrate an invasive carcinoma in the underlying breast parenchyma or at least in the dermal lymphatics, as well as to determine biological markers, such as ER, PgR, and HER2 status. Tumor emboli in dermal lymphatics without the clinical skin changes described above do not qualify as inflammatory carcinoma. Locally advanced breast cancers directly invading the dermis or ulcerating the skin without the clinical skin changes also do not qualify as inflammatory carcinoma. Thus, the term inflammatory carcinoma should not be applied to neglected locally advanced cancer of the breast presenting late in the course of a patient's disease. The rare case that exhibits all the features of inflammatory carcinoma, but in which skin changes involve less than one-third of the skin, should be classified by the size and extent of the underlying carcinoma.

Pathologic N (pN): The pathologic assessment of regional lymph nodes (pN) ideally requires resection of a minimum number of lymph nodes to assure that there is sufficient sampling to identify positive nodes if present. The recommended number generally does not apply in cases where sentinel node has been accepted as accurate for defining regional node involvement and a sentinel node procedure has been performed. At least 1 node with *presence or absence* of cancer documented by pathologic examination is required for pathologic N classification.

Direct extension of primary tumor into a regional node is classified as node positive. A tumor nodule in a regional node area is classified as a positive node. The size of the metastasis, not the size of the node, is used for the criterion for the N category.

Specialized pathologic techniques such as immunohistochemistry or molecular techniques may identify limited metastases in lymph nodes that may not have been identified without the use of the special diagnostic techniques. Single tumor cells or small clusters of cells are classified as isolated tumor cells (ITCs). The standard definition for ITCs is a cluster of cells not more than 0.2 mm in greatest diameter. Cases with ITCs only in lymph nodes are classified as pN0. This rule also generally applies to cases with findings of tumor cells or their components by nonmorphologic techniques such as flow cytometry or DNA analysis.

AJCC/UICC definition of isolated tumor cells: Isolated tumor cell clusters (ITC) are defined as small clusters of cells not greater than 0.2 mm or single tumor cells, or fewer than 200 cells in a single histologic cross-section. ITCs may be detected by routine histology or by immunohistochemical (IHC) methods. Nodes containing only ITCs are excluded from the total positive node count for purposes of N classification but should be included in the total number of nodes evaluated.

Approximately 1000 tumor cells are contained in a 3-dimensional 0.2-mm cluster. Thus, if more than 200 individual tumor cells are identified as single dispersed tumor cells or as a nearly confluent elliptical or spherical focus in a single histologic section of a lymph node, there is a high probability that more than 1000 cells are present in the lymph node. In these situations, the node should be classified as containing a micrometastasis (pN1mi). Cells in different lymph node cross-sections or longitudinal sections or levels of the block are not added together; the 200 cells must be in a single node profile even if the node has been thinly sectioned into multiple slices. It is recognized that there is substantial overlap between the upper limit of the ITC and the lower limit of the micrometastasis categories due to inherent limitations in pathologic nodal evaluation and detection of minimal tumor burden in lymph nodes. Thus, the threshold of 200 cells in a single cross-section is a guideline to help pathologists distinguish between these 2 categories. The pathologist should use judgment regarding whether it is likely that the cluster of cells represents a true micrometastasis or is simply a small group of isolated tumor cells.

Pathologic M (pM): The pathologic assignment of the presence of metastases (pM1) requires histologic confirmation of cancer at the metastatic site. The designation MX has been eliminated from the AJCC/UICC TNM system. Pathologic M0 is an undefined concept, and the category “pM0” may not be used. Pathologic classification of the absence of distant metastases can only be made at autopsy. Cases with a biopsy of a possible metastatic site that shows ITCs such as circulating tumor cells (CTCs) or disseminated tumor cells (DTCs), or bone marrow micrometastases detected by IHC or molecular techniques, are classified as M0(i+) to denote the uncertain prognostic significance of these findings, and to classify the stage group according to the T and N and M0.

Posttherapy or post-neoadjuvant therapy classification (yTNM): Cases for which systemic and/or radiation therapy are given before surgery (“neoadjuvant”) or for which no surgery is performed may have the extent of disease assessed at the conclusion of the therapy by clinical or pathologic means (if resection performed). This classification is useful to clinicians because the extent of response to therapy may provide important prognostic information to patients and help direct the extent of surgery or subsequent systemic and/or radiation therapy. T and N are classified by using the same categories as for clinical or pathologic staging for the disease type, and the findings are recorded by using the prefix designator “y” (e.g., ycT; ycN; ypT; ypN). The “yc” prefix is used for the clinical stage after therapy, and the “yp” prefix is used for the pathologic stage for those cases that have surgical resection after neoadjuvant therapy. The M component should be classified by the M status defined pathologically prior to therapy.

Retreatment classification (rTNM): This classification is assigned when further treatment is planned for a cancer that recurs after a disease-free interval. Second or subsequent primary cancers detected outside the staging window (generally 4 months) are known as metachronous primary tumors and are not staged with the 'y' prefix. The original stage assigned at the time of initial diagnosis and treatment does not change when the cancer recurs or progresses. The use of this staging for retreatment or recurrence is denoted with the 'r' prefix (rTNM). All information available at the time of retreatment should be used in determining the rTNM stage.

Multiple tumors: For patients with multiple ipsilateral invasive carcinomas, the T category assignment is based on the largest tumor. The “(m)” modifier is used to distinguish these cases from those with only a single invasive focus. For patients with simultaneous bilateral invasive carcinomas, each carcinoma is staged as a separate primary tumor, with independent determination of T and N categories and biomarker status.

Metachronous primaries: Second or subsequent primary cancers occurring in the same organ or in different organs are staged as a new cancer with the TNM system. Second cancers are not staged using the “y” prefix unless the treatment of the second cancer warrants this use.

References

1. Amin MB, Edge SB, Greene FL, et al, eds. *AJCC Cancer Staging Manual*. 8th ed. New York, NY: Springer; 2017.

O. Additional Findings

In some cases, additional pathologic findings are important for the clinical management of patients.

If the biopsy was performed for a benign lesion and the invasive carcinoma is an incidental finding, this should be documented. An example would be the finding of DCIS with microinvasion in an excision for a large palpable fibroadenoma.

If there has been a prior core needle biopsy or excisional biopsy, the biopsy site should be sampled and documented in the report. If the intention was to completely re-excite a prior surgical site, the report should document biopsy changes at the margin that could indicate an incomplete excision. This protocol should not be used if the main area of carcinoma has been previously removed and the current specimen is a re-excision of the margins.

If multiple invasive carcinomas are present and differ in histologic type, grade, or the expression of ER, PgR, or HER2, this information should be included as text in this section.

RETIRED