



Protocol for the Examination of Excisional Biopsy Specimens From Patients With Primary Carcinoma of the Colon and Rectum

Version: 4.2.0.1

Protocol Posting Date: November 2021

The use of this protocol is recommended for clinical care purposes but is not required for accreditation purposes.

This protocol may be used for the following procedures AND tumor types:

Procedure	Description
Excisional biopsy	Excisional Biopsy (Polypectomy)
Tumor Type	Description
Carcinoma	Invasive carcinomas including small cell and large cell (poorly differentiated) neuroendocrine carcinoma

The following should NOT be reported using this protocol:

Procedure
Forceps biopsy
Local excision (transanal disk excision) (consider the Colon Resection protocol)
Resection (consider the Colon Resection protocol)
Cytologic specimens

The following tumor types should NOT be reported using this protocol:

Tumor Type
Well-differentiated neuroendocrine tumors (consider the Colorectal NET protocol)
Lymphoma (consider the Hodgkin or non-Hodgkin Lymphoma protocol)
Sarcoma (consider the Soft Tissue protocol)

Authors

Lawrence J. Burgart, MD*; William V. Chopp, MD*; Dhanpat Jain, MD*.

With guidance from the CAP Cancer and CAP Pathology Electronic Reporting Committees.

* Denotes primary author.

Accreditation Requirements

The use of this case summary is recommended for clinical care purposes but is not required for accreditation purposes. The core and conditional data elements are routinely reported. Non-core data elements are indicated with a plus sign (+) to allow for reporting information that may be of clinical value.

Summary of Changes

v 4.2.0.1

- The CAP made no changes to Cancer Protocol content. We updated metadata only for the electronic Cancer Checklists (eCC), requiring a version number change for the Word and PDF Cancer Protocols.

Reporting Template

Protocol Posting Date: November 2021

Select a single response unless otherwise indicated.

CASE SUMMARY: (COLON AND RECTUM: Excisional Biopsy (Polypectomy))

Standard(s): AJCC-UICC 8

This case summary is recommended for reporting biopsy specimens, but is not required for accreditation purposes.

SPECIMEN

+Specimen Integrity

- Intact
 Fragmented

TUMOR

Tumor Site (Note [A](#))

- Cecum: _____
 Ileocecal valve: _____
 Ascending colon: _____
 Hepatic flexure: _____
 Transverse colon: _____
 Splenic flexure: _____
 Descending colon: _____
 Sigmoid colon: _____
 Rectosigmoid region: _____
 Rectum: _____
 Other (specify): _____
 Not specified

Histologic Type (Note [B](#))

- Adenocarcinoma
 Mucinous adenocarcinoma
 Signet-ring cell carcinoma (poorly cohesive carcinoma)
 Medullary carcinoma
 Serrated adenocarcinoma
 Micropapillary carcinoma
 Adenoma-like adenocarcinoma
 Adenosquamous carcinoma
 Undifferentiated carcinoma
 Carcinoma with sarcomatoid component
 Large cell neuroendocrine carcinoma
 Small cell neuroendocrine carcinoma
 Mixed neuroendocrine-non-neuroendocrine neoplasm
 Other histologic type not listed (specify): _____
 Carcinoma, type cannot be determined: _____

+Histologic Type Comment: _____

Histologic Grade (Note C)

- G1, well differentiated
- G2, moderately differentiated
- G3, poorly differentiated
- G4, undifferentiated
- Other (specify): _____
- GX, cannot be assessed: _____
- Not applicable

+Size of Invasive Carcinoma

- Greatest dimension in Centimeters (cm): _____ cm
- +Additional Dimension in Centimeters (cm): _____ x _____ cm**
- Cannot be determined (explain): _____

Tumor Extent (Note D)

- Invades lamina propria
- Invades muscularis mucosae
- Invades submucosa
- Invades muscularis propria
- Cannot be determined: _____

Lymphovascular Invasion (Notes D,E) (select all that apply)

- Not identified
- Small vessel
- Large vessel (venous)
- Present (not otherwise specified)
- Cannot be determined: _____

+Number of Tumor Buds (Note F)

- Specify number in one 'hotspot' field (in an area = 0.785 mm²): _____ per 'hotspot' field
- Other (specify): _____
- Cannot be determined: _____

+Tumor Bud Score (Note F)

- Low (0-4)
- Intermediate (5-9)
- High (10 or more)
- Cannot be determined: _____

+Type of Polyp in which Invasive Carcinoma Arose (Note G)

- Tubular adenoma
- Villous adenoma
- Tubulovillous adenoma
- Traditional serrated adenoma
- Sessile serrated adenoma / sessile serrated polyp
- Hamartomatous polyp
- Other (specify): _____

+Polyp Size

___ Greatest polyp dimension in Centimeters (cm): _____ cm
+Additional Polyp Dimension in Centimeters (cm): _____ cm
___ Cannot be determined (explain): _____

+Polyp Configuration

___ Pedunculated with stalk
+Stalk Length
___ Specify length in Centimeters (cm): _____ cm
___ Other (specify): _____
___ Cannot be determined: _____
___ Sessile

+Tumor Comment: _____

MARGINS

Margin Status for Invasive Carcinoma

___ All margins negative for invasive carcinoma
Distance from Invasive Carcinoma to Deep (Stalk) Margin

Specify in Centimeters (cm)
___ Exact distance in cm: _____ cm
___ Greater than 1 cm

Specify in Millimeters (mm)
___ Exact distance in mm: _____ mm
___ Greater than 10 mm

Other
___ Other (specify): _____
___ Cannot be determined: _____
___ Not applicable

+Distance from Invasive Carcinoma to Mucosal Margin

Specify in Centimeters (cm)
___ Exact distance in cm: _____ cm
___ Greater than 1 cm

Specify in Millimeters (mm)
___ Exact distance in mm: _____ mm
___ Greater than 10 mm

Other
___ Other (specify): _____
___ Cannot be determined: _____
___ Not applicable

___ Invasive carcinoma present at margin

Margin(s) Involved by Invasive Carcinoma (select all that apply)

___ Deep (stalk): _____
___ Mucosal: _____
___ Other (specify): _____
___ Cannot be determined (explain): _____
___ Other (specify): _____
___ Cannot be determined (explain): _____

Not applicable

Margin Status for Non-Invasive Tumor (select all that apply)

- All margins negative for adenoma
- Adenoma present at mucosal margin: _____
- Other (specify): _____
- Cannot be determined (explain): _____
- Not applicable

+Margin Comment: _____

ADDITIONAL FINDINGS

+Additional Findings (select all that apply)

- None identified
- Ulcerative colitis
- Crohn disease
- Other polyp(s) (specify type[s]): _____
- Other (specify): _____

SPECIAL STUDIES (Note [H](#))

For reporting molecular testing and immunohistochemistry for mismatch repair proteins, and for other cancer biomarker testing results, the CAP Colorectal Biomarker Template should be used. Pending biomarker studies should be listed in the Comments section of this report.

COMMENTS

Comment(s): _____

Explanatory Notes

A. Anatomic Sites

The protocol applies to all carcinomas arising in the colon and rectum.¹ It excludes carcinomas of the vermiform appendix and well-differentiated neuroendocrine tumors.

The colon is divided as shown in Figure 1. The right colon is subdivided into the cecum and the ascending colon². The left colon is subdivided into the descending colon and sigmoid colon (see Table 1).¹

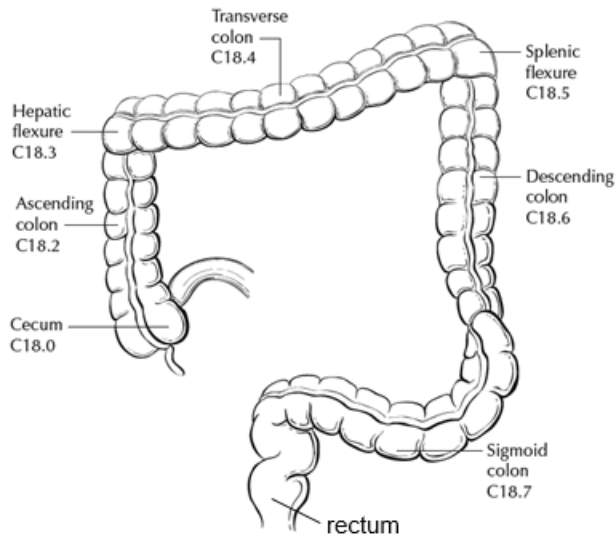


Figure 1. Anatomic subsites of the colon. Used with permission of the American Joint Committee on Cancer (AJCC), Chicago, Ill. The original source for this material is the *AJCC Cancer Staging Atlas* (2006) edited by Greene et al³ and published by Springer Science and Business Media, LLC, www.springerlink.com.

Table 1. Anatomic Subsites of the Colon and Rectum

Site	Relationship to Peritoneum	Dimensions (approximate)
Cecum	Entirely covered by peritoneum	6 x 9 cm
Ascending colon	Retroperitoneal; posterior surface lacks peritoneal covering; lateral and anterior surfaces covered by visceral peritoneum (serosa)	15-20 cm long
Transverse colon	Intraperitoneal; has mesentery	Variable
Descending colon	Retroperitoneal; posterior surface lacks peritoneal covering; lateral and anterior surfaces covered by visceral peritoneum (serosa)	10-15 cm long
Sigmoid colon	Intraperitoneal; has mesentery	Variable
Rectum	Upper third covered by peritoneum on anterior and lateral surfaces; middle third covered by peritoneum only on anterior surface; lower third has no peritoneal covering	12 cm long

The transition from sigmoid to rectum is marked by the fusion of the tenia coli of the sigmoid to form the circumferential longitudinal muscle of the rectal wall approximately 12 to 15 cm from the dentate line. The rectum is defined clinically as the distal large intestine commencing opposite the sacral promontory and ending at the anorectal ring, which corresponds to the proximal border of the puborectalis muscle palpable on digital rectal examination¹ (Figure 2). When measuring below with a rigid sigmoidoscope, it extends 16 cm from the anal verge.

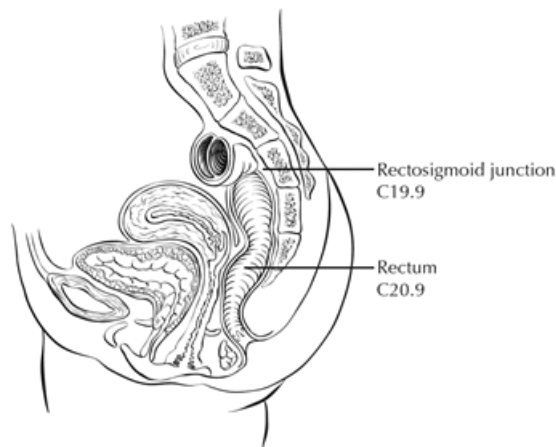


Figure 2. Anatomic subsites of the rectum. Used with permission of the American Joint Committee on Cancer (AJCC), Chicago, Ill. The original source for this material is the *AJCC Cancer Staging Atlas* (2006) edited by Greene et al² and published by Springer Science and Business Media, LLC, www.springerlink.com.

Tumors located at the border between two subsites of the colon (eg, cecum and ascending colon) are registered as tumors of the subsite that is more involved. If two subsites are involved to the same extent, the tumor is classified as an 'overlapping' lesion.

A tumor is classified as rectal if its inferior margin lies less than 16 cm from the anal verge or if any part of the tumor is located at least partly within the supply of the superior rectal artery.³ The rectum commences at the sacral promontory, and the junction of sigmoid colon and rectum is anatomically marked by fusion of tenia coli to form the circumferential longitudinal muscle of the rectal wall. Intraoperatively, the rectosigmoid junction corresponds to the sacral promontory. A tumor is classified as rectosigmoid when differentiation between rectum and sigmoid according to the previously mentioned guidelines is not possible.⁴

References

1. Amin MB, Edge SB, Greene FL, et al, eds. *AJCC Cancer Staging Manual. 8th ed.* New York, NY: Springer; 2017.
2. Greene FL, Compton CC, Fritz AG, Shah J, Winchester DP, eds. *AJCC Cancer Staging Atlas.* New York, NY: Springer; 2006.
3. Fielding LP, Arsenault PA, Chapuis PH, et al. Clinicopathological staging for colorectal cancer: an International Documentation System (IDS) and an International Comprehensive Anatomical Terminology (ICAT). *J Gastroenterol Hepatol.* 1991;6(4):325-344.
4. Wittekind C, Henson DE, Hutter RVP, Sobin LH, eds. *TNM Supplement: A Commentary on Uniform Use. 2nd ed.* New York, NY: Wiley-Liss; 2001

B. Histologic Types

For consistency in reporting, the histologic classification proposed by the World Health Organization (WHO) is recommended.¹

The histologic types of colorectal carcinoma that have been shown to have adverse prognostic significance independent of stage are signet-ring cell carcinoma² and poorly differentiated neuroendocrine carcinoma, such as small cell carcinoma small cell carcinoma (poorly differentiated neuroendocrine carcinoma).³

Medullary carcinoma is a distinctive histologic type strongly associated with high levels of microsatellite instability (MSI-H), indicative of defects in DNA repair gene function. Medullary carcinoma may occur either sporadically or in association with Lynch syndrome.^{4,5,6} This tumor type is characterized by solid growth in nested, organoid, or trabecular patterns, with no immunohistochemical evidence of neuroendocrine differentiation. Medullary carcinomas are also characterized by numerous tumor infiltrating lymphocytes and a better prognosis.

Micropapillary carcinoma is characterized by small, tight clusters of tumor cells in cleft-like spaces, and is often present in association with conventional adenocarcinoma. This variant is strongly associated with lymphovascular invasion and lymph node metastasis.⁷

Serrated adenocarcinomas are characterized by neoplastic glands showing prominent serrations, tumor cells with basal nuclei and eosinophilic cytoplasm, and no or minimal luminal necrosis. These tumors are thought to be related to traditional serrated adenomas and may have a more aggressive course than conventional adenocarcinoma.⁸

References

1. WHO Classification of Tumours Editorial Board. *Digestive system tumours*. Lyon (France): International Agency for Research on Cancer; 2019. (WHO classification of tumours series, 5th ed.; vol. 1).
2. Kang H, O'Connell JB, Maggard MA, Sack J, Ko CY. A 10-year outcomes evaluation of mucinous and signet-ring cell carcinoma of the colon and rectum. *Dis Colon Rectum*. 2005;48(6):1161-1168.
3. Bernick PE, Klimstra DS, Shia J, et al. Neuroendocrine carcinomas of the colon and rectum. *Dis Colon Rectum*. 2004;47(2):163-169.
4. Wick MR, Vitsky JL, Ritter JH, Swanson PE, Mills SE. Sporadic medullary carcinoma of the colon: a clinicopathologic comparison with nonhereditary poorly differentiated enteric-type adenocarcinoma and neuroendocrine colorectal carcinoma. *Am J Clin Pathol*. 2005;123:56-65.
5. Pyo JS, Sohn JH, Kang G. Medullary carcinoma in the colorectum: a systematic review and meta-analysis. *Hum Pathol*. 2016;53:91-96.
6. Knox RD, Luey N, Sioson L, et al. Medullary colorectal carcinoma revisited: a clinical and pathological study of 102 cases. *Ann Surg Oncol*. 2015;22(9):2988-96.
7. Haupt B, Ro JY, Schwartz MR, et al. Colorectal adenocarcinoma with micropapillary pattern and its association with lymph node metastasis. *Mod Pathol*. 2007;20:729-733.
8. Garcia-Solano J, Pérez-Guillermo M, Conesa-Zamora P, et al. Clinicopathologic study of 85 colorectal serrated adenocarcinomas: further insights into the full recognition of a new subset of colorectal carcinoma. *Hum Pathol*. 2010;41(10):1359-1368.

C. Histologic Grade

A number of grading systems for colorectal cancer have been suggested, but a single widely accepted and uniformly used standard for grading is lacking. Most systems stratify tumors into 3 or 4 grades as follows:

Grade 1	Well differentiated (>95% gland formation)
Grade 2	Moderately differentiated (50-95% gland formation)
Grade 3	Poorly differentiated (<50% gland formation)

Grade 4 Undifferentiated (no gland formation or mucin; no squamous or neuroendocrine differentiation)

Despite a significant degree of interobserver variability¹ histologic grade has been shown to be an important prognostic factor in many studies,^{2,3} with strong correlation between poor differentiation and adverse outcome.⁴ While some studies have stratified grade into a two-tiered low- and high-grade system, a three- or four-tier system is more commonly used for gastrointestinal carcinomas. The AJCC has specified use of a four-tiered grading system for colorectal cancer for the 8th edition of the TNM manual.⁵ Pathologists should use the four-tier histologic grading scheme as specified above to prevent errors in data recording. As per WHO, the grading scheme applies to adenocarcinoma, not otherwise specified, and not to histologic variants. For example, medullary carcinomas behave as low grade tumors even though they may appear poorly differentiated. This grading scheme is also not applicable to poorly differentiated neuroendocrine carcinomas.

References

1. Chandler I, Houlston RS. Interobserver agreement in grading of colorectal cancers-findings from a nationwide web-based survey of histopathologists. *Histopathology*. 2008;52(4):494-499.
2. Cho YB, Chun HK, Yun HR, Kim HC, Yun SH, Lee WY. Histological grade predicts survival time associated with recurrence after resection for colorectal cancer. *Hepatogastroenterology*. 2009;56(94-95):1335-1340.
3. Derwinger K, Kodeda K, Bexe-Lindskog E, Taflin H. Tumour differentiation grade is associated with TNM staging and the risk of node metastasis in colorectal cancer. *Acta Oncol*. 2010;49(1):57-62.
4. Barresi V, Reggiani Bonetti L, Ieni A, Domati F, Tuccari G. Prognostic significance of grading based on the counting of poorly differentiated clusters in colorectal mucinous adenocarcinoma. *Hum Pathol*. 2015;46(11):1722-1729.
5. Amin MB, Edge SB, Greene FL, et al, eds. *AJCC Cancer Staging Manual*. 8th ed. New York, NY: Springer; 2017.

D. Carcinoma in an Adenomatous Polyp: Microscopic Tumor Extension and High-Risk Features

Colorectal adenomas containing invasive adenocarcinoma that extends through the muscularis mucosa into the submucosa have been defined as *malignant polyps*.¹ This term encompasses cases in which the entire polyp head is replaced by carcinoma and adenomas with focal malignancy, but the definition excludes adenomas with high-grade dysplasia or intramucosal carcinoma (invasive carcinoma limited to the lamina propria or invading no deeper than the muscularis mucosa), because these polyps possess negligible biological potential for metastasis.

Malignant polyps removed by endoscopic polypectomy require evaluation of histologic factors related to the risk of adverse outcome (ie, lymph node metastasis or local recurrence from residual malignancy) following polypectomy.^{2,3,4} Factors shown to have independent prognostic significance and are important in determining the need for further surgical treatment include:

- Histologic grade
- Status of the resection margin
- Lymphatic/venous vessel involvement

An increased risk of adverse outcome has been shown to be associated with:

- High-grade carcinoma
- Tumor at or less than 1 mm from the resection margin
- Lymphatic/venous involvement

Reporting of additional histologic factors that have been advocated for assessing risk include tumor budding (note F), depth or area of submucosal invasion. Submucosal involvement has been divided into superficial, mid and deep levels for sessile polyps (Kikuchi levels sm1, sm2 and sm3),⁵ and into four levels (head, neck, stalk and beyond stalk) in pedunculated polyps (Haggitt levels).⁶ Based on measurement, submucosal invasion more than 1mm has been recognized as an adverse prognostic factor.⁴ However, it can be difficult to accurately assess the depth or extent of submucosal involvement due to improper orientation and absence of muscularis propria in these specimens.

References

1. Chandler I, Houlston RS. Interobserver agreement in grading of colorectal cancers-findings from a nationwide web-based survey of histopathologists. *Histopathology*. 2008;52(4):494-499.
2. Cooper HS. Pathology of endoscopically removed malignant colorectal polyp. *Curr Diagn Pathol*. 2007;13(6):423-437.
3. Ueno H, Mochizuki H, Hashiguchi Y, et al. Risk factors for an adverse outcome in early invasive colorectal carcinoma. *Gastroenterology*. 2004;127(2):385-394.
4. Bosch SL, Teerenstra S, de Wilt JH, Cunningham C, Nagtegaal ID. Predicting lymph node metastasis in pT1 colorectal cancer: a systematic review of risk factors providing rationale for therapy decisions. *Endoscopy*. 2013;45(10):827-834.
5. Nascimbeni R, Burgart LJ, Nivatvongs S, Larson DR. Risk of lymph node metastasis in T1 carcinoma of the colon and rectum. *Dis Colon Rectum*. 2002;45(2):200-6.
6. Haggitt RC, Glotzbach RE, Soffer EE, Wruble LD. Prognostic factors in colorectal carcinomas arising in adenomas: implications for lesions removed by endoscopic polypectomy. *Gastroenterology*. 1985;89:328-336.

E. Lymphovascular and Perineural Invasion

It is recommended that small vessel vascular invasion should be reported separately from venous (large vessel) invasion. Small vessel invasion indicates tumor involvement of thin-walled structures lined by endothelium, without an identifiable smooth muscle layer or elastic lamina. Small vessels include lymphatics, capillaries, and postcapillary venules. Small vessel invasion is associated with lymph node metastasis and has been shown to be independent indicator of adverse outcome in several studies.^{1,2} The higher prognostic significance of extramural small vessel invasion has been suggested,³ but the importance of anatomic location in small vessel invasion (extramural or intramural) is not well defined.

Tumor involving endothelium-lined spaces with an identifiable smooth muscle layer or elastic lamina is considered venous (large vessel) invasion. Circumscribed tumor nodules surrounded by an elastic lamina on hematoxylin-eosin (H&E) or elastic stain are also considered venous invasion. Venous invasion can be extramural (beyond muscularis propria) or intramural (submucosa or muscularis propria). Extramural venous invasion has been demonstrated by multivariate analysis to be an independent adverse prognostic factor in multiple studies and is a risk factor for liver metastasis.³ The significance of intramural venous invasion is less clear. Perineural invasion has been shown to be independent indicator of poor prognosis.^{4,5,6} While some series did not find perineural invasion to be a significant predictive factor in stage II disease,^{7,8} many studies have confirmed its adverse effect on survival in stage II disease.^{2,9} Extramural perineural invasion may have a greater adverse prognostic effect,⁵ but the distinction between intramural and extramural perineural invasion has not been well studied.

References

1. Lim SB, Yu CS, Jang SJ, Kim TW, Kim JH, Kim JC. Prognostic significance of lymphovascular invasion in sporadic colorectal cancer. *Dis Colon Rectum*. 2010;53(4):377-384.
2. Santos C, López-Doriga A, Navarro M, et al. Clinicopathological risk factors of Stage II colon cancer: results of a prospective study. *Colorectal Dis*. 2013;15(4):414-422

3. Betge J, Pollheimer MJ, Lindtner RA, et al. Intramural and extramural vascular invasion in colorectal cancer: prognostic significance and quality of pathology reporting. *Cancer*. 2012;118(3):628-638.
4. Liebig C, Ayala G, Wilks J, et al. Perineural invasion is an independent predictor of outcome in colorectal cancer. *J Clin Oncol*. 2009;27(31):5131-5137.
5. Ueno H, Shirouzu K, Eishi Y, et al; Study Group for Perineural Invasion projected by the Japanese Society for Cancer of the Colon and Rectum (JSCCR). Characterization of perineural invasion as a component of colorectal cancer staging. *Am J Surg Pathol*. 2013;37(10):1542-1549
6. Gomez D, Zaitoun AM, De Rosa A, et al. Critical review of the prognostic significance of pathological variables in patients undergoing resection for colorectal liver metastases. *HPB (Oxford)*. 2014;16(9):836-844.
7. Peng SL, Thomas M, Ruszkiewicz A, Hunter A, Lawrence M, Moore J. Conventional adverse features do not predict response to adjuvant chemotherapy in stage II colon cancer. *ANZ J Surg*. 2014;84(11):837-841.
8. Ozturk MA, Dane F, Karagoz S, et al. Is perineural invasion (PN) a determinant of disease free survival in early stage colorectal cancer? *Hepatogastroenterology*. 2015;62(137):59-64
9. Huh JW, Kim HR, Kim YJ. Prognostic value of perineural invasion in patients with stage II colorectal cancer. *Ann Surg Oncol*. 2010;17(8):2066-2072.

F. Tumor Budding

The presence of single cells or small clusters of less than five cells at the advancing front of the tumor is considered as peritumoral tumor budding. Numerous studies have shown that high tumor budding in adenocarcinoma arising in polyp is a significant risk factor for nodal involvement,^{1,2,3,4,5,6} with tumor budding being the most significant factor in some studies.³ Different criteria for evaluating and reporting tumor budding have been followed in literature. An international tumor budding consensus conference (ITBCC) in 2016 recommended the following criteria for evaluating tumor budding⁷:

- (1) Tumor budding counts should be done on H&E sections. In cases of obscuring factors like inflammation, immunohistochemistry for keratin can be obtained to assess the advancing edge for tumor buds, but the scoring should be done on H&E sections.
- (2) Tumor budding should be reported by selecting a “hotspot” chosen after review of all available slides with invasive tumor. The total number of buds should be reported in an area measuring 0.785 mm², which corresponds to 20x field in some microscopes (use appropriate conversion for other microscopes, see table below).
- (3) Both total number of buds and a three-tier score (based on 0.785 mm² field area) should be reported: low (0-4 buds), intermediate (5-9 buds) and high (10 or more buds).

This is not a required element, but it is recommended that this feature be reported for cancers arising in polyps as well as for stage I and II cases.

Objective Magnification:		20		
Eyepiece FN Diameter	Eyepiece FN Radius	Specimen FN Radius	Specimen Area	Normalization Factor
(mm)	(mm)	(mm)	(mm ²)	
18	9.0	0.450	0.636	0.810
19	9.5	0.475	0.709	0.903
20	10.0	0.500	0.785	1.000
21	10.5	0.525	0.866	1.103
22	11.0	0.550	0.950	1.210
23	11.5	0.575	1.039	1.323
24	12.0	0.600	1.131	1.440
25	12.5	0.625	1.227	1.563
26	13.0	0.650	1.327	1.690

Table. ITBCC Normalization Table for Reporting Tumor Budding According to Microscope.

To obtain tumor bud count for your field of view, divide by the normalization number

References

1. Bosch SL, Teerenstra S, de Wilt JH, Cunningham C, Nagtegaal ID. Predicting lymph node metastasis in pT1 colorectal cancer: a systematic review of risk factors providing rationale for therapy decisions. *Endoscopy*. 2013;45(10):827-834.
2. Ueno H, Mochizuki H, Hashiguchi Y, et al. Risk factors for an adverse outcome in early invasive colorectal carcinoma. *Gastroenterology*. 2004 ;127(2):385-394.
3. Choi DH, Sohn DK, Chang HJ, Lim SB, Choi HS, Jeong SY. Indications for subsequent surgery after endoscopic resection of submucosally invasive colorectal carcinomas: a prospective cohort study. *Dis Colon Rectum*. 2009;52(3):438-445.
4. Petrelli F, Pezzica E, Cabiddu M, et al. Tumour Budding and Survival in Stage II Colorectal Cancer: a Systematic Review and Pooled Analysis. *J Gastrointest Cancer*. 2015;46(3):212-218.
5. Graham RP, Vierkant RA, Tillmans LS, et al. Tumor budding in colorectal carcinoma: confirmation of prognostic significance and histologic cutoff in a population-based cohort. *Am J Surg Pathol*. 2015;39(10):1340-1346
6. Koelzer VH, Zlobec I, Lugli A. Tumor budding in colorectal cancer-ready for diagnostic practice? *Hum Pathol*. 2016;47(1):4-19.
7. Lugli A, Kirsch R, Ajioka Y, Bosman F, et al. Recommendations for reporting tumor budding in colorectal cancer based on the International Tumor Budding Consensus Conference (ITBCC) 2016. *Mod Pathol*. 2017;30:1299-1311.

G. Polyps

The adenocarcinoma can arise in adenomatous (tubular, tubulovillous, or villous) or serrated (sessile serrated adenoma/polyp or traditional serrated adenoma) polyp. Sessile serrated adenoma often develops cytologic dysplasia resembling tubular adenoma during neoplastic progression. These are presumed to be the precursors of right-sided adenocarcinomas with high levels of microsatellite instability (MSI-H).¹

References

1. Rex DK, Ahnen DJ, Baron JA, et al. Serrated lesions of the colorectum: review and recommendations from an expert panel. *Am J Gastroenterol*. 2012;107(9):1315-1330.

H. Ancillary Studies

Universal testing for microsatellite instability and/or status of DNA mismatch repair enzymes by immunohistochemistry is recommended by the EGAPP guidelines.^{1,2} The NCCN guidelines also advocate this approach for patients <70 years. MSI-high cancers are associated with right-sided location, tumor infiltrating lymphocytes, Crohn-like infiltrate, pushing borders, mucinous/signet ring/medullary subtypes, intratumoral heterogeneity (mixed conventional, mucinous, and poorly differentiated carcinoma), high-grade histology, and lack of dirty necrosis.^{3,4} In view of recommendations for universal testing and chance of missing cases of Lynch syndrome with testing based on Bethesda guidelines,⁴ evaluation of histologic features associated with MSI is not required and is no longer included in the synoptic comment.

Further details about mismatch repair enzyme immunohistochemistry and PCR for MSI testing, as well as other mutation testing in colorectal cancer (such as *KRAS*, *BRAF*) can be found in the CAP Colon and Rectum Biomarkers protocol.

References

1. Evaluation of Genomic Applications in Practice and Prevention (EGAPP) Working Group. Recommendations from the EGAPP Working Group: genetic testing strategies in newly

- diagnosed individuals with colorectal cancer aimed at reducing morbidity and mortality from Lynch syndrome in relatives. *Genet Med*. 2009;11(1):35-41.
2. Ladabaum U, Wang G, et al. Strategies to identify the Lynch syndrome among patients with colorectal cancer: a cost-effectiveness analysis. *Ann Intern Med*. 2011;155(2):69-79.
 3. Greenson JK, Bonner JD, Ben-Yzhak O, et al. Phenotype of microsatellite unstable colorectal carcinomas. *Am J Surg Pathol*. 2003;27(5):563-570.
 4. Umar A, Boland CR, Terdiman JP, et al. Revised Bethesda guidelines for hereditary nonpolyposis colorectal cancer (Lynch syndrome) and microsatellite instability. *J Natl Cancer Inst*. 2004;96(4):261-268.