



Protocol for the Examination of Specimens from Patients with Well-Differentiated Neuroendocrine Tumors (Carcinoid Tumors) of the Colon and Rectum

Version: 5.0.0.0

Protocol Posting Date: December 2023

CAP Laboratory Accreditation Program Protocol Required Use Date: September 2024

The changes included in this current protocol version affect accreditation requirements. The new deadline for implementing this protocol version is reflected in the above accreditation date.

For accreditation purposes, this protocol should be used for the following procedures AND tumor types:

Procedure	Description
Resection	Includes specimens designated as low anterior resection and abdominoperineal resection, total, partial, or segmental resection
Tumor Type	Description
Well-differentiated neuroendocrine tumor	

This protocol is NOT required for accreditation purposes for the following:

Procedure
Biopsy
Excision biopsy (transanal disk excision or polypectomy)
Primary resection specimen with no residual cancer (e.g., following neoadjuvant therapy)
Recurrent tumor
Cytologic specimens

The following tumor types should NOT be reported using this protocol:

Tumor Type
Poorly-differentiated neuroendocrine carcinoma including small cell and large cell neuroendocrine carcinoma (consider the Colon and Rectum Carcinoma protocol)
Other epithelial carcinoma of the colon and rectum including mixed neuroendocrine-non-neuroendocrine neoplasm (consider the Colon and Rectum Carcinoma protocol)
Gastrointestinal stromal tumor (consider the GIST protocol)
Non-GIST sarcoma (consider the Soft Tissue protocol)

Authors

Dhanpat Jain, MD*; William V. Chopp, MD*; Rondell P. Graham, MBBS*.

With guidance from the CAP Cancer and CAP Pathology Electronic Reporting Committees.

* Denotes primary author.

Accreditation Requirements

This protocol can be utilized for a variety of procedures and tumor types for clinical care purposes. For accreditation purposes, only the definitive primary cancer resection specimen is required to have the core and conditional data elements reported in a synoptic format.

- Core data elements are required in reports to adequately describe appropriate malignancies. For accreditation purposes, essential data elements must be reported in all instances, even if the response is “not applicable” or “cannot be determined.”
- Conditional data elements are only required to be reported if applicable as delineated in the protocol. For instance, the total number of lymph nodes examined must be reported, but only if nodes are present in the specimen.
- Optional data elements are identified with “+” and although not required for CAP accreditation purposes, may be considered for reporting as determined by local practice standards.

The use of this protocol is not required for recurrent tumors or for metastatic tumors that are resected at a different time than the primary tumor. Use of this protocol is also not required for pathology reviews performed at a second institution (i.e., secondary consultation, second opinion, or review of outside case at second institution).

Synoptic Reporting

All core and conditionally required data elements outlined on the surgical case summary from this cancer protocol must be displayed in synoptic report format. Synoptic format is defined as:

- Data element: followed by its answer (response), outline format without the paired Data element: Response format is NOT considered synoptic.
- The data element should be represented in the report as it is listed in the case summary. The response for any data element may be modified from those listed in the case summary, including “Cannot be determined” if appropriate.
- Each diagnostic parameter pair (Data element: Response) is listed on a separate line or in a tabular format to achieve visual separation. The following exceptions are allowed to be listed on one line:
 - Anatomic site or specimen, laterality, and procedure
 - Pathologic Stage Classification (pTNM) elements
 - Negative margins, as long as all negative margins are specifically enumerated where applicable
- The synoptic portion of the report can appear in the diagnosis section of the pathology report, at the end of the report or in a separate section, but all Data element: Responses must be listed together in one location

Organizations and pathologists may choose to list the required elements in any order, use additional methods in order to enhance or achieve visual separation, or add optional items within the synoptic report. The report may have required elements in a summary format elsewhere in the report IN ADDITION TO but not as replacement for the synoptic report ie, all required elements must be in the synoptic portion of the report in the format defined above.

Summary of Changes

v 5.0.0.0

- Update to AJCC Version 9 pTNM Staging Classifications
- WHO 5th Edition update to content and explanatory notes
- “Lymphovascular Invasion” question updated to “Lymphatic and/or Vascular Invasion”

Reporting Template**Protocol Posting Date: December 2023****Select a single response unless otherwise indicated.****CASE SUMMARY: (COLON AND RECTUM NEUROENDOCRINE TUMOR)****Standard(s):** AJCC-UICC 9*This case summary is recommended for reporting local excision and polypectomy specimens, but is not required for accreditation purposes.***SPECIMEN (Note [A](#))****Procedure**

- Right hemicolectomy
 Transverse colectomy
 Left hemicolectomy
 Sigmoidectomy
 Low anterior resection
 Total abdominal colectomy
 Abdominoperineal resection
 Transanal disk excision / Endoscopic mucosal resection (local excision)
 Endoscopic mucosal dissection (local excision)
 Polypectomy
 Other (specify): _____
 Not specified

TUMOR**Tumor Site (Note [B](#)) (select all that apply)**

- Cecum: _____
 Right (ascending) colon: _____
 Hepatic flexure: _____
 Transverse colon: _____
 Splenic flexure: _____
 Left (descending) colon: _____
 Sigmoid colon: _____
 Rectosigmoid junction: _____
 Rectum: _____
 Ileocecal valve: _____
 Colon, not otherwise specified: _____
 Cannot be determined (explain): _____

Histologic Type and Grade# (Notes [C,D](#))*# For poorly differentiated neuroendocrine carcinomas, the College of American Pathologists (CAP) checklist for carcinoma of the colon and rectum should be used.*

- G1, well-differentiated neuroendocrine tumor
 G2, well-differentiated neuroendocrine tumor
 G3, well-differentiated neuroendocrine tumor
 GX, grade cannot be assessed

___ Other (specify): _____

___ Not applicable: _____

+Histologic Type and Grade Comment: _____

Histologic Grade Determination (Note D)

Mitotic rate and / or Ki-67 labeling index is required to determine histologic grade

Mitotic Rate (required only when Ki-67 labeling index is not reported)#

Mitotic rate should be reported as number of mitoses per 2 mm², by evaluating at least 10 mm² in the most mitotically active part of the tumor (e.g., if using a microscope with a field diameter of 0.55 mm, count 42 high power fields (10 mm²) and divide the resulting number of mitoses by 5 to determine the number of mitoses per 2 mm² needed to assign tumor grade).

___ Not applicable (Ki-67 labeling index is reported)

___ Specify number of mitoses per 2 mm²: _____ mitoses per 2 mm²

___ Less than 2 mitoses per 2 mm²

___ 2 to 20 mitoses per 2 mm²

___ Greater than 20 mitoses per 2 mm²

___ Cannot be determined (explain): _____

Ki-67 Labeling Index (required only when mitotic rate is not reported)

___ Not applicable (mitotic rate is reported)

___ Specify Ki-67 percentage: _____ %

___ Less than 3%

___ 3% to 20%

___ Greater than 20%

___ Cannot be determined (explain): _____

Tumor Size (Note E)

___ Greatest dimension in Centimeters (cm) (specify size of largest tumor if multiple tumors are present):
_____ cm

+Additional Dimension in Centimeters (cm): ___ x ___ cm

___ Cannot be determined (explain): _____

Tumor Focality

___ Unifocal

___ Multifocal

Number of Tumors

___ Specify number: _____

___ Other (specify): _____

___ Cannot be determined: _____

___ Cannot be determined: _____

Multiple Primary Sites (e.g., hepatic flexure and transverse colon)

___ Not applicable (no additional primary site(s) present)

___ Present: _____

Please complete a separate checklist for each primary site

Tumor Extent

___ Invades lamina propria

___ Invades submucosa

___ Invades muscularis propria

- Invades through muscularis propria into subserosal tissue without penetration of overlying serosa
- Invades visceral peritoneum (serosa)
- Invades other organ(s) or adjacent structure(s) (specify): _____
- Cannot be determined: _____
- No evidence of primary tumor

Lymphatic and / or Vascular Invasion (Note [F](#))

- Not identified
- Present
- Cannot be determined: _____

+Perineural Invasion

- Not identified
- Present
- Cannot be determined: _____

+Tumor Comment: _____

MARGINS (Note [G](#))

Margin Status

- All margins negative for tumor
- +Closest Margin(s) to Tumor (select all that apply)**
- Proximal: _____
- Distal: _____
- Radial: _____
- Mesenteric: _____
- Mucosal: _____
- Deep: _____
- Other (specify): _____
- Cannot be determined: _____

+Distance from Tumor to Closest Margin

Specify in Centimeters (cm)

Exact distance in cm: _____ cm

Greater than 1 cm

Specify in Millimeters (mm)

Exact distance in mm: _____ mm

Greater than 10 mm

Other

Other (specify): _____

Cannot be determined: _____

Tumor present at margin

Margin(s) Involved by Tumor (select all that apply)

- Proximal: _____
- Distal: _____
- Radial: _____
- Mesenteric: _____
- Mucosal: _____

- Deep: _____
- Other (specify): _____
- Cannot be determined: _____
- Other (specify): _____
- Cannot be determined (explain): _____
- Not applicable

+Margin Comment: _____

REGIONAL LYMPH NODES

Regional Lymph Node Status

- Not applicable (no regional lymph nodes submitted or found)
- Regional lymph nodes present
 - All regional lymph nodes negative for tumor
 - Tumor present in regional lymph node(s)

Number of Lymph Nodes with Tumor

- Exact number (specify): _____
- At least (specify): _____
- Other (specify): _____
- Cannot be determined (explain): _____
- Other (specify): _____
- Cannot be determined (explain): _____

Number of Lymph Nodes Examined

- Exact number (specify): _____
- At least (specify): _____
- Other (specify): _____
- Cannot be determined (explain): _____

+Regional Lymph Node Comment: _____

DISTANT METASTASIS

Distant Site(s) Involved, if applicable (select all that apply)

- Not applicable
- Liver: _____
- Lung: _____
- Ovary: _____
- Nonregional lymph node(s): _____
- Peritoneum: _____
- Bone: _____
- Other (specify): _____
- Cannot be determined: _____

pTNM CLASSIFICATION (AJCC Version 9) (Note H)

Reporting of pT, pN, and (when applicable) pM categories is based on information available to the pathologist at the time the report is issued. As per the AJCC (Chapter 1, 8th Ed.) it is the managing physician's responsibility to establish the final pathologic stage based upon all pertinent information, including but potentially not limited to this pathology report.

Modified Classification (required only if applicable) (select all that apply)

- Not applicable
 y (post-neoadjuvant therapy)
 r (recurrence)

pT Category#

Multiple tumors should be designated as such (the largest tumor should be used to assign T category). Use T(#); e.g., pT3(4) N0 M0, OR use the m suffix, T(m); e.g., pT3(m) N0 M0.

- pT not assigned (cannot be determined based on available pathological information)
 pT0: No evidence of primary tumor
pT1: Tumor invades the mucosa or submucosa, and is less than or equal to 2 cm in greatest dimension
 pT1a: Tumor is less than or equal to 1 cm in greatest dimension
 pT1b: Tumor is greater than 1 cm but less than or equal to 2 cm in greatest dimension
 pT1 (subcategory cannot be determined)
 pT2: Tumor invades the muscularis propria, or is greater than 2 cm in greatest dimension with invasion of the mucosa or submucosa
 pT3: Tumor invades through the muscularis propria into subserosal tissue without penetration of overlying serosa
 pT4: Tumor invades the visceral peritoneum (serosa), or other organs or adjacent structures

T Suffix (required only if applicable)

- Not applicable
 (m) multiple primary synchronous tumors in a single organ

pN Category

- pN not assigned (no nodes submitted or found)
 pN not assigned (cannot be determined based on available pathological information)
 pN0: No tumor involvement of regional lymph node(s)
 pN1: Tumor involvement of regional lymph node(s)

pM Category (required only if confirmed pathologically)

- Not applicable - pM cannot be determined from the submitted specimen(s)
pM1: Microscopic confirmation of distant metastasis
 pM1a: Microscopic confirmation of metastasis confined to liver
 pM1b: Microscopic confirmation of metastasis in at least one extrahepatic site (e.g., lung, ovary, nonregional lymph node, peritoneum, bone)
 pM1c: Microscopic confirmation of both hepatic and extrahepatic metastases
 pM1 (subcategory cannot be determined)

ADDITIONAL FINDINGS (Note !)**+Additional Findings (select all that apply)**

- None identified
 Tumor necrosis
 Other (specify): _____

CAP Approved

ColoRectal.NET_5.0.0.0.REL_CAPCP

COMMENTS

Comment(s): _____

Explanatory Notes

A. Application and Tumor Location

This protocol applies to well-differentiated neuroendocrine tumors (carcinoid tumors) of the colon and rectum. Poorly differentiated neuroendocrine carcinomas (including small cell carcinomas and large cell neuroendocrine carcinomas) and tumors with mixed glandular/neuroendocrine differentiation are not included.¹

Because of site-specific similarities in histology, immunohistochemistry, and histochemistry, neuroendocrine tumors of the digestive tract have traditionally been subdivided into those of foregut, midgut, and hindgut origin (Table 1). In general, the distribution pattern along the gastrointestinal (GI) tract parallels that of the progenitor cell type, and the anatomic site of origin of GI neuroendocrine tumors is an important predictor of clinical behavior.²

Table 1. Site of Origin of Gastrointestinal Neuroendocrine Tumors

	Foregut Tumors	Midgut Tumors	Hindgut Tumors
<u>Site</u>	<u>Stomach, Proximal Duodenum</u>	<u>Jejunum, Ileum, Appendix, Proximal Colon</u>	<u>Distal Colon, Rectum</u>
Immunohistochemistry			
Chromogranin A	86%-100% +	82%-92% +	40%-58% +
Synaptophysin	50% +	95%-100% +	94%-100% +
Serotonin	33% + ³	86% + ³	45%-83% + ^{3,4,5,6,7}
Other Immunohistochemical Markers	Rarely, + for pancreatic polypeptide, histamine, gastrin, vasoactive intestinal peptide (VIP), or adrenocorticotrophic hormone (ACTH)	Prostatic acid phosphatase + in 20%-40% ^{8,9}	Prostatic acid phosphatase + in 20%-82% ^{3,4,5,6,7,8,9}
Carcinoid syndrome	Rare	5%-39% ^{10,11}	Rare

References

- Burghart LJ, Chopp WV, Jain D. Protocol for the Examination of Specimens From Patients With Primary Carcinoma of the Colon and Rectum. 2021. Available at www.cap.org/cancerprotocols.
- Rorstad O. Prognostic indicators for carcinoid neuroendocrine tumors of the gastrointestinal tract. *J Surg Oncol*. 2005;89(3):151-160.
- Eckhauser FE, Argenta LC, Strodel WE, et al. Mesenteric angiopathy, intestinal gangrene, and midgut carcinoids. *Surgery*. 1981;90(4):720-728.
- Modlin IM, Lye KD, Kidd M. A 5-decade analysis of 13,715 carcinoid tumors. *Cancer*. 2003;97(4):934-959.
- Graeme-Cook F. Neuroendocrine tumors of the GI tract and appendix. In: Odze RD, Goldblum JR, Crawford JM, eds. *Surgical Pathology of the GI Tract, Liver, Biliary Tract, and Pancreas*. Philadelphia, PA: Saunders; 2004: 483-504.
- Anlauf M, Garbrecht N, Henopp T, et al. Sporadic versus hereditary gastrinomas of the duodenum and pancreas: distinct clinico-pathological and epidemiological features. *World J Gastroenterol*. 2006;12(34):5440-5446.
- Eckhauser FE, Argenta LC, Strodel WE, et al. Mesenteric angiopathy, intestinal gangrene, and midgut carcinoids. *Surgery*. 1981;90(4):720-728.

8. Kimura N, Sasano N. Prostate-specific acid phosphatase in carcinoid tumors. *Virchows Arch A Pathol Anat Histopathol*. 1986;410(3):247-251.
9. Nash SV, Said JW. Gastroenteropancreatic neuroendocrine tumors: a histochemical and immunohistochemical study of epithelial (keratin proteins, carcinoembryonic antigen) and neuroendocrine (neuron-specific enolase, bombesin and chromogranin) markers in foregut, midgut, and hindgut tumors. *Am J Clin Pathol*. 1986;86(2):415-422.
10. Williams GT. Endocrine tumours of the gastrointestinal tract: selected topics. *Histopathology*. 2007;50(1):30-41.
11. Garbrecht N, Anlauf M, Schmitt A, et al. Somatostatin-producing neuroendocrine tumors of the duodenum and pancreas: incidence, types, biological behavior, association with inherited syndromes, and functional activity. *Endocr Rel Cancer*. 2008;15(1):229-241.

B. Site-Specific Features

Rectal neuroendocrine tumors are not uncommon, constitute approximately one-quarter of GI neuroendocrine tumors.¹ They are usually small, solitary, and clinically silent, most commonly occurring 4 cm to 13 cm from the anal verge. Mitotically inactive rectal neuroendocrine tumors or those smaller than 2.0 cm are almost always clinically indolent.² Metastases and carcinoid syndrome are very rare. L-cell NETs are usually seen in the rectum. Colonic neuroendocrine tumors outside the ileocecal region and rectum are extremely rare; most are large, bulky, highly invasive tumors that are metastatic at presentation. Two-thirds of them arise within the cecum or right colon. Many well-differentiated neuroendocrine tumors involving the ileocecal valve represent tumors arising in the terminal ileum, rather than in the large bowel. Colonic tumors are biologically more aggressive and similar to jejunoileal tumors, while rectal tumors are more indolent.³

References

1. Modlin IM, Lye KD, Kidd M. A 5-decade analysis of 13,715 carcinoid tumors. *Cancer*. 2003;97(4):934-959.
2. Soga J. Carcinoids of the colon and ileocecal region: a statistical evaluation of 363 cases collected from the literature. *J Exp Clin Cancer Res*. 1998;17(2):139-148
3. AJCC Version 9 Neuroendocrine Tumors of the Colon and Rectum Cancer Staging System. Copyright 2023 American College of Surgeons.

C. Histologic Type

The World Health Organization (WHO) classifies neuroendocrine neoplasms as well-differentiated neuroendocrine tumors (either the primary tumor or metastasis) and poorly differentiated neuroendocrine carcinomas.^{1,2,3,4} Historically, well-differentiated neuroendocrine tumors have been referred to as “carcinoid” tumors, a term which may cause confusion because clinically a carcinoid tumor is a serotonin-producing tumor associated with functional manifestations of carcinoid syndrome. The use of the term “carcinoid” for neuroendocrine tumor reporting is therefore discouraged for these reasons.

Classification of neuroendocrine tumors is based upon size, functionality, site, and invasion. Functioning tumors are those associated with clinical manifestations of hormone production or secretion of measurable amounts of active hormone; immunohistochemical demonstration of hormone production is not equivalent to clinically apparent functionality.

Similar to appendix, colorectal neuroendocrine tumors composed of L-cell have been considered of low malignant potential and represent most (60-80%) of the rectal tumors.⁵ Immunohistochemistry for glucagon like peptide 1 or peptide YY that identifies these tumors is not widely available and is not

recommended for routine clinical practice. These tumors can be negative for chromogranin, which is a known diagnostic pitfall and use of other additional endocrine markers is suggested in suspected cases. Studies suggest that L-cell phenotype is associated with lower histologic grade, smaller tumor size, and lower T-stage, as well as absence of LVI, nodal metastasis and distant metastasis.^{6,7}

Although specific histologic patterns in well-differentiated neuroendocrine tumors, such as trabecular, insular, and glandular, roughly correlate with tumor location,⁸ these patterns have not been clearly shown independently to predict response to therapy or risk of nodal metastasis and are rarely reported in clinical practice. Immunohistochemistry and other ancillary techniques are generally not required to diagnose well-differentiated neuroendocrine tumors. Specific markers that may be used to establish neuroendocrine differentiation include chromogranin A, synaptophysin, INSM1, and CD56.^{3,9,10} Because of their relative sensitivity and specificity, chromogranin A and synaptophysin are recommended, although INSM1 is also emerging as a good marker for endocrine differentiation. It should be noted that hindgut neuroendocrine tumors often do not express appreciable amounts of chromogranin A. Rectal neuroendocrine tumors express prostatic acid phosphatase, a potential diagnostic pitfall for tumors arising in male patients.¹¹

References

1. Graeme-Cook F. Neuroendocrine tumors of the GI tract and appendix. In: Odze RD, Goldblum JR, Crawford JM, eds. *Surgical Pathology of the GI Tract, Liver, Biliary Tract, and Pancreas*. Philadelphia, PA: Saunders; 2004:483-504.
2. WHO Classification of Tumours Editorial Board. *Digestive system tumours*. Lyon (France): International Agency for Research on Cancer; 2019. (WHO classification of tumours series, 5th ed.; vol. 1).
3. Williams GT. Endocrine tumours of the gastrointestinal tract: selected topics. *Histopathology*. 2007;50(1):30-41.
4. Kloppel G, Perren A, Heitz PU. The gastroenteropancreatic neuroendocrine cell system and its tumors: the WHO classification. *Ann N Y Acad Sci*. 2004;1014:13-27.
5. AJCC Version 9 Neuroendocrine Tumors of the Colon and Rectum Cancer Staging System. Copyright 2023 American College of Surgeons.
6. Kim, J. Y., K. S. Kim, K. J. Kim, I. J. Park, J. L. Lee, S. J. Myung, Y. Park, et al. 'Non-L-Cell Immunophenotype and Large Tumor Size in Rectal Neuroendocrine Tumors Are Associated with Aggressive Clinical Behavior and Worse Prognosis.' *Am J Surg Pathol* 39, no. 5 (May 2015): 632-43.
7. Kim, J., D. H. Yang, H. Jung, H. Cho, H. J. Jang, C. Yoo, I. J. Park, et al. 'Clinicopathologic Impact of Peptide Hormonal Expression in Rectal Neuroendocrine Tumors.' *Arch Pathol Lab Med* 147, no. 7 (Jul 1 2023): 797-807. Zhang Q, Huang J, He Y, Cao R, Shu J. Insulinoma-associated protein 1(INSM1) is a superior marker for the diagnosis of gastroenteropancreatic neuroendocrine neoplasms: a meta-analysis. *Endocrine*. 2021;74(1):61-71.
8. Soga J. Carcinoids of the colon and ileocecal region: a statistical evaluation of 363 cases collected from the literature. *J Exp Clin Cancer Res*. 1998;17(2):139-148.
9. Zhang Q, Huang J, He Y, Cao R, Shu J. Insulinoma-associated protein 1(INSM1) is a superior marker for the diagnosis of gastroenteropancreatic neuroendocrine neoplasms: a meta-analysis. *Endocrine*. 2021;74(1):61-71.
10. McHugh KE, Mukhopadhyay S, Doxtader EE, Lanigan C, Allende DS. INSM1 Is a Highly Specific Marker of Neuroendocrine Differentiation in Primary Neoplasms of the Gastrointestinal Tract, Appendix, and Pancreas. *Am J Clin Pathol*. 2020;153(6):811-20.

11. Sobin LH, Hjermsstad BM, Sesterhenn IA, Helwig EB. Prostatic acid phosphatases activity in carcinoid tumors. *Cancer*. 1986;58(1):136-138.

D. Histologic Grade

Cytologic atypia in well-differentiated neuroendocrine tumors has no impact on clinical behavior of these tumors. The WHO classification¹ and others² use mitotic rate and/or Ki-67 index as one of the criteria for potential for aggressive behavior. Mitotic rate should be reported as number of mitoses per 2 mm², by evaluating at least 10 mm² in the most mitotically active part of the tumor. Only clearly identifiable mitotic figures should be counted; hyperchromatic, karyorrhectic, or apoptotic nuclei are excluded. Because of variations in field size, the number of high-power fields (HPF) (at 40X magnification) for 10 mm² (thereby 2 mm²) must be determined for each microscope (Table 2). For example, if using a microscope with a field diameter of 0.55 mm, count 42 HPF and divide the resulting number of mitoses by 5 to determine the number of mitoses per 2 mm² needed to assign tumor grade.

Table 2. Number of HPF Required for 10mm² Using Microscopes with Different Field Diameters

Field Diameter (mm)	Area (mm ²)	Number of HPF for 10 mm ²
0.40	0.125	80
0.41	0.132	75
0.42	0.139	70
0.43	0.145	69
0.44	0.152	65
0.45	0.159	63
0.46	0.166	60
0.47	0.173	58
0.48	0.181	55
0.49	0.189	53
0.50	0.196	50
0.51	0.204	49
0.52	0.212	47
0.53	0.221	45
0.54	0.229	44
0.55	0.238	42
0.56	0.246	41
0.57	0.255	39
0.58	0.264	38
0.59	0.273	37
0.60	0.283	35
0.61	0.292	34
0.62	0.302	33
0.63	0.312	32
0.64	0.322	31
0.65	0.332	30
0.66	0.342	29
0.67	0.353	28
0.68	0.363	28
0.69	0.374	28

Ki-67 index is reported as percent positive tumor cells in area of highest nuclear labeling (“hot spot”), although the precise method of assessment has not been standardized. A number of methods have used to assess Ki-67 index, including automatic counting and “eyeballing”.^{3,4} Automated counting is not widely available and requires careful modification of the software to circumvent the inaccuracies.³ Eye-balling can be used for most tumors; however, for tumors with Ki-67 index close to grade cut-offs, it is recommended to perform the manual count on the print of camera-captured image of the hot spot. It has been recommended that a minimum of 500 tumor cells be counted to determine the Ki-67 index and a notation is made if less cells are available. Grade assigned based on Ki-67 index is typically higher than that based on mitotic count, and the case is assigned to the higher of the 2 if both methods are performed.¹

Similar to other sites, histologic grade remains prognostically important for colorectal tumors. Even in low risk tumors (≤ 2 cm or even ≤ 1 cm) tumor that metastasize are invariably G2 tumors.^{5,6} It is also important to note that there are a small group of well-differentiated neuroendocrine tumors with a Ki-67 index $>20\%$ and a mitotic rate usually <20 per 10 HPF. In WHO-2010, these tumors were considered as G3 poorly differentiated neuroendocrine carcinomas. However, they have typical morphology of well-differentiated tumors. Previous studies (most on pancreatic neuroendocrine tumors) have demonstrated that these tumors have a worse prognosis than grade 2 (Ki-67=3-20 % and mitosis $<20/10$ HPF) neuroendocrine tumors, but they are not as aggressive as poorly differentiated neuroendocrine carcinomas.⁷ In addition, these tumors do not have the genetic abnormalities seen in poorly differentiated neuroendocrine carcinomas.⁸ Furthermore, unlike poorly differentiated neuroendocrine carcinomas, they are less responsive to platinum-based chemotherapy.⁹ In WHO-2019 blue book of digestive system tumors and AJCC version 9, those with typical morphology of well-differentiated tumors are classified as “well-differentiated neuroendocrine tumor” but as grade 3 (Table 3) and are increasingly being recognized at all sites.^{10,11}

Table 3. Recommended Grading System for Well-Differentiated Gastroenteropancreatic Neuroendocrine Tumors

Grade	Mitotic Rate (per 2mm)	Ki-67 index (%)
Well-differentiated neuroendocrine tumor, G1	<2	<3
Well-differentiated neuroendocrine tumor, G2	2-20	3-20
Well-differentiated neuroendocrine tumor, G3	>20	>20

References

1. WHO Classification of Tumours Editorial Board. *Digestive system tumours*. Lyon (France): International Agency for Research on Cancer; 2019. (WHO classification of tumours series, 5th ed.; vol. 1).
2. Rindi G, Kloppel G, Couvelard A, et al. TNM staging of midgut and hindgut (neuro) endocrine tumors: a consensus proposal including a grading system. *Virchows Arch*. 2007;451(4):757-762.
3. Tang LH, Gonen M, Hedvat C, Modlin I, Klimstra DS. Objective quantification of the Ki67 proliferative index in neuroendocrine tumors of gastroenteropancreatic system: a comparison of digital image analysis with manual methods. *Am J Surg Pathol*. 2012;36(12):1761-1770.
4. Reid MD, Bagci P, Ohike N, et al. Calculation of the Ki67 index in pancreatic neuroendocrine tumors: a comparative analysis of four counting methodologies. *Mod Pathol*. 2016;29(1):93.
5. Kuiper T, van Oijen MGH, van Velthuysen MF, van Lelyveld N, van Leerdam ME, Vleggaar FD, et al. Endoscopically removed rectal NETs: a nationwide cohort study. *Int J Colorectal Dis*. 2021;36(3):535-41.

6. Folkert IW, Sinnamon AJ, Concors SJ, Bennett BJ, Fraker DL, Mahmoud NN, et al. Grade is a Dominant Risk Factor for Metastasis in Patients with Rectal Neuroendocrine Tumors. *Ann Surg Oncol*. 2020;27(3):855-63.
7. Shi C, Klimstra DS. Pancreatic neuroendocrine tumors: pathologic and molecular characteristics. *Semin Diagn Pathol*. 2014;31(6):498-511.
8. Yachida S, Vakiani E, White CM, et al. Small cell and large cell neuroendocrine carcinomas of the pancreas are genetically similar and distinct from well-differentiated pancreatic neuroendocrine tumors. *Am J Surg Pathol*. 2012;36(2):173-84.
9. Sorbye H, Strosberg J, Baudin E, Klimstra DS, Yao JC. Gastroenteropancreatic high-grade neuroendocrine carcinoma. *Cancer*. 2014;120(18):2814-2823
10. AJCC Version 9 Neuroendocrine Tumors of the Colon and Rectum Cancer Staging System. Copyright 2023 American College of Surgeons.
11. Yuan H, Yang Y, Wang W, Cheng Y. A case report of neuroendocrine tumor (G3) at lower rectum with liver metastasis. *Medicine (Baltimore)*. 2018;97(38):e12423.

E. Tumor Size

For neuroendocrine tumors in any part of the gastrointestinal tract, size greater than 2.0 cm is associated with a higher risk of lymph node metastasis. Rectal carcinoids smaller than 1.0 cm are almost always clinically indolent, and local excision is generally considered sufficient for tumors 1.0 cm or smaller, as well as many tumors between 1.0 cm and 2.0 cm. Metastasis in tumors ≤ 2 cm is uncommon, and those that metastasize tend to be histologically higher grade ($>G1$).¹ More extensive procedures (e.g., right hemicolectomy and abdominoperineal resection) are usually reserved for patients with rectal tumors larger than 2.0 cm, rectal tumors with regional metastasis, and most colonic neuroendocrine tumors.

Determination of size remains of colorectal tumors on resection specimens, including local excision, is performed similar to any other tumor. However, many of the rectal tumors are detected incidentally on biopsies or on digital rectal examination. In such situations, the size and depth of invasion are assessed clinically based on imaging, especially endoscopic ultrasound that has been shown to be highly sensitive for lesions between 0.5-2 cm, and can detect lesions as small as 0.2cm. Staging examinations using imaging (CT or MRI) are typically performed in tumors ≥ 1 cm or higher grade tumors ($>G1$).²

References

1. Kuiper T, van Oijen MGH, van Velthuysen MF, van Lelyveld N, van Leerdam ME, Vleggaar FD, et al. Endoscopically removed rectal NETs: a nationwide cohort study. *Int J Colorectal Dis*. 2021;36(3):535-41.
2. AJCC Version 9 Neuroendocrine Tumors of the Colon and Rectum Cancer Staging System. Copyright 2023 American College of Surgeons.

F. Lymphatic and/or Vascular Invasion

Lymphovascular invasion (LVI) has been associated recurrence and nodal metastasis.^{1,2} Studies show that LVI correlated with larger tumor size (>0.5 cm), but not grade and use of vascular endothelial immunohistochemical markers can enhance their detection.³ However, the overall risk of recurrence at 5-years is so low that in the absence of any other high-risk features follow-up rather than radical resection has been suggested.³

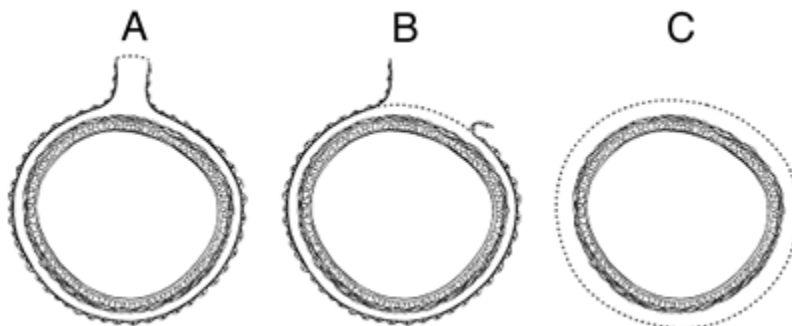
References

1. Kojima M, Ikeda K, Saito N, Sakuyama N, Koushi K, Kawano S, et al. Neuroendocrine Tumors of the Large Intestine: Clinicopathological Features and Predictive Factors of Lymph Node Metastasis. *Front Oncol.* 2016;6:173.
2. Ricci AD, Pusceddu S, Panzuto F, Gelsomino F, Massironi S, De Angelis CG, et al. Assessment of the Risk of Nodal Involvement in Rectal Neuroendocrine Neoplasms: The NOVARA Score, a Multicentre Retrospective Study. *J Clin Med.* 2022;11(3).
3. Kang HS, Kwon MJ, Kim TH, Han J, Ju YS. Lymphovascular invasion as a prognostic value in small rectal neuroendocrine tumor treated by local excision: A systematic review and meta-analysis. *Pathol Res Pract.* 2019;215(11):152642.

G. Surgical Resection Margin

For resection specimens, in addition to addressing the proximal and distal margins, assessment of the circumferential (radial) margin is necessary for any segment of gastrointestinal tract either unencased (Figure C) or incompletely encased by peritoneum (Figure B). The circumferential margin represents the adventitial soft-tissue margin closest to the deepest penetration of tumor and is created surgically by blunt or sharp dissection of the retroperitoneal or subperitoneal aspect, respectively. The distance between the tumor and circumferential (radial) margin should be reported, if applicable. The circumferential (radial) margin is considered positive if the tumor is present at the nonperitonealized surface. This assessment includes tumor within a lymph node as well as direct tumor extension, but if circumferential (radial) margin positivity is based solely on intranodal tumor, this should be so stated. The mesenteric resection margin is the only relevant circumferential margin in segments completely encased by peritoneum (e.g., transverse colon) (Figure A). Involvement of this margin should be reported even if tumor does not penetrate the serosal surface.

For local excisions (endoscopic mucosal resections/ transanal disc excisions/ submucosal dissection), reliable assessment is only possible for specimens that are removed without any fragmentation. In such specimens, lateral mucosal and deep margins should be assessed and reported. However, incomplete removal of rectal NETs, especially with conventional EMR, is not infrequent.^{1,2,3} Positive margins in some studies have been associated with local recurrence and nodal metastasis, although the vast majority of patients with positive margins neither recur nor progress.^{4,5} The overall risk of recurrence or progression in these patients remains very low, and studies show no difference in risk of recurrence or survival in patients with positive margins who underwent salvage local resections versus those who opted for only follow-up.⁵



A: Mesenteric margin in viscus completely encased by peritoneum (dotted line). **B:** Circumferential (radial) margin (dotted line) in viscus incompletely encased by peritoneum. **C:** Circumferential (radial) margin (dotted line) in viscus completely unencased by peritoneum.

References

1. Kuiper T, van Oijen MGH, van Velthuysen MF, van Lelyveld N, van Leerdam ME, Vleggaar FD, et al. Endoscopically removed rectal NETs: a nationwide cohort study. *Int J Colorectal Dis.* 2021;36(3):535-41.
2. Kamigaichi Y, Yamashita K, Oka S, Tamari H, Shimohara Y, Nishimura T, et al. Clinical outcomes of endoscopic resection for rectal neuroendocrine tumors: Advantages of endoscopic submucosal resection with a ligation device compared to conventional EMR and ESD. *DEN Open.* 2022;2(1):e35.
3. Fine C, Roquin G, Terrebbonne E, Lecomte T, Coriat R, Do Cao C, et al. Endoscopic management of 345 small rectal neuroendocrine tumours: A national study from the French group of endocrine tumours (GTE). *United European Gastroenterol J.* 2019;7(8):1102-12.
4. Cha B, Shin J, Ko WJ, Kwon KS, Kim H. Prognosis of incompletely resected small rectal neuroendocrine tumor using endoscope without additional treatment. *BMC Gastroenterol.* 2022;22(1):293
5. Sun D, Ren Z, Xu E, Cai S, Qi Z, Chen Z, et al. Long-term clinical outcomes of endoscopic submucosal dissection in rectal neuroendocrine tumors based on resection margin status: a real-world study. *Surg Endosc.* 2023;37(4):2644-52.

H. pTNM Classification

The TNM staging system for neuroendocrine tumors of the colon and rectum of the American Joint Committee on Cancer (AJCC) and the International Union Against Cancer (UICC) is recommended.^{1,2} By AJCC/UICC convention, the designation “T” refers to a primary tumor that has not been previously treated. The symbol “p” refers to the pathologic classification of the TNM, as opposed to the clinical classification, and is based on gross and microscopic examination. pT entails resection of the primary tumor or biopsy adequate to evaluate the highest pT category, pN entails removal of nodes adequate to validate lymph node metastasis, and pM implies microscopic examination of distant lesions. Clinical classification (cTNM) is usually carried out by the referring physician before treatment, during initial evaluation of the patient, or when pathologic classification is not possible.

Pathologic staging is usually performed after surgical resection of the primary tumor. Pathologic staging depends on pathologic documentation of the anatomic extent of disease, whether or not the primary tumor has been completely removed. If a biopsied tumor is not resected for any reason (e.g., when technically unfeasible) and if the highest T and N categories or the M1 category of the tumor can be confirmed microscopically, the criteria for pathologic classification and staging have been satisfied without total removal of the primary cancer.

TNM Descriptors

For identification of special cases of TNM or pTNM classifications, the “m” suffix and “y,” “r,” and “a” prefixes are used. Although they do not affect the stage grouping, they indicate cases needing separate analysis.

The “m” suffix indicates the presence of multiple primary tumors in a single site and is recorded in parentheses: pT(m)NM.

The “y” prefix indicates those cases in which classification is performed during or following initial multimodality therapy (i.e., neoadjuvant chemotherapy, radiation therapy, or both chemotherapy and radiation therapy). The cTNM or pTNM category is identified by a “y” prefix. The ycTNM or ypTNM categorizes the extent of tumor actually present at the time of that examination. The “y” categorization is not an estimate of tumor prior to multimodality therapy (i.e., before initiation of neoadjuvant therapy).

The “r” prefix indicates a recurrent tumor when staged after a documented disease-free interval and is identified by the “r” prefix: rTNM.

The “a” prefix designates the stage determined at autopsy: aTNM.

N Category Considerations

The regional lymph nodes of the colon and rectum are as follows:

Cecum: Pericolic, anterior cecal, posterior cecal, ileocolic, right colic

Ascending colon: Pericolic, ileocolic, right colic, middle colic

Hepatic flexure: Pericolic, middle colic, right colic

Transverse colon: Pericolic, middle colic

Splenic flexure: Pericolic, middle colic, left colic, inferior mesenteric

Descending colon: Pericolic, left colic, inferior mesenteric, sigmoid

Sigmoid colon: Pericolic, inferior mesenteric, superior rectal (hemorrhoidal), sigmoidal, sigmoid mesenteric

Rectosigmoid: Pericolic, perirectal, left colic, sigmoid mesenteric, sigmoidal, inferior mesenteric, superior rectal (hemorrhoidal), middle rectal (hemorrhoidal)

Rectum: Perirectal, sigmoid mesenteric, inferior mesenteric, lateral sacral, presacral, internal iliac, sacral promontory (Gerota’s), internal iliac, superior rectal (hemorrhoidal), middle rectal (hemorrhoidal), inferior rectal (hemorrhoidal)

References

1. Shi C, Klimstra DS. Pancreatic neuroendocrine tumors: pathologic and molecular characteristics. *Semin Diagn Pathol.* 2014;31(6):498-511
2. AJCC Version 9 Neuroendocrine Tumors of the Duodenum and Ampulla Cancer Staging System. Copyright 2023 American College of Surgeons.

I. Additional Findings

Coagulative tumor necrosis, usually punctate, may indicate more aggressive behavior¹ and should be reported.

References

1. Rindi G, Kloppel G, Alhman H, et al; and all other Frascati Consensus Conference participants; European Neuroendocrine Tumor Society (ENETS). TNM staging of foregut (neuro)endocrine tumors: a consensus proposal including a grading system. *Virchows Arch.* 2006;449(4):395-401.