



Protocol for the Examination of Specimens From Patients With Cancers of the Larynx

Version: 4.1.0.0

Protocol Posting Date: June 2021

CAP Laboratory Accreditation Program Protocol Required Use Date: March 2022

The changes included in this current protocol version affect accreditation requirements. The new deadline for implementing this protocol version is reflected in the above accreditation date.

For accreditation purposes, this protocol should be used for the following procedures AND tumor types:

Procedure	Description
Resection	Includes specimens designated larynx, supraglottis, glottis, and subglottis.
Tumor Type	Description
Carcinoma	Includes squamous cell carcinoma, neuroendocrine carcinoma, and minor salivary gland carcinoma
Mucosal Melanoma	

This protocol is NOT required for accreditation purposes for the following:

Procedure
Biopsy
Primary resection specimen with no residual cancer (eg, following neoadjuvant therapy)
Cytologic specimens

The following tumor types should NOT be reported using this protocol:

Tumor Type
Hypopharyngeal squamous cell carcinoma (consider the Pharynx protocol)
Sarcoma (consider the Soft Tissue protocol)
Lymphoma (consider the Hodgkin or non-Hodgkin Lymphoma protocols)

Authors

Raja R. Seethala, MD*; Ilan Weinreb, MD; Martin J. Bullock, MD; Diane L. Carlson, MD; Robert L. Ferris, MD, PhD; Louis B. Harrison, MD; Jonathan B. McHugh, MD; Jason Pettus, MD; Mary S. Richardson, MD, DDS; Jatin Shah, MD; Lester D.R.. Thompson, MD; Bruce M. Wenig, MD.

With guidance from the CAP Cancer and CAP Pathology Electronic Reporting Committees.

* Denotes primary author.

Accreditation Requirements

This protocol can be utilized for a variety of procedures and tumor types for clinical care purposes. For accreditation purposes, only the definitive primary cancer resection specimen is required to have the core and conditional data elements reported in a synoptic format.

- Core data elements are required in reports to adequately describe appropriate malignancies. For accreditation purposes, essential data elements must be reported in all instances, even if the response is “not applicable” or “cannot be determined.”
- Conditional data elements are only required to be reported if applicable as delineated in the protocol. For instance, the total number of lymph nodes examined must be reported, but only if nodes are present in the specimen.
- Optional data elements are identified with “+” and although not required for CAP accreditation purposes, may be considered for reporting as determined by local practice standards.

The use of this protocol is not required for recurrent tumors or for metastatic tumors that are resected at a different time than the primary tumor. Use of this protocol is also not required for pathology reviews performed at a second institution (ie, secondary consultation, second opinion, or review of outside case at second institution).

Synoptic Reporting

All core and conditionally required data elements outlined on the surgical case summary from this cancer protocol must be displayed in synoptic report format. Synoptic format is defined as:

- Data element: followed by its answer (response), outline format without the paired Data element: Response format is NOT considered synoptic.
- The data element should be represented in the report as it is listed in the case summary. The response for any data element may be modified from those listed in the case summary, including “Cannot be determined” if appropriate.
- Each diagnostic parameter pair (Data element: Response) is listed on a separate line or in a tabular format to achieve visual separation. The following exceptions are allowed to be listed on one line:
 - Anatomic site or specimen, laterality, and procedure
 - Pathologic Stage Classification (pTNM) elements
 - Negative margins, as long as all negative margins are specifically enumerated where applicable
- The synoptic portion of the report can appear in the diagnosis section of the pathology report, at the end of the report or in a separate section, but all Data element: Responses must be listed together in one location

Organizations and pathologists may choose to list the required elements in any order, use additional methods in order to enhance or achieve visual separation, or add optional items within the synoptic report. The report may have required elements in a summary format elsewhere in the report IN ADDITION TO but not as replacement for the synoptic report ie, all required elements must be in the synoptic portion of the report in the format defined above.

Summary of Changes

v4.1.0.0

- Summary of Changes
- General reformatting
- Revised Margins section
- Revised Lymph Node section
- Added Distant Metastasis section
- Removed pTX and pNX staging classifications

Reporting Template

Protocol Posting Date: June 2021

Select a single response unless otherwise indicated.

CASE SUMMARY: (LARYNX (SUPRAGLOTTIS, GLOTTIS, SUBGLOTTIS))

Standard(s): AJCC-UICC 8

SPECIMEN (Note [A](#))

Procedure (select all that apply)

- Excision
- Endolaryngeal excision
- Transoral laser excision (glottis)
- Supraglottic laryngectomy
- Supracricoid laryngectomy
- Vertical hemilaryngectomy (specify side): _____
- Partial laryngectomy (specify type): _____
- Total laryngectomy
- Neck (lymph node) dissection (specify): _____
- Other (specify): _____
- Not specified

TUMOR

Tumor Focality

- Unifocal
- Multifocal: _____
- Cannot be determined: _____

Multiple Primary Sites (e.g., anterior epiglottis and glottis)

- Not applicable (no additional primary site(s) present)
- Present: _____

Please complete a separate checklist for each primary site

Tumor Site (Note [B](#))

- Larynx, supraglottis: _____

+Tumor Subsite (select all that apply)

- Epiglottis, lingual aspect
- Epiglottis, laryngeal aspect
- Aryepiglottic folds
- Arytenoid(s)
- False vocal cord
- Ventricle
- Larynx, glottis: _____

+Tumor Subsite (select all that apply)

- True vocal cord
- Anterior commissure
- Posterior commissure

+Subglottic Extension

- Not identified
- Present
- Larynx, subglottis: _____
- Other (specify): _____
- Not specified

Transglottic Extension

- Not identified
- Present

Tumor Laterality (select all that apply)

- Right
- Left
- Midline
- Not specified

Tumor Size

- Greatest dimension in Centimeters (cm): _____ cm
- +Additional Dimension in Centimeters (cm): _____ x _____ cm**
- Cannot be determined (explain): _____

Histologic Type (Note [C](#))

- Squamous Cell Carcinoma and Variants
 - Squamous cell carcinoma, conventional (keratinizing)
 - Squamous cell carcinoma, nonkeratinizing
 - Acantholytic squamous cell carcinoma
 - Adenosquamous carcinoma
 - Basaloid squamous cell carcinoma
 - Papillary squamous cell carcinoma
 - Spindle cell squamous carcinoma
 - Verrucous squamous cell carcinoma
 - Lymphoepithelioma-like carcinoma

Carcinoma of Minor Salivary Glands

- Mucoepidermoid carcinoma, low grade
- Mucoepidermoid carcinoma, intermediate grade
- Mucoepidermoid carcinoma, high grade

If multiple patterns present, select predominant pattern unless solid pattern is greater than 30%, in which case should select solid pattern.

- Adenoid cystic carcinoma, tubular pattern#

+Percentage of Solid Component

- Specify percentage: _____ %
- Other (specify): _____
- Cannot be determined

- Adenoid cystic carcinoma, cribriform pattern#

+Percentage of Solid Component

- Specify percentage: _____ %
- Other (specify): _____
- Cannot be determined

- Adenoid cystic carcinoma, solid pattern#

+Percentage of Solid Component

- Specify percentage: _____ %
- Other (specify): _____
- Cannot be determined
- Adenocarcinoma, not otherwise specified, low grade
- Adenocarcinoma, not otherwise specified, intermediate grade
- Adenocarcinoma, not otherwise specified, high grade

Neuroendocrine Carcinoma

- Well differentiated neuroendocrine carcinoma (typical carcinoid tumor)
- Moderately differentiated neuroendocrine carcinoma (atypical carcinoid tumor)
- Poorly differentiated neuroendocrine carcinoma, small cell type
- Poorly differentiated neuroendocrine carcinoma, large cell type
- Combined (or composite) neuroendocrine carcinoma

Type of Combined Histology (select all that apply)

- Squamous cell carcinoma: _____
- Adenocarcinoma: _____
- Small cell neuroendocrine carcinoma: _____
- Large cell neuroendocrine carcinoma: _____
- Other (specify): _____

Mucosal melanoma

- Mucosal melanoma

Other

- Carcinoma, type cannot be determined: _____
- Other histologic type not listed (specify): _____

+Histologic Type Comment: _____

Histologic Grade# (Note [D](#))

The Histologic Grade section is applicable only to squamous cell carcinomas.

- Not applicable
- G1, well differentiated
- G2, moderately differentiated
- G3, poorly differentiated
- Other (specify): _____
- GX, cannot be assessed: _____

+Tumor Extent (specify other structures / spaces involved): _____

Lymphovascular Invasion

- Not identified
- Present
- Cannot be determined: _____

Perineural Invasion (Note [E](#))

- Not identified
- Present
- Cannot be determined: _____

+Tumor Comment: _____

MARGINS (Notes [F,G](#))

Margin Status for Invasive Tumor

All margins negative for invasive tumor

Distance from Invasive Tumor to Closest Margin

Specify in Millimeters (mm)

Exact distance: _____ mm

Greater than: _____ mm

Less than 1 mm

Other (specify): _____

Cannot be determined: _____

Closest Margin(s) to Invasive Tumor (per orientation, if possible)

Specify location(s) of closest margin(s): _____

Cannot be determined

+Other Close Margin(s) to Invasive Tumor

Specify location(s) and distance(s) of other close margin(s): _____

Cannot be determined

Invasive tumor present at margin

Margin(s) Involved by Invasive Tumor (per orientation)

Specify involved margin(s): _____

Cannot be determined: _____

Other (specify): _____

Cannot be determined (explain): _____

Not applicable

Margin Status for Noninvasive Tumor#

Margin status for noninvasive tumor is required only for squamous cell carcinoma when closer than invasive tumor

Not applicable

All margins negative for noninvasive tumor

Distance from Noninvasive Tumor to Closest Margin

Specify in Millimeters (mm)

Exact distance: _____ mm

Greater than: _____ mm

Less than 1 mm

Other (specify): _____

Cannot be determined: _____

Closest Margin(s) to Noninvasive Tumor (per orientation, if possible)

Specify location(s) of closest margin(s): _____

Cannot be determined

+Other Close Margin(s) to Noninvasive Tumor

Specify location(s) and distance(s) of other close margin(s): _____

Cannot be determined

Noninvasive tumor present at margin

Margin(s) Involved by Noninvasive Tumor (per orientation)

Specify involved margin(s): _____

Cannot be determined: _____

Other (specify): _____

Cannot be determined (explain): _____

+Margin Comment: _____

REGIONAL LYMPH NODES (Note [H](#))

Regional Lymph Node Status

- Not applicable (no regional lymph nodes submitted or found)
- Regional lymph nodes present
 - All regional lymph nodes negative for tumor
 - Tumor present in regional lymph node(s)

Number of Lymph Nodes with Tumor

- Exact number (specify): _____
- At least (specify): _____
- Other (specify): _____
- Cannot be determined

Laterality of Lymph Node(s) with Tumor (not applicable for mucosal melanoma)

- Ipsilateral (including midline): _____
- Contralateral: _____
- Bilateral: _____
- Cannot be determined: _____
- Not applicable

Size of Largest Nodal Metastatic Deposit (not applicable for mucosal melanoma)

Specify in Centimeters (cm)

- Exact size: _____ cm
- At least: _____ cm
- Greater than: _____ cm
- Less than: _____ cm
- Other (specify): _____
- Cannot be determined
- Not applicable

Extranodal Extension (ENE) (not applicable for mucosal melanoma) (Note [H](#))

- Not identified
- Present

+Distance of ENE from Lymph Node Capsule

Specify in Millimeters (mm)

- Exact distance: _____ mm
- Greater than 2 mm (macroscopic ENE)
- Less than or equal to 2 mm (microscopic ENE)
- Less than 1 mm
- Other (specify): _____
- Cannot be determined: _____
- Cannot be determined: _____
- Not applicable
- Other (specify): _____
- Cannot be determined: _____

Number of Lymph Nodes Examined

- Exact number (specify): _____
- At least (specify): _____
- Other (specify): _____
- Cannot be determined: _____

+Regional Lymph Node Comment: _____

DISTANT METASTASIS

Distant Site(s) Involved, if applicable (select all that apply)

- Not applicable
- Lung: _____
- Bone: _____
- Brain: _____
- Liver: _____
- Other (specify): _____
- Cannot be determined: _____

PATHOLOGIC STAGE CLASSIFICATION (pTNM, AJCC 8th Edition) (Note !)

Reporting of pT, pN, and (when applicable) pM categories is based on information available to the pathologist at the time the report is issued. As per the AJCC (Chapter 1, 8th Ed.) it is the managing physician's responsibility to establish the final pathologic stage based upon all pertinent information, including but potentially not limited to this pathology report.

TNM Descriptors (select all that apply)

- Not applicable: _____
- m (multiple primary tumors)
- r (recurrent)
- y (post-treatment)

The phrases in *asterisks* include clinical findings required for AJCC staging. This clinical information may not be available to the pathologist. However, if known, these findings should be incorporated into the pathologic staging.

Pathologic Stage Classification

- For All Carcinomas

pT Category

- Primary tumor cannot be assessed
- Carcinoma **in situ**

For the Supraglottis

- pT1: Tumor limited to one subsite of supraglottis **with normal vocal cord mobility**
- pT2: Tumor invades mucosa of more than one adjacent subsite of supraglottis or glottis or region outside the supraglottis (e.g., mucosa of base of tongue, vallecula, medial wall of pyriform sinus)

without fixation of the larynx

- pT3: Tumor limited to larynx **with vocal cord fixation** and / or invades any of the following: postcricoid area, preepiglottic space, paraglottic space, and / or inner cortex of thyroid cartilage

pT4: Moderately advanced or very advanced

- pT4a: Moderately advanced local disease. Tumor invades through the thyroid cartilage and / or invades tissues beyond the larynx (e.g., trachea, soft tissues of neck including deep extrinsic muscle of tongue, strap muscles, thyroid, or esophagus)

- pT4b: Very advanced local disease. Tumor invades prevertebral space, encases carotid artery, or invades mediastinal structures

- pT4 (subgroup cannot be determined)

For the Glottis

*pT1: Tumor limited to the vocal cords (may involve anterior or posterior commissure) **with normal mobility***

- pT1a: Tumor limited to one vocal cord
- pT1b: Tumor involves both vocal cords
- pT1 (subgroup cannot be determined)

- pT2: Tumor extends to supraglottis and / or subglottis, **and / or with impaired vocal cord mobility**

- pT3: Tumor limited to the larynx **with vocal cord fixation** and / or invasion of paraglottic space and / or inner cortex of the thyroid cartilage

Approved

pT4: Moderately advanced or very advanced

___ pT4a: Moderately advanced local disease. Tumor invades through the outer cortex of the thyroid cartilage and / or invades tissues beyond the larynx (e.g., trachea, cricoid cartilage, soft tissues of neck including deep extrinsic muscle of the tongue, strap muscles, thyroid, or esophagus)

___ pT4b: Very advanced local disease. Tumor invades prevertebral space, encases carotid artery, or invades mediastinal structures

___ pT4 (subgroup cannot be determined)

For the Subglottis

___ pT1: Tumor limited to subglottis

___ pT2: Tumor extends to vocal cord(s) *with normal or impaired mobility*

___ pT3: Tumor limited to larynx *with vocal cord fixation* and / or invasion of paraglottic space and / or inner cortex of the thyroid cartilage

pT4: Moderately advanced or very advanced

___ pT4a: Moderately advanced local disease. Tumor invades cricoid or thyroid cartilage and / or invades tissues beyond the larynx (e.g., trachea, soft tissues of neck including deep extrinsic muscles of the tongue, strap muscles, thyroid, or esophagus)

___ pT4b: Very advanced local disease. Tumor invades prevertebral space, encases carotid artery, or invades mediastinal structures

___ pT4 (subgroup cannot be determined)

pN Category# (Note H)*# Midline nodes are considered ipsilateral nodes.**Pathological ENE should be recorded as ENE(-) or ENE(+).**Measurement of the metastatic focus in the lymph nodes is based on the largest metastatic deposit size, which may include matted or fused lymph nodes.*

___ pN not assigned (no nodes submitted or found)

___ pN not assigned (cannot be determined based on available pathological information)

___ pN0: No regional lymph node metastasis

___ pN1: Metastasis in a single ipsilateral lymph node, 3 cm or smaller in greatest dimension and

ENE(-)*pN2: Metastasis in a single ipsilateral lymph node, 3 cm or smaller in greatest dimension and ENE(+); or larger than 3 cm but not larger than 6 cm in greatest dimension and ENE(-); or metastases in multiple ipsilateral lymph nodes, none larger than 6 cm in greatest dimension and ENE(-); or in bilateral or contralateral lymph node(s), none larger than 6 cm in greatest dimension and ENE(-)*

___ pN2a: Metastasis in a single ipsilateral node, 3 cm or smaller in greatest dimension and ENE(+); or in a single ipsilateral node, larger than 3 cm but not larger than 6 cm in greatest dimension and ENE(-)

___ pN2b: Metastases in multiple ipsilateral nodes, none larger than 6 cm in greatest dimension and ENE(-)

___ pN2c: Metastases in bilateral or contralateral lymph node(s), none larger than 6 cm in greatest dimension and ENE(-)

___ pN2 (subgroup cannot be determined)

pN3: Metastasis in a lymph node, larger than 6 cm in greatest dimension and ENE(-); or metastasis in a single ipsilateral node, larger than 3 cm in greatest dimension and ENE(+); or multiple ipsilateral, contralateral, or bilateral lymph nodes any with ENE(+); or a single contralateral node of any size and ENE(+)

___ pN3a: Metastasis in a lymph node, larger than 6 cm in greatest dimension and ENE(-)

___ pN3b: Metastasis in a single ipsilateral node, larger than 3 cm in greatest dimension and ENE(+); or multiple ipsilateral, contralateral, or bilateral lymph nodes any with ENE(+); or a single contralateral node of any size and ENE(+)

___ pN3 (subgroup cannot be determined)

pM Category (required only if confirmed pathologically)

Not applicable - pM cannot be determined from the submitted specimen(s)

pM1: Distant metastasis

For Mucosal Melanoma

pT Category

pT3: Tumors limited to the mucosa and immediately underlying soft tissue, regardless of thickness or greatest dimension; for example, polypoid nasal disease, pigmented or nonpigmented lesions of the oral cavity, pharynx, or larynx

pT4: Moderately advanced or very advanced disease

pT4a: Moderately advanced disease. Tumor involving deep soft tissue, cartilage, bone, or overlying skin

pT4b: Very advanced disease. Tumor involving brain, dura, skull base, lower cranial nerves (IX, X, XI, XII), masticator space, carotid artery, prevertebral space, or mediastinal structures

pT4 (subgroup cannot be determined)

pN Category

pN not assigned (no nodes submitted or found)

pN not assigned (cannot be determined based on available pathological information)

pN0: No regional lymph node metastasis

pN1: Regional lymph node metastases present

pM Category (required only if confirmed pathologically)

Not applicable - pM cannot be determined from the submitted specimen(s)

pM1: Distant metastasis

ADDITIONAL FINDINGS (Note J)

+Additional Findings (select all that apply)

None identified

Dysplasia, low grade (includes hyperplasia, keratosis, and mild dysplasia): _____

Dysplasia, high grade (includes moderate to severe dysplasia, and carcinoma in situ): _____

Squamous papilloma, solitary

Squamous papillomatosis

Inflammation (specify type): _____

Squamous metaplasia

Colonization, fungal

Colonization, bacterial

Other (specify): _____

SPECIAL STUDIES

For reporting molecular testing and other cancer biomarker testing results, the CAP Head and Neck Biomarker Template should be used. Pending biomarker studies should be listed in the Comments section of this report.

Specify test(s) (repeat as needed)

+Specify Test and Results: _____

COMMENTS

Comment(s): _____

Explanatory Notes

A. Scope of Guidelines

The reporting of laryngeal cancer is facilitated by the provision of a case summary illustrating the features required for comprehensive patient care. However, there are many cases in which the individual practicalities of applying such a case summary may not be straightforward. Common examples include finding the prescribed number of lymph nodes, trying to determine the levels of the radical neck dissection, and determining if isolated tumor cells in a lymph node represent metastatic disease. Case summaries have evolved to include clinical, radiographic, morphologic, immunohistochemical, and molecular results in an effort to guide clinical management. Adjuvant and neoadjuvant therapy can significantly alter histologic findings, making accurate classification an increasingly complex and demanding task. This protocol tries to remain simple while still incorporating important pathologic features as proposed by the American Joint Committee on Cancer (AJCC) cancer staging manual, the World Health Organization (WHO) classification of tumors, the TNM classification,¹ the American College of Surgeons Commission on Cancer, and the International Union on Cancer (UICC). This protocol is to be used as a guide and resource, an adjunct to diagnosing and managing cancers of the larynx in a standardized manner. It should not be used as a substitute for dissection or grossing techniques and does not give histologic parameters to reach the diagnosis. Subjectivity is always a factor, and elements listed are not meant to be arbitrary but are meant to provide uniformity of reporting across all the disciplines that use the information. It is a foundation of practical information that will help to meet the requirements of daily practice to benefit both clinicians and patients alike.

References

1. Gress DM, Edge SB, Greene FL, et al. Principles of cancer staging. In: Amin MB, ed. *AJCC Cancer Staging Manual*. 8th ed. New York, NY: Springer; 2017.

B. Anatomic Sites and Subsites for the Larynx (Figure 1)

Supraglottis

Epilarynx, including marginal zone

 Suprahyoid epiglottis, including tip, lingual (anterior), and laryngeal surfaces

 Aryepiglottic fold, laryngeal aspect

 Arytenoid

Supraglottis, excluding epilarynx

 Infrahyoid epiglottis

 Ventricular bands (false cords)

 Ventricle

Glottis

Vocal cords

Anterior commissure

Posterior commissure

Subglottis

The protocol applies to all carcinomas arising at these sites.¹ The piriform sinus represents part of the hypopharynx which expands bilaterally and forward around the sides of the larynx and lies between the larynx and the thyroid cartilage. Cancers of the piriform sinus are included in the protocol on pharynx cancers.

Anatomic Compartments (Figure 1)

The anatomic compartments of the larynx include:

1. Supraglottic larynx extending from the tip of the epiglottis to a horizontal line passing through the apex of the ventricle; structures included in this compartment are the epiglottis (lingual and laryngeal aspects), aryepiglottic folds, arytenoids, false vocal cords and the ventricle.
2. Glottic region, which extends from the ventricle to approximately 0.5 cm to 1.0 cm below the free level of the true vocal cord and includes the anterior and posterior commissures and the true vocal cord.
3. Subglottic larynx, which extends approximately 1.0 cm below the level of the true vocal cord to the inferior rim of the cricoid cartilage.
4. The paraglottic space is a potential space deep to the ventricles and saccules filled with adipose tissue and connective tissue (Figure 2). It is bounded by the conus elasticus inferiorly, the thyroid cartilage laterally, the quadrangular membrane medially, and the piriform sinus posteriorly. Like the paraglottic space, the pre-epiglottic space is filled with adipose tissue and connective tissue (Figure 3); it is triangular in shape and is bounded by the thyroid cartilage and thyrohyoid membrane anteriorly, the epiglottis and thyroepiglottic ligament posteriorly, and the hyoepiglottic ligament at its base (Figures 1 and 2).¹ The paraglottic and preglottic spaces contain lymphatics and blood vessels but no lymph nodes.¹

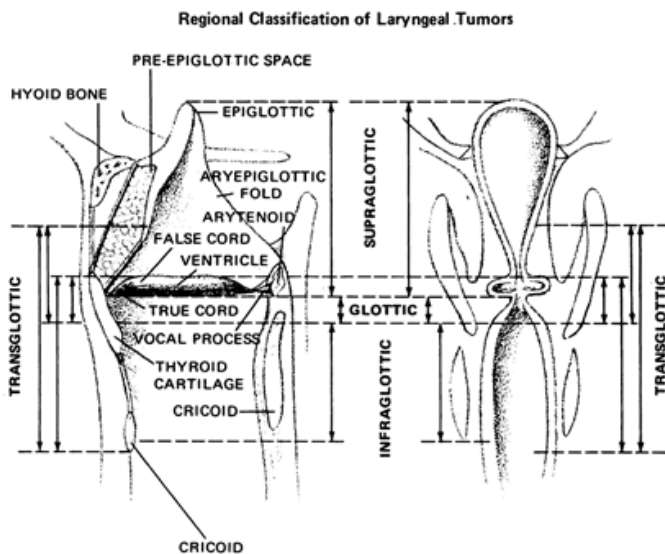


Figure 1. Anatomic compartments of the larynx. From Cocke EW Jr, Wang CC. Part I - Cancer of the larynx: selecting optimum treatment. *CA Cancer J Clin.* 1976;26:194-200. Figure by J.H. Ogura, MD.

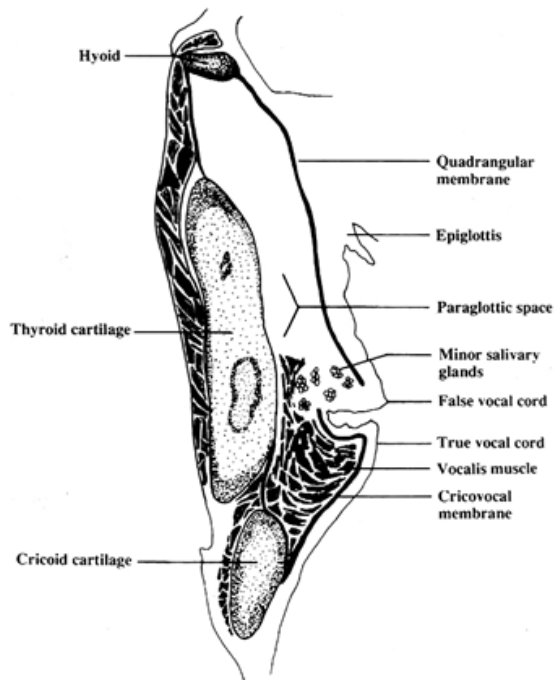


Figure 2. The paraglottic space. From *World Health Organization Classification of Tumours: Pathology and Genetics of Head and Neck Tumours*. Lyon, France: IARC Press; 2005. Reproduced with permission.

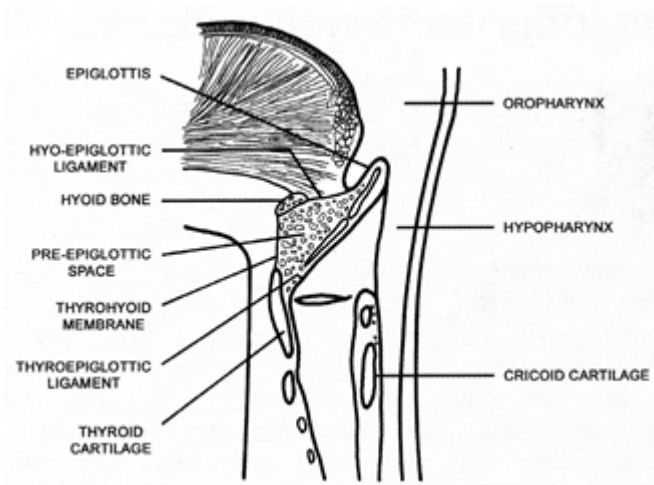


Figure 3. The pre-epiglottic space. From *World Health Organization Classification of Tumours: Pathology and Genetics of Head and Neck Tumours*. Lyon, France: IARC Press; 2005. Reproduced with permission.

Site-Specific Carcinomas

1. Supraglottic squamous cell carcinoma represents a squamous cell carcinoma that involves the structures of the supraglottic larynx, including the epiglottis (laryngeal and lingual surfaces), aryepiglottic folds, arytenoids, false vocal cords, and ventricles.
2. Glottic squamous cell carcinoma represents a squamous cell carcinoma that involves the structures of the glottis, including the true vocal cords, and the anterior and posterior commissures.
3. Subglottic squamous cell carcinoma represents a squamous cell carcinoma that involves the subglottis, which begins 1 cm below the apex of the ventricle to its inferior border represented by the rim of the cricoid cartilage.
4. Transglottic carcinomas represent a carcinoma that crosses the ventricles in a vertical direction arising in either the glottic or supraglottic larynx.

References

1. Patel SG, Lydiatt WM, Glastonbury CM, et al. Larynx. In: Amin MB, ed. *AJCC Cancer Staging Manual*. 8th ed. New York, NY: Springer; 2017.

C. Histologic Type

A modification of the WHO classification of carcinomas of the larynx is shown below.^{1,2} This list may not be complete. This protocol applies to carcinomas and melanomas and does not apply to lymphomas or sarcomas.

Carcinomas of Larynx

Squamous cell carcinoma

- Squamous cell carcinoma, conventional (keratinizing)
- Squamous cell carcinoma, nonkeratinizing
- Adenosquamous carcinoma
- Basaloid squamous cell carcinoma
- Papillary squamous cell carcinoma
- Spindle cell squamous cell carcinoma
- Verrucous squamous cell carcinoma
- Lymphoepithelial carcinoma

Neuroendocrine carcinoma

- Well-differentiated neuroendocrine carcinoma (typical carcinoid tumor)
- Moderately differentiated neuroendocrine carcinoma (atypical carcinoid tumor)
- Poorly differentiated neuroendocrine carcinoma, small cell type
- Poorly differentiated neuroendocrine carcinoma, large cell type
- Combined (or composite) neuroendocrine carcinoma#

#Represents a carcinoma showing combined features of small cell neuroendocrine carcinoma associated with a squamous or adenocarcinomatous component.¹

Carcinomas of Minor Salivary Glands

Adenoid cystic carcinoma
Mucoepidermoid carcinoma
Adenocarcinoma, not otherwise specified
Other[#]

[#]Please refer to the CAP protocol for major salivary glands for detailed listing of other tumor types.

Mucosal Melanoma

References

1. El-Naggar AK. Introduction. In: El-Naggar AK, Chan JKC, Grandis JR, Takata T, Slootweg PJ, eds. *World Health Organization (WHO) Classification of Head and Neck Tumours*. 4th ed. Geneva, Switzerland: WHO Press; 2017:160-162.
2. Slootweg PJ, Grandis JR. Tumours of the hypopharynx, larynx and trachea and parapharyngeal space. In: El-Naggar AK, Chan JKC, Grandis JR, Takata T, Slootweg PJ, eds. *World Health Organization (WHO) Classification of Head and Neck Tumours*. 4th ed. Geneva, Switzerland: WHO Press; 2017:78-81.

D. Histologic Grade

For histologic types of carcinomas that are amenable to grading, 3 histologic grades are suggested, as shown below. For conventional squamous cell carcinoma, histologic grading as a whole does not perform well as a prognosticator.¹ Nonetheless, it should be recorded when applicable, as it is a basic tumor characteristic. Selecting either the most prevalent grade or the highest grade for this synoptic protocol is acceptable. Variants of squamous cell carcinoma (ie, verrucous, basaloid, etc) have an intrinsic biologic potential and currently do not appear to require grading.

Grade 1	Well differentiated
Grade 2	Moderately differentiated
Grade 3	Poorly differentiated
Grade X	Cannot be assessed

The histologic (microscopic) grading of salivary gland carcinomas has been shown to be an independent predictor of behavior and plays a role in optimizing therapy. Further, there is often a positive correlation between histologic grade and clinical stage.^{2,3,4,5} However, most salivary gland carcinoma types have an intrinsic biologic behavior and attempted application of a universal grading scheme is merely a crude surrogate.⁴ Thus a generic grading scheme is no longer recommended for salivary gland carcinomas.⁶ Carcinoma types for which grading systems exist and are relevant are incorporated into histologic type. The 3 major categories that are amenable to grading include adenoid cystic carcinoma, mucoepidermoid carcinoma, and adenocarcinoma, not otherwise specified.^{3,4,7}

In some carcinomas, histologic grading may be based on growth pattern, such as in adenoid cystic carcinoma, for which a histologic high-grade variant has been recognized based on the percentage of solid growth.⁷ Those adenoid cystic carcinomas showing 30% or greater of solid growth pattern are considered to be histologically high-grade carcinomas. The histologic grading of mucoepidermoid carcinoma includes a combination of growth pattern characteristics (eg, cystic, solid, neurotropism) and cytomorphic findings (eg, anaplasia, mitoses, necrosis).^{8,9,10} Adenocarcinomas, not otherwise specified, do not have a formalized grading scheme and are graded intuitively based on cytomorphic features.⁴

References

1. Barnes L, Eveson JW, Reichart P, Sidransky D. WHO histological classification of tumours of the oral cavity and oropharynx. In: Barnes L, Eveson JW, Reichart P, Sidransky D, eds. *World*

Health Organization (WHO) Classification of Tumours: Pathology and Genetics of Head and Neck Tumours. Lyon: IARC; 2005:164.

2. Spiro RH, Thaler HT, Hicks WF, Kher UA, Huvos AH, Strong EW. The importance of clinical staging of minor salivary gland carcinoma. *Am J Surg*. 1991;162(4):330-336.
3. Spiro RH, Huvos AG, Strong EW. Adenocarcinoma of salivary origin. Clinicopathologic study of 204 patients. *Am J Surg*. 1982;144(4):423-431.
4. Seethala RR. Histologic grading and prognostic biomarkers in salivary gland carcinomas. *Adv Anat Pathol*. 2011;18(1):29-45.
5. Kane WJ, McCaffrey TV, Olsen KD, Lewis JE. Primary parotid malignancies: a clinical and pathologic review. *Arch Otolaryngol Head Neck Surg*. 1991;117(3):307-315.
6. Lydiatt WM, Mukherji SK, O'Sullivan B, Patel SG, Shah JP. Major salivary glands. In: Amin MB, ed. *AJCC Cancer Staging Manual*. 8th ed. New York, NY: Springer; 2017.
7. Szanto PA, Luna MA, Tortoledo ME, White RA. Histologic grading of adenoid cystic carcinoma of the salivary glands. *Cancer*. 1984;54(6):1062-1069.
8. Seethala RR, Dacic S, Cieply K, Kelly LM, Nikiforova MN. A reappraisal of the MECT1/MAML2 translocation in salivary mucoepidermoid carcinomas. *Am J Surg Pathol*. 2010;34(8):1106-1121.
9. Brandwein MS, Ivanov K, Wallace DI, et al. Mucoepidermoid carcinoma: a clinicopathologic study of 80 patients with special reference to histological grading. *Am J Surg Pathol*. 2001;25(7):835-845.
10. Auclair PL, Goode RK, Ellis GL. Mucoepidermoid carcinoma of intraoral salivary glands. Evaluation and application of grading criteria in 143 cases. *Cancer*. 1992;69(8):2021-2030.

E. Perineural Invasion

Traditionally, the presence of perineural invasion (neurotropism) is an important predictor of poor prognosis in head and neck cancer of virtually all sites.¹ The presence of perineural invasion (neurotropism) in the primary cancer is associated with poor local disease control and regional control, as well as being associated with metastasis to regional lymph nodes.¹ Further, perineural invasion is associated with decrease in disease-specific survival and overall survival.¹ There is conflicting data relative to an association between the presence of perineural invasion and the development of distant metastasis, with some studies showing an increased association with distant metastasis, while other studies showing no correlation with distant metastasis.¹ The relationship between perineural invasion and prognosis is independent of nerve diameter.² Additionally, emerging evidence suggests that extratumoral perineural invasion may be more prognostically relevant.³ Although perineural invasion of small unnamed nerves may not produce clinical symptoms, the reporting of perineural invasion includes nerves of all sizes including small peripheral nerves (ie, less than 1 mm in diameter). Aside from the impact on prognosis, the presence of perineural invasion also guides therapy. Concurrent adjuvant chemoradiation therapy has been shown to improve outcomes in patients with perineural invasion (as well as in patients with extranodal extension and bone invasion).^{4,5} Given the significance relative to prognosis and treatment, perineural invasion is a required data element in the reporting of head and neck cancers.

References

1. Smith BD, Haffty BG. Prognostic factoris in patients with head and neck cancer. In: Harrison LB, Sessions RB, Hong WK, eds. *Head and Neck Cancer: A Multidisciplinary Approach*. Philadelphia, PA: Lippincott Williams and Wilkins; 2009:51-75.
2. Fagan JJ, Collins B, Barnes L, et al. Perineural invasion in squamous cell carcinoma of the head and neck. *Arch Otolaryngol Head Neck Surg*. 1998;124(6):637-640.
3. Miller ME, Palla B, Chen Q, et al. A novel classification system for perineural invasion in noncutaneous head and neck squamous cell carcinoma: histologic subcategories and patient outcomes. *Am J Otolaryngol*. 2012;33(2):212-215.
4. Cooper JS, Pajak TF, Forastiere AA, et al. Postoperative concurrent radiotherapy and chemotherapy for high-risk squamous-cell carcinoma of the head and neck. *N Engl J Med*. 2004;350(19):1937-1944.

5. Bernier J, Domenge C, Ozsahin M, et al. Postoperative irradiation with or without concomitant chemotherapy for locally advanced head and neck cancer. *N Engl J Med*. 2004;350(19):1945-1952.

F. Surgical Margins

The definition of a positive margin is somewhat controversial given the varied results from prior studies.^{1,2} However, overall, several studies support the definition of a positive margin to be invasive carcinoma or carcinoma in situ/high-grade dysplasia present at margins (microscopic cut-through of tumor).³ Furthermore, reporting of surgical margins should also include information regarding the distance of invasive carcinoma, carcinoma in situ, or high-grade dysplasia (moderate to severe) from the surgical margin. Tumors with “close” margins also carry an increased risk for local recurrence.^{2,3} The definition of a “close” margin is not standardized as the effective cut-off varies between studies and between anatomic subsites. Commonly used cut points to define close margins are 5 mm in general and 2 mm with respect to glottic larynx.² However, values ranging from 3 mm to 7 mm have been used with success,^{2,4} and for glottic tumors as low as 1 mm.⁵ Thus, distance of tumor from the nearest margin should be recorded.

Reporting of surgical margins for carcinomas of the minor salivary glands should follow those used for squamous cell carcinoma of larynx.

Dysplasia

The types of intraepithelial dysplasia of the upper aerodigestive tract (UADT) include nonkeratinizing (“classic”) dysplasia and keratinizing dysplasia. Of the 2 types of dysplasias, the keratinizing dysplasias are significantly more common than the nonkeratinizing dysplasias. The current WHO advocates a 2-tiered approach with low-grade and high-grade dysplasia categories (see below under Note M).⁶ High-grade dysplasia at a margin is regarded and reported as a positive margin, while low-grade dysplasia is not.

References

1. Brandwein-Gensler M, Teixeira MS, Lewis CM, et al. Oral squamous cell carcinoma: histologic risk assessment, but not margin status, is strongly predictive of local disease-free and overall survival. *Am J Surg Pathol*. 2005;29(2):167-178.
2. Hinni ML, Ferlito A, Brandwein-Gensler MS, et al. Surgical margins in head and neck cancer: a contemporary review. *Head Neck*. 2012.
3. Alicandri-Ciufelli M, Bonali M, Piccinini A, et al. Surgical margins in head and neck squamous cell carcinoma: what is 'close'? *Eur Arch Otorhinolaryngol*. 2012;270(10):2603-2609.
4. Liao CT, Chang JT, Wang HM, et al. Analysis of risk factors of predictive local tumor control in oral cavity cancer. *Ann Surg Oncol*. 2008;15(3):915-922.
5. Ansarin M, Santoro L, Cattaneo A, et al. Laser surgery for early glottic cancer: impact of margin status on local control and organ preservation. *Arch Otolaryngol Head Neck Surg*. 2009;135(4):385-390.
6. Gale N, Hille JJ, Jordan RC, Nadal A, Williams MD. Dysplasia. In: El-Naggar AK, Chan JKC, Grandis JR, Takata T, Slootweg PJ, eds. *World Health Organization (WHO) Classification of Head and Neck Tumours*. 4th ed. Geneva, Switzerland: WHO Press; 2017:91-93.

G. Orientation of Specimen

Complex specimens should be examined and oriented with the assistance of the operating surgeon(s). Direct communication between the surgeon and pathologist is a critical component in specimen orientation and proper sectioning. Whenever possible, the tissue examination request form should include a drawing or photograph of the resected specimen showing the extent of the tumor and its relation to the anatomic structures of the region. The lines and extent of the resection can be depicted on preprinted adhesive labels and attached to the surgical pathology request forms.

H. Lymph Nodes

Measurement of Tumor Metastasis

The cross-sectional diameter of the largest lymph node metastasis (not the lymph node itself) is measured in the gross specimen at the time of macroscopic examination or, if necessary, on the histologic slide at the time of microscopic examination.^{1,2}

Special Procedures for Lymph Nodes

The risk of regional (cervical neck) nodal spread from cancers varies based on anatomic subsite. At the current time, no additional special techniques are required other than routine histology for the assessment of nodal metastases. Immunohistochemistry and polymerase chain reaction (PCR) to detect isolated tumor cells are considered investigational techniques at this time.

Regional Lymph Nodes (pN0): Isolated Tumor Cells

Isolated tumor cells (ITCs) are single cells or small clusters of cells not more than 0.2 mm in greatest dimension. While the generic recommendation is that for lymph nodes with ITCs found by either histologic examination, immunohistochemistry, or nonmorphologic techniques (eg, flow cytometry, DNA analysis, PCR amplification of a specific tumor marker), they should be classified as N0 or M0, respectively.^{3,4} Evidence for the validity of this practice in head and neck squamous cell carcinoma and other histologic subtypes is lacking. In fact, rare studies relevant to head and neck sites indicate that isolated tumor cells may actually be a poor prognosticator in terms of local control.⁵

Lymph Node Number

Histologic examination of a selective neck dissection specimen will ordinarily include 6 or more lymph nodes. Histologic examination of a radical or modified radical neck dissection specimen will ordinarily include 10 or more lymph nodes in the untreated neck.

Classification of Neck Dissection

1. Radical neck dissection
2. Modified radical neck dissection, internal jugular vein and/or sternocleidomastoid muscle spared
3. Selective neck dissection (SND), as specified by the surgeon (Figure 4), defined by dissection of less than the 5 traditional levels of a radical and modified radical neck dissection. The following dissections are now under this category.^{6,7,8}
 - a. Supraomohyoid neck dissection
 - b. Posterolateral neck dissection
 - c. Lateral neck dissection
 - d. Central compartment neck dissection
4. Superselective neck dissection (SSND), a relatively new term defined by dissection of the fibrofatty elements of 2 or less levels.⁹
5. Extended radical neck dissection, as specified by the surgeon.

For purposes of pathologic evaluation, lymph nodes are organized by levels as shown in Figure 4.

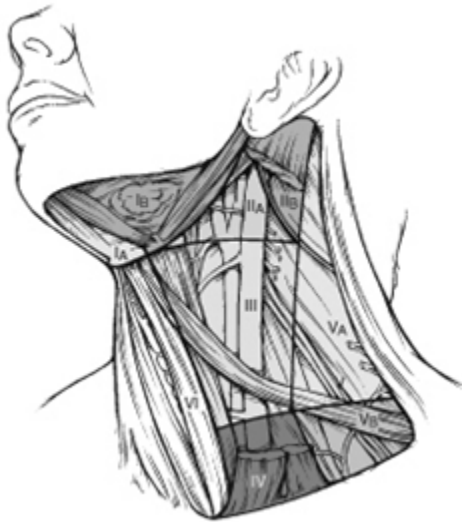

Figure 4. The six sublevels of the neck for describing the location of lymph nodes within levels I, II, and V. Level IA, submental group; level IB, submandibular group; level IIA, upper jugular nodes along the carotid sheath, including the subdigastric group; level IIB, upper jugular nodes in the submuscular recess; level VA, spinal accessory nodes; and level VB, the supraclavicular and transverse cervical nodes. From: Flint PW, et al, eds. *Cummings Otolaryngology: Head and Neck Surgery*. 5th ed. Philadelphia, PA; Saunders: 2010. Reproduced with permission © Elsevier.

In order for pathologists to properly identify these nodes, they must be familiar with the terminology of the regional lymph node groups and with the relationships of those groups to the regional anatomy. Which lymph node groups surgeons submit for histopathologic evaluation depends on the type of neck dissection they perform. Therefore, surgeons must supply information on the types of neck dissections that they perform and the details of the local anatomy in the specimens they submit for examination or, in other manners, orient those specimens for pathologists.

If it is not possible to assess the levels of lymph nodes (for instance, when the anatomic landmarks in the excised specimens are not specified), then the lymph node levels may be estimated as follows: level II, upper third of internal jugular (IJ) vein or neck specimen; level III, middle third of IJ vein or neck specimen; level IV, lower third of IJ vein or neck specimen, all anterior to the sternocleidomastoid muscle.

Level I. Submental Group (Sublevel IA)

Lymph nodes within the triangular boundary of the anterior belly of the digastric muscles and the hyoid bone.

Level I. Submandibular Group (Sublevel IB)

Lymph nodes within the boundaries of the anterior and posterior bellies of the digastric muscle and the body of the mandible. The submandibular gland is included in the specimen when the lymph nodes within this triangle are removed.

Level II. Upper Jugular Group (Sublevels IIA and IIB)

Lymph nodes located around the upper third of the internal jugular vein and adjacent spinal accessory nerve extending from the level of the carotid bifurcation (surgical landmark) or hyoid bone (clinical landmark)

to the skull base. The posterior boundary is the posterior border of the sternocleidomastoid muscle, and the anterior boundary is the lateral border of the stylohyoid muscle.

Level III. Middle Jugular Group

Lymph nodes located around the middle third of the internal jugular vein extending from the carotid bifurcation superiorly to the omohyoid muscle (surgical landmark), or cricothyroid notch (clinical landmark) inferiorly. The posterior boundary is the posterior border of the sternocleidomastoid muscle, and the anterior boundary is the lateral border of the sternohyoid muscle.

Level IV. Lower Jugular Group

Lymph nodes located around the lower third of the internal jugular vein extending from the omohyoid muscle superiorly to the clavicle inferiorly. The posterior boundary is the posterior border of the sternocleidomastoid muscle, and the anterior boundary is the lateral border of the sternohyoid muscle.

Level V. Posterior Triangle Group (Sublevels VA and VB)

This group comprises predominantly the lymph nodes located along the lower half of the spinal accessory nerve and the transverse cervical artery. The supraclavicular nodes are also included in this group. The posterior boundary of the posterior triangle is the anterior border of the trapezius muscle, the anterior boundary of the posterior triangle is the posterior border of the sternocleidomastoid muscle, and the inferior boundary of the posterior triangle is the clavicle.

Level VI. Anterior (Central) Compartment

Lymph nodes in this compartment include the pre- and paratracheal nodes, precricoid (Delphian) node, and the perithyroidal nodes, including the lymph nodes along the recurrent laryngeal nerve. The superior boundary is the hyoid bone, the inferior boundary is the suprasternal notch, the lateral boundaries are the common carotid arteries, and the posterior boundary by the prevertebral fascia.

Level VII. Superior Mediastinal Lymph Nodes

Metastases at level VII are considered regional lymph node metastases; all other mediastinal lymph node metastases are considered distant metastases.

Lymph node groups removed from areas not included in the above levels, eg, scalene, suboccipital, and retropharyngeal, should be identified and reported from all levels separately. Midline nodes are considered ipsilateral nodes.

Extranodal Extension

The status of cervical lymph nodes is the single most important prognostic factor in aerodigestive cancer. All macroscopically negative or equivocal lymph nodes should be submitted in toto. Grossly positive nodes may be partially submitted for microscopic documentation of metastasis. Reporting of lymph nodes containing metastasis should include whether there is presence or absence of extranodal extension (ENE),¹⁰ which is now part of N staging. This finding consists of extension of metastatic tumor, present within the confines of the lymph node, through the lymph node capsule into the surrounding connective tissue, with or without associated stromal reaction. A distance of extension from the native lymph node capsule is now suggested (but not yet required) with the proposed stratification of ENE into ENE_{ma} (>2 mm) and ENE_{mi} (≤2 mm).^{11,12,13,14} However, pitfalls in the measurement (ie, in larger, matted lymph nodes, in nodes post fine-needle aspiration, and in nodes with near total replacement of lymph node architecture), and the disposition of soft tissue deposits is still not resolved. In general, absence of ENE in

a large (>3 cm) lymph node, especially with traversing fibrous bands, should be viewed with skepticism. Soft tissue deposits for lymph node metastases based on limited studies appear to be the equivalent of a positive lymph node with ENE and should be recorded as such.¹⁵

1. References
2. Cooper JS, Pajak TF, Forastiere AA, et al. Postoperative concurrent radiotherapy and chemotherapy for high-risk squamous-cell carcinoma of the head and neck. *N Engl J Med*. 2004;350(19):1937-1944.
3. Bernier J, Dommenege C, Ozsahin M, et al. Postoperative irradiation with or without concomitant chemotherapy for locally advanced head and neck cancer. *N Engl J Med*. 2004;350(19):1945-1952.
4. Sobin LH, Gospodarowicz MK, Wittekind CH, eds. TNM Classification of Malignant Tumours. New York, NY: Wiley-Liss; 2009.
5. Singletary SE, Greene FL, Sobin LH. Classification of isolated tumor cells: clarification of the 6th edition of the American Joint Committee on Cancer Staging Manual. *Cancer*. 2003;98(12):2740-2741.
6. Broglio MA, Haerle SK, Huber GF, Haile SR, Stoeckli SJ. Occult metastases detected by sentinel node biopsy in patients with early oral and oropharyngeal squamous cell carcinomas: Impact on survival. *Head Neck*. 2013;35(5):660-666.
7. Ferlito A, Robbins KT, Shah JP, et al. Proposal for a rational classification of neck dissections. *Head Neck*. 2011;33(3):445-450.
8. Robbins KT, Saha AR, Medina JE, et al. Consensus statement on the classification and terminology of neck dissection. *Arch Otolaryngol Head Neck Surg*. 2008;134(5):536-538.
9. Seethala RR. Current state of neck dissection in the United States. *Head Neck Pathol*. 2009;3(3):238-245.
10. Suarez C, Rodrigo JP, Robbins KT, et al. Superselective neck dissection: rationale, indications, and results. *Eur Arch Otorhinolaryngol*. 2013.
11. Ebrahimi A, Gil Z, Amit M. International Consortium for Outcome Research (ICOR) in Head and Neck Cancer. Primary tumor staging for oral cancer and a proposed modification incorporating depth of invasion: an international multicenter retrospective study. *JAMA Otolaryngol Head Neck Surg*. 2014;140(12):1138-1148.
12. Ridge JA, Lydiatt WM, Patel SG, et al. Lip and oral cavity. In: Amin MB, ed. *AJCC Cancer Staging Manual*. 8th ed. New York, NY: Springer; 2017.
13. Ebrahimi A, Clark JR, Amit M, et al. Minimum nodal yield in oral squamous cell carcinoma: defining the standard of care in a multicenter international pooled validation study. *Ann Surg Oncol*. 2014;21(9):3049-3055.
14. Prabhu RS, Hanasoge S, Magliocca KR, et al. Extent of pathologic extracapsular extension and outcomes in patients with nonoropharyngeal head and neck cancer treated with initial surgical resection. *Cancer*. 2014;120(10):1499-1506.
15. Dunne AA, Muller HH, Eisele DW, et al. Meta-analysis of the prognostic significance of perinodal spread in head and neck squamous cell carcinomas (HNSCC) patients. *Eur J Cancer*. 2006;42(12):1863-1868.
16. Jose J, Moor JW, Coatesworth AP, Johnston C, MacLennan K. Soft tissue deposits in neck dissections of patients with head and neck squamous cell carcinoma: prospective analysis of prevalence, survival, and its implications. *Arch Otolaryngol Head Neck Surg*. 2004;130(2):157-160.

I. TNM and Stage Groupings

The protocol recommends the TNM staging system of the American Joint Committee on Cancer.¹ There are no significant alterations in the 8th edition to T stage of larynx. However, extranodal extension (ENE) is included in N stage. In essence, pathologic ENE(+) will increase the nodal category by 1.

The 8th edition of the AJCC staging of head and neck cancers includes mucosal melanomas; this does not show significant changes from the 7th edition. Approximately two-thirds of mucosal melanomas arise in the sinonasal tract, one-quarter are found in the oral cavity, and the remainder occur only sporadically in other mucosal sites of the head and neck. Even small cancers behave aggressively with high rates of recurrence and death. To reflect this aggressive behavior, primary cancers limited to the mucosa are considered T3 lesions. Advanced mucosal melanomas are classified as T4a and T4b. The anatomic extent criteria to define *moderately advanced* (T4a) and *very advanced* (T4b) disease are given below. The AJCC staging for mucosal melanomas does not provide for the histologic definition of a T3 lesion; as the majority of mucosal melanomas are invasive at presentation, mucosal-based melanomas (T3 lesions) include those lesions that involve either the epithelium and/or lamina propria of the involved site. Rare examples of in situ mucosal melanomas occur, but In situ mucosal melanomas are excluded from staging, as they are extremely rare.²

By AJCC/UICC convention, the designation “T” refers to a primary tumor that has not been previously treated. The symbol “p” refers to the pathologic classification of the TNM, as opposed to the clinical classification, and is based on gross and microscopic examination. pT entails a resection of the primary tumor or biopsy adequate to evaluate the highest pT category, pN entails removal of nodes adequate to validate lymph node metastasis, and pM implies microscopic examination of distant lesions. Clinical classification (cTNM) is usually carried out by the referring physician before treatment during initial evaluation of the patient or when pathologic classification is not possible.

Pathologic staging is usually performed after surgical resection of the primary tumor. Pathologic staging depends on pathologic documentation of the anatomic extent of disease, whether or not the primary tumor has been completely removed. If a biopsied tumor is not resected for any reason (eg, when technically unfeasible) and if the highest T and N categories or the M1 category of the tumor can be confirmed microscopically, the criteria for pathologic classification and staging have been satisfied without total removal of the primary cancer.

TNM Descriptors

For identification of special cases of TNM or pTNM classifications, the “m” suffix and “y” and “r” prefixes are used. Although they do not affect the stage grouping, they indicate cases needing separate analysis.

The “m” suffix indicates the presence of multiple primary tumors in a single site and is recorded in parentheses: pT(m)NM.

The “y” prefix indicates those cases in which classification is performed during or following initial multimodality therapy (ie, neoadjuvant chemotherapy, radiation therapy, or both chemotherapy and radiation therapy). The cTNM or pTNM category is identified by a “y” prefix. The ycTNM or ypTNM categorizes the extent of tumor actually present at the time of that examination. The “y” categorization is not an estimate of tumor prior to multimodality therapy (ie, before initiation of neoadjuvant therapy).

The “r” prefix indicates a recurrent tumor when staged after a documented disease-free interval, and is identified by the “r” prefix: rTNM.

Additional Descriptors

Residual Tumor (R)

Tumor remaining in a patient after therapy with curative intent (eg, surgical resection for cure) is categorized by a system known as R classification, shown below.

RX Presence of residual tumor cannot be assessed

- R0 No residual tumor
- R1 Microscopic residual tumor
- R2 Macroscopic residual tumor

For the surgeon, the R classification may be useful to indicate the known or assumed status of the completeness of a surgical excision. For the pathologist, the R classification is relevant to the status of the margins of a surgical resection specimen. That is, tumor involving the resection margin on pathologic examination may be assumed to correspond to residual tumor in the patient and may be classified as macroscopic or microscopic according to the findings at the specimen margin(s).

T Category Considerations

Supraglottis. Normal vocal cord mobility (T1), fixation of the larynx (T2), and vocal cord fixation (T3) may only be determined clinically.

Glottis. Normal vocal cord mobility (T1), impaired vocal cord mobility (T2), and vocal cord fixation (T3) may only be determined clinically.

Subglottis. Normal or impaired vocal cord mobility (T2) and vocal cord fixation (T3) may only be determined clinically.

References

1. Patel SG, Lydiatt WM, Glastonbury CM, et al. Larynx. In: Amin MB, ed. *AJCC Cancer Staging Manual*. 8th ed. New York, NY: Springer; 2017.
2. Lydiatt WM, Brandwein-Gensler MS, Kraus DH, et al. Mucosal melanoma of the head and neck. In: Amin MB, ed. *AJCC Cancer Staging Manual*. 8th ed. New York, NY: Springer; 2017.

J. Dysplasia of the Upper Aerodigestive Tract (UADT)

In contrast to the uterine cervix in which the nonkeratinizing (“classic”) form of epithelial dysplasia is most common resulting in a reproducible and clinically useful grading scheme of mild, moderate, and severe dysplasia (ie, carcinoma in situ), the majority of the UADT mucosal lesions fall under the designation of keratinizing dysplasias, for which the aforementioned criteria are not as easily applied.

The current approach indicated by the WHO for laryngeal precursor lesions is to use a 2-tiered classification of low-grade and high-grade dysplasia. Hyperplasias and keratoses without atypia as well as those with mild dysplasia are categorized as “low grade,” while lesions with moderate and severe dysplasia as well as carcinoma in situ are considered “high grade.”¹ Separation of carcinoma in situ as a distinct category (ie, 3 tiers) is an acceptable option, but data are limited to support this.²

Morphologic criteria for the classification of laryngeal precursor lesions are summarized below.¹

Low-grade dysplasia (including previous category of mild dysplasia)	
Architectural criteria	<p>Stratification is preserved: transition of basal cells or augmented basal/parabasal cell layer with perpendicular orientation to the basement membrane to prickle cells horizontally oriented in the upper part</p> <p>Spinous layer: spectrum of changes ranging from increased spinous layer in the whole thickness up to changes in which prickle cells are seen only in the upper epithelial half</p> <p>Basal/parabasal layer: spectrum of changes, from 2-3 unchanged layers to augmentation of basal and parabasal cells in the lower half of the epithelium</p>

Cytologic criteria	<p>At most minimal cellular atypia</p> <p>Parabasal cells; slightly increased cytoplasm compared to basal cells, enlarged nuclei, uniformly distributed chromatin, no intercellular bridges</p> <p>Rare regular mitoses in or near basal layer</p> <p>Few dyskeratotic cells present</p>
High-grade dysplasia (including previous category of moderate and severe dysplasia, and carcinoma in situ)	
Architectural criteria*	<p>Abnormal maturation</p> <p>Variable degrees of disordered stratification and polarity in as much as the whole epithelium</p> <p>Altered epithelial cells usually occupying from half to the entire epithelial thickness</p> <p>Two subtypes: keratinizing (spinous-cell type) and nonkeratinizing (basal-cell type)</p> <p>Variable degree of irregularly shaped rete (bulbous, downwardly extending), with an intact basement membrane</p> <p>No stromal alterations</p>
Cytologic criteria*	<p>Easily identified conspicuous cellular and nuclear atypia, including marked variation in size and shape, marked variation in stain intensity with frequent hyperchromasia, nucleoli increased in number and size</p> <p>Increased N:C ratio</p> <p>Increased mitoses at or above the suprabasal level, with or without atypical forms</p> <p>Dyskeratotic and apoptotic cells are frequent throughout the entire epithelium</p>
* Complete loss of stratification and polarity and/or severe cytological atypia and atypical mitoses qualifies as carcinoma in situ if a 3-tiered system is used.	

The risk of malignant progression in low-grade dysplasia is ~1.6%, while that of high-grade dysplasia is ~12.5%. Limited data suggest that the specific designation of carcinoma in situ carries a risk of 40%.¹

References

1. Gale N, Hille JJ, Jordan RC, Nadal A, Williams MD. Dysplasia. In: El-Naggar AK, Chan JKC, Grandis JR, Takata T, Slootweg PJ, eds. *World Health Organization (WHO) Classification of Head and Neck Tumours*. 4th ed. Geneva, Switzerland: WHO Press; 2017:91-93.
2. Gale N, Blagus R, El-Mofty SK, et al. Evaluation of a new grading system for laryngeal squamous intraepithelial lesions - a proposed unified classification. *Histopathology*. 2014;65(4):456-464.