



# Protocol for the Examination of Specimens from Patients with Mucosal Melanoma of the Head and Neck

Version: 1.0.0.0

Protocol Posting Date: April 2026

**CAP Laboratory Accreditation Program Protocol Required Use Date:** January 2027

The changes included in this current protocol version affect accreditation requirements. The new deadline for implementing this protocol version is reflected in the above accreditation date.

**For accreditation purposes, this protocol should be used for the following procedures AND tumor types:**

Procedure	Description
Resection	Includes specimens designated from all mucosal head and neck sites
Tumor Type	Description
Mucosal Melanoma	Includes invasive (not in situ) mucosal melanomas

**This protocol is NOT required for accreditation purposes for the following:**

Procedure
Biopsy
Primary resection specimen with no residual cancer (e.g., following neoadjuvant therapy)
Cytologic specimens

**The following tumor types should NOT be reported using this protocol:**

Tumor Type
Sarcoma (consider the Soft Tissue protocol)
Hematologic malignancies (consider the Precursor and Mature Lymphoid Malignancies, Myeloid and Mixed / Ambiguous Lineage Neoplasms, and Plasma Cell Malignancies protocols)
Carcinomas (consider the corresponding site-specific Head and Neck protocols or Salivary Gland protocol)
Cutaneous melanomas of the head and neck (consider the Invasive Melanoma of the Skin protocol)
Uveal melanomas (consider the Uveal Melanoma protocol)
Conjunctival melanomas

## **Version Contributors**

**Committee Authors:** Raja R. Seethala, MD, FCAP\*, Nicole A. Cipriani, MD, FCAP\*, Lananh Nguyen, MD, MSc, FCAP, Rashmi Samdani, MD, FCAP, Michael A. Berman, MD, FCAP, Jason R. Pettus, MD, FCAP

**Expert Panel Contributors:** Justin A. Bishop, MD, William C. Faquin, MD, PhD, Shao Hui Huang, MD, Nora Katabi, MD, William Lydiatt, MD, Brian O'Sullivan, MB BCh, Snehal Patel, MD, Lindsay Williams, MD

\* Denotes primary author.

For any questions or comments, contact: [cancerprotocols@cap.org](mailto:cancerprotocols@cap.org).

## **Glossary:**

**Author:** Expert who is designated by the chair of the Cancer Committee.

**Expert Contributors:** Includes members of other CAP committees or external subject matter experts who contribute to the current version of the protocol.

© 2026 College of American Pathologists (CAP). All rights reserved. For Terms of Use please visit [www.cap.org/cancerprotocols](http://www.cap.org/cancerprotocols) . 1

Replaced by version 1.1.0.0 on June 17, 2026, Obsolete as of March 2027 (8 months after newest release date)

### Accreditation Requirements

Synoptic reporting with core and conditional data elements for designated specimen types\* is required for accreditation.

- Data elements designated as core must be reported.
- Data elements designated as conditional only need to be reported if applicable.
- Data elements designated as optional are identified with "+". Although not required for accreditation, they may be considered for reporting.

This protocol is not required for recurrent or metastatic tumors resected at a different time than the primary tumor. This protocol is also not required for pathology reviews performed at a second institution (i.e., second opinion and referrals to another institution).

Full accreditation requirements can be found on the CAP website under [Accreditation Checklists](#).

A list of core and conditional data elements can be found in the Summary of Required Elements under Resources on the CAP Cancer Protocols [website](#).

*\*Includes definitive primary cancer resection and pediatric biopsy tumor types.*

### Synoptic Reporting

All core and conditionally required data elements outlined on the surgical case summary from this cancer protocol must be displayed in synoptic report format. Synoptic format is defined as:

- Data element: followed by its answer (response), outline format without the paired Data element: Response format is NOT considered synoptic.
- The data element should be represented in the report as it is listed in the case summary. The response for any data element may be modified from those listed in the case summary, including "Cannot be determined" if appropriate.
- Each diagnostic parameter pair (Data element: Response) is listed on a separate line or in a tabular format to achieve visual separation. The following exceptions are allowed to be listed on one line:
  - Anatomic site or specimen, laterality, and procedure
  - Pathologic Stage Classification (pTNM) elements
  - Negative margins, as long as all negative margins are specifically enumerated where applicable
- The synoptic portion of the report can appear in the diagnosis section of the pathology report, at the end of the report or in a separate section, but all Data element: Responses must be listed together in one location
- Organizations and pathologists may choose to list the required elements in any order, use additional methods in order to enhance or achieve visual separation, or add optional items within the synoptic report. The report may have required elements in a summary format elsewhere in the report IN ADDITION TO but not as replacement for the synoptic report ie, all required elements must be in the synoptic portion of the report in the format defined above.

**Summary of Changes**

**v 1.0.0.0**

- New protocol resulting from the separation of select Head and Neck protocols

RETIRED

## Reporting Template

Protocol Posting Date: April 2026

Select a single response unless otherwise indicated.

**CASE SUMMARY: (MUCOSAL MELANOMA)**

Standard(s): AJCC 8

### CLINICAL

#### +Prior Therapy (select all that apply)

- None
- Surgery: \_\_\_\_\_
- Chemotherapy: \_\_\_\_\_
- Radiotherapy: \_\_\_\_\_
- Targeted therapy: \_\_\_\_\_
- Immunotherapy: \_\_\_\_\_

### SPECIMEN (Note [A](#))

#### Procedure (select all that apply)

- Excision (specify type): \_\_\_\_\_
- Neck (lymph node) dissection (specify type): \_\_\_\_\_
- Oral Cavity*
- Glossectomy: \_\_\_\_\_
- Buccal mucosal resection: \_\_\_\_\_
- Mandibulectomy: \_\_\_\_\_
- Maxillectomy: \_\_\_\_\_
- Palatectomy
- Oropharynx and Hypopharynx*
- Tonsillectomy
- Laryngopharyngectomy
- Nasopharynx and Sinonasal*
- Endoscopic endonasal resection
- Partial maxillectomy
- Radical maxillectomy
- Larynx*
- Endolaryngeal excision
- Transoral laser excision (glottis)
- Supraglottic laryngectomy
- Supracricoid laryngectomy
- Vertical hemilaryngectomy (specify laterality): \_\_\_\_\_
- Partial laryngectomy (specify type): \_\_\_\_\_
- Total laryngectomy
- Laryngopharyngectomy
- Other*
- Other (specify): \_\_\_\_\_
- Not specified

## TUMOR

### Multiple Primary Sites (required only if applicable)#

# Please complete a separate checklist for each primary site

Not applicable (no additional primary site(s) present)

Present: \_\_\_\_\_

### Tumor Focality

Unifocal

Multifocal: \_\_\_\_\_

Cannot be determined (explain): \_\_\_\_\_

### Tumor Site (Note B)

If multiple sites are involved, please select the dominant site / epicenter. Multiple tumor subsites may be involved. Please use Tumor Comment to list involved subsites outside the main tumor site.

Oral cavity: \_\_\_\_\_

#### +Tumor Subsite(s) (select all that apply)

Wet mucosa of upper lip

Wet mucosa of lower lip

Wet mucosa of lip, NOS

Lateral border of tongue

Ventral surface of tongue

Dorsal surface of tongue

Anterior two-thirds of tongue

Tongue, NOS

Upper gingiva

Lower gingiva

Gingiva, NOS

Anterior floor of mouth

Lateral floor of mouth

Hard palate

Buccal mucosa

Vestibule of mouth, maxillary

Vestibule of mouth, mandibular

Oropharynx: \_\_\_\_\_

#### +Tumor Subsite(s) (select all that apply)

Palatine tonsil

Tonsillar pillar

Tonsillar fossa

Lingual tonsil

Tonsil, NOS

Base of tongue

Soft palate

Uvula

Lateral wall of oropharynx

Posterior wall of oropharynx

- Vallecula
- Epiglottis, anterior surface (lingual aspect)

Hypopharynx: \_\_\_\_\_

**+Tumor Subsite(s) (select all that apply)**

- Pyriform sinus
- Aryepiglottic fold, hypopharyngeal aspect
- Postcricoid
- Posterior wall of hypopharynx

Supraglottic larynx: \_\_\_\_\_

**+Tumor Subsite(s) (select all that apply)**

- Epiglottis, posterior surface (laryngeal aspect)
- Aryepiglottic folds, laryngeal aspect
- False vocal cord
- Ventricle

Glottic larynx: \_\_\_\_\_

**+Tumor Subsite(s) (select all that apply)**

- True vocal cord
- Anterior commissure
- Posterior commissure

Subglottic larynx: \_\_\_\_\_

Trachea: \_\_\_\_\_

Cervical esophagus: \_\_\_\_\_

Nasopharynx: \_\_\_\_\_

**+Tumor Subsite(s) (select all that apply)**

- Superior wall
- Posterior wall
- Anterior wall
- Lateral wall (including lateral pharyngeal recess [i.e., Rosenmüller fossa])
- Nasopharyngeal tonsils (adenoids)

Nasal and paranasal sinuses: \_\_\_\_\_

**+Tumor Subsite(s) (select all that apply)**

- Nasal septum
- Nasal floor
- Nasal lateral wall
- Nasal vestibule
- Nasal cavity, NOS
- Middle ear
- Paranasal sinus(es), maxillary
- Paranasal sinus(es), ethmoid
- Paranasal sinus(es), frontal
- Paranasal sinus(es), sphenoid

Other (specify): \_\_\_\_\_

Not specified

**Tumor Laterality (select all that apply)**

- Right
- Left
- Midline
- Not specified

**Tumor Size**

- Greatest dimension in Centimeters (cm): \_\_\_\_\_ cm
- Cannot be determined (explain): \_\_\_\_\_

**+Histologic Subtype (Note [C](#))**

- Desmoplastic
- Lentiginous
- Nodular
- Other (specify): \_\_\_\_\_

**+Histologic Type Comment:** \_\_\_\_\_

**+Necrosis**

- Not identified
- Present

**+Tumor Extent (select all that apply)**

*pT3*

- Limited to mucosa and / or submucosa

*pT4a*

- Deep soft tissues or muscle
- Cartilage
- Bone
- Overlying Skin

*pT4b*

- Brain
- Dura
- Skull base
- Any lower cranial nerves (IX, X, XI, XII)
- Masticator space
- Carotid artery encasement
- Prevertebral space
- Mediastinal structures

*Other*

- Other (specify): \_\_\_\_\_
- Cannot be determined: \_\_\_\_\_

**Lymphatic and / or Vascular Invasion (Note [D](#))**

- Not identified
- Present: \_\_\_\_\_
- Cannot be determined (explain): \_\_\_\_\_

**Perineural Invasion (Note D)**

- Not identified
- Present
- Cannot be determined (explain): \_\_\_\_\_

**+Post Therapy Changes**

- No known presurgical therapy
- Not identified
- Present: \_\_\_\_\_

**+Specify Percentage of Treatment Effect:** \_\_\_\_\_ %

**+Tumor Comment:** \_\_\_\_\_

**MARGINS (Note E)**

**Specimen Margin Status for Invasive Melanoma**

- All specimen margins negative for mucosal melanoma

**Distance from Invasive Melanoma to Closest Specimen Margin**

*Specify in Millimeters (mm)*

- Exact distance: \_\_\_\_\_ mm
- Greater than: \_\_\_\_\_ mm
- Less than 1 mm
- Other (specify): \_\_\_\_\_
- Cannot be determined (explain): \_\_\_\_\_

**Closest Specimen Margin(s) to Invasive Melanoma**

- Specify location(s) of closest specimen margin(s): \_\_\_\_\_
- Cannot be determined (explain): \_\_\_\_\_

**+Other Close Specimen Margin(s) to Invasive Melanoma**

- Specify location(s) and distance(s) of other close specimen margin(s): \_\_\_\_\_
- Cannot be determined: \_\_\_\_\_

- Invasive tumor present at specimen margin(s)

**Specimen Margin(s) Involved by Invasive Melanoma (per orientation)**

- Specify involved specimen margin(s): \_\_\_\_\_
- Cannot be determined (explain): \_\_\_\_\_
- Other (specify): \_\_\_\_\_
- Cannot be determined (explain): \_\_\_\_\_
- Not applicable

**Specimen Margin Status for Melanoma In Situ (required only if applicable)#**

# Specimen Margin status for melanoma in situ is required only for mucosal melanoma when closer than invasive tumor.

- Not applicable
- All specimen margins negative for in situ disease

**+Distance from Melanoma In Situ to Closest Specimen Margin**

*Specify in Millimeters (mm)*

Exact distance: \_\_\_\_\_ mm

Greater than: \_\_\_\_\_ mm

Less than 1 mm

Other (specify): \_\_\_\_\_

Cannot be determined: \_\_\_\_\_

**+Closest Specimen Margin(s) to Melanoma In Situ (use orientation when provided)**

Specify closest specimen margin(s): \_\_\_\_\_

Cannot be determined: \_\_\_\_\_

In situ disease present at specimen margin

**Specimen Margin(s) Involved by Melanoma In Situ (per orientation)**

Specify involved specimen margin(s): \_\_\_\_\_

Cannot be determined (explain): \_\_\_\_\_

Other (specify): \_\_\_\_\_

Cannot be determined (explain): \_\_\_\_\_

**+Tumor Bed Margin Status (separately submitted)**

Tumor bed margins assessed

**+Tumor Bed Margin Orientation**

Oriented to true margin surface

Unoriented to true margin surface

Cannot be determined (explain): \_\_\_\_\_

**Tumor Bed Margin Status for Melanoma**

All tumor bed margins negative for invasive tumor

**+Distance from Melanoma to True Margin Surface (pertinent to oriented specimens which are sectioned perpendicularly)**

*Specify in Millimeters (mm)*

Exact distance: \_\_\_\_\_ mm

Greater than: \_\_\_\_\_ mm

Less than 1 mm

Other (specify): \_\_\_\_\_

Cannot be determined: \_\_\_\_\_

Invasive tumor present at tumor bed margin(s)

**Tumor Bed Margin(s) Involved by Melanoma (per part labeling)**

Specify involved tumor bed margin(s): \_\_\_\_\_

Cannot be determined (explain): \_\_\_\_\_

**+Tumor Bed Margin Status for Melanoma In Situ**

All tumor bed margins negative for melanoma in situ

**+Distance from Melanoma In Situ to True Margin Surface (pertinent to oriented specimens which are sectioned perpendicularly)**

*Specify in Millimeters (mm)*

- Exact distance: \_\_\_\_\_ mm
- Greater than: \_\_\_\_\_ mm
- Less than 1 mm
- Other (specify): \_\_\_\_\_
- Cannot be determined: \_\_\_\_\_
- Melanoma in situ present at tumor bed margin(s)

**Tumor Bed Margin(s) Involved by Melanoma In Situ (per part labeling)**

- Specify involved tumor bed margin(s): \_\_\_\_\_
- Cannot be determined (explain): \_\_\_\_\_
- Other(specify): \_\_\_\_\_
- Cannot be determined (explain): \_\_\_\_\_
- Other (specify): \_\_\_\_\_
- Cannot be determined (explain): \_\_\_\_\_
- Not applicable

**+Margin Comment:** \_\_\_\_\_

**REGIONAL LYMPH NODES (Note [E](#))**

**Regional Lymph Node Status**

- Not applicable (no regional lymph nodes submitted or found)
- Regional lymph nodes present
  - All regional lymph nodes negative for tumor
  - Tumor present in regional lymph node(s)

**Number of Sentinel Lymph Node(s) with Tumor (required only if applicable)**

- Not applicable
- Exact number (specify): \_\_\_\_\_
- At least (specify): \_\_\_\_\_
- Other (specify): \_\_\_\_\_
- Cannot be determined (explain): \_\_\_\_\_

**Total Number of Lymph Nodes with Tumor (sentinel and non-sentinel)**

- Exact number (specify): \_\_\_\_\_
- At least (specify): \_\_\_\_\_
- Other (specify): \_\_\_\_\_
- Cannot be determined (explain): \_\_\_\_\_

**+Nodal Site(s) with Tumor (select all that apply)**

- Intraparotid: \_\_\_\_\_
- Periparotid: \_\_\_\_\_
- Level I: \_\_\_\_\_
- Level II: \_\_\_\_\_
- Level III: \_\_\_\_\_
- Level IV: \_\_\_\_\_
- Level V: \_\_\_\_\_
- Other (specify): \_\_\_\_\_
- Cannot be determined: \_\_\_\_\_

**+Size of Largest Sentinel Node Metastatic Deposit**

*Specify in Millimeters (mm)*

Exact size (specify): \_\_\_\_\_ mm

At least: \_\_\_\_\_ mm

Greater than: \_\_\_\_\_ mm

Less than: \_\_\_\_\_ mm

Other (specify): \_\_\_\_\_

Cannot be determined (explain): \_\_\_\_\_

**+Size of Largest Non-sentinel Node Metastatic Deposit**

*Specify in Millimeters (mm)*

Exact size (specify): \_\_\_\_\_ mm

At least: \_\_\_\_\_ mm

Greater than: \_\_\_\_\_ mm

Less than: \_\_\_\_\_ mm

Other (specify): \_\_\_\_\_

Cannot be determined (explain): \_\_\_\_\_

**Extranodal Extension (ENE)**

Not identified

Present

Cannot be determined (explain): \_\_\_\_\_

**Matted Nodes**

Not identified

Present

Other (specify): \_\_\_\_\_

Cannot be determined (explain): \_\_\_\_\_

**Total Number of Lymph Nodes Examined (sentinel and non-sentinel)**

Exact number (specify): \_\_\_\_\_

At least (specify): \_\_\_\_\_

Other (specify): \_\_\_\_\_

Cannot be determined (explain): \_\_\_\_\_

**Number of Sentinel Nodes Examined (required only if applicable)**

Not applicable

Exact number (specify): \_\_\_\_\_

At least (specify): \_\_\_\_\_

Other (specify): \_\_\_\_\_

Cannot be determined (explain): \_\_\_\_\_

**+Regional Lymph Node Comment:** \_\_\_\_\_

**DISTANT METASTASIS**

**Distant Site(s) Involved, if applicable (select all that apply)**

Not applicable

Lung: \_\_\_\_\_

- Bone: \_\_\_\_\_  
 Brain: \_\_\_\_\_  
 Liver: \_\_\_\_\_  
 Other (specify): \_\_\_\_\_  
 Cannot be determined (explain): \_\_\_\_\_

**pTNM CLASSIFICATION (AJCC 8th Edition) (Note [G](#))**

*Reporting of pT, pN, and (when applicable) pM categories is based on information available to the pathologist at the time the report is issued. As per the AJCC (Chapter 1, 8th Ed.) it is the managing physician's responsibility to establish the final pathologic stage based upon all pertinent information, including but potentially not limited to this pathology report.*

**Modified Classification (required only if applicable) (select all that apply)**

- Not applicable  
 y (post-neoadjuvant therapy)  
 r (recurrence)

**pT Category**

pT3: Tumors limited to the mucosa and immediately underlying soft tissue, regardless of thickness or greatest dimension; for example, polypoid nasal disease, pigmented or nonpigmented lesions of the oral cavity, pharynx, or larynx

*pT4: Moderately advanced or very advanced*

- pT4a: Moderately advanced disease. Tumor involving deep soft tissue, cartilage, bone, or overlying skin  
 pT4b: Very advanced disease. Tumor involving brain, dura, skull base, lower cranial nerves (IX, X, XI, XII), masticator space, carotid artery, prevertebral space, or mediastinal structures  
 pT4 (subgroup cannot be determined)

**T Suffix (required only if applicable)**

- Not applicable  
 (m) multiple primary synchronous tumors in a single organ

**pN Category**

- pN not assigned (no nodes submitted or found)  
 pN not assigned (cannot be determined based on available pathological information)  
 pN0: No regional lymph node metastases  
 pN1: Regional lymph node metastases present

**N Suffix (required only if applicable) (select all that apply)**

- Not applicable  
 (sn) Sentinel node procedure  
 (f) FNA or core needle biopsy

**pM Category (required only if confirmed pathologically)**

- Not applicable - pM cannot be determined from the submitted specimen(s)  
 pM1: Distant metastasis present

**SPECIAL STUDIES**

CAP  
Approved

HN.MucosalMelanoma.Res\_1.0.0.0.REL\_CAPCP

*Pending biomarker studies should be listed in the Comments section of this report.*

**+Specify Test and Results (repeat as needed):** \_\_\_\_\_

**COMMENTS**

**Comment(s):** \_\_\_\_\_

RETIRED

## Explanatory Notes

### A. Specimen

Surgery is the mainstay of treatment for locally advanced head and neck mucosal melanoma, with adjuvant radiotherapy playing a role in local disease control. Targeted therapy and immunotherapy have changed the treatment of cutaneous melanoma, and are being explored in mucosal melanoma.<sup>1,2</sup> The main objective of surgery is total tumor resection with clear margins.<sup>3</sup> The use of frozen sections for evaluation of biopsy or excision of melanocytic lesions is strongly discouraged.<sup>4</sup> Similarly, frozen sections of sentinel lymph nodes are discouraged in light of decreased sensitivity.<sup>5</sup>

### References

1. Motoo Nomura. Definitive treatment for head and neck mucosal melanoma. *Japanese Journal of Clinical Oncology*, Volume 53, Issue 12, December 2023, Pages 1112–1118, <https://doi.org/10.1093/jjco/hyad109>.
2. Hanba C, Hanna E. Head and Neck Mucosal Melanoma: Where Are We Now? *Curr Oncol Rep*. 2024 Apr;26(4):421-425. doi: 10.1007/s11912-024-01513-w. Epub 2024 Mar 21. PMID: 38512416.
3. Foreman RK, Duncan LM. Sinonasal Mucosal Melanoma: A Contemporary Review. *Surg Pathol Clin*. 2024 Dec;17(4):667-682. doi: 10.1016/j.path.2024.07.006. Epub 2024 Aug 17. PMID: 39489556.
4. Chiu AG, Ma Y. Accuracy of intraoperative frozen margins for sinonasal malignancies and its implications for endoscopic resection of sinonasal melanomas. *Int Forum Allergy Rhinol*. 2013 Feb;3(2):157-60. doi: 10.1002/alr.21075. Epub 2012 Sep 12. PMID: 22972711.
5. Scolyer RA, Thompson JF, McCarthy SW, Gershenwald JE, Ross MI, Cochran AJ. Intraoperative frozen-section evaluation can reduce accuracy of pathologic assessment of sentinel nodes in melanoma patients. *J Am Coll Surg*. 2005 Nov;201(5):821-3; author reply 823-4. doi: 10.1016/j.jamcollsurg.2005.07.017. PMID: 16256927.

### B. Anatomic Sites and Subsites

#### Anatomic Sites and Subsites for Oral Cavity<sup>1</sup>

- Mucosa of wet upper and lower lips
- Buccal mucosa
  - Cheek mucosa
  - Retromolar areas
- Upper alveolus and gingiva (upper gum)
- Lower alveolus and gingiva (lower gum)
- Hard palate
- Tongue
  - Dorsal surface and lateral borders anterior to circumvallate papillae (anterior two-thirds)
  - Inferior (ventral) surface
- Floor of mouth

The protocol applies to all melanomas arising at these sites.

**Mucosal Lip.** The mucosal lip begins at the junction of the wet and dry mucosa of the lip (the anterior border of the portion of the lip that comes into contact with the opposed lip) and extends posteriorly into the oral cavity to the attached gingiva of the alveolar ridge. For staging purposes, tumors of the dry vermilion

lip and vermillion border are now grouped with cutaneous sites given their shared pathogenesis and similar embryologic origin of these subsites to skin; only mucosal sites are covered by this protocol.

**Buccal Mucosa (Inner Cheek).** This includes all the membrane lining of the inner surface of the cheeks and lips from the line of contact of the opposing lips to the line of attachment of mucosa of the alveolar ridge (upper and lower) and pterygomandibular raphe.

**Lower Alveolar Ridge.** This refers to the mucosa overlying the alveolar process of the mandible, which extends from the line of attachment of mucosa in the buccal gutter to the line of free mucosa of the floor of the mouth. Posteriorly it extends to the ascending ramus of the mandible.

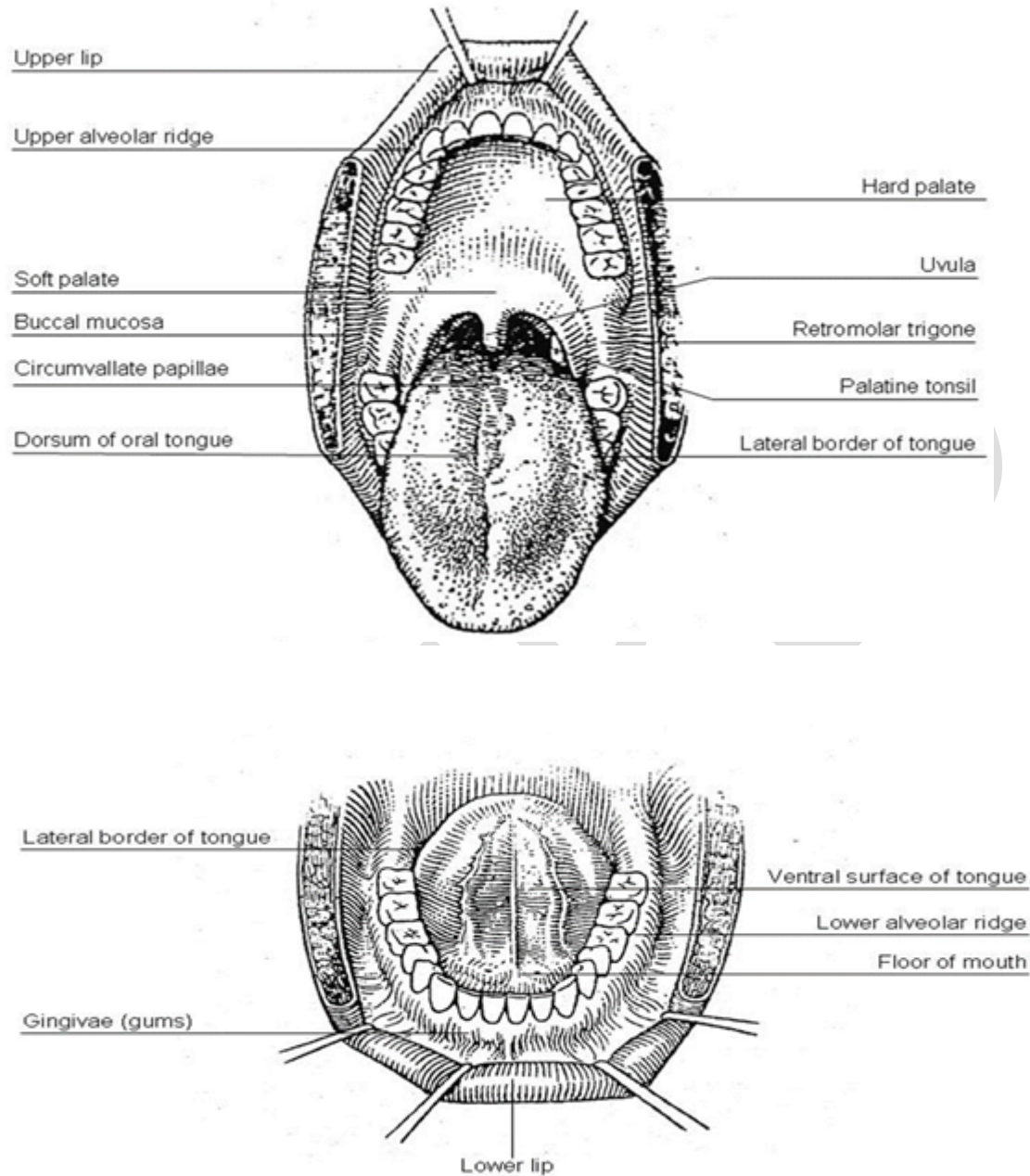
**Upper Alveolar Ridge.** This refers to the mucosa overlying the alveolar process of the maxilla, which extends from the line of attachment of mucosa in the upper gingival buccal gutter to the junction of the hard palate. Its posterior margin is the upper end of the pterygopalatine arch.

**Retromolar Gingiva (Retromolar Trigone).** This is the attached mucosa overlying the ascending ramus of the mandible from the level of the posterior surface of the last molar tooth and the apex superiorly, adjacent to the tuberosity of the maxilla.

**Floor of the Mouth.** This is a semilunar space over the mylohyoid and hyoglossus muscles, extending from the inner surface of the lower alveolar ridge to the undersurface of the tongue. Its posterior boundary is the base of the anterior pillar of the tonsil. It is divided into 2 sides of the submaxillary and sublingual salivary glands.

**Hard Palate.** This is the semilunar area between the upper alveolar ridge and the mucous membrane covering the palatine process of the maxillary palatine bones. It extends from the inner surface of the superior alveolar ridge to the posterior edge of the palatine bone.

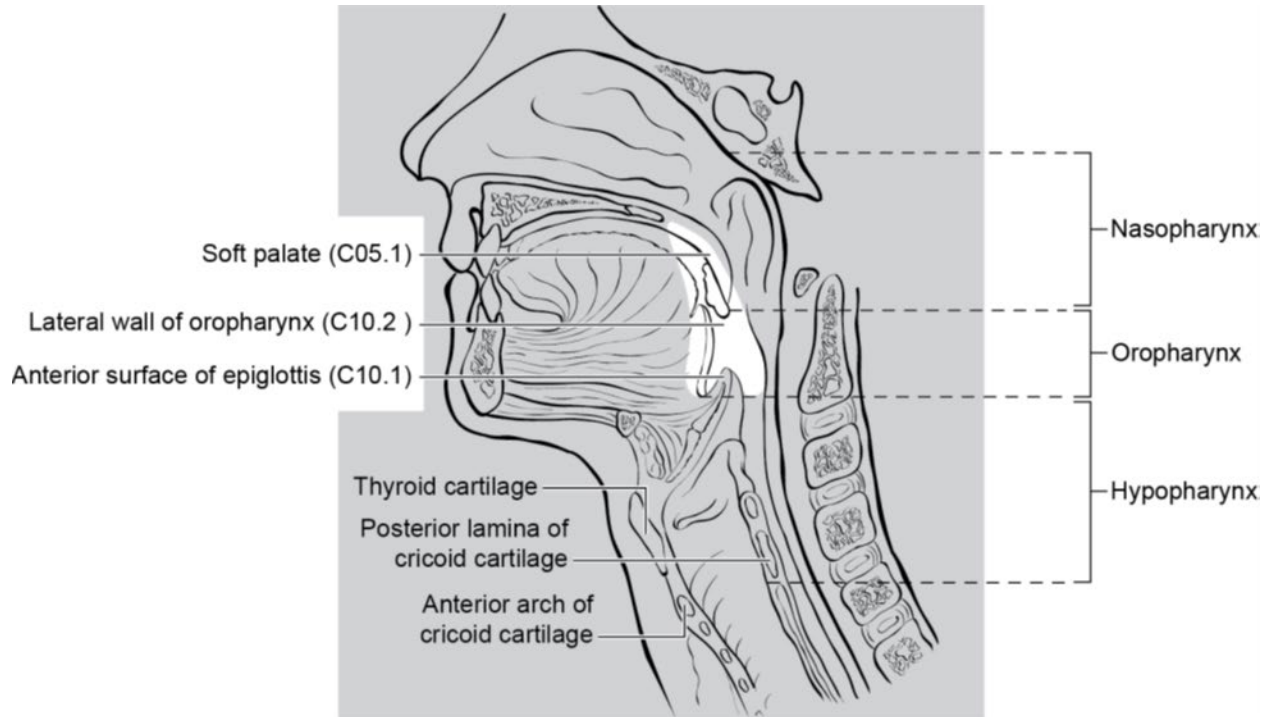
**Anterior Two-Thirds of the Tongue (Oral Tongue).** This is the freely mobile portion of the tongue that extends anteriorly from the line of circumvallate papillae to the undersurface of the tongue at the junction of the floor of the mouth. It is composed of 4 areas: the tip, the lateral borders, the dorsum, and the undersurface (non-villous ventral surface of the tongue).



**Figure 1.** Diagrams illustrating the oral cavity anatomic subsites. Figure courtesy of Beth Israel Medical Center, St. Luke's and Roosevelt Hospitals, New York.

**Anatomic Sites and Subsites for Pharynx<sup>2,3</sup>**

The pharynx is divided into 3 parts including the nasopharynx, oropharynx, and hypopharynx (Figure 2).



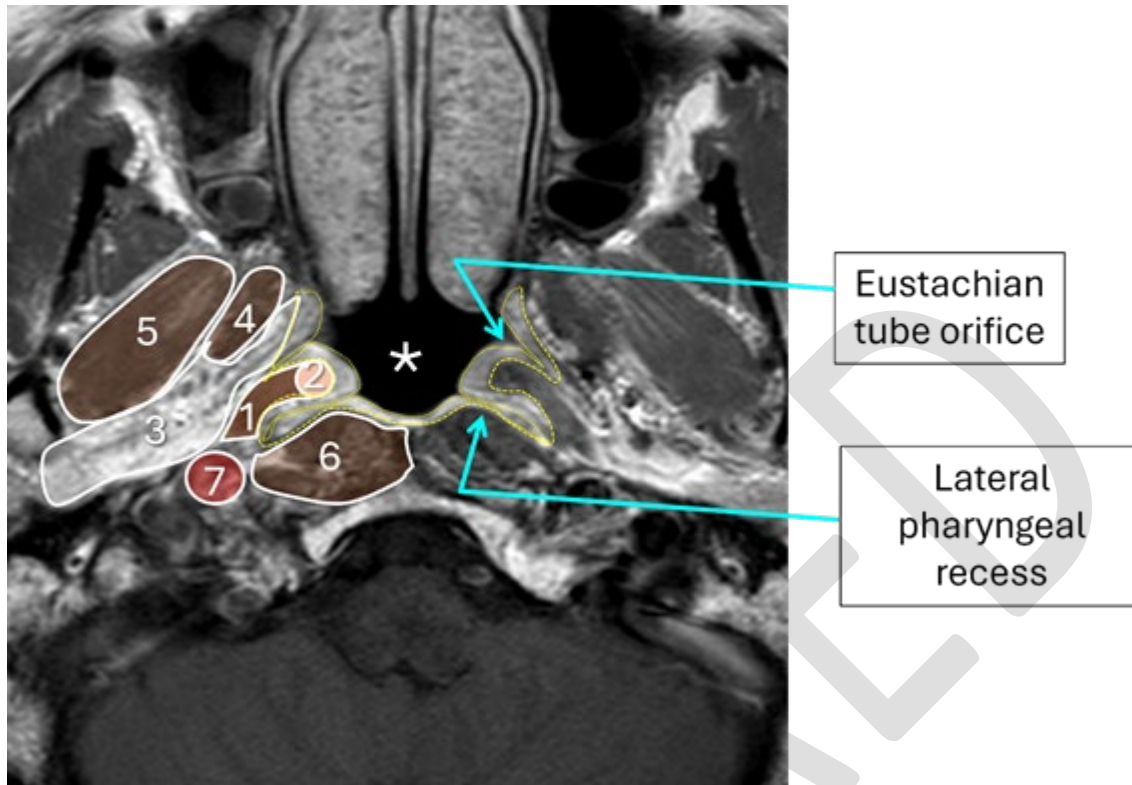
**Figure 2.** Anatomic subdivisions and “contents” of the pharynx. Evans M, Huang S, Ho A, et al. American Joint Committee on Cancer (AJCC). 2025. AJCC Protocol for Cancer Staging: Oropharynx (HPV-Associated) (Version 9). Reproduced with permission.

### Nasopharynx

The nasopharynx is situated behind the nasal cavity and above the soft palate; it begins anteriorly at the posterior choana and extends along the plane of the airway to the level of the free border of the soft palate.

The subsites of the nasopharynx include:

- Superior
- Posterior
- Lateral (including lateral pharyngeal recess, i.e., Rosenmüller fossa)
- Nasopharyngeal tonsils (adenoids)



**Figure 3.** AWM, Huang SH, Chua MLK, et al. Nasopharynx. In: Washington MK, ed. *AJCC Cancer Staging System*. 9th ver. American College of Surgeons; 2025. Reproduced with permission.

The nasopharynx is associated with several key anatomic structures (Figure 3). This nasopharynx axial MRI shows:

1. Levator palatini muscle (brown)
2. Torus tubarius (pink), mucosa/submucosa outlined in yellow.
3. Parapharyngeal fat containing venous plexus and nerves (white)
4. Medial pterygoid muscle (brown)
5. Lateral pterygoid muscle (brown)
6. Prevertebral muscles (brown)
7. Carotid sheath

### Oropharynx

The oropharynx is the portion of the continuity of the pharynx extending from the plane of the superior surface of the soft palate to the superior surface of the hyoid bone or floor of the vallecula. The contents of the oropharynx include:

- soft palate
- palatine tonsils
- anterior and posterior tonsillar pillars
- tonsillar fossa and tonsillar (faucial) pillars
- uvula
- base of tongue, including the lingual tonsils

- vallecule
- posterior oropharyngeal wall

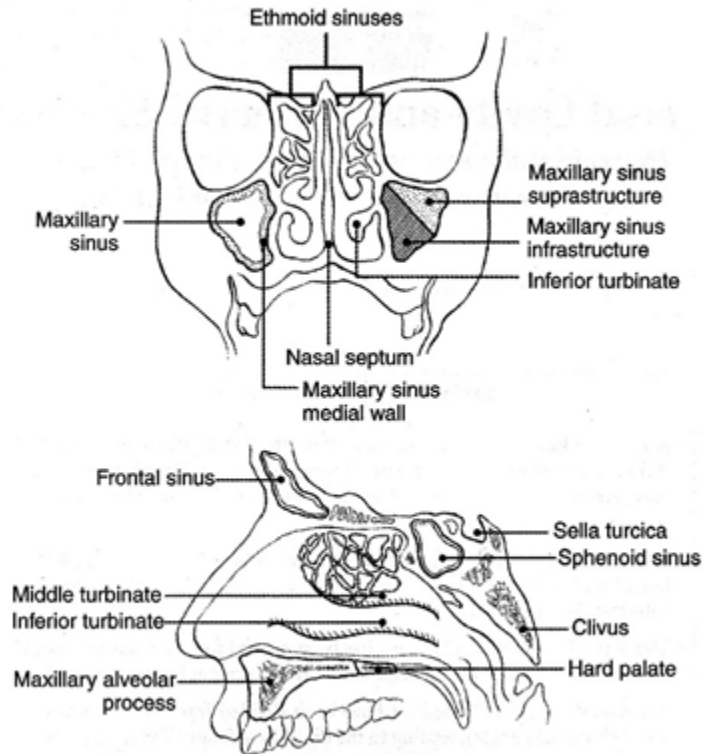
### **Hypopharynx**

The hypopharynx is the portion of the pharynx extending from the plane of the superior border of the hyoid bone (or floor of the vallecule) to the plane corresponding to the lower border of the cricoid cartilage. The contents of the hypopharynx include:

- piriform sinus (right and left) - represents part of the hypopharynx which expands bilaterally and forward around the sides of the larynx and lies between the larynx and the thyroid cartilage
- lateral and posterior hypopharyngeal walls
- postcricoid region extending from the level of the arytenoid cartilage and connecting folds to the inferior border of the cricoid cartilage; it connects the 2 piriform sinuses, thereby forming the anterior wall of the hypopharynx

### **Anatomic Sites and Subsites for the Nasal Cavity and Paranasal Sinuses**<sup>4,5</sup>

The nasal cavity is divided in the midline to right and left halves by the septum; each half opens on the face via the nares or nostrils and communicates behind with the nasopharynx through the posterior nasal apertures or the choanae. The nasal cavity is divided into 4 subsites including the septum, floor, lateral wall, and vestibule. The paranasal sinuses represent a grouping of 4 paired sinuses including the maxillary sinuses, ethmoid sinuses, frontal sinuses, and sphenoid sinuses. The nasoethmoidal complex is divided into 2 sites including the nasal cavity and the ethmoid sinuses (Figure 4). Ohngren's line, connecting the medial canthus of the eye to the angle of the mandible, divides the maxillary sinus into an anteroinferior portion (infrastructure) and superioposterior portion (suprastructure).



**Figure 4.** Anatomic sites and subsites for the nasal cavity and paranasal sinuses. From AJCC Cancer Staging Manual. 6<sup>th</sup> ed. New York: Springer; 2002. © American Joint Committee on Cancer. Reproduced with permission.

### **Anatomic Sites and Subsites for the Larynx<sup>6</sup>**

#### **Supraglottis**

Epilarynx, including marginal zone

- Suprahyoid epiglottis, including tip, and laryngeal surfaces
- Aryepiglottic fold, laryngeal aspect
- Arytenoid

Supraglottis, excluding epilarynx

- Infrahyoid epiglottis
- Ventricular bands (false cords)
- Ventricle

#### **Glottis**

- Vocal cords

- Anterior commissure
- Posterior commissure

### **Subglottis**

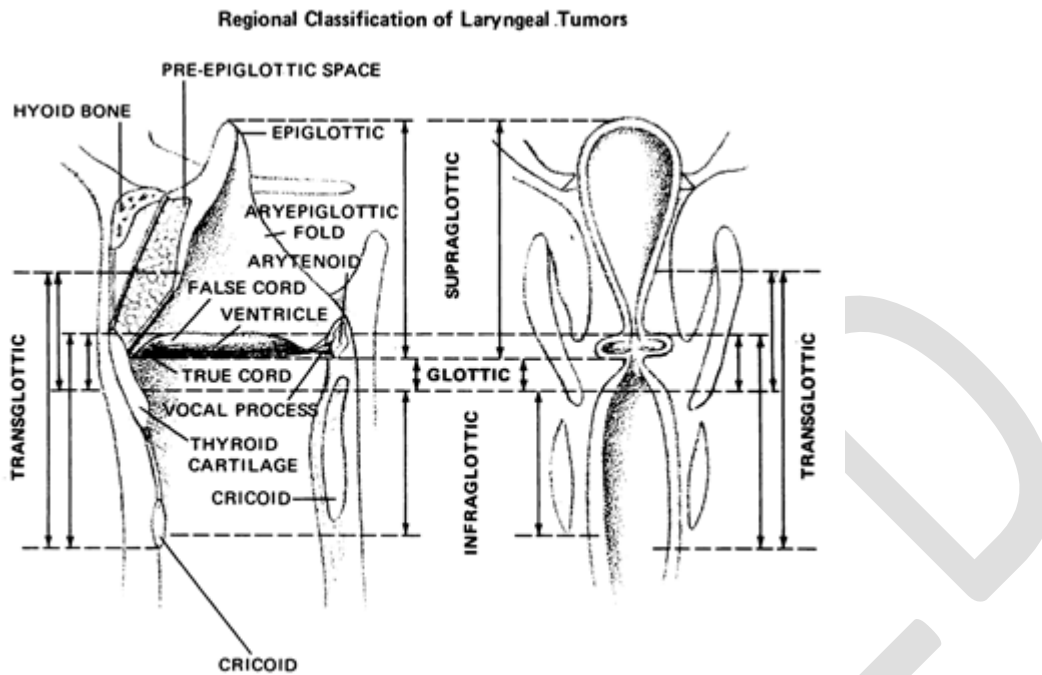
#### **Other**

Cancers of the pyriform sinus are included in the protocol on hypopharynx cancers.

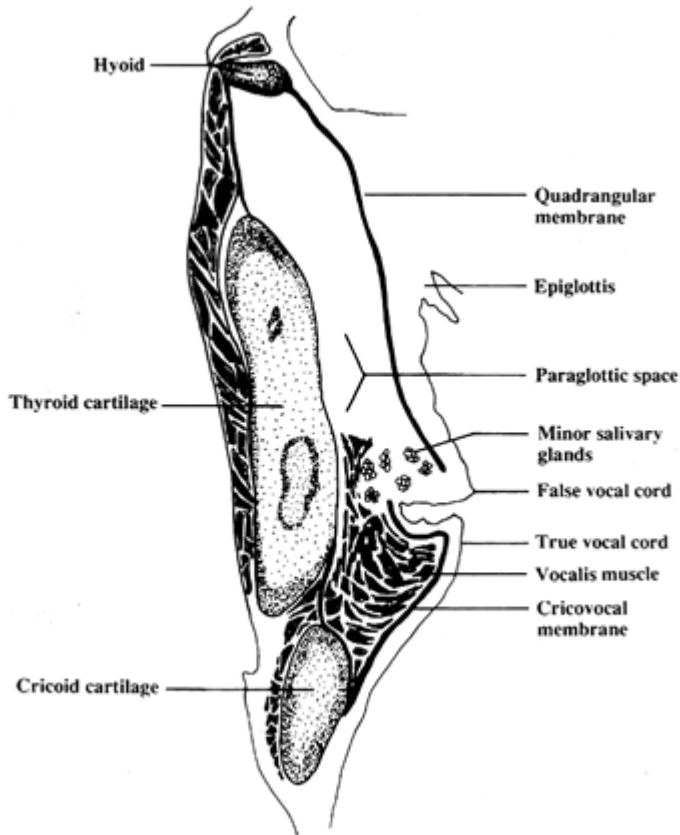
#### **Anatomic Compartments (Figure 5)**

The anatomic compartments of the larynx include:

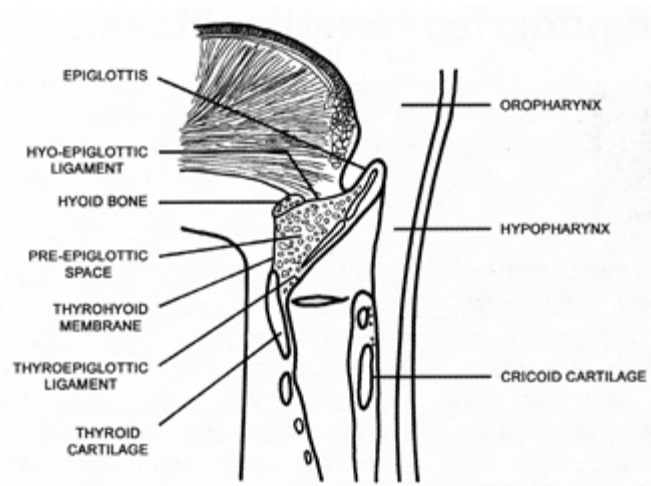
1. Supraglottic larynx extending from the tip of the epiglottis to a horizontal line passing through the apex of the ventricle; structures included in this compartment are the epiglottis (lingual and laryngeal aspects), aryepiglottic folds, arytenoids, false vocal cords and the ventricle.
2. Glottic region, which extends from the ventricle to approximately 0.5 cm to 1.0 cm below the free level of the true vocal cord and includes the anterior and posterior commissures and the true vocal cord.
3. Subglottic larynx, which extends approximately 1.0 cm below the level of the true vocal cord to the inferior rim of the cricoid cartilage.
4. The paraglottic space is a potential space deep to the ventricles and saccules filled with adipose tissue and connective tissue (Figure 6). It is bounded by the conus elasticus inferiorly, the thyroid cartilage laterally, the quadrangular membrane medially, and the pyriform sinus posteriorly. Like the paraglottic space, the pre-epiglottic space is filled with adipose tissue and connective tissue (Figure 7); it is triangular in shape and is bounded by the thyroid cartilage and thyrohyoid membrane anteriorly, the epiglottis and thyroepiglottic ligament posteriorly, and the hyoepiglottic ligament at its base (Figures 5 and 6). The paraglottic and preglottic spaces contain lymphatics and blood vessels but no lymph nodes.



**Figure 5.** Anatomic compartments of the larynx. From Cocke EW Jr, Wang CC. Part I - Cancer of the larynx: selecting optimum treatment. *CA Cancer J Clin.* 1976; 26:194-200. Figure by J.H. Ogura, MD. Reproduced with permission.



**Figure 6.** The paraglottic space. From World Health Organization Classification of Tumours: Pathology and Genetics of Head and Neck Tumours. Lyon, France: IARC Press; 2005. Reproduced with permission.



**Figure 7.** The pre-epiglottic space. From World Health Organization Classification of Tumours: Pathology and Genetics of Head and Neck Tumours. Lyon, France: IARC Press; 2005. Reproduced with permission.

#### References

1. Ridge JA, Lydiatt WM, Patel SG, et al. Oral Cavity. In: Amin MB, ed. *AJCC Cancer Staging Manual*. 8th ed. New York, NY: Springer; 2017.
2. AWM, Huang SH, Chua MLK, et al. Nasopharynx. In: Washington MK, ed. *AJCC Cancer Staging System*. 9th ver. American College of Surgeons; 2025.
3. Lydiatt WM, Ridge JA, Patel SG, et al. Oropharynx (p16 -) and hypopharynx. In: Amin MB, ed. *AJCC Cancer Staging Manual*. 8th ed. New York, NY: Springer; 2017.
4. Gress DM, Edge SB, Greene FL, et al. Principles of cancer staging. In: Amin MB, ed. *AJCC Cancer Staging Manual*. 8th ed. New York, NY: Springer; 2017.
5. Kraus DH, Lydiatt WM, Patel SG, et al. Nasal cavity paranasal sinuses. In: Amin MB, ed. *AJCC Cancer Staging Manual*. 8th ed. New York, NY: Springer; 2017.
6. Patel SG, Lydiatt WM, Glastonbury CM, et al. Larynx. In: Amin MB, ed. *AJCC Cancer Staging Manual*. 8th ed. New York, NY: Springer; 2017.

#### C. Histologic Type

Given the rarity of mucosal melanoma, subtyping and grading are not required. However, as the WHO recognizes three histologic subtypes (desmoplastic, lentiginous, and nodular), these are included as non-required elements.<sup>1</sup> If the melanoma represents a metastasis to mucosa from a non-mucosal site, synoptic and stage should not be provided.

#### References

1. WHO Classification of Tumours Editorial Board. *Head and neck tumours* [Internet; beta version ahead of print]. Lyon (France): International Agency for Research on Cancer; 2022 [cited 2026, Jan 23]. (WHO classification of tumours series, 5th ed.; vol. 9). Available from: <https://tumourclassification.iarc.who.int/chapters/52>

#### D. Lymphatic and/or Vascular and Perineural Invasion

Some studies have suggested that lymphovascular and perineural invasion are not statistically significant in the prognostication of mucosal melanoma.<sup>1</sup> However, these parameters are reported in all head and neck malignancies, and clinical teams may use these features in developing patient-specific treatment protocols.

#### References

1. Hahn HM, Lee KG, Choi W, Cheong SH, Myung KB, Hahn HJ. An updated review of mucosal melanoma: Survival meta-analysis. *Mol Clin Oncol*. 2019 Aug;11(2):116-126. doi: 10.3892/mco.2019.1870. Epub 2019 May 29. PMID: 31281645; PMCID: PMC6589937.

#### E. Surgical Margin

Complex specimens should be examined and oriented with the assistance of the operating surgeon(s). Direct communication between the surgeon and pathologist is a critical component in specimen orientation and proper sectioning. Whenever possible, the tissue examination request form should include a drawing or photograph of the resected specimen showing the extent of the tumor and its relation to the anatomic structures of the region. The lines and extent of the resection can be depicted on preprinted adhesive labels and attached to the surgical pathology request forms.

Studies support the definition of a positive margin to be invasive melanoma or melanoma in situ present at margins (microscopic cut-through of tumor). Furthermore, reporting of surgical margins should also include information regarding the distance of invasive melanoma or melanoma in situ from the surgical margin. Margin status in mucosal melanomas is often regarded as most important morphologic determinant of disease-specific and overall survival.<sup>1,2</sup>

#### References

1. Hahn HM, Lee KG, Choi W, Cheong SH, Myung KB, Hahn HJ. An updated review of mucosal melanoma: Survival meta-analysis. *Mol Clin Oncol*. 2019 Aug;11(2):116-126. doi: 10.3892/mco.2019.1870. Epub 2019 May 29. PMID: 31281645; PMCID: PMC6589937.
2. Motoo Nomura, Definitive treatment for head and neck mucosal melanoma, *Japanese Journal of Clinical Oncology*, Volume 53, Issue 12, December 2023, Pages 1112–1118, <https://doi.org/10.1093/jjco/hyad109>

#### F. Regional Lymph Nodes

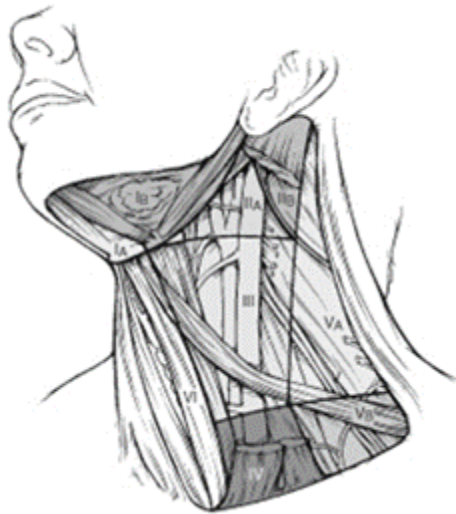Lymph nodes may be removed in a standard neck dissection or as sentinel lymph nodes. Frozen section analysis of sentinel lymph nodes is not advised.<sup>1</sup> For histologic examination, whether for sentinel node analysis or for routine regional lymph node evaluation, the entire node, except tissue collected for consented research protocols (not advised for sentinel lymph nodes), should be submitted. For routine evaluation, large lymph nodes (greater than or equal to 5 mm) may be bisected or sliced at 2-3 mm intervals, whereas smaller nodes (less than 5 mm) may be submitted whole. At the current time, no additional special techniques are required other than routine histology for the assessment of non-sentinel lymph nodes. Regarding sentinel nodes, the risk of finding a positive sentinel lymph node is related to thickness of the melanoma, ulceration, and the number of mitoses in the primary tumor. Positive sentinel lymph nodes predict higher rates of recurrence and worse disease-specific and overall survival.<sup>2,3</sup> Therefore, immunohistochemical stains (e.g., HMB45, MART1/MelanA, SOX10, or melanocytic cocktails) should be considered in the examination of sentinel lymph nodes that are apparently negative on H&E stains. The use of immunostains is thought to increase the sensitivity of detection of microscopic melanoma metastases. All lymph nodes with metastatic tumor cells (regardless of size, number of cells, or whether they were identified on H&E or immunostained sections) are regarded as positive. The cross-sectional diameter of the largest lymph node metastasis (not the lymph node itself) is measured in the gross specimen at the time of macroscopic examination or, if necessary, on the histologic slide at the time of microscopic examination.<sup>4,5</sup> Tumor deposit size and the presence of extranodal extension are non-required elements for mucosal melanomas, as they are not critical for staging or outcome-prediction.

For purposes of pathologic evaluation, lymph nodes are organized by levels as shown in Figure 8.

#### Classification of Neck Dissection

1. Radical neck dissection
2. Modified radical neck dissection, internal jugular vein and/or sternocleidomastoid muscle spared
3. Selective neck dissection (SND), as specified by the surgeon (Figure 1), defined by dissection of less than the 5 traditional levels of a radical and modified radical neck dissection. The following dissections are now under this category:<sup>4,6,7</sup>
  1. Supraomohyoid neck dissection
  2. Posterolateral neck dissection
  3. Lateral neck dissection

4. Central compartment neck dissection
4. Superselective neck dissection (SSND), a relatively new term defined by dissection of the fibrofatty elements of 2 or less levels<sup>8</sup>
5. Extended radical neck dissection, as specified by the surgeon



**Figure 8.** The 6 sublevels of the neck for describing the location of lymph nodes within levels I, II, and V. Level IA, submental group; level IB, submandibular group; level IIA, upper jugular nodes along the carotid sheath, including the subdigastric group; level IIB, upper jugular nodes in the submuscular recess; level VA, spinal accessory nodes; and level VB, the supraclavicular and transverse cervical nodes. From: Flint PW, et al, eds. *Cummings Otolaryngology: Head and Neck Surgery*. 5<sup>th</sup> ed. Philadelphia, PA; Saunders: 2010. Reproduced with permission © Elsevier.

In order for pathologists to properly identify these nodes, they must be familiar with the terminology of the regional lymph node groups and with the relationships of those groups to the regional anatomy. Which lymph node groups surgeons submit for histopathologic evaluation depends on the type of neck dissection they perform. Therefore, surgeons must supply information on the types of neck dissections that they perform and on the details of the local anatomy in the specimens they submit for examination or, in other manners, orient those specimens for pathologists.

If it is not possible to assess the levels of lymph nodes (for instance, when the anatomic landmarks in the excised specimens are not specified), then the lymph node levels may be estimated as follows: level II, upper third of internal jugular (IJ) vein or neck specimen; level III, middle third of IJ vein or neck specimen; level IV, lower third of IJ vein or neck specimen, all anterior to the sternocleidomastoid muscle.

#### **Level I. Submental Group (Sublevel IA)**

Lymph nodes within the triangular boundary of the anterior belly of the digastric muscles and the hyoid bone.

#### **Level I. Submandibular Group (Sublevel IB)**

Lymph nodes within the boundaries of the anterior and posterior bellies of the digastric muscle and the body of the mandible. The submandibular gland is included in the specimen when the lymph nodes within this triangle are removed.

**Level II. Upper Jugular Group (Sublevels IIA and IIB)**

Lymph nodes located around the upper third of the internal jugular vein and adjacent spinal accessory nerve extending from the level of the carotid bifurcation (surgical landmark) or hyoid bone (clinical landmark) to the skull base. The posterior boundary is the posterior border of the sternocleidomastoid muscle, and the anterior boundary is the lateral border of the stylohyoid muscle.

**Level III. Middle Jugular Group**

Lymph nodes located around the middle third of the internal jugular vein extending from the carotid bifurcation superiorly to the omohyoid muscle (surgical landmark), or cricothyroid notch (clinical landmark) inferiorly. The posterior boundary is the posterior border of the sternocleidomastoid muscle, and the anterior boundary is the lateral border of the sternohyoid muscle.

**Level IV. Lower Jugular Group**

Lymph nodes located around the lower third of the internal jugular vein extending from the omohyoid muscle superiorly to the clavicle inferiorly. The posterior boundary is the posterior border of the sternocleidomastoid muscle, and the anterior boundary is the lateral border of the sternohyoid muscle.

**Level V. Posterior Triangle Group (Sublevels VA and VB)**

This group comprises predominantly the lymph nodes located along the lower half of the spinal accessory nerve and the transverse cervical artery. The supraclavicular nodes are also included in this group. The posterior boundary of the posterior triangle is the anterior border of the trapezius muscle, the anterior boundary of the posterior triangle is the posterior border of the sternocleidomastoid muscle, and the inferior boundary of the posterior triangle is the clavicle.

**Level VI. Anterior (Central) Compartment**

Lymph nodes in this compartment include the pre- and paratracheal nodes, precricoid (Delphian) node, and the perithyroidal nodes, including the lymph nodes along the recurrent laryngeal nerve. The superior boundary is the hyoid bone, the inferior boundary is the suprasternal notch, the lateral boundaries are the common carotid arteries, and the posterior boundary by the prevertebral fascia.

**Level VII. Superior Mediastinal Lymph Nodes**

Metastases at level VII are considered regional lymph node metastases; all other mediastinal lymph node metastases are considered distant metastases.

Lymph node groups removed from areas not included in the above levels, e.g., scalene, suboccipital, and retropharyngeal, should be identified and reported from all levels separately. Midline nodes are considered ipsilateral nodes.

**References**

1. Scolyer RA, Thompson JF, McCarthy SW, Gershenwald JE, Ross MI, Cochran AJ. Intraoperative frozen-section evaluation can reduce accuracy of pathologic assessment of sentinel nodes in melanoma patients. *J Am Coll Surg*. 2005;201(5):821-823; author reply 823-824.

2. Rubatto M, Picciotto F, Moirano G, Fruttero E, Caliendo V, Borriello S, Sciamarrelli N, Fava P, Senetta R, Lesca A, Sapino A, Deandreis D, Ribero S, Quaglino P. Sentinel Lymph Node Biopsy in Malignant Melanoma of the Head and Neck: A Single Center Experience. *J Clin Med*. 2023 Jan 10;12(2):553. doi: 10.3390/jcm12020553. PMID: 36675481; PMCID: PMC9864837.
3. Passmore-Webb B, Gurney B, Yuen HM, Sloane J, Lee J, Proctor M, Sundram F, Newlands C, Sharma S. Sentinel lymph node biopsy for melanoma of the head and neck: a multicentre study to examine safety, efficacy, and prognostic value. *Br J Oral Maxillofac Surg*. 2019 Nov;57(9):891-897. doi: 10.1016/j.bjoms.2019.07.022. Epub 2019 Aug 26. PMID: 31466802.
4. Seethala RR. Current state of neck dissection in the United States. *Head Neck Pathol*. 2009;3(3):238-245.
5. Ebrahimi A, Gil Z, Amit M. International Consortium for Outcome Research (ICOR) in Head and Neck Cancer. Primary tumor staging for oral cancer and a proposed modification incorporating depth of invasion: an international multicenter retrospective study. *JAMA Otolaryngol Head Neck Surg*. 2014;140(12):1138-1148.
6. Ferlito A, Robbins KT, Shah JP, et al. Proposal for a rational classification of neck dissections. *Head Neck*. 2011;33(3):445-450.
7. Robbins KT, Shaha AR, Medina JE, et al. Consensus statement on the classification and terminology of neck dissection. *Arch Otolaryngol Head Neck Surg*. 2008;134(5):536-538.
8. Suarez C, Rodrigo JP, Robbins KT, et al. Superselective neck dissection: rationale, indications, and results. *Eur Arch Otorhinolaryngol*. 2013.

### G. pTNM Classification

Approximately two-thirds of mucosal melanomas arise in the sinonasal tract, one quarter are found in the oral cavity and the remainder occur only sporadically in other mucosal sites of the head and neck. Even small cancers behave aggressively with high rates of recurrence and death. To reflect this aggressive behavior, primary cancers limited to the mucosa are considered T3 lesions. Advanced mucosal melanomas are classified as T4a and T4b. The anatomic extent criteria to define *moderately advanced* (T4a) and *very advanced* (T4b) disease are given below. The AJCC staging for mucosal melanomas does not provide for the histologic definition of a T3 lesion; as the majority of mucosal melanomas are invasive at presentation, mucosal based melanomas (T3 lesions) include those lesions that involve either the epithelium and/or lamina propria of the involved site. Rare examples of in situ mucosal melanomas occur, but In situ mucosal melanomas are excluded from staging, as they are extremely rare.<sup>1</sup>

By AJCC/UICC convention, the designation “T” refers to a primary tumor that has not been previously treated. The symbol “p” refers to the pathologic classification of the TNM, as opposed to the clinical classification, and based on clinical stage information supplemented/modified by operative findings and gross and microscopic evaluation of the resected specimens.<sup>2</sup> pT entails a resection of the primary tumor or biopsy adequate to evaluate the highest pT category, pN entails removal of nodes adequate to validate lymph node metastasis, and pM implies microscopic examination of distant lesions. Clinical classification (cTNM) is usually carried out by the referring physician before treatment during initial evaluation of the patient or when pathologic classification is not possible.

Pathologic staging is usually performed after surgical resection of the primary tumor. Pathologic staging depends on pathologic documentation of the anatomic extent of disease, whether or not the primary tumor has been completely removed. If a biopsied tumor is not resected for any reason (e.g., when technically unfeasible) and if the highest T and N categories or the M1 category of the tumor can be confirmed

microscopically, the criteria for pathologic classification and staging have been satisfied without total removal of the primary cancer.

### **TNM Descriptors**

For identification of special cases of TNM or pTNM classifications, the “m” suffix and “y”, “r”, and “a” prefixes are used. Although they do not affect the stage grouping, they indicate cases needing separate analysis. Reporting of pT, pN, and (when applicable) pM categories is based on information available to the pathologist at the time the report is issued. As per the AJCC (Chapter 1, 8<sup>th</sup> Ed.) it is the managing physician’s responsibility to establish the final pathologic stage based upon all pertinent information, including but potentially not limited to this pathology report.

The “m” suffix indicates the presence of multiple primary tumors in a single site and is recorded in parentheses: pT(m)NM.

The “y” prefix indicates those cases in which classification is performed during or following initial multimodality therapy (i.e., neoadjuvant chemotherapy, radiation therapy, or both chemotherapy and radiation therapy). The cTNM or pTNM category is identified by a “y” prefix. The ycTNM or ypTNM categorizes the extent of tumor actually present at the time of that examination. The “y” categorization is not an estimate of tumor prior to multimodality therapy (i.e., before initiation of neoadjuvant therapy).

The “r” prefix indicates a recurrent tumor when staged after a documented disease-free interval, and is identified by the “r” prefix: rTNM.

The “a” prefix designates the stage determined at autopsy: aTNM.

### **References**

1. Lydiatt WM, Brandwein-Gensler MS, Kraus DH, et al. Mucosal melanoma of the head and neck. In: Amin MB, ed. *AJCC Cancer Staging Manual*. 8th ed. New York, NY: Springer; 2017.
2. Gress DM, Edge SB, Greene FL, et al. Principles of cancer staging. In: Amin MB, ed. *AJCC Cancer Staging Manual*. 8th ed. New York, NY: Springer; 2017.