



## Protocol for the Examination of Specimens From Patients With Cancers of the Nasal Cavity and Paranasal Sinuses

**Version:** 4.1.0.0

**Protocol Posting Date:** June 2021

**CAP Laboratory Accreditation Program Protocol Required Use Date:** March 2022

The changes included in this current protocol version affect accreditation requirements. The new deadline for implementing this protocol version is reflected in the above accreditation date.

**For accreditation purposes, this protocol should be used for the following procedures AND tumor types:**

Procedure	Description
Resection	Includes specimens designated nasal cavity and paranasal sinuses
Tumor Type	Description
Carcinoma	Includes squamous cell carcinoma, neuroendocrine carcinoma, and minor salivary gland carcinoma
Mucosal Melanoma	

**This protocol is NOT required for accreditation purposes for the following:**

Procedure
Biopsy
Primary resection specimen with no residual cancer (eg, following neoadjuvant therapy)
Cytologic specimens

**The following tumor types should NOT be reported using this protocol:**

Tumor Type
Olfactory Neuroblastoma
Sarcoma (consider the Soft Tissue protocol)
Lymphoma (consider the Hodgkin or non-Hodgkin Lymphoma protocols)

### Authors

Raja R. Seethala, MD\*; Ilan Weinreb, MD; Martin J. Bullock, MD; Diane L. Carlson, MD; Robert L. Ferris, MD, PhD; Louis B. Harrison, MD; Jonathan B. McHugh, MD; Jason Pettus, MD; Mary S. Richardson, MD, DDS; Jatin Shah, MD; Lester D.R.. Thompson, MD; Bruce M. Wenig, MD.

With guidance from the CAP Cancer and CAP Pathology Electronic Reporting Committees.

\* Denotes primary author.

### **Accreditation Requirements**

This protocol can be utilized for a variety of procedures and tumor types for clinical care purposes. For accreditation purposes, only the definitive primary cancer resection specimen is required to have the core and conditional data elements reported in a synoptic format.

- Core data elements are required in reports to adequately describe appropriate malignancies. For accreditation purposes, essential data elements must be reported in all instances, even if the response is “not applicable” or “cannot be determined.”
- Conditional data elements are only required to be reported if applicable as delineated in the protocol. For instance, the total number of lymph nodes examined must be reported, but only if nodes are present in the specimen.
- Optional data elements are identified with “+” and although not required for CAP accreditation purposes, may be considered for reporting as determined by local practice standards.

The use of this protocol is not required for recurrent tumors or for metastatic tumors that are resected at a different time than the primary tumor. Use of this protocol is also not required for pathology reviews performed at a second institution (ie, secondary consultation, second opinion, or review of outside case at second institution).

### **Synoptic Reporting**

All core and conditionally required data elements outlined on the surgical case summary from this cancer protocol must be displayed in synoptic report format. Synoptic format is defined as:

- Data element: followed by its answer (response), outline format without the paired Data element: Response format is NOT considered synoptic.
- The data element should be represented in the report as it is listed in the case summary. The response for any data element may be modified from those listed in the case summary, including “Cannot be determined” if appropriate.
- Each diagnostic parameter pair (Data element: Response) is listed on a separate line or in a tabular format to achieve visual separation. The following exceptions are allowed to be listed on one line:
  - Anatomic site or specimen, laterality, and procedure
  - Pathologic Stage Classification (pTNM) elements
  - Negative margins, as long as all negative margins are specifically enumerated where applicable
- The synoptic portion of the report can appear in the diagnosis section of the pathology report, at the end of the report or in a separate section, but all Data element: Responses must be listed together in one location

Organizations and pathologists may choose to list the required elements in any order, use additional methods in order to enhance or achieve visual separation, or add optional items within the synoptic report. The report may have required elements in a summary format elsewhere in the report IN ADDITION TO but not as replacement for the synoptic report ie, all required elements must be in the synoptic portion of the report in the format defined above.

### **Summary of Changes**

#### **v 4.1.0.0**

- General Reformatting
- Revised Margins Section
- Revised Lymph Nodes Section
- Added Distant Metastasis Section
- Removed pTX and pNX Staging Classification

## Reporting Template

---

**Protocol Posting Date: June 2021**

**Select a single response unless otherwise indicated.**

**CASE SUMMARY: (NASAL CAVITY AND PARANASAL SINUSES)**

**Standard(s):** AJCC-UICC 8

### SPECIMEN

**Procedure (select all that apply)**

- Excision
- Partial maxillectomy
- Radical maxillectomy
- Neck (lymph node) dissection (specify): \_\_\_\_\_
- Other (specify): \_\_\_\_\_
- Not specified

### TUMOR

**Tumor Focality**

- Unifocal
- Multifocal: \_\_\_\_\_
- Cannot be determined: \_\_\_\_\_

**Multiple Primary Sites (e.g., nasal cavity and paranasal sinus, maxillary)**

- Not applicable (no additional primary site(s) present)
- Present: \_\_\_\_\_

*Please complete a separate checklist for each primary site*

**Tumor Site (Note [A](#)) (select all that apply)**

- Nasal septum: \_\_\_\_\_
- Nasal floor: \_\_\_\_\_
- Nasal lateral wall: \_\_\_\_\_
- Nasal vestibule: \_\_\_\_\_
- Nasal cavity, not otherwise specified: \_\_\_\_\_
- Paranasal sinus(es), maxillary: \_\_\_\_\_
- Paranasal sinus(es), ethmoid: \_\_\_\_\_
- Paranasal sinus(es), frontal: \_\_\_\_\_
- Paranasal sinus(es), sphenoid: \_\_\_\_\_
- Other (specify): \_\_\_\_\_
- Not specified

**Tumor Laterality (select all that apply)**

- Right
- Left
- Midline
- Not specified

**Tumor Size**

\_\_\_ Greatest dimension in Centimeters (cm): \_\_\_\_\_ cm  
**+Additional Dimension in Centimeters (cm): \_\_\_ x \_\_\_ cm**  
\_\_\_ Cannot be determined (explain): \_\_\_\_\_

**Histologic Type (Note B)**

*Squamous Cell Carcinoma and Variants (select all that apply)*

- \_\_\_ Squamous Cell Carcinoma and Variants
- \_\_\_ Squamous cell carcinoma, keratinizing
- \_\_\_ Squamous cell carcinoma, nonkeratinizing
- \_\_\_ Adenosquamous carcinoma
- \_\_\_ Basaloid squamous cell carcinoma
- \_\_\_ Papillary squamous cell carcinoma
- \_\_\_ Spindle cell squamous cell carcinoma
- \_\_\_ Verrucous squamous cell carcinoma
- \_\_\_ Lymphoepithelial carcinoma (non-nasopharyngeal)
- \_\_\_ Sinonasal undifferentiated carcinoma (SNUC)
- \_\_\_ NUT carcinoma

*Adenocarcinoma, Non-Salivary Gland Type*

- \_\_\_ Intestinal adenocarcinoma, papillary pattern
- \_\_\_ Intestinal adenocarcinoma, colonic pattern
- \_\_\_ Intestinal adenocarcinoma, solid pattern
- \_\_\_ Intestinal adenocarcinoma, mucinous pattern
- \_\_\_ Intestinal adenocarcinoma, mixed pattern
- \_\_\_ Non-intestinal adenocarcinoma, low grade
- \_\_\_ Non-intestinal adenocarcinoma, intermediate grade
- \_\_\_ Non-intestinal adenocarcinoma, high grade

*Carcinomas of Minor Salivary Glands*

- \_\_\_ Mucoepidermoid carcinoma, low grade
- \_\_\_ Mucoepidermoid carcinoma, intermediate grade
- \_\_\_ Mucoepidermoid carcinoma, high grade

*# If multiple patterns present, select predominant pattern unless solid pattern is greater than 30%, in which case should select solid pattern.*

\_\_\_ Adenoid cystic carcinoma, tubular pattern#

**+Percentage of Solid Component**

- \_\_\_ Specify percentage: \_\_\_\_\_ %
- \_\_\_ Other (specify): \_\_\_\_\_
- \_\_\_ Cannot be determined

\_\_\_ Adenoid cystic carcinoma, cribriform pattern#

**+Percentage of Solid Component**

- \_\_\_ Specify percentage: \_\_\_\_\_ %
- \_\_\_ Other (specify): \_\_\_\_\_
- \_\_\_ Cannot be determined

\_\_\_ Adenoid cystic carcinoma, solid pattern#

**+Percentage of Solid Component**

- \_\_\_ Specify percentage: \_\_\_\_\_ %
- \_\_\_ Other (specify): \_\_\_\_\_
- \_\_\_ Cannot be determined

\_\_\_ Acinic cell carcinoma

- Polymorphous adenocarcinoma, classic, low grade
- Polymorphous adenocarcinoma, classic, intermediate grade
- Polymorphous adenocarcinoma, classic, high grade
- Polymorphous adenocarcinoma, cribriform (cribriform adenocarcinoma of salivary origin), low grade
- Polymorphous adenocarcinoma, cribriform (cribriform adenocarcinoma of salivary origin), intermediate grade
- Polymorphous adenocarcinoma, cribriform (cribriform adenocarcinoma of salivary origin), high grade
- (Mammary analogue) Secretory carcinoma
- Salivary duct carcinoma
- Epithelial-myoeithelial carcinoma
- (Hyalinizing) clear cell carcinoma
- Adenocarcinoma, not otherwise specified, low grade
- Adenocarcinoma, not otherwise specified, intermediate grade
- Adenocarcinoma, not otherwise specified, high grade

*Neuroendocrine carcinoma*

- Well-differentiated neuroendocrine carcinoma (typical carcinoid tumor)
- Moderately differentiated neuroendocrine carcinoma (atypical carcinoid tumor)
- Poorly differentiated neuroendocrine carcinoma, small cell type
- Poorly differentiated neuroendocrine carcinoma, large cell type
- Combined (or composite) small cell carcinoma, neuroendocrine type

**Type of Combined Histology (select all that apply)**

- Squamous cell carcinoma: \_\_\_\_\_
- Adenocarcinoma: \_\_\_\_\_
- Small cell neuroendocrine carcinoma: \_\_\_\_\_
- Large cell neuroendocrine carcinoma: \_\_\_\_\_
- Other (specify): \_\_\_\_\_

*Mucosal melanoma*

- Mucosal melanoma

*Other*

- Other histologic type not listed (specify): \_\_\_\_\_
- Carcinoma, type cannot be determined: \_\_\_\_\_

**Preexisting Pleomorphic Adenoma Component**

*Required only for carcinomas of minor salivary glands, if applicable*

- Not applicable
- Carcinoma ex pleomorphic adenoma, minimally invasive
- Carcinoma ex pleomorphic adenoma, invasive
- Carcinoma ex pleomorphic adenoma, intracapsular (noninvasive)
- Carcinoma ex pleomorphic adenoma, extent cannot be determined

**+Histologic Type Comment:** \_\_\_\_\_

**Histologic Grade # (Note C)**

*# The Histologic Grade section is required for squamous cell carcinoma only.*

- Not applicable
- G1, well differentiated
- G2, moderately differentiated
- G3, poorly differentiated
- Other (specify): \_\_\_\_\_
- GX, cannot be assessed: \_\_\_\_\_

**+Tumor Extent (specify):** \_\_\_\_\_

**Lymphovascular Invasion**

- Not Identified
- Present
- Cannot be determined: \_\_\_\_\_

**Perineural Invasion (Note [D](#))**

- Not identified
- Present
- Cannot be determined: \_\_\_\_\_

**+Tumor Comment:** \_\_\_\_\_

**MARGINS (Note [E](#))**

**Margin Status for Invasive Tumor**

- All margins negative for invasive tumor

**Distance from Invasive Tumor to Closest Margin**

*Specify in Millimeters (mm)*

- Exact distance: \_\_\_\_\_ mm
- Greater than: \_\_\_\_\_ mm
- Less than 1 mm
- Other (specify): \_\_\_\_\_
- Cannot be determined: \_\_\_\_\_

**Closest Margin(s) to Invasive Tumor (per orientation, if possible)**

- Specify location(s) of closest margin(s): \_\_\_\_\_
- Cannot be determined

**+Other Close Margin(s) to Invasive Tumor**

- Specify location(s) and distance(s) of other close margin(s): \_\_\_\_\_
- Cannot be determined

- Invasive tumor present at margin

**Margin(s) Involved by Invasive Tumor (per orientation, if possible)**

- Specify involved margin(s): \_\_\_\_\_
- Cannot be determined
- Other (specify): \_\_\_\_\_
- Cannot be determined

**Margin Status for Noninvasive Tumor**

*Applicable only to squamous cell carcinoma and histologic variants.*

- Not applicable
- All margins negative for high grade dysplasia / in situ disease

**Distance from Noninvasive Tumor to Closest Margin**

*Specify in Millimeters (mm)*

- Exact distance: \_\_\_\_\_ mm
- Greater than: \_\_\_\_\_ mm
- Less than 1 mm
- Other (specify): \_\_\_\_\_
- Cannot be determined: \_\_\_\_\_

**Closest Margin(s) to Noninvasive Tumor (per orientation, if possible)**

- Specify location(s) of closest margin(s): \_\_\_\_\_
- Cannot be determined

High grade dysplasia / in situ disease present at margin

**Margin(s) Involved by Noninvasive Tumor (per orientation, if possible)**

Specify involved margin(s): \_\_\_\_\_

Cannot be determined

Other (specify): \_\_\_\_\_

Cannot be determined

**+Margin Comment:** \_\_\_\_\_

**REGIONAL LYMPH NODES (Note [E](#))**

**Regional Lymph Node Status**

Not applicable (no regional lymph nodes submitted or found)

Regional lymph nodes present

All regional lymph nodes negative for tumor

Tumor present in regional lymph node(s)

**Number of Lymph Nodes with Tumor**

Exact number (specify): \_\_\_\_\_

At least (specify): \_\_\_\_\_

Other (specify): \_\_\_\_\_

Cannot be determined

**Laterality of Lymph Node(s) with Tumor (not applicable for mucosal melanoma)**

Ipsilateral (including midline): \_\_\_\_\_

Contralateral: \_\_\_\_\_

Bilateral: \_\_\_\_\_

Cannot be determined: \_\_\_\_\_

Not applicable

**Size of Largest Nodal Metastatic Deposit (not applicable for mucosal melanoma)**

*Specify in Centimeters (cm)*

Exact size: \_\_\_\_\_ cm

At least: \_\_\_\_\_ cm

Greater than: \_\_\_\_\_ cm

Less than: \_\_\_\_\_ cm

Other (specify): \_\_\_\_\_

Cannot be determined: \_\_\_\_\_

Not applicable

**Extranodal Extension (ENE) (not applicable for mucosal melanoma)**

Not identified

Present

**+Distance of ENE from Lymph Node Capsule**

*Specify in Millimeters (mm)*

Exact distance: \_\_\_\_\_ mm

Greater than 2 mm (macroscopic ENE)

Less than or equal to 2 mm (microscopic ENE)

Less than 1 mm

Other (specify): \_\_\_\_\_

Cannot be determined

Cannot be determined: \_\_\_\_\_

Not applicable

Approved

\_\_\_ Other (specify): \_\_\_\_\_  
 \_\_\_ Cannot be determined (explain): \_\_\_\_\_

**Number of Lymph Nodes Examined**

\_\_\_ Exact number (specify): \_\_\_\_\_  
 \_\_\_ At least (specify): \_\_\_\_\_  
 \_\_\_ Other (specify): \_\_\_\_\_  
 \_\_\_ Cannot be determined

**+Regional Lymph Node Comment:** \_\_\_\_\_

**DISTANT METASTASIS****Distant Site(s) Involved, if applicable (select all that apply)**

\_\_\_ Not applicable  
 \_\_\_ Lung: \_\_\_\_\_  
 \_\_\_ Bone: \_\_\_\_\_  
 \_\_\_ Brain: \_\_\_\_\_  
 \_\_\_ Liver: \_\_\_\_\_  
 \_\_\_ Other (specify): \_\_\_\_\_  
 \_\_\_ Cannot be determined: \_\_\_\_\_

**PATHOLOGIC STAGE CLASSIFICATION (pTNM, AJCC 8th Edition) (Note [G](#))**

*Reporting of pT, pN, and (when applicable) pM categories is based on information available to the pathologist at the time the report is issued. As per the AJCC (Chapter 1, 8th Ed.) it is the managing physician's responsibility to establish the final pathologic stage based upon all pertinent information, including but potentially not limited to this pathology report.*

**TNM Descriptors (select all that apply)**

\_\_\_ Not applicable  
 \_\_\_ m (multiple primary tumors)  
 \_\_\_ r (recurrent)  
 \_\_\_ y (post-treatment)

**Pathologic Stage Classification**

\_\_\_ For All Carcinomas

**pT Category**

\_\_\_ pT not assigned (cannot be determined based on available pathological information)

*For the Maxillary Sinus*

\_\_\_ pTis: Carcinoma \*in situ\*

\_\_\_ pT1: Tumor limited to the maxillary sinus mucosa with no erosion or destruction of bone

\_\_\_ pT2: Tumor causing bone erosion or destruction including extension into the hard palate and / or middle nasal meatus, except extension to posterior wall of maxillary sinus and pterygoid plates

\_\_\_ pT3: Tumor invades any of the following: bone of the posterior wall of maxillary sinus, subcutaneous tissues, floor or medial wall of orbit, pterygoid fossa, ethmoid sinuses

*pT4: Moderately advanced or very advanced local disease*

\_\_\_ pT4a: Moderately advanced local disease. Tumor invades anterior orbital contents, skin of cheek, pterygoid plates, infratemporal fossa, cribriform plate, sphenoid or frontal sinuses

\_\_\_ pT4b: Very advanced local disease. Tumor invades any of the following: orbital apex, dura, brain, middle cranial fossa, cranial nerves other than maxillary division of trigeminal nerve (V2), nasopharynx, or clivus

\_\_\_ pT4 (subcategory cannot be determined)



*For the Nasal Cavity and Ethmoid Sinus*

\_\_\_ pTis: Carcinoma \*in situ\*

\_\_\_ pT1: Tumor restricted to any one subsite, with or without bony invasion

\_\_\_ pT2: Tumor invading two subsites in a single region or extending to involve an adjacent region within the nasoethmoidal complex, with or without bony invasion

\_\_\_ pT3: Tumor extends to invade the medial wall or floor of the orbit, maxillary sinus, palate, or cribriform plate

*pT4: Moderately advanced or very advanced local disease*

\_\_\_ pT4a: Moderately advanced local disease. Tumor invades any of the following: anterior orbital contents, skin of nose or cheek, minimal extension to anterior cranial fossa, pterygoid plates, sphenoid or frontal sinuses

\_\_\_ pT4b: Very advanced local disease. Tumor invades any of the following: orbital apex, dura, brain, middle cranial fossa, cranial nerves other than maxillary division of trigeminal nerve (V2), nasopharynx, or clivus

\_\_\_ pT4 (subcategory cannot be determined)

**pN Category# (Note D)**

\_\_\_ pN not assigned (no nodes submitted or found)

\_\_\_ pN not assigned (cannot be determined based on available pathological information)

*# Midline nodes are considered ipsilateral nodes.*

*Pathological ENE should be recorded as ENE(-) or ENE(+).*

*Measurement of the metastatic focus in the lymph nodes is based on the largest metastatic deposit size, which may include matted or fused lymph nodes.*

\_\_\_ pN0: No regional lymph node metastasis

\_\_\_ pN1: Metastasis in a single ipsilateral lymph node, 3 cm or smaller in greatest dimension and ENE(-)

*pN2: Metastasis in a single ipsilateral node larger than 3 cm but not larger than 6 cm in greatest dimension and ENE(-); or metastases in multiple ipsilateral lymph nodes, none larger than 6 cm in greatest dimension and ENE(-); or in bilateral or contralateral lymph node(s), none larger than 6 cm in greatest dimension and ENE(-)*

\_\_\_ pN2a: Metastasis in single ipsilateral node 3 cm or less in greatest dimension and ENE(+); or a single ipsilateral node larger than 3 cm but not larger than 6 cm in greatest dimension and ENE(-)

\_\_\_ pN2b: Metastases in multiple ipsilateral nodes, none larger than 6 cm in greatest dimension and ENE(-)

\_\_\_ pN2c: Metastases in bilateral or contralateral lymph node(s), none larger than 6 cm in greatest dimension and ENE(-)

\_\_\_ pN2 (subcategory cannot be determined)

*pN3: Metastases in a lymph node larger than 6 cm in greatest dimension and ENE(-); or in a single ipsilateral node larger than 3 cm in greatest dimension and ENE(+); or multiple ipsilateral, contralateral, or bilateral nodes, any with ENE(+); or a single contralateral node of any size and ENE(+)*

\_\_\_ pN3a: Metastasis in a lymph node larger than 6 cm in greatest dimension and ENE(-)

\_\_\_ pN3b: Metastasis in a single ipsilateral node larger than 3 cm in greatest dimension and ENE(+); or multiple ipsilateral, contralateral or bilateral nodes any with ENE(+); or a single contralateral node of any size and ENE(+)

\_\_\_ pN3 (subcategory cannot be determined)

**pM Category (required only if confirmed pathologically)**

\_\_\_ Not applicable - pM cannot be determined from the submitted specimen(s)

\_\_\_ pM1: Distant metastasis

\_\_\_ For Mucosal Melanoma

**pT Category**

\_\_\_ pT3: Tumors limited to the mucosa and immediately underlying soft tissue, regardless of thickness or greatest dimension; for example, polypoid nasal disease, pigmented or nonpigmented lesions of the oral cavity, pharynx, or larynx

*pT4: Moderately advanced or very advanced disease*

pT4a: Moderately advanced disease. Tumor involving deep soft tissue, cartilage, bone, or overlying skin

pT4b: Very advanced disease. Tumor involving brain, dura, skull base, lower cranial nerves (IX, X, XI, XII), masticator space, carotid artery, prevertebral space, or mediastinal structures

pT4 (subcategory cannot be determined)

**pN Category**

pN not assigned (no nodes submitted or found)

pN not assigned (cannot be determined based on available pathological information)

pN0: No regional lymph node metastasis

pN1: Regional lymph node metastases present

**pM Category (required only if confirmed pathologically)**

Not applicable - pM cannot be determined from the submitted specimen(s)

pM1: Distant metastasis present

**ADDITIONAL FINDINGS (Note [H](#))**

**+Additional Findings (select all that apply)**

None identified

Carcinoma in situ

Epithelial dysplasia (specify type): \_\_\_\_\_

Sinonasal papilloma (specify type): \_\_\_\_\_

Inflammation (specify type): \_\_\_\_\_

Squamous metaplasia

Epithelial hyperplasia

Colonization, fungal

Colonization, bacterial

Other (specify): \_\_\_\_\_

**SPECIAL STUDIES**

*For reporting molecular testing and other cancer biomarker testing results, the CAP Head and Neck Biomarker Template should be used. Pending biomarker studies should be listed in the Comments section of this report.*

**COMMENTS**

**Comment(s):** \_\_\_\_\_

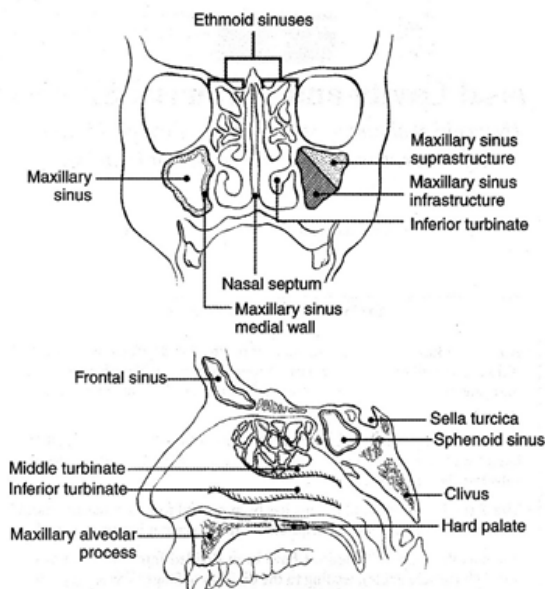
## Explanatory Notes

### A. Anatomic Sites and Subsites for the Nasal Cavity and Paranasal Sinuses (Figure 1)

The nasal cavity is divided in the midline to right and left halves by the septum; each half opens on the face via the nares or nostrils and communicates behind with the nasopharynx through the posterior nasal apertures or the choanae. The nasal cavity is divided into 4 subsites including the septum, floor, lateral wall, and vestibule. The paranasal sinuses represent a grouping of 4 paired sinuses including the maxillary sinuses, ethmoid sinuses, frontal sinuses, and sphenoid sinuses. The nasoethmoidal complex is divided into 2 sites including the nasal cavity and the ethmoid sinuses.

Cancers of the maxillary sinuses are the most common sinonasal malignancies followed by cancers of the ethmoid sinuses, which are much less common.<sup>1</sup> Cancers of the frontal and sphenoid sinuses are rare. When considering the nasal cavity and paranasal sinuses, 60% of malignant neoplasms originate from the maxillary sinus, 20% to 30% from the nasal cavity, 10% to 15% from the ethmoid sinus, and 1% from the sphenoid and frontal sinuses.<sup>2</sup> When only considering the paranasal sinuses, 77% of malignant neoplasms originate from the maxillary sinus, 22% from the ethmoid sinus, and 1% from the sphenoid and frontal sinuses.<sup>2</sup>

The location as well as the extent of the mucosal lesion in the maxillary sinus has prognostic importance. Ohngren's line, connecting the medial canthus of the eye to the angle of the mandible, divides the maxillary sinus into an anterioinferior portion (infrastructure) and superioposterior portion (suprastructure) structures. Carcinomas of the infrastructure are associated with a good prognosis; carcinomas of the suprastructure are associated with a poor prognosis. The poorer prognosis with carcinomas of the suprastructure reflects early access of these tumors to critical structures, including the eye, skull base, pterygoids, and infratemporal fossa.<sup>1</sup>



**Figure 1.** Anatomic sites and subsites for the nasal cavity and paranasal sinuses. From *AJCC Cancer Staging Manual*. 6th ed. New York: Springer; 2002. © American Joint Committee on Cancer. Reproduced with permission.

#### References

1. Gress DM, Edge SB, Greene FL, et al. Principles of cancer staging. In: Amin MB, ed. *AJCC Cancer Staging Manual*. 8th ed. New York, NY: Springer; 2017.
2. Kraus DH, Lydiatt WM, Patel SG, et al. Nasal cavity paranasal sinuses. In: Amin MB, ed. *AJCC Cancer Staging Manual*. 8th ed. New York, NY: Springer; 2017.

#### **B. Histologic Type**

A modification of the WHO classification of carcinomas of the nasal cavity and paranasal sinuses is shown below. This list may not be complete. This protocol applies only to carcinomas and melanomas and does not apply to lymphomas, sarcomas or neuroectodermal tumors (eg, olfactory neuroblastoma, primitive neuroectodermal tumor [PNET], others).

#### **Nasal Cavity and Paranasal Sinuses**

- Squamous cell carcinoma, keratinizing
- Squamous cell carcinoma, non-keratinizing
- Adenosquamous carcinoma
- Basaloid squamous cell carcinoma
- Papillary squamous cell carcinoma
- Spindle cell squamous cell carcinoma
- Verrucous squamous cell carcinoma
- Lymphoepithelial carcinoma (non-nasopharyngeal)
- Sinonasal undifferentiated carcinoma (SNUC)
- NUT carcinoma

#### **Adenocarcinoma, Non-Salivary Gland Type**

- Intestinal-type
- Non-intestinal type

#### **Carcinomas of Minor Salivary Glands**

- Mucoepidermoid carcinoma, low grade
- Adenoid cystic carcinoma
- Acinic cell carcinoma
- Polymorphous adenocarcinoma
- (Mammary analogue) secretory carcinoma
- Salivary duct carcinoma
- Carcinoma ex pleomorphic adenoma
- Epithelial-myoeepithelial carcinoma
- (Hyalinizing) clear cell carcinoma
- Adenocarcinoma, not otherwise specified

#### **Neuroendocrine Carcinoma**

Large cell neuroendocrine carcinoma

Small cell neuroendocrine carcinoma

## Mucosal Melanoma

### C. Histologic Grade

For histologic types of carcinomas that are amenable to grading, 3 histologic grades are suggested, as shown below. For conventional squamous cell carcinoma, histologic grading as a whole does not perform well as a prognosticator.<sup>1</sup> Nonetheless, it should be recorded when applicable, as it is a basic tumor characteristic. Selecting either the most prevalent grade or the highest grade for this synoptic protocol is acceptable. Variants of squamous cell carcinoma (ie, verrucous, basaloid, etc) have an intrinsic biologic potential and currently do not appear to require grading.

Grade 1	Well-differentiated
Grade 2	Moderately differentiated
Grade 3	Poorly differentiated
Grade X	Cannot be assessed

The histologic (microscopic) grading of salivary gland carcinomas has been shown to be an independent predictor of behavior and plays a role in optimizing therapy. Further, there is often a positive correlation between histologic grade and clinical stage.<sup>2,3,4,5</sup> However, most salivary gland carcinoma types have an intrinsic biologic behavior and attempted application of a universal grading scheme is merely a crude surrogate. Thus, a generic grading scheme is no longer recommended for salivary gland carcinomas.<sup>6</sup> Carcinoma types for which grading systems exist and are relevant are incorporated into histologic type. The 3 major categories that are amenable to grading include adenoid cystic carcinoma, mucoepidermoid carcinoma, and adenocarcinoma, not otherwise specified.<sup>3,4,7</sup>

In some carcinomas, histologic grading may be based on growth pattern, such as in adenoid cystic carcinoma, for which a histologic high-grade variant has been recognized based on the percentage of solid growth.<sup>7</sup> Those adenoid cystic carcinomas showing 30% or greater of solid growth pattern are considered to be histologically high-grade carcinomas. The histologic grading of mucoepidermoid carcinoma includes a combination of growth pattern characteristics (eg, cystic, solid, neurotropism) and cytomorphic findings (eg, anaplasia, mitoses, necrosis).<sup>8,9,10</sup> Adenocarcinomas, not otherwise specified, do not have a formalized grading scheme and are graded intuitively based on cytomorphic features.<sup>4</sup> Polymorphous adenocarcinomas are to be graded as per current WHO recommendations, though these are also graded intuitively as there are no listed criteria.

Carcinoma ex pleomorphic adenoma is subclassified by histologic type and or grade and extent of invasion, the latter including minimally invasive, widely invasive and intracapsular (noninvasive) cancers. Previously the cut-off for minimal invasion was designated as 1.5 mm; however, more recent studies have shown a favorable prognosis even with cut-offs of 4-6 mm.<sup>11</sup> Thus there is no agreement on an optimal cut-off. However, from a practical standpoint, the terms intracapsular and minimally invasive should only be applied to uninodular tumors (as opposed to carcinomas arising in multinodular recurrent pleomorphic adenomas) with a well-delineated interface for which the entire lesional border has been microscopically evaluated. Prognosis has been linked to degree of invasion with noninvasive and minimally invasive cancers apparently having a better prognosis than invasive cancers.<sup>4,11,12</sup>

For nonsalivary sinonasal adenocarcinoma, intestinal type adenocarcinomas grading is based on growth pattern. Generally, papillary patterns correspond to low-grade tumors, colonic to intermediate grade, and solid to high grade. Mucinous and mixed types have variable behavior.<sup>13</sup> Non-intestinal type adenocarcinomas are graded intuitively into low, intermediate and high-grade tumors.

## References

1. Eveson JW, Auclair PL, Gnepp DR, El-Naggar AK. Tumours of the salivary gland. In: Barnes L, Eveson JW, Reichart P, Sidransky D, eds. *World Health Organization Classification of Tumours: Pathology and Genetics of Head and Neck Tumours*. Lyon: IARC; 2005:164.
2. Spiro RH, Thaler HT, Hicks WF, Kher UA, Huvos AH, Strong EW. The importance of clinical staging of minor salivary gland carcinoma. *Am J Surg*. 1991;162(4):330-336.
3. Spiro RH, Huvos AG, Strong EW. Adenocarcinoma of salivary origin: clinicopathologic study of 204 patients. *Am J Surg*. 1982;144(4):423-431.
4. Seethala RR. Histologic grading and prognostic biomarkers in salivary gland carcinomas. *Adv Anat Pathol*. 2011;18(1):29-45.
5. Kane WJ, McCaffrey TV, Olsen KD, Lewis JE. Primary parotid malignancies. A clinical and pathologic review. *Arch Otolaryngol Head Neck Surg*. 1991;117(3):307-315.
6. Lydiatt WM, Mukherji SK, O'Sullivan B, Patel SG, Shah JP. Major salivary glands. In: Amin MB, ed. *AJCC Cancer Staging Manual*. 8th ed. New York, NY: Springer; 2017.
7. Szanto PA, Luna MA, Tortoledo ME, White RA. Histologic grading of adenoid cystic carcinoma of the salivary glands. *Cancer*. 1984;54(6):1062-1069.
8. Seethala RR, Dacic S, Cieply K, Kelly LM, Nikiforova MN. A reappraisal of the MECT1/MAML2 translocation in salivary mucoepidermoid carcinomas. *Am J Surg Pathol*. 2010;34(8):1106-1121.
9. Brandwein MS, Ivanov K, Wallace DI, et al. Mucoepidermoid carcinoma: a clinicopathologic study of 80 patients with special reference to histological grading. *Am J Surg Pathol*. 2001;25(7):835-845.
10. Auclair PL, Goode RK, Ellis GL. Mucoepidermoid carcinoma of intraoral salivary glands: evaluation and application of grading criteria in 143 cases. *Cancer*. 1992;69(8):2021-2030.
11. Williams MD, Ihrler S, Seethala RR. Carcinoma ex pleomorphic adenoma. In: El-Naggar AK, Chan JKC, Grandis JR, Takata T, Slootweg PJ, eds. *WHO Classification of Head and Neck Tumours*. 4th ed. Geneva, Switzerland: *WHO Press*; 2017:176-177.
12. Brandwein M, Huvos AG, Dardick I, Thomas MJ, Theise ND. Noninvasive and minimally invasive carcinoma ex mixed tumor: a clinicopathologic and ploidy study of 12 patients with major salivary tumors of low (or no?) malignant potential. *Oral Surg Oral Med Oral Pathol Oral Radiol Endod*. 1996;81(6):655-664.
13. Barnes L. Intestinal-type adenocarcinoma of the nasal cavity and paranasal sinuses. *Am J Surg Pathol*. 1986;10(3):192-202.

## D. Perineural Invasion

Traditionally, the presence of perineural invasion (neurotropism) is an important predictor of poor prognosis in head and neck cancer of virtually all sites.<sup>1</sup> The presence of perineural invasion (neurotropism) in the primary cancer is associated with poor local disease control and regional control, as well as being associated with metastasis to regional lymph nodes.<sup>1</sup> Further, perineural invasion is associated with decrease in disease-specific survival and overall survival.<sup>1</sup> There is conflicting data relative to an association between the presence of perineural invasion and the development of distant metastasis, with some studies showing an increased association with distant metastasis, while other studies showing no correlation with distant metastasis.<sup>1</sup> The relationship between perineural invasion and prognosis is independent of nerve diameter.<sup>2</sup> Additionally, emerging evidence suggests that extratumoral perineural invasion may be more prognostically relevant.<sup>3</sup> Although perineural invasion of small unnamed nerves may not produce clinical symptoms, the reporting of perineural invasion includes nerves of all sizes including small peripheral nerves (ie, less than 1 mm in diameter). Aside from the impact on prognosis, the presence of perineural invasion also guides therapy. Concurrent adjuvant chemoradiation therapy has been shown to improve outcomes in patients with perineural invasion (as well as in patients with extranodal extension and bone invasion).<sup>4,5</sup> Given the significance relative to prognosis and treatment, perineural invasion is a required data element in the reporting of head and neck cancers.

## References

1. Smith BD, Haffty BG. Prognostic factoris in patients with head and neck cancer. In: Harrison LB, Sessions RB, Hong WK, eds. *Head and Neck Cancer: A Multidisciplinary Approach*. Philadelphia, PA: Lippincott Williams and Wilkins; 2009:51-75.
2. Fagan JJ, Collins B, Barnes L, D'Amico F, Myers EN, Johnson JT. Perineural invasion in squamous cell carcinoma of the head and neck. *Arch Otolaryngol Head Neck Surg*. 1998;124(6):637-640.
3. Miller ME, Palla B, Chen Q, et al. A novel classification system for perineural invasion in noncutaneous head and neck squamous cell carcinoma: histologic subcategories and patient outcomes. *Am J Otolaryngol*. 2012;33(2):212-215.
4. Cooper JS, Pajak TF, Forastiere AA, et al. Postoperative concurrent radiotherapy and chemotherapy for high-risk squamous-cell carcinoma of the head and neck. *N Engl J Med*. 2004;350(19):1937-1944.
5. Bernier J, Dometge C, Ozsahin M, et al. Postoperative irradiation with or without concomitant chemotherapy for locally advanced head and neck cancer. *N Engl J Med*. 2004;350(19):1945-1952.

## E. Surgical Margins

The definition of a positive margin is somewhat controversial given the varied results from prior studies.<sup>1,2</sup> This is made even more challenging and nebulous for sinonasal tumors, which are often received piecemeal with margins submitted separately. But for squamous cell carcinoma, data is essentially extrapolated from other sites. Here, overall, several studies support the definition of a positive margin to be invasive carcinoma or carcinoma in situ/high-grade dysplasia present at margins (microscopic cut-through of tumor).<sup>2</sup> Furthermore, reporting of surgical margins should also include information regarding the distance of invasive carcinoma, carcinoma in situ, or high-grade dysplasia (moderate to severe) from the surgical margin. Tumors with “close” margins also carry an increased risk for local recurrence.<sup>2,3</sup> The definition of a “close” margin is not standardized as the effective cut-off varies between studies and between anatomic subsites. Commonly used cut points to define close margins are 5 mm in general and 2 mm with respect to glottic larynx.<sup>2</sup> However, values ranging from 3 mm to 7 mm have been used with success,<sup>2,4</sup> and for glottic tumors as low as 1 mm.<sup>5</sup> Thus, distance of tumor from the nearest margin should be recorded.

Reporting of surgical margins for carcinomas of the minor salivary glands should follow those used for squamous cell carcinoma of oral cavity. While there is no standard recommendation for the other histologic types of carcinoma encountered, adherence to the recommendations for squamous cell carcinoma is acceptable.

## Orientation of Specimen

Complex intact specimens should be examined and oriented with the assistance of attending surgeons. Direct communication between the surgeon and pathologist is a critical component in specimen orientation and proper sectioning. For multipart piecemeal endoscopic resections, specimens should be clearly and precisely labeled. Parts that are margins should be designated explicitly as such. Whenever possible, the tissue examination request form should include a drawing of the resected specimen showing the extent of the tumor and its relation to the anatomic structures of the region. The lines and extent of the resection can be depicted on preprinted adhesive labels and attached to the surgical pathology request forms.

## References

1. Brandwein-Gensler M, Teixeira MS, Lewis CM, et al. Oral squamous cell carcinoma: histologic risk assessment, but not margin status, is strongly predictive of local disease-free and overall survival. *Am J Surg Pathol*. 2005;29(2):167-178.

2. Hinni ML, Ferlito A, Brandwein-Gensler MS, et al. Surgical margins in head and neck cancer: a contemporary review. *Head Neck*. 2012.
3. Alicandri-Ciuffelli M, Bonali M, Piccinini A, et al. Surgical margins in head and neck squamous cell carcinoma: what is 'close'? *Eur Arch Otorhinolaryngol*. 2012.
4. Liao CT, Chang JT, Wang HM, et al. Analysis of risk factors of predictive local tumor control in oral cavity cancer. *Ann Surg Oncol*. 2008;15(3):915-922.
5. Ansarin M, Santoro L, Cattaneo A, et al. Laser surgery for early glottic cancer: impact of margin status on local control and organ preservation. *Arch Otolaryngol Head Neck Surg*. 2009;135(4):385-390.

## F. Lymph Nodes

### Measurement of Tumor Metastasis

The cross-sectional diameter of the largest lymph node metastasis (not the lymph node itself) is measured in the gross specimen at the time of macroscopic examination or, if necessary, on the histologic slide at the time of microscopic examination.<sup>1,2</sup>

### Special Procedures for Lymph Nodes

At the current time, no additional special techniques should be used other than routine histology for the assessment of nodal metastases. Immunohistochemistry and polymerase chain reaction (PCR) to detect isolated tumor cells are considered investigational techniques at this time.

### Lymph Node Number

For assessment of pN, a selective neck dissection will ordinarily include 10 or more lymph nodes, and a comprehensive neck dissection (radical or modified radical neck dissection) will ordinarily include 15 or more lymph nodes. Examination of fewer tumor-free nodes still mandates a pN0 designation.

### Regional Lymph Nodes (pN0): Isolated Tumor Cells

Isolated tumor cells (ITCs) are single cells or small clusters of cells not more than 0.2 mm in greatest dimension. While the generic recommendation is that for lymph nodes with ITCs found by either histologic examination, immunohistochemistry, or nonmorphologic techniques (eg, flow cytometry, DNA analysis, PCR amplification of a specific tumor marker), they should be classified as N0 or M0, respectively.<sup>3,4</sup> Evidence for the validity of this practice in head and neck squamous cell carcinoma and other histologic subtypes is lacking. In fact, rare studies relevant to head and neck sites indicate that isolated tumor cells may actually be a poor prognosticator in terms of local control.<sup>5</sup>

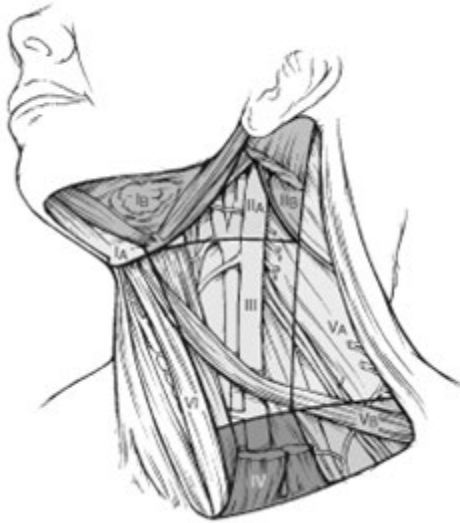For purposes of pathologic evaluation, lymph nodes are organized by levels, as shown in Figure 2.

## I. Classification of Neck Dissection

1. Radical neck dissection
2. Modified radical neck dissection, internal jugular vein and/or sternocleidomastoid muscle spared
3. Selective neck dissection (SND), as specified by the surgeon (Figure 3), defined by dissection of less than the 5 traditional levels of a radical and modified radical neck dissection. The following dissections are now under this category<sup>2,6,7</sup>:
  - a. Supraomohyoid neck dissection
  - b. Posterolateral neck dissection
  - c. Lateral neck dissection
  - d. Central compartment neck dissection



4. Superselective neck dissection (SSND), a relatively new term defined by dissection of the fibrofatty elements of 2 or less levels.<sup>8</sup>
5. Extended radical neck dissection, as specified by the surgeon



**Figure 2.** The six sublevels of the neck for describing the location of lymph nodes within levels I, II, and V. Level IA, submental group; level IB, submandibular group; level IIA, upper jugular nodes along the carotid sheath, including the subdigastric group; level IIB, upper jugular nodes in the submuscular recess; level VA, spinal accessory nodes; and level VB, the supraclavicular and transverse cervical nodes. From: Flint PW, et al, eds. *Cummings Otolaryngology: Head and Neck Surgery*. 5th ed. Philadelphia, PA; Saunders: 2010. Reproduced with permission © Elsevier.

In order for pathologists to properly identify these nodes, they must be familiar with the terminology of the regional lymph node groups and with the relationships of those groups to the regional anatomy. Which lymph node groups surgeons submit for histopathologic evaluation depends on the type of neck dissection they perform. Therefore, surgeons must supply information on the types of neck dissections that they perform and the details of the local anatomy in the specimens they submit for examination or, in other manners, orient those specimens for pathologists.

If it is not possible to assess the levels of lymph nodes (for instance, when the anatomic landmarks in the excised specimens are not specified), then the lymph node levels may be estimated as follows: level II, upper third of internal jugular (IJ) vein or neck specimen; level III, middle third of IJ vein or neck specimen; level IV, lower third of IJ vein or neck specimen, all anterior to the sternocleidomastoid muscle.

#### **Level I. Submental Group (Sublevel IA)**

Lymph nodes within the triangular boundary of the anterior belly of the digastric muscles and the hyoid bone.

#### **Level I. Submandibular Group (Sublevel IB)**

Lymph nodes within the boundaries of the anterior and posterior bellies of the digastric muscle and the body of the mandible. The submandibular gland is included in the specimen when the lymph nodes within this triangle are removed.

### **Level II. Upper Jugular Group (Sublevels IIA and IIB)**

Lymph nodes located around the upper third of the internal jugular vein and adjacent spinal accessory nerve extending from the level of the carotid bifurcation (surgical landmark) or hyoid bone (clinical landmark) to the skull base. The posterior boundary is the posterior border of the sternocleidomastoid muscle, and the anterior boundary is the lateral border of the stylohyoid muscle.

### **Level III. Middle Jugular Group**

Lymph nodes located around the middle third of the internal jugular vein extending from the carotid bifurcation superiorly to the omohyoid muscle (surgical landmark), or cricothyroid notch (clinical landmark) inferiorly. The posterior boundary is the posterior border of the sternocleidomastoid muscle, and the anterior boundary is the lateral border of the sternohyoid muscle.

### **Level IV. Lower Jugular Group**

Lymph nodes located around the lower third of the internal jugular vein extending from the omohyoid muscle superiorly to the clavicle inferiorly. The posterior boundary is the posterior border of the sternocleidomastoid muscle, and the anterior boundary is the lateral border of the sternohyoid muscle.

### **Level V. Posterior Triangle Group (Sublevels VA and VB)**

This group comprises predominantly the lymph nodes located along the lower half of the spinal accessory nerve and the transverse cervical artery. The supraclavicular nodes are also included in this group. The posterior boundary of the posterior triangle is the anterior border of the trapezius muscle, the anterior boundary of the posterior triangle is the posterior border of the sternocleidomastoid muscle, and the inferior boundary of the posterior triangle is the clavicle.

### **Level VI. Anterior (Central) Compartment**

Lymph nodes in this compartment include the pre- and paratracheal nodes, precricoid (Delphian) node, and the perithyroidal nodes, including the lymph nodes along the recurrent laryngeal nerve. The superior boundary is the hyoid bone, the inferior boundary is the suprasternal notch, the lateral boundaries are the common carotid arteries and the posterior boundary by the prevertebral fascia.

### **Level VII. Superior Mediastinal Lymph Nodes**

Metastases at level VII are considered regional lymph node metastases; all other mediastinal lymph node metastases are considered distant metastases.

Lymph node groups removed from areas not included in the above levels, eg, scalene, suboccipital, and retropharyngeal, should be identified and reported from all levels separately. Midline nodes are considered ipsilateral nodes.

### **Extranodal Extension**

The status of cervical lymph nodes is the single most important prognostic factor in aerodigestive cancer. All macroscopically negative or equivocal lymph nodes should be submitted in toto. Grossly positive nodes may be partially submitted for microscopic documentation of metastasis. Reporting of lymph nodes containing metastasis should include whether there is presence or absence of extranodal extension (ENE),<sup>9</sup> which is now part of N staging. This finding consists of extension of metastatic tumor, present within the confines of the lymph node, through the lymph node capsule into the surrounding connective tissue, with or without associated stromal reaction. A distance of extension from the native lymph node capsule is now suggested (but not yet required) with the proposed stratification of ENE into ENema (>2 mm) and ENEmi (≤2 mm).<sup>10,11,12,13</sup> However, pitfalls in the measurement (i.e. in larger, matted lymph nodes, in nodes post fine-needle aspiration, and in nodes with near total replacement of lymph node architecture), and the

disposition of soft tissue deposits is still not resolved. In general, absence of ENE in a large (>3 cm) lymph node, especially with traversing fibrous bands, should be viewed with skepticism. Soft tissue deposits for lymph node metastases based on limited studies appear to be the equivalent of a positive lymph node with ENE and should be recorded as such.<sup>14</sup>

#### References

1. Smith BD, Haffty BG. Prognostic factoris in patients with head and neck cancer. In: Harrison LB, Sessions RB, Hong WK, eds. *Head and Neck Cancer: A Multidisciplinary Approach*. Philadelphia, PA: Lippincott Williams and Wilkins; 2009:51-75.
2. Seethala RR. Current state of neck dissection in the United States. *Head Neck Pathol*. 2009;3(3):238-245.
3. Sobin LH, Gospodarowicz MK, Wittekind CH, eds. *TNM Classification of Malignant Tumours*. New York: Wiley-Liss; 2009.
4. Singletary SE, Greene FL, Sobin LH. Classification of isolated tumor cells: clarification of the 6th edition of the American Joint Committee on Cancer Staging Manual. *Cancer*. 2003;98(12):2740-2741.
5. Broglie MA, Haerle SK, Huber GF, Haile SR, Stoeckli SJ. Occult metastases detected by sentinel node biopsy in patients with early oral and oropharyngeal squamous cell carcinomas: impact on survival. *Head Neck*. 2013;35(5):660-666.
6. Ferlito A, Robbins KT, Shah JP, et al. Proposal for a rational classification of neck dissections. *Head Neck*. 2011;33(3):445-450.
7. Robbins KT, Shaha AR, Medina JE, et al. Consensus statement on the classification and terminology of neck dissection. *Arch Otolaryngol Head Neck Surg*. 2008;134(5):536-538.
8. Suarez C, Rodrigo JP, Robbins KT, et al. Superselective neck dissection: rationale, indications, and results. *Eur Arch Otorhinolaryngol*. 2013.
9. Ebrahimi A, Gil Z, Amit M. International Consortium for Outcome Research (ICOR) in Head and Neck Cancer. Primary tumor staging for oral cancer and a proposed modification incorporating depth of invasion: an international multicenter retrospective study. *JAMA Otolaryngol Head Neck Surg*. 2014;140(12):1138-1148.
10. Ridge JA, Lydiatt WM, Patel SG, et al. Lip and oral cavity. In: Amin MB, ed. *AJCC Cancer Staging Manual*. 8th ed. New York, NY: Springer; 2017.
11. Ebrahimi A, Clark JR, Amit M, et al. Minimum nodal yield in oral squamous cell carcinoma: defining the standard of care in a multicenter international pooled validation study. *Ann Surg Oncol*. 2014;21(9):3049-3055.
12. Prabhu RS, Hanasoge S, Magliocca KR, et al. Extent of pathologic extracapsular extension and outcomes in patients with nonoropharyngeal head and neck cancer treated with initial surgical resection. *Cancer*. 2014;120(10):1499-1506.
13. Dunne AA, Muller HH, Eisele DW, Kessel K, Moll R, Werner JA. Meta-analysis of the prognostic significance of perinodal spread in head and neck squamous cell carcinomas (HNSCC) patients. *Eur J Cancer*. 2006;42(12):1863-1868.
14. Jose J, Moor JW, Coatesworth AP, Johnston C, MacLennan K. Soft tissue deposits in neck dissections of patients with head and neck squamous cell carcinoma: prospective analysis of prevalence, survival, and its implications. *Arch Otolaryngol Head Neck Surg*. 2004;130(2):157-160.

#### G. TNM and Stage Groupings

The protocol recommends the TNM staging system of the American Joint Committee on Cancer and the International Union Against Cancer for nasal cavity and paranasal sinus cancer.<sup>1,2</sup> Of note in the 7<sup>th</sup> edition of the AJCC staging of head and neck cancers<sup>1</sup> is the division of T4 lesions into T4a (moderately advanced local disease) and T4b (very advanced local disease), leading to the stratification of stage IV into stage IVA (moderately advanced local/regional disease), stage IVB (very advanced local/regional disease), and stage IVC (distant metastatic disease).

The 8<sup>th</sup> edition of the AJCC staging of head and neck cancers includes mucosal melanomas; this does not show significant changes from the 7<sup>th</sup> edition. Approximately two-thirds of mucosal melanomas arise in the sinonasal tract, one quarter are found in the oral cavity and the remainder occur only sporadically in other mucosal sites of the head and neck. Even small cancers behave aggressively with high rates of recurrence and death. To reflect this aggressive behavior, primary cancers limited to the mucosa are considered T3 lesions. Advanced mucosal melanomas are classified as T4a and T4b. The anatomic extent criteria to define *moderately advanced* (T4a) and *very advanced* (T4b) disease are given below. The AJCC staging for mucosal melanomas does not provide for the histologic definition of a T3 lesion; as the majority of mucosal melanomas are invasive at presentation, mucosal based melanomas (T3 lesions) include those lesions that involve either the epithelium and/or lamina propria of the involved site. Rare examples of in situ mucosal melanomas occur, but in situ mucosal melanomas are excluded from staging, as they are extremely rare.<sup>3</sup>

New to the 8<sup>th</sup> edition of the AJCC is the site-specific staging of head and neck soft tissue sarcomas.<sup>4</sup> Despite smaller size, they tend to have disproportionately greater risk of local recurrence compared with extremities.<sup>5</sup> While head and neck soft tissue sarcomas are not generally intrinsically different from their extremity counterparts, their proximity to vital anatomic structures (ie, major nerves, vessels, bone, and skull base). Mortality and morbidity from soft tissue sarcomas is mainly from uncontrolled local disease rather than distant metastatic spread. The traditional 5-cm size cut point separating T1 and T2 extremity soft tissue sarcomas is not meaningful for head and neck sarcomas since the majority are actually less than 5 cm in largest dimension.<sup>6,7,8</sup> Staging of soft tissue sarcomas in head and neck has thus been brought in line with size cut-offs for other head and neck cancers. Thus, T1 is used for tumors with a maximum dimension  $\leq 2$  cm, T2 for those  $>2$  cm to  $\leq 4$  cm, and T3 for those  $>4$  cm. Also in line with other head and neck cancers, T4a and T4b denote very extensive tumors using the same criteria. This staging is not applicable to the following soft tissue sarcoma types/sites: orbital sarcoma, Kaposi sarcoma, cutaneous angiosarcoma, embryonal and alveolar rhabdomyosarcoma, dermatofibrosarcoma protuberans. Grade is still a vital prognosticator for head and neck soft tissue sarcomas, and the FNCLCC system is used (see soft tissue protocols).

Carcinomas of minor salivary glands of the upper aerodigestive tract site, including the nasal cavity and paranasal sinuses, are staged according to schemes corresponding to the anatomic site of occurrence. There is no currently accepted staging for central (primary intraosseous) salivary gland tumors.

By AJCC/UICC convention, the designation “T” refers to a primary tumor that has not been previously treated. The symbol “p” refers to the pathologic classification of the TNM, as opposed to the clinical classification, and is based on gross and microscopic examination. pT entails a resection of the primary tumor or biopsy adequate to evaluate the highest pT category, pN entails removal of nodes adequate to validate lymph node metastasis, and pM implies microscopic examination of distant lesions. Clinical classification (cTNM) is usually carried out by the referring physician before treatment during initial evaluation of the patient or when pathologic classification is not possible.

Pathologic staging is usually performed after surgical resection of the primary tumor. Pathologic staging depends on pathologic documentation of the anatomic extent of disease, whether or not the primary tumor has been completely removed. If a biopsied tumor is not resected for any reason (eg, when technically unfeasible) and if the highest T and N categories or the M1 category of the tumor can be confirmed microscopically, the criteria for pathologic classification and staging have been satisfied without total removal of the primary cancer.

## Stage Groupings – For Soft Tissue Sarcomas

*As this is a new TNM staging, there are currently no stage groupings.*

### TNM Descriptors

For identification of special cases of TNM or pTNM classifications, the “m” suffix and “y” and “r” prefixes are used. Although they do not affect the stage grouping, they indicate cases needing separate analysis.

The “m” suffix indicates the presence of multiple primary tumors in a single site and is recorded in parentheses: pT(m)NM.

The “y” prefix indicates those cases in which classification is performed during or following initial multimodality therapy (ie, neoadjuvant chemotherapy, radiation therapy, or both chemotherapy and radiation therapy). The cTNM or pTNM category is identified by a “y” prefix. The ycTNM or ypTNM categorizes the extent of tumor actually present at the time of that examination. The “y” categorization is not an estimate of tumor prior to multimodality therapy (ie, before initiation of neoadjuvant therapy).

The “r” prefix indicates a recurrent tumor when staged after a documented disease-free interval, and is identified by the “r” prefix: rTNM.

### Additional Descriptors

#### Residual Tumor (R)

Tumor remaining in a patient after therapy with curative intent (eg, surgical resection for cure) is categorized by a system known as R classification, shown below.

- |    |   |
|----|---|
| RX | Presence of residual tumor cannot be assessed |
| R0 | No residual tumor                             |
| R1 | Microscopic residual tumor                    |
| R2 | Macroscopic residual tumor                    |

For the surgeon, the R classification may be useful to indicate the known or assumed status of the completeness of a surgical excision. For the pathologist, the R classification is relevant to the status of the margins of a surgical resection specimen. That is, tumor involving the resection margin on pathologic examination may be assumed to correspond to residual tumor in the patient and may be classified as macroscopic or microscopic according to the findings at the specimen margin(s).

### References

1. Gress DM, Edge SB, Greene FL, et al. Principles of cancer staging. In: Amin MB, ed. AJCC Cancer Staging Manual. 8th ed. New York, NY: Springer; 2017.
2. Jose J, Moor JW, Coatesworth AP, Johnston C, MacLennan K. Soft tissue deposits in neck dissections of patients with head and neck squamous cell carcinoma: prospective analysis of prevalence, survival, and its implications. Arch Otolaryngol Head Neck Surg. 2004;130(2):157-160.
3. Lydiatt WM, Brandwein-Gensler MS, Kraus DH, Mukherji SK, Ridge JA, Shah JP. Mucosal melanoma of the head and neck. In: Amin MB, ed. AJCC Cancer Staging Manual. 8th ed. New York, NY: Springer; 2017.
4. O'Sullivan B, Maki RG, Agulnik M, et al. Soft tissue sarcoma of the head and neck. In: Amin MB, ed. AJCC Cancer Staging Manual. 8th ed. New York, NY: Springer; 2017.

Approved

5. Penel N, Mallet Y, Robin YM, et al. Prognostic factors for adult sarcomas of head and neck. *Int J Oral Maxillofac Surg.* 2008;37(5):428-432.
6. Chang AE, Chai X, Pollack SM, et al. Analysis of clinical prognostic factors for adult patients with head and neck sarcomas. *Otolaryngol Head Neck Surg.* 2014;151(6):976-983.
7. Mattavelli D, Miceli R, Radaelli S, et al. Head and neck soft tissue sarcomas: prognostic factors and outcome in a series of patients treated at a single institution. *Ann Oncol.* 2013;24(8):2181-2189.
8. Park JT, Roh J-L, Kim S-O, et al. Prognostic factors and oncological outcomes of 122 head and neck soft tissue sarcoma patients treated at a single institution. *Ann Surg Oncol.* 2015;22(1):248-255.

## **H. Dysplasia of the Upper Aerodigestive Tract (UADT)**

Epithelial dysplasias of the nasal cavity and paranasal sinuses as a precursor lesion for sinonasal carcinomas are less common and less well defined as compared to epithelial dysplasias of the oral cavity and the larynx. Further, unlike dysplastic lesions of the oral cavity and/or the larynx, precursor lesions of the nasal cavity and paranasal sinuses are generally asymptomatic and therefore are not biopsied. Instead, they are identified more often in association with another lesion, such as an invasive carcinoma.

### **I. Scope of Guidelines**

The reporting of nasal cavity and paranasal sinus cancer is facilitated by the provision of a case summary illustrating the features required for comprehensive patient care. However, there are many cases in which the individual practicalities of applying such a case summary may not be straightforward. Common examples include finding the prescribed number of lymph nodes, trying to determine the levels of the radical neck dissection, and determining if isolated tumor cells in a lymph node represent metastatic disease. Case summaries have evolved to include clinical, radiographic, morphologic, immunohistochemical, and molecular results in an effort to guide clinical management. Adjuvant and neoadjuvant therapy can significantly alter histologic findings, making accurate classification an increasingly complex and demanding task. This protocol tries to remain simple while still incorporating important pathologic features as proposed by the American Joint Committee on Cancer (AJCC) cancer staging manual, the World Health Organization (WHO) classification of tumors, the TNM classification, the American College of Surgeons Commission on Cancer, and the International Union on Cancer (UICC). This protocol is to be used as a guide and resource, an adjunct to diagnosing and managing cancers of the nasal cavity and paranasal sinus in a standardized manner. It should not be used as a substitute for dissection or grossing techniques and does not give histologic parameters to reach the diagnosis. Subjectivity is always a factor, and elements listed are not meant to be arbitrary but are meant to provide uniformity of reporting across all the disciplines that use the information. It is a foundation of practical information that will help to meet the requirements of daily practice to benefit both clinicians and patients alike.