



Protocol for the Examination of Resection Specimens from Patients with Renal Cell Carcinoma

Version: 4.3.0.0

Protocol Posting Date: June 2026

CAP Laboratory Accreditation Program Protocol Required Use Date: March 2027

The changes included in this current protocol version affect accreditation requirements. The new deadline for implementing this protocol version is reflected in the above accreditation date.

For accreditation purposes, this protocol should be used for the following procedures AND tumor types:

Procedure	Description
Nephrectomy	Includes specimens designated partial, total, or radical nephrectomy
Tumor Type	Description
Renal cell carcinomas	Includes all renal cell carcinoma types

This protocol is NOT required for accreditation purposes for the following:

Procedure
Biopsy (use optional Kidney Biopsy protocol)
Primary resection specimen with no residual cancer (e.g., following neoadjuvant therapy)
Cytologic specimens
Low malignant potential tumors such as clear cell papillary renal tumor, multilocular cystic renal neoplasm of low malignant potential, and low-grade oncocytic neoplasms

The following tumor types should NOT be reported using this protocol:

Tumor Type
Urothelial tumors (use Ureter, Renal Pelvis protocol)
Nephroblastic (Wilms) tumors (use Wilms Tumor Resection protocol)
Hematopoietic neoplasms (use the Precursor and Mature Lymphoid neoplasm, Myeloid and Mixed / Ambiguous Lineage Neoplasms or Plasma Cell Malignancies and Immunoglobulin Deposition Related Disorders protocol)
Sarcoma (use the Soft Tissue protocol)

Version Contributors

Author(s): Paari Murugan, MD, FCAP*, Robert W. Allan, MD, FCAP*, Gladell P. Paner, MD, FCAP*, Mahul B. Amin, MD, FCAP*, Jason R. Pettus, MD, FCAP*, Veronica Klepeis, MD, PhD, FCAP*

Other Expert Contributors: John R. Srigley, MD, Sean Williamson, MD, Ying-Bei Chen, MD, PhD, Kiril Trpkov, MD, Michelle Hirsch, MD, PhD, Steven Smith, MD, PhD, Holger Moch, MD, Peter A. Humphrey, MD, PhD, Maria Carlo, MD, Viraj Master, MD, PhD, Lara R. Harik, MD, FCAP

* Denotes primary author.

For any questions or comments, contact: cancerprotocols@cap.org.

Glossary:

Author: Expert who is a current member of the Cancer Committee, or an expert designated by the chair of the Cancer Committee.

Expert Contributors: Includes members of other CAP committees or external subject matter experts who contribute to the current version of the protocol.

Accreditation Requirements

Synoptic reporting with core and conditional data elements for designated specimen types* is required for accreditation.

- Data elements designated as core must be reported.
- Data elements designated as conditional only need to be reported if applicable.
- Data elements designated as optional are identified with "+". Although not required for accreditation, they may be considered for reporting.

This protocol is not required for recurrent or metastatic tumors resected at a different time than the primary tumor. This protocol is also not required for pathology reviews performed at a second institution (i.e., second opinion and referrals to another institution).

Full accreditation requirements can be found on the CAP website under [Accreditation Checklists](#).

A list of core and conditional data elements can be found in the Summary of Required Elements under Resources on the CAP Cancer Protocols [website](#).

**Includes definitive primary cancer resection and pediatric biopsy tumor types.*

Synoptic Reporting

All core and conditionally required data elements outlined on the surgical case summary from this cancer protocol must be displayed in synoptic report format. Synoptic format is defined as:

- Data element: followed by its answer (response), outline format without the paired Data element: Response format is NOT considered synoptic.
- The data element should be represented in the report as it is listed in the case summary. The response for any data element may be modified from those listed in the case summary, including "Cannot be determined" if appropriate.
- Each diagnostic parameter pair (Data element: Response) is listed on a separate line or in a tabular format to achieve visual separation. The following exceptions are allowed to be listed on one line:
 - Anatomic site or specimen, laterality, and procedure
 - Pathologic Stage Classification (pTNM) elements
 - Negative margins, as long as all negative margins are specifically enumerated where applicable
- The synoptic portion of the report can appear in the diagnosis section of the pathology report, at the end of the report or in a separate section, but all Data element: Responses must be listed together in one location
- Organizations and pathologists may choose to list the required elements in any order, use additional methods in order to enhance or achieve visual separation, or add optional items within the synoptic report. The report may have required elements in a summary format elsewhere in the report, IN ADDITION TO but not as a replacement for the synoptic report, i.e., all required elements must be in the synoptic portion of the report in the format defined above.

Summary of Changes

v 4.3.0.0

- Removed the Histologic Features question to make Rhabdoid Features and Sarcomatoid Features two separate questions
- Removed Additional Dimensions for Tumor Size
- G4 Histologic Grade is now a list item (previously a list item response), and GX, cannot be determined now a list item response (previously a list item)

Reporting Template

Protocol Posting Date: June 2026

Select a single response unless otherwise indicated.

CASE SUMMARY: (KIDNEY: Nephrectomy)

Standard(s): AJCC 8

SPECIMEN (Note [A](#))

Procedure

- Partial nephrectomy
- Total (simple) nephrectomy
- Radical nephrectomy
- Other (specify): _____
- Not specified

Specimen Laterality

- Right
- Left
- Other (specify): _____
- Not specified

TUMOR

Tumor Focality

- Unifocal
- Multifocal (specify numbers of tumors): _____

+Tumor Site (select all that apply)

- Upper pole
- Middle
- Lower pole
- Other (specify): _____
- Not specified

Tumor Size

If multiple tumors are present, document the size of the largest tumor.

Greatest dimension in Centimeters (cm): _____ cm

+Greatest Dimension of Other Tumor(s) in Centimeters (cm) (repeat as needed):

_____ cm

Cannot be determined (explain): _____

Histologic Type (Note [B](#))

Clear cell tumors

- Clear cell renal cell carcinoma
- Multilocular cystic renal neoplasm of low malignant potential

Papillary renal tumors

- Papillary renal cell carcinoma
- Oncocytic and chromophobe renal tumors*
- Chromophobe renal cell carcinoma
- Other oncocytic tumors of the kidney (specify): _____
- Collecting duct tumors*
- Collecting duct carcinoma
- Other renal tumors*
- Clear cell papillary renal cell tumor
- Mucinous tubular and spindle renal cell carcinoma
- Tubulocystic renal cell carcinoma
- Acquired cystic disease-associated renal cell carcinoma
- Eosinophilic solid and cystic renal cell carcinoma
- Renal cell carcinoma, NOS (unclassified)
- Molecularly defined renal carcinomas*
- TFE3-rearranged renal cell carcinoma
- TFE3-altered renal cell carcinoma
- ELOC (formerly TCEB1)-mutated renal cell carcinoma
- Fumarate hydratase-deficient renal cell carcinoma
- Succinate dehydrogenase-deficient (SDH) renal cell carcinoma
- ALK-rearranged renal cell carcinoma
- SMARCB1-deficient renal medullary carcinoma
- Other*
- Renal cell carcinoma, subtype pending additional studies
- Other histologic type not listed (specify): _____
- +Histologic Type Comment:** _____

Histologic Grade (WHO / ISUP) (Note C)

See table for renal carcinoma subtype grading requirements

- G1, nucleoli absent or inconspicuous at 400x magnification
- G2, nucleoli conspicuous and visible at 400x magnification, not prominent at 100x magnification
- G3, nucleoli conspicuous at 100x magnification
- G4, extreme nuclear pleomorphism and / or multinucleated giant cells and / or rhabdoid and / or sarcomatoid differentiation
- GX, cannot be assessed: _____
- Not applicable: _____
- +Histologic Grade Comment:** _____

Tumor Extent (Note D) (select all that apply)

- Limited to kidney
- Extends into perinephric tissue (beyond renal capsule)
- Extends into renal sinus
- Extends into pelvicalyceal system
- Extends into renal vein or its segmental branches
- Extends into inferior vena cava
- Extends beyond renal Gerota's fascia (renal fascia)
- Directly invades adrenal gland (T4)

- Involves adrenal gland non-contiguously (M1)
- Extends into other organ(s) / structure(s) (specify): _____
- Cannot be determined (explain): _____

Rhabdoid Features (Note E)

- Not identified
- Present
- +Specify Percentage of Rhabdoid Component:** _____ %
- Cannot be determined (explain): _____

Sarcomatoid Features (Note E)

- Not identified
- Present
- +Specify Percentage of Sarcomatoid Component:** _____ %
- Cannot be determined (explain): _____

Tumor Necrosis (Note F)

- Not identified
- Present
- +Specify Percentage of Tumor Necrosis:** _____ %
- Cannot be determined (explain): _____

Lymphatic and / or Small Vessel Vascular Invasion (excluding renal vein and its segmental branches and inferior vena cava)

- Not identified
- Present
- Cannot be determined (explain): _____

+Tumor Comment: _____

MARGINS (Note G)

Margin Status

- All margins negative for invasive carcinoma
- Invasive carcinoma present at margin

Margin(s) Involved by Invasive Carcinoma (select all that apply)

For partial nephrectomy only

- Renal parenchymal#: _____
- Renal capsular#: _____
- Renal sinus soft tissue#: _____
- Renal hilar soft tissue: _____
- Renal vein (tumor invades or is adherent to vein wall at margin): _____
- Ureteral: _____
- Perinephric fat: _____
- Gerota's fascia: _____
- Other (specify): _____

- Cannot be determined (explain): _____
- Other (specify): _____
- Cannot be determined (explain): _____
- Not applicable

+Margin Comment: _____

REGIONAL LYMPH NODES

Regional Lymph Node Status

- Not applicable (no regional lymph nodes submitted or found)
- Regional lymph nodes present
 - All regional lymph nodes negative for tumor
 - Tumor present in regional lymph node(s)

Number of Lymph Nodes with Tumor

- Exact number (specify): _____
- At least (specify): _____
- Other (specify): _____
- Cannot be determined (explain): _____

+Nodal Site(s) with Tumor (select all that apply)

- Hilar: _____
- Precaval: _____
- Interaortocaval: _____
- Paracaval: _____
- Retrocaval: _____
- Preaortic: _____
- Paraaortic: _____
- Retroaortic: _____
- Other (specify): _____

+Size of Largest Nodal Metastatic Deposit

Specify in Centimeters (cm)

- Exact size: _____ cm
- At least: _____ cm
- Greater than: _____ cm
- Less than: _____ cm
- Other (specify): _____
- Cannot be determined: _____

+Specify Nodal Site with Largest Metastatic Deposit: _____

+Extranodal Extension (ENE)

- Not identified
- Present

+Specify Location of Involved Lymph Node(s): _____

- Cannot be determined: _____
- Other (specify): _____
- Cannot be determined (explain): _____

Number of Lymph Nodes Examined

- Exact number (specify): _____
- At least (specify): _____
- Other (specify): _____
- Cannot be determined (explain): _____

+Regional Lymph Node Comment: _____

DISTANT METASTASIS

Distant Site(s) Involved, if applicable

- Not applicable
- Specify site(s): _____
- Cannot be determined (explain): _____

pTNM CLASSIFICATION (AJCC 8th Edition) (Note [H](#))

Reporting of pT, pN, and (when applicable) pM categories is based on information available to the pathologist at the time the report is issued. As per the AJCC (Chapter 1, 8th Ed.) it is the managing physician's responsibility to establish the final pathologic stage based upon all pertinent information, including but potentially not limited to this pathology report.

Modified Classification (required only if applicable) (select all that apply)

- Not applicable
- y (post-neoadjuvant therapy)
- r (recurrence)

pT Category

- pT not assigned (cannot be determined based on available pathological information)
- pT0: No evidence of primary tumor
- pT1: Tumor less than or equal to 7 cm in greatest dimension, limited to the kidney*
 - pT1a: Tumor less than or equal to 4 cm in greatest dimension, limited to the kidney
 - pT1b: Tumor greater than 4 cm but less than or equal to 7 cm in greatest dimension limited to the kidney
 - pT1 (subcategory cannot be determined)
- pT2: Tumor greater than 7 cm in greatest dimension, limited to the kidney*
 - pT2a: Tumor greater than 7 cm but less than or equal to 10 cm in greatest dimension, limited to the kidney
 - pT2b: Tumor greater than 10 cm, limited to the kidney
 - pT2 (subcategory cannot be determined)
- pT3: Tumor extends into major veins or perinephric tissues, but not into the ipsilateral adrenal gland and not beyond Gerota's fascia*
 - pT3a: Tumor extends into the renal vein or its segmental branches, or invades the pelvicalyceal system, or invades perirenal and / or renal sinus fat but not beyond Gerota's fascia
 - pT3b: Tumor extends into the vena cava below the diaphragm
 - pT3c: Tumor extends into the vena cava above the diaphragm or invades the wall of the vena cava
 - pT3 (subcategory cannot be determined)
- pT4: Tumor invades beyond Gerota's fascia (including contiguous extension into the ipsilateral adrenal gland)

T Suffix (required only if applicable)

- Not applicable
- (m) multiple primary synchronous tumors in a single organ

pN Category

- pN not assigned (no nodes submitted or found)
- pN not assigned (cannot be determined based on available pathological information)
- pN0: No regional lymph node metastasis
- pN1: Metastasis in regional lymph node(s)

pM Category (required only if confirmed pathologically)

- Not applicable - pM cannot be determined from the submitted specimen(s)
- pM1: Distant metastasis (including non-contiguous adrenal gland involvement)

ADDITIONAL FINDINGS (Note !)

Additional Findings in Kidney (select all that apply)

- Insufficient tissue
- No significant pathologic change identified
- Glomerular disease (specify type): _____
- Tubulointerstitial disease (specify type): _____
- Vascular disease (specify type): _____
- Cyst(s) (specify type): _____
- Papillary adenoma(s): _____
- Other (specify): _____

COMMENTS

Comment(s): _____

Explanatory Notes

A. Specimen Type

A standard radical nephrectomy specimen consists of the entire kidney including the calyces, pelvis, and a variable length of ureter. Although in the past the adrenal gland was considered a standard part of radical nephrectomy, current surgical recommendations are that the adrenal gland should not be removed unless there is suspicion for involvement. The entire perirenal fatty tissue is removed to the level of Gerota's fascia, a membranous structure that is similar to the consistency of the renal capsule that encases the kidney in perirenal fat. Variable lengths of the major renal vessels at the hilus are submitted. Total nephrectomy is a similar procedure but typically performed for clinical presumption of benign disease and may not extend to Gerota's fascia.

Regional lymphadenectomy is not generally performed even with a radical nephrectomy unless there is clinical suspicion of involved or abnormal lymph nodes. A few lymph nodes may occasionally be found in the renal hilus around major vessels. Other regional lymph nodes (e.g., paracaval, para-aortic, and retroperitoneal) may be submitted separately.

A partial nephrectomy specimen may vary from an enucleation of the tumor with almost no normal tissue to a partial resection containing variable portions of calyceal or renal pelvic collecting system. The perirenal fat immediately overlying the resected portion of the kidney is usually included, but not to the level of Gerota's fascia. The perinephric fat may also be detached by the surgeon to improve visualization of the tumor, and either submitted detached in the same specimen, or as a separate specimen.

B. Histologic Type

This protocol was updated to incorporate the changes made in the 5th edition WHO Urinary and Male Genital Tumors Classification.¹

The updated entities that should be reported using the kidney cancer protocol are listed below:

Clear cell renal tumors

- Clear cell renal cell carcinoma
- Multilocular cystic renal neoplasm of low malignant potential

Papillary renal tumors

- Papillary renal cell carcinoma

Oncocytic and chromophobe renal cell tumors

- Chromophobe renal cell carcinoma
- Other oncocytic tumors of the kidney

Collecting duct tumors

- Collecting duct carcinoma

Other renal tumors

- Clear cell papillary renal cell tumor
- Mucinous tubular and spindle cell carcinoma
- Tubulocystic renal cell carcinoma

Acquired cystic disease-associated renal cell carcinoma
Eosinophilic solid and cystic renal cell carcinoma
Renal cell carcinoma, NOS

Molecularly defined renal carcinoma

TFE3-rearranged renal cell carcinomas
TFEB-altered renal cell carcinomas
ELOC (formerly *TCEB1*)-mutated renal cell carcinoma
Fumarate hydratase-deficient renal cell carcinoma
Succinate dehydrogenase-deficient renal cell carcinoma
ALK-rearranged renal cell carcinomas
SMARCB1-deficient renal medullary carcinoma

The changes made in the 5th WHO edition are summarized below and the reader is encouraged to reference the updated manuscript.

Papillary renal cell carcinoma: Subclassification into type 1 and type 2 is no longer recommended. This reflects the recognition that many tumors characterized as type 2 papillary renal cell carcinoma now represent other distinct entities (e.g., Fumarate hydratase-deficient renal cell carcinoma).

Other oncocytic tumors of the kidney: This is a heterogeneous group of renal tumors with eosinophilic/oncocytic cells with oncocytoma-like and/or chromophobe renal cell carcinoma-like features. This includes hybrid oncocytic tumors (HOCT) that may occur sporadically or associated with Birt-Hogg-Dube syndrome; the emerging entities of eosinophilic vacuolated tumor (EVT), low-grade oncocytic tumor (LOT) and other eosinophilic/oncocytic tumors with intermediate (borderline) features.

Clear cell papillary renal cell tumor (CCPRCT): Renamed from carcinoma to tumor to reflect its indolent behavior.

Eosinophilic solid and cystic renal cell carcinoma: This was recognized as a separate entity characterized by solid and cystic architecture with voluminous eosinophilic cytoplasm, frequent (but not required) keratin 20 reactivity and typically negative keratin 7 expression. The clinical behavior is indolent in the great majority of cases and these tumors may occur in association with tuberous sclerosis complex or sporadically. In both settings, there are alterations in the *TSC1/2* genes.

Renal cell carcinoma, NOS: This category should be reserved for carcinomas that cannot be placed into one of the morphologically and molecularly defined categories. These are usually high-grade. Low-grade oncocytic tumors that are difficult to classify should be placed in the “Other oncocytic tumors of the kidney” group.

Molecularly defined renal cell carcinoma

The category of molecularly defined renal carcinoma was added to the 5th edition WHO to include carcinomas that demonstrate characteristic molecular alterations that define these tumor types.

TFE3-rearranged renal cell carcinomas: This was formerly called Xp11 translocation renal cell carcinoma. These tumors morphologically often show mixed papillary and solid architecture, with mixed clear and

eosinophilic cytoplasm, sometimes with scattered psammoma bodies. These tumors are characterized by *TFE3* rearrangements, revealed by nuclear expression of *TFE3* protein or preferably, demonstration of *TFE3* rearrangement by break-apart FISH or sequencing methods. Other immunohistochemical markers that may be positive include variable melanocytic markers, cathepsin K, and GPNMB.

TFEB-altered renal cell carcinoma: This category encompasses renal carcinoma that possess either a *TFEB* rearrangement or *TFEB*/6p21 amplification. *TFEB* rearranged carcinomas frequently display a biphasic pattern with smaller cells clustering around basement membrane-like material surrounded by larger epithelioid cells. However, other patterns can also be present that may overlap with clear cell renal cell carcinoma, *TFE3* rearranged renal cell carcinoma, and tumors with oncocytic features. *TFEB* amplified carcinoma is less characteristic and may appear poorly differentiated and infiltrative with papillary and oncocytic features. Useful markers for detection of *TFEB* rearranged carcinomas include the melanocytic markers melan-A and HMB45, cathepsin K, or nuclear reactivity for *TFEB* protein. *TFEB* amplified carcinomas may also have melanocytic marker and cathepsin K positivity, and some are positive for keratin 20, overlapping with the immunohistochemical pattern of eosinophilic solid and cystic renal cell carcinoma. If a break-apart FISH method is used, *TFEB* amplified carcinomas show numerous copies of the *TFEB* region, usually without rearrangement. Other genes at 6p21, such as *VEGFA*, are typically included in the amplicon. Whereas *TFE3/TFEB* rearranged carcinomas have a tendency to occur in younger patients (although not always), *TFEB* amplified carcinomas appear to occur in older patients and have a worse prognosis.^{2,3}

ELOC mutated renal cell carcinoma: The *ELOC* gene was formerly known as *TCEB1*, therefore, this tumor was formerly known as *TCEB1* mutated renal cell carcinoma. These tumors tend to be small and of low stage, with prominent fibromuscular bands, overlapping with renal cell carcinoma with leiomyomatous or fibromyomatous stroma. Keratin 7 appears to be consistently expressed, and the tumor is characterized by bi-allelic inactivation of *ELOC*. Data are limited; however, behavior appears mostly favorable.

Fumarate hydratase (*FH*) deficient renal cell carcinoma: This entity was previously known as hereditary leiomyomatosis and renal cell carcinoma syndrome-associated renal cell carcinoma. This is typically an aggressive tumor with variable architecture patterns (papillary, solid, tubulocystic, cribriform) with high-grade appearing cells with prominent bright red macronucleoli and perinucleolar clearing. The morphological spectrum was recently expanded to include cases with low-grade oncocytic morphology. These tumors have mutations in the fumarate hydratase (*FH*) gene which can be demonstrated by lack of *FH* protein expression (“loss”) and 2-succinocysteine (2SC) reactivity by immunohistochemistry. Rarely, mutated tumors may show focal or patchy *FH* staining, presumably due to a dysfunctional protein that remains recognizable by the antibody. Most patients are thought to have germline *FH* alterations and thus the hereditary leiomyomatosis and renal cell carcinoma syndrome, accompanied also by skin and uterine leiomyomas (in females); however, a subset of tumors appear to occur due to somatic *FH* mutations in the absence of the syndrome.

Succinate dehydrogenase-deficient renal cell carcinoma: This rare renal cell carcinoma typically has bland, bubbly eosinophilic cells, overlapping with oncocytic tumors such as oncocytoma and chromophobe renal cell carcinoma. The most diagnostic finding is immunohistochemistry for *SDHB* showing abnormal absence of staining in the tumor cells (“loss”) serving as a surrogate marker for *SDH* gene complex alterations. Contrasting to most other oncocytic tumors, these neoplasms are typically negative for *KIT* and entirely

negative for keratin 7. Most patients have germline *SDHB* alterations and thus the hereditary SDH-deficient tumor syndrome.

ALK-rearranged renal cell carcinoma: *ALK*-rearranged renal cell carcinoma is newly included in the 5th edition WHO Classification. These tumors show variable morphology, including solid, papillary, and cribriform patterns. Mucin production is a common feature. Tumors are characterized by rearrangements of *ALK* demonstrated by positive immunohistochemistry or abnormal FISH. Although very rare, this tumor type may be particularly relevant for treatment, as *ALK* inhibitors appear to have benefit.

SMARCB1-deficient renal medullary carcinoma: *SMARCB1*-deficient renal medullary carcinoma was previously designated renal medullary carcinoma but has been brought under the umbrella of molecularly defined renal cell carcinoma. This tumor type retains the classical association with renal medullary location and strong association with sickle cell trait or rarely other hemoglobinopathies. The name was updated to include the characteristic loss of *SMARCB1* (also known as *INI1*, *BAF47*) demonstrable by immunohistochemistry that serves as a surrogate for *SMARCB1* inactivation on 22q11.23. An important point to emphasize is that this category should be reserved for those tumors with medullary location/phenotype that are very frequently, but not always associated with sickle cell trait. Other renal cell carcinoma subtypes, for example clear cell with sarcomatoid transformation or FH deficient renal cell carcinoma, may show secondary *SMARCB1* loss and should be categorized according to the underlying morphologic/genetic feature.

The category of “Other histologic type not listed (specify)” can be used to diagnose entities that are emerging provisional entities such as, biphasic hyalinizing psammomatous renal cell carcinoma, or thyroid-like follicular renal cell carcinoma.

In recognition of the increasing number of molecularly defined renal cell carcinomas, a category of “Renal cell carcinoma, subtype pending additional studies” has been added to the protocol. Since many pathologists will not have immediate access to the immunohistochemistry (IHC) and molecular studies required to define these rare tumors, this category facilitates preliminary sign-out while awaiting reference lab results. An addendum report should be issued on completion of the additional studies.

References

1. WHO Classification of Tumours Editorial Board. *Urinary and male genital tumours*. Lyon (France): International Agency for Research on Cancer; 2022. (WHO classification of tumours series, 5th ed.; vol. 8). <https://publications.iarc.fr/610>.
2. Kammerer-Jacquet SF, Gandon C, Dugay F, et al. Comprehensive study of nine novel cases of TFEB-amplified renal cell carcinoma: an aggressive tumour with frequent PDL1 expression. *Histopathology*. 2022 Aug;81(2):228-238.
3. Lobo J, Rechsteiner M, Helmchen BM, et al. Eosinophilic solid and cystic renal cell carcinoma and renal cell carcinomas with TFEB alterations: a comparative study. *Histopathology*. 2022 Jul;81(1):32-43.

C. Histologic Grade

Grade should be assigned based on the highest grade cells present in a single high power field rather than the most predominant pattern.^{1,2} Grade is based upon the degree of nucleolar predominance (grades 1-3) and presence of nuclear pleomorphism, including giant cells, sarcomatoid or rhabdoid features (grade 4).

This grading system has been validated for both clear cell and papillary renal cell carcinoma; however, it has not been validated for other RCC subtypes.^{3,4} Nevertheless, the WHO/ISUP grade should be included for descriptive purposes. The following table^{5,6} outlines the utility of grading in the different subtypes of renal carcinoma.

Category and Tumor Type	Notes
RCC subtypes validated for WHO/ISUP grading	
Clear cell RCC	
Papillary RCC	
RCC subtypes where WHO/ISUP grading is clearly not applicable	
Chromophobe RCC	WHO/ISUP grading is not applicable; alternative schemes have been proposed, such as chromophobe tumor grade and grading by necrosis and sarcomatoid change
<i>TFE3</i> -rearranged RCC	Studies show that WHO/ISUP grade may not be useful
RCC subtypes where WHO/ISUP grading is potentially useful	
SDH-deficient RCC	Low and high-grade features using Fuhrman or WHO/ISUP grading seem to be associated with outcome, suggesting the potential value of nuclear grading
Mucinous tubular and spindle cell carcinoma	
<i>ELOC</i> -mutated RCC ^a	
<i>TFEB</i> -altered RCC	WHO/ISUP grade may help separate aggressive <i>TFEB</i> -amplified RCC from <i>TFEB</i> -rearranged RCC
RCC, NOS	Includes tumors with heterogeneous morphology; providing information on nuclear grade ^b would be helpful to communicate potential prognosis to clinicians
<i>FH</i> -deficient RCC including HLRCC-RCC	The vast majority of tumors have high-grade ^b nuclei, in keeping with their aggressive behavior, but rare low-grade potentially indolent tumors have been reported; therefore, specifying the low-grade tumors (to distinguish from the more common high-grade tumors) may be helpful
Inherently aggressive RCC subtypes irrespective of WHO/ISUP grading	
Collecting duct carcinoma	Inherent high-grade nuclei and almost uniform aggressive clinical course in these tumor types obviates use of nuclear grading
<i>SMARCB1</i> -deficient renal medullary carcinoma	
RCC subtypes where WHO/ISUP grading is potentially misleading	
Tubulocystic carcinoma	Nuclear grading ^b may be problematic because of pure or predominantly high-grade-appearing nuclei despite the overall indolent behavior of tumor types
Acquired cystic disease-associated RCC	
Eosinophilic solid and cystic RCC and eosinophilic vacuolated tumor	
Renal epithelial neoplasms where low WHO/ISUP grade features are essential for accurate histological classification	
Papillary adenoma	
Multilocular cystic renal neoplasm of low malignant potential	
Clear cell papillary renal cell tumor	
Renal epithelial neoplasm with no or limited data on grading or behavior	
<i>ALK</i> -rearranged RCC	

Other oncocytic tumors	
Other oncocytic tumors	Other oncocytic tumors in the 5 th edition WHO classification are low or high-grade tumors even though their histological features are not predictive of clinical behavior

FH, fumarate hydratase; HLRCC-RCC, hereditary leiomyomatosis, and renal cell carcinoma syndrome-associated renal cell carcinoma; RCC, renal cell carcinoma; SDH, succinate dehydrogenase.

^aFormerly *TCEB1*-mutated RCC. ^bNuclear grade: used here when a grading system is not specified in the literature, or when the data span the Fuhrman and WHO/ISUP grading systems or when they mention nuclear grade without specific criteria. WHO/ISUP grading may be generally inferred from nuclear features, with G1 and G2 tumors being low-grade and G3 and G4 tumors being high-grade.

References

1. Moch H, Humphrey PA, Ulbright TM, Reuter VE, eds. World Health Organization (WHO) Classification of Tumours: Pathology and Genetics of the Urinary System and Male Genital Organs. Geneva, Switzerland: WHO Press; 2016.
2. Delahunt B, Cheville JC, Martignoni G, et al. The International Society of Urological Pathology (ISUP) grading system for renal cell carcinoma and other prognostic parameters. *Am J Surg Pathol*. 2013; 37:1490-1504.
3. Sika-Paotonu D, Bethwaite PB, McCredie MRE, Jordan TW, Delahunt B. Nucleolar grade but not Fuhrman grade is applicable to papillary renal cell carcinoma. *Am J Surg Pathol*. 2006; 30:1091-1096.
4. Delahunt B, Sika-Paotonu D, Bethwaite PB, et al. Grading of clear cell renal cell carcinoma should be based on nucleolar prominence. *Am J Surg Pathol*. 2011; 135:1134-1139.
5. Raspollini MR, Moch H, Tan PH, et al. *Tumours of the kidney*. In: WHO Classification of Tumours Editorial Board, eds. Urinary and Male Genital Tumours. WHO Classification of Tumours. Geneva, Switzerland: WHO Press; 2022.
6. Paner GP, Chumbalkar V, Montironi R, et al. Updates in Grading of Renal Cell Carcinomas Beyond Clear Cell Renal Cell Carcinoma and Papillary Renal Cell Carcinoma. *Adv Anat Pathol*. 2022 May 1;29(3):117-130.

D. Extent of Tumor

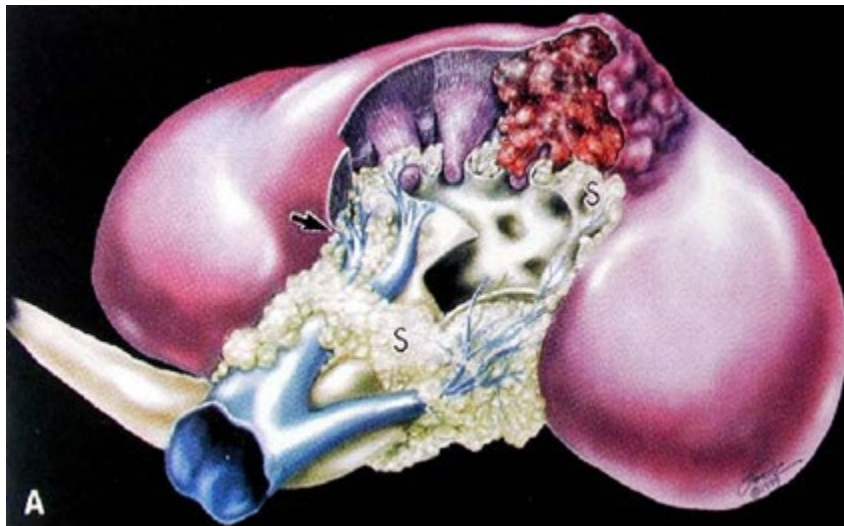A careful gross analysis and description of tumor extension in a nephrectomy specimen is important and should guide blocking of tissue samples for histologic assessment.¹ Careful documentation of the tumor extension beyond kidney into the renal vein, renal sinus, perinephric fat and Gerota's fascia (pT4) provides important staging information.^{2,3} Histologic sampling should be utilized to confirm the presence of renal vein invasion. Perinephric adipose tissue (outer surface of the kidney away from the renal sinus) extension is present when there is one or more of the following features: (1) direct tumor invasion of perinephric adipose tissue (2) irregular tongues of tumor extending beyond the renal capsule and (3) separate tumor nodules distributed in the adjacent perinephric adipose tissue beyond the renal capsule or tumor pseudo capsule. Invasion of the renal capsule without extension into perinephric soft tissue has no adverse prognostic significance⁴ and carcinomas with this finding are not upstaged to pT3.

The renal sinus is an anatomical compartment separating the renal parenchyma from the collecting system (renal pelvis and calyces).^{1,5} This area contains abundant adipose tissue, lymphatics, and thin-walled veins. In recent years, the definition of renal sinus involvement has been clarified and includes the following: (1)

tumor in contact with renal sinus fat, (2) tumor infiltrating the loose connective tissue of the sinus that is clearly beyond the renal parenchyma, and (3) involvement of any endothelial lined space within the renal sinus (with or without mural smooth muscle), including lymphatics.^{1,6,7}

Renal sinus involvement in renal cell carcinoma is an under-recognized phenomenon.⁵ The renal sinus is an important pathway of spread of renal cell carcinoma (Figure 1, A and B). The renal sinus should be carefully assessed and generously sampled to detect renal sinus fat and vessel involvement, particularly in larger tumors ($\geq 7\text{cm}$), as renal sinus invasion is present in greater than 90% of these tumors.^{1,6} As tumor size increases over 4 cm, the likelihood of renal sinus invasion increases dramatically.⁸

Although earlier literature suggested that renal sinus involvement predicts a more aggressive outcome than peripheral perinephric fat invasion, more recent studies show the presence of multiple patterns of extrarenal extension is associated with a higher risk of disease progression and cancer-related death after radical nephrectomy compared to isolated involvement of the perinephric fat, renal sinus fat, or renal vein, which carry similar prognostic weight.^{8,9,10,11} If a tumor thrombus is present in the renal vein it is important to determine if the tumor is confined to the renal vein (pT3a), or whether it extends into inferior vena cava (pT3b/c) or invades into the wall of the inferior vena cava (pT3c). When renal carcinoma involves the adrenal gland, it is important to document whether the involvement is contiguous spread of tumor (pT4) or a separate (noncontiguous) nodule of carcinoma, the latter representing metastatic disease (pM1) (Figure 2).^{2,9,12} Additionally, the presence of metastatic disease in any other accompanying organs would be considered pM1 disease for the purpose of the TNM system.²



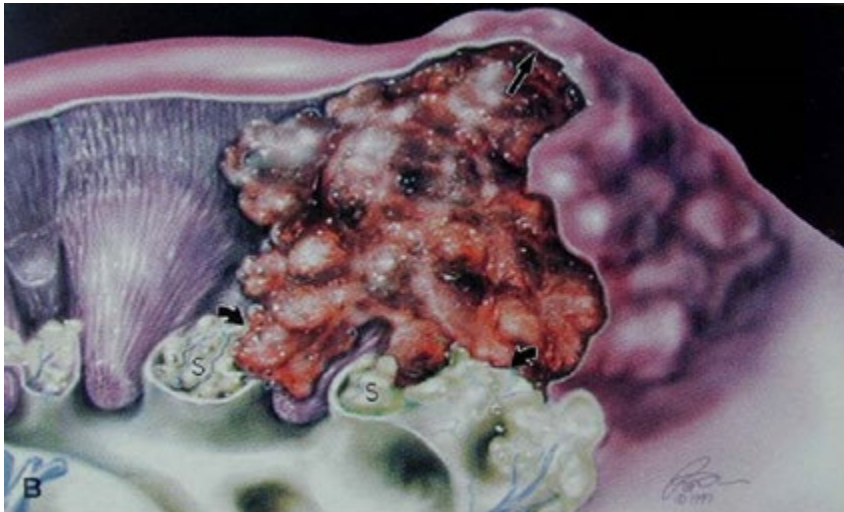


Figure 1. A: Diagram showing the renal sinus fat (S) and its rich venous system that envelops the collecting system. The renal capsule terminates (arrow) just inside the vestibule of the hilus. B: A renal malignancy is constrained by the renal capsule (arrow), yet no fibrous capsule impedes its growth into the vascular tissue of the renal sinus (curved arrows). From Bonsib et al.⁵ Reproduced with permission of the *American Journal of Surgical Pathology*. © 2000 Wolters Kluwer Health.

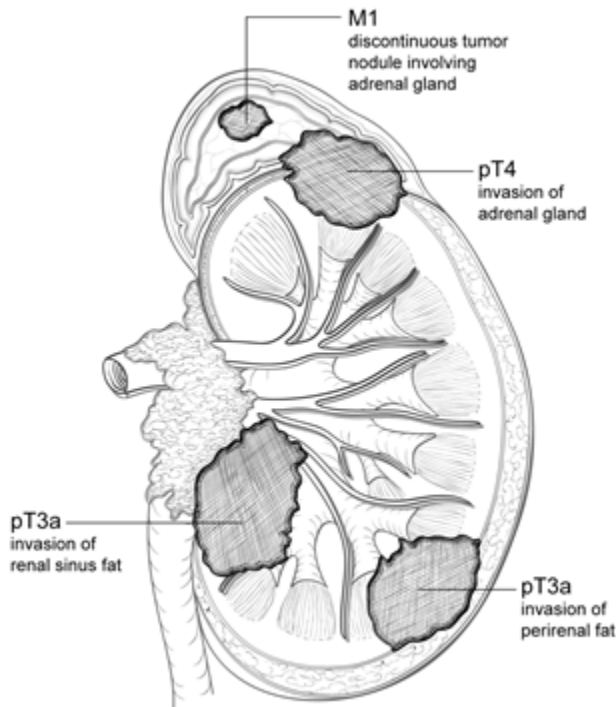


Figure 2. Diagram showing relationship between local tumor extension and pT designation. When a tumor shows direct invasion into the perirenal fat or renal sinus fat, it is designated as pT3a. A tumor that directly invades the adrenal gland is designated as pT4, while a tumor that shows discontinuous (noncontiguous) involvement of the adrenal gland is considered metastatic (M1).

References

1. Trpkov K, Grignon DJ, Bonsib SN, et al. Handling and staging of renal cell carcinoma: the International Society of Urological Pathology (ISUP) Consensus conference recommendations. *Am J Surg Pathol*. 2013; 37:1505-1517.
2. Amin MB, Edge SB, Greene FL, et al., eds. *AJCC Cancer Staging Manual*. 8th ed. New York, NY: Springer; 2017.
3. Brierley JD, Gospodarowicz MK, Wittekind CH, et al., eds. *TNM Classification of Malignant Tumours*. 8th ed. Oxford: Wiley;2016.
4. Sürer E, Ergün G, Baltacı S, Bedük Y. Does renal capsular invasion have any prognostic value in localized renal cell carcinoma? *J Urol*. 2008 Jul;180(1):68-71.
5. Bonsib SM, Gibson D, Mhoon M, Greene GF. Renal sinus involvement in renal cell carcinoma. *Am J Surg Pathol*. 2000; 24:451-458.
6. Bonsib SM. Renal lymphatics and lymphatic involvement in sinus vein invasive (pT3b) clear cell renal cell carcinoma: a study of 40 cases. *Mod Pathol*. 2006; 19:746-753.
7. Madbouly K, Al-Qahtani SM, Ghazwani Y, et al. Microvascular tumour invasion: prognostic significance in low stage renal cell carcinoma. *Urology*. 2007; 69:670-674.
8. Bonsib SM. T2 clear cell renal cell carcinoma is a rare entity: a study of 120 clear cell renal cell carcinomas. *J Urol*. 2005; 174:1199-1202.
9. Thompson RH, Leibovich BC, Chevillet JC, et al. Is renal sinus fat invasion the same as perinephric fat invasion for pT3a renal cell carcinoma? *J Urol*. 2005; 174:1218-1221.
10. Shah PH, Lyon TD, Lohse CM, Chevillet JC, Leibovich BC, Boorjian SA, Thompson RH. Prognostic evaluation of perinephric fat, renal sinus fat, and renal vein invasion for patients with pathological stage T3a clear-cell renal cell carcinoma. *BJU Int*. 2019 Feb;123(2):270-276.
11. Wang Z, Yu K, Zhu Y, Feng C, Liu C, Liu S, Wang J, Zeng X. Multiple Patterns of Perirenal Fat Invasion Are Associated with a Poorer Prognosis Compared with Isolated Invasion: A Proposal for a Revision of T3aN0M0 TNM Staging System. *Front Oncol*. 2020 Mar 11; 10:336.
12. Ficcaro V, Novara G, Iafrate M, et al. Proposal for reclassification of the TNM staging system in patients with locally advanced (pT3-4) renal cell carcinoma according to the cancer-related outcome. *Eur Urol*. 2007; 51:722-729.

E. Sarcomatoid and Rhabdoid Features

Sarcomatoid carcinoma is not a specific morphologic or genetic subtype of renal cell carcinoma but is considered a pattern of dedifferentiation of different renal carcinoma subtypes.^{1,2,3,4} Sarcomatoid change in a renal cell carcinoma is associated with an adverse outcome.^{1,4} Sarcomatoid morphology may be found in any histologic subtypes of renal cell carcinomas, including clear cell, papillary, chromophobe, collecting duct, and other rare and unclassified subtypes.^{1,2,3,4} When the background carcinoma subtype is recognized, it should be specified under histologic type (see Note B). Pure sarcomatoid carcinoma or sarcomatoid carcinoma associated with epithelial elements that do not conform to usual renal carcinoma cell types should be considered as renal cell carcinoma, NOS. Sarcomatoid morphology is also incorporated into the WHO/ISUP grading system as grade 4.

Rhabdoid features, like sarcomatoid features, are a characteristic of high-grade disease. Rhabdoid cells have abundant eosinophilic cytoplasm with an eccentric nucleus and often a prominent nucleolus. These cells mimic rhabdomyoblasts but do not show true skeletal muscle differentiation.^{4,5,6,7} Rhabdoid features are associated with adverse outcomes, and about 25% concurrently show sarcomatoid features.¹ Rhabdoid morphology is also by definition WHO/ISUP grade 4.⁴

There is some indication that the percentage of sarcomatoid component in a renal cell carcinoma has prognostic importance.^{2,4,8} A recent study has also shown that the extent of WHO/ISUP grade 4 component in a tumor influences outcome for clear cell RCC irrespective of type of grade 4 histology (sarcomatoid, rhabdoid or extreme atypia). This study demonstrated that although cancers with overall grade 4 morphology had a significantly worse outcome than grade 3 cancers, those with <10% grade 4 component were not associated with a significant survival difference from grade 3 cancers. In addition, there was a significant difference in survival between tumors with <10% versus >50% grade 4 areas.⁹

References

1. WHO Classification of Tumours Editorial Board. *Urinary and male genital tumours*. Lyon (France): International Agency for Research on Cancer; 2022. (WHO classification of tumours series, 5th ed.; vol. 8). <https://publications.iarc.fr/610>.
2. de Peralta-Venturina M, Moch H, Amin M, et al. Sarcomatoid differentiation in renal cell carcinoma: a study of 101 cases. *Am J Surg Pathol*. 2001; 25:275-278.
3. Cheville JC, Lohse CM, Zincke H, et al. Sarcomatoid renal cell carcinoma: an examination of underlying histologic subtype and an analysis of associations with patient outcome. *Am J Surg Pathol*. 2004; 28:435-441.
4. Delahunt B, Cheville JC, Martignoni G, et al. The International Society of Urological Pathology (ISUP) grading system for renal cell carcinoma and other prognostic parameters. *Am J Surg Pathol*. 2013; 37:1490-1504.
5. Kuroiwa K, Kinoshita Y, Shiratsuchi H, et al. Renal cell carcinoma with rhabdoid features: an aggressive neoplasm. *Histopathology*. 2002; 41:538-548.
6. Gokden N, Nappi O, Swanson PE, et al. Renal cell carcinoma with rhabdoid features. *Am J Surg Pathol*. 2000; 24:1329-1338.
7. Leroy X, Zini L, Buob D, et al. Renal cell carcinoma with rhabdoid features. *Arch Pathol Lab Med*. 2007; 131:102-106.
8. Zhang BY, Thompson RH, Lohse CM, Leibovich BC, Boorjian SA, Cheville JC, Costello BA. A novel prognostic model for patients with sarcomatoid renal cell carcinoma. *BJU Int*. 2015 Mar;115(3):405-11.
9. Dagher J, Delahunt B, Rioux-Leclercq N, Egevad L, Varma M, Samarasinghe H. Percentage grade 4 tumour predicts outcome for clear cell renal cell carcinoma. *Pathology*. 2019 Jun;51(4):349-352.

F. Necrosis

Tumor necrosis is an important prognostic factor in renal cell carcinoma.^{1,2,3} The prognostic significance of necrosis independent of tumor stage has been identified in clear cell and chromophobe renal cell carcinoma.^{2,4} In addition, tumor-associated necrosis has been shown to be an important prognostic factor for clear cell RCC, independently of WHO/ISUP grade. The prognostic significance of necrosis in papillary renal cell carcinoma is controversial. Large papillary carcinomas commonly display cystic necrosis and yet do not exhibit extra renal spread.⁵ Tumor necrosis cannot be assessed as a prognostic factor when patients have undergone presurgical arterial embolization, as tumor-type necrosis cannot be definitively distinguished from treatment effect.

At present, the prognostic significance of the extent of necrosis is unclear; however, it is recommended that this be recorded as a percentage incorporating the best estimate of extent, based upon macroscopic

and confirmatory microscopic evaluation.³ Extensive necrosis in the setting of a low-grade RCC appears to be associated with a more favorable prognosis.⁶

References

1. Delahunt B, Cheville JC, Martignoni G, et al. The International Society of Urological Pathology (ISUP) grading system for renal cell carcinoma and other prognostic parameters. *Am J Surg Pathol*. 2013; 37:1490-1504.
2. Cheville JC, Lohse CM, Zincke H, Weaver AL, Blute ML. Comparison of outcome and prognostic features among histologic subtypes of renal cell carcinoma. *Am J Surg Pathol*. 2003; 27:612-624.
3. Klatte T, Said JW, de Martino M, et al. Presence of tumour necrosis is not a significant predictor of survival in clear cell renal cell carcinoma: higher prognostic accuracy of extent based rather than presence/absence classification. *J Urol*. 2009; 181:1558-1564.
4. Dagher J, Delahunt B, Rioux-Leclercq N, Egevad L, Coughlin G, Dungalison N, Gianduzzo T, Kua B, Malone G, Martin B, Preston J, Pokorny M, Wood S, Samaratunga H. Assessment of tumour-associated necrosis provides prognostic information additional to World Health Organization/International Society of Urological Pathology grading for clear cell renal cell carcinoma. *Histopathology*. 2019 Jan;74(2):284-290.
5. Peckova K, Martinek P, Pivovarcikova K, Vanecek T, Alaghehbandan R, Prochazkova K, Montiel DP, Hora M, Skenderi F, Ulamec M, Rotterova P, Daum O, Ferda J, Davidson W, Ondic O, Dubova M, Michal M, Hes O. Cystic and necrotic papillary renal cell carcinoma: prognosis, morphology, immunohistochemical, and molecular-genetic profile of 10 cases. *Ann Diagn Pathol*. 2017 Feb; 26:23-30.
6. Collins J, Epstein JI. Prognostic significance of extensive necrosis in renal cell carcinoma. *Hum Pathol*. 2017 Aug; 66:108-114.

G. Margins

Partial Nephrectomy: The renal parenchymal margin should be inked and histologically assessed; preferably utilizing perpendicular sections.¹ Sections demonstrating the relationship of the tumor to perinephric adipose tissue (when present), renal capsule, and renal sinus soft tissue margin should be evaluated. A positive surgical margin is defined as extension of tumor to the inked surface of the resected specimen. Any benign tissue overlying the tumor, regardless of thickness, renders the margin negative.^{2,3,4}

Total/Radical Nephrectomy: The ureteric, vascular (renal artery and vein), and soft tissue (renal hilar, Gerota's fascia when appropriate) margins should be evaluated.¹ The renal vein margin is more commonly a challenge than the ureter or artery margin, as tumors often extend with finger-like projections into the main renal vein or vena cava. If tumor is present in the vascular lumen but not adherent to, or invading, the wall at the margin by microscopic evaluation, this is considered a negative margin since the tumor may be manipulated backward within the vein before ligation and not transected. Involvement of the Gerota's fascia/soft tissue margin is very rare in total/radical nephrectomy, except with the highest stage tumors. In this setting, it is usually apparent that the adipose tissue is adherent to the tumor.

References

1. Trpkov K, Grignon DJ, Bonsib SN, et al. Handling and staging of renal cell carcinoma: the International Society of Urological Pathology (ISUP) Consensus conference recommendations. *Am J Surg Pathol*. 2013; 37:1505-1517.

2. Lee J, Kim J, Kim JC, et al. Evaluation of the Surgical Margin Threshold for Avoiding Recurrence after Partial Nephrectomy in Patients with Renal Cell Carcinoma. *Yonsei Med J.* 2022 Feb;63(2):173-178.
3. Castilla EA, Liou LS, Abrahams NA, et al. Prognostic importance of resection margin width after nephron-sparing surgery for renal cell carcinoma. *Urology.* 2002 Dec;60(6):993-7.
4. Timsit MO, Bazin JP, Thiounn N, et al. Prospective study of safety margins in partial nephrectomy: intraoperative assessment and contribution of frozen section analysis. *Urology.* 2006 May;67(5):923-6.

H. pTNM Classification

The TNM staging system of the American Joint Committee on Cancer (AJCC) for renal cell carcinoma is recommended.¹

By AJCC convention, the designation “T” refers to a primary tumor that has not been previously treated. The symbol “p” refers to the pathologic classification of the TNM, as opposed to the clinical classification, and is based on gross and microscopic examination. pT entails a resection of the primary tumor or biopsy adequate to evaluate the highest pT category, pN entails removal of nodes adequate to validate lymph node metastasis, and pM implies microscopic examination of distant lesions. Clinical classification (cTNM) is usually carried out by the referring physician before treatment during initial evaluation of the patient or when pathologic classification is not possible.

Pathologic staging is usually performed after surgical resection of the primary tumor. Pathologic staging depends on pathologic documentation of the anatomic extent of disease, whether or not the primary tumor has been completely removed. If a biopsied tumor is not resected for any reason (e.g., when technically unfeasible) and if the highest T and N categories or the M1 category of the tumor can be confirmed microscopically, the criteria for pathologic classification and staging have been satisfied without total removal of the primary cancer.

TNM Descriptors

For identification of special cases of TNM or pTNM classifications, the “m” suffix and “y”, “r”, and “a” prefixes are used. Although they do not affect the stage grouping, they indicate cases needing separate analysis.

The “m” suffix indicates the presence of multiple primary tumors in a single site and is recorded in parentheses: pT(m)NM.

The “y” prefix indicates those cases in which classification is performed during or following initial multimodality therapy (i.e., neoadjuvant chemotherapy, radiation therapy, or both chemotherapy and radiation therapy). The cTNM or pTNM category is identified by a “y” prefix. The ycTNM or ypTNM categorizes the extent of tumor actually present at the time of that examination. The “y” categorization is not an estimate of tumor prior to multimodality therapy (i.e., before initiation of neoadjuvant therapy).

The “r” prefix indicates a recurrent tumor when staged after a documented disease-free interval and is identified by the “r” prefix: rTNM.

The “a” prefix designates the stage determined at autopsy: aTNM.

Additional Descriptors

For the surgeon, the R classification may be useful to indicate the known or assumed status of the completeness of a surgical excision. For the pathologist, the R classification is relevant to the status of the margins of a surgical resection specimen. That is, tumor involving the resection margin on pathologic examination may be assumed to correspond to residual tumor in the patient and may be classified as macroscopic or microscopic according to the findings at the specimen margin(s).

Lymphatic and/or Vascular Invasion

By AJCC convention, vessel invasion (lymphatic or venous) does not affect the T category indicating local extent of tumor unless specifically included in the definition of a T category. In all other cases, lymphatic and venous invasion by tumor are coded separately.

References

1. Amin MB, Edge SB, Greene FL, et al., eds. *AJCC Cancer Staging Manual*. 8th ed. New York, NY: Springer; 2017.

I. Additional Findings in Kidney

It is important to recognize that medical kidney diseases may be present in nonneoplastic renal tissue in nephrectomy and nephroureterectomy specimens.^{1,2} Arterionephrosclerosis (or hypertensive nephropathy) and diabetic nephropathy are seen in approximately 30% and 20% of patients, respectively. Other medical renal diseases that have been identified include thrombotic microangiopathy, focal segmental glomerulosclerosis, membranous glomerulonephritis, amyloidosis, and IgA nephropathy.

The findings of greater than 20% global glomerulosclerosis or advanced diffuse diabetic glomerulosclerosis are predictive of significant decline in renal function 6 months after radical nephrectomy.³ Evaluation for medical renal disease should be performed in each case; additional special stains, such as PAS and/or Jones methenamine silver stains should be applied if necessary. Consultation with a nephropathologist should be pursued as needed.

However, no studies have specifically measured peritumoral-related changes in the renal cortex. Some tumors have no peritumoral changes (oncocytoma is the best example), whereas some large tumors often have a large zone of peritumoral changes compared with smaller tumors. The pseudocapsule may contain sclerotic glomeruli, tubular atrophy and show fibrointimal thickening of arteries, followed by a zone of several millimeters of acute tubular injury, none of which is representative of the cortex elsewhere.⁴ A judgement whether the amount of nonneoplastic renal parenchyma is sufficient for evaluation of medical kidney diseases should be made on a case by case basis. Two studies have used 1 mm to 5 mm as the cut-off for insufficient renal parenchyma.^{5,6} Five millimeters of nonneoplastic renal parenchyma is a reasonable recommendation.

References

1. Henriksen KJ, Meehan SM, Chang A. Non-neoplastic renal diseases are often unrecognized in adult tumor nephrectomy specimens: a review of 246 cases. *Am J Surg Pathol*. 2007; 31:1703-1708.

2. Bijol V, Mendez GP, Hurwitz S, Rennke HG, Nose V. Evaluation of the non-neoplastic pathology in tumor nephrectomy specimens: predicting the risk of progressive failure. *Am J Surg Pathol.* 2006; 30:575-584.
3. Thompson RH, Cheville JC, Lohse CM, et al. Reclassification of patients with pT3 and pT4 renal cell carcinoma improves prognostic accuracy. *Cancer.* 2005; 104:53-60.
4. Bonsib SM, Pei Y. The non-neoplastic kidney in tumor nephrectomy specimens: what can it show and what is important? *Adv Anat Pathol.* 2010;17(4):235-250.
5. Garcia-Roig M, Gorin MA, Parra-Herran C, et al. Pathologic evaluation of non-neoplastic renal parenchyma in partial nephrectomy specimens. *World J Urol.* 2013;8(4):835-839.
6. Henriksen KJ, Meehan SM, Chang A. Nonneoplastic kidney diseases in adult tumor nephrectomy and nephroureterectomy specimens: common, harmful, yet underappreciated. *Arch Pathol Lab Med.* 2009;133(7):1012-1025.