



## Protocol for the Examination of Resection Specimens From Patients With Primary Non-Small Cell Carcinoma, Small Cell Carcinoma, or Carcinoid Tumor of the Lung

**Version:** 4.2.0.0

**Protocol Posting Date:** June 2021

**CAP Laboratory Accreditation Program Protocol Required Use Date:** March 2022

The changes included in this current protocol version affect accreditation requirements. The new deadline for implementing this protocol version is reflected in the above accreditation date.

**For accreditation purposes, this protocol should be used for the following procedures AND tumor types:**

Procedure	Description
Resection	Includes pneumonectomy, lobectomy, segmentectomy, and wedge resection
Tumor Type	Description
Carcinoma	Includes non-small cell carcinoma, small cell carcinoma, and carcinoid tumor of the lung

**This protocol is NOT required for accreditation purposes for the following:**

Procedure
Biopsy
Primary resection specimen with no residual cancer (e.g. following neoadjuvant therapy)
Cytologic specimens

**The following tumor types should NOT be reported using this protocol:**

Tumor Type
Mesothelioma (consider the Pleural Mesothelioma protocol)
Lymphoma (consider the Hodgkin or non-Hodgkin Lymphoma protocol)
Sarcoma (consider the Soft Tissue protocol)

### Authors

Frank Schneider, MD\*; Mary Beth Beasley, MD; Sanja Dacic, MD, PhD; Kelly J. Butnor, MD.

With guidance from the CAP Cancer and CAP Pathology Electronic Reporting Committees.

\* Denotes primary author.

### **Accreditation Requirements**

This protocol can be utilized for a variety of procedures and tumor types for clinical care purposes. For accreditation purposes, only the definitive primary cancer resection specimen is required to have the core and conditional data elements reported in a synoptic format.

- Core data elements are required in reports to adequately describe appropriate malignancies. For accreditation purposes, essential data elements must be reported in all instances, even if the response is “not applicable” or “cannot be determined.”
- Conditional data elements are only required to be reported if applicable as delineated in the protocol. For instance, the total number of lymph nodes examined must be reported, but only if nodes are present in the specimen.
- Optional data elements are identified with “+” and although not required for CAP accreditation purposes, may be considered for reporting as determined by local practice standards.

The use of this protocol is not required for recurrent tumors or for metastatic tumors that are resected at a different time than the primary tumor. Use of this protocol is also not required for pathology reviews performed at a second institution (ie, secondary consultation, second opinion, or review of outside case at second institution).

### **Synoptic Reporting**

All core and conditionally required data elements outlined on the surgical case summary from this cancer protocol must be displayed in synoptic report format. Synoptic format is defined as:

- Data element: followed by its answer (response), outline format without the paired Data element: Response format is NOT considered synoptic.
- The data element should be represented in the report as it is listed in the case summary. The response for any data element may be modified from those listed in the case summary, including “Cannot be determined” if appropriate.
- Each diagnostic parameter pair (Data element: Response) is listed on a separate line or in a tabular format to achieve visual separation. The following exceptions are allowed to be listed on one line:
  - Anatomic site or specimen, laterality, and procedure
  - Pathologic Stage Classification (pTNM) elements
  - Negative margins, as long as all negative margins are specifically enumerated where applicable
- The synoptic portion of the report can appear in the diagnosis section of the pathology report, at the end of the report or in a separate section, but all Data element: Responses must be listed together in one location

Organizations and pathologists may choose to list the required elements in any order, use additional methods in order to enhance or achieve visual separation, or add optional items within the synoptic report. The report may have required elements in a summary format elsewhere in the report IN ADDITION TO but not as replacement for the synoptic report ie, all required elements must be in the synoptic portion of the report in the format defined above.

### **Summary of Changes**

#### **v 4.2.0.0**

- General Reformatting
- New WHO 5th Edition Histological Updates
- Revised Margins Section
- Revised Lymph Nodes Section
- Added Distant Metastasis Section
- Removed pNX Staging Classification

## Reporting Template

---

**Protocol Posting Date: June 2021**

**Select a single response unless otherwise indicated.**

### **CASE SUMMARY: (LUNG)**

**Standard(s):** AJCC-UICC 8

### **SPECIMEN**

**Synchronous Tumors (required if morphologically distinct unrelated multiple primary tumors are present)**

Not applicable

*# Morphologically distinct tumors that are considered to represent separate primary lung cancers should have separate synoptic reports*

Present#

**Total Number of Primary Tumors:** \_\_\_\_\_

**Specimen ID(s):** \_\_\_\_\_

Cannot be determined

### **Procedure (select all that apply)**

Wedge resection

Segmentectomy

Lobectomy

Completion lobectomy

Sleeve lobectomy

Bilobectomy

Pneumonectomy

Major airway resection (specify): \_\_\_\_\_

Other (specify): \_\_\_\_\_

Not specified

### **Specimen Laterality**

Right

Left

Not specified

### **TUMOR**

#### **Tumor Focality (Note [D](#))**

Single focus

Separate tumor nodules (metastases) in same lobe (pT3)

**+Number of Intrapulmonary Metastases:** \_\_\_\_\_

Separate tumor nodules (metastases) in different ipsilateral lobe (pT4)

**+Number of Intrapulmonary Metastases:** \_\_\_\_\_

Separate tumor nodules (metastases) in a contralateral lobe (pM1a)

**+Number of Distant Metastases:** \_\_\_\_\_

\_\_\_ Multifocal tumor nodules of similar histology type not considered intrapulmonary metastases or too numerous for separate synoptic reports (e.g. multiple ground-glass/lepidic nodules or carcinoid tumors) (use m suffix)

**+Number of Tumor Nodules**

- \_\_\_ Specify number: \_\_\_\_\_
- \_\_\_ Other (specify): \_\_\_\_\_
- \_\_\_ Cannot be determined: \_\_\_\_\_
- \_\_\_ Pneumonic-type adenocarcinoma
- \_\_\_ Cannot be determined

**Tumor Site (select all that apply)**

- \_\_\_ Upper lobe of lung: \_\_\_\_\_
- \_\_\_ Middle lobe of lung: \_\_\_\_\_
- \_\_\_ Lower lobe of lung: \_\_\_\_\_
- \_\_\_ Bronchus, main: \_\_\_\_\_
- \_\_\_ Bronchus intermedius: \_\_\_\_\_
- \_\_\_ Bronchus, lobar (specify): \_\_\_\_\_
- \_\_\_ Other (specify): \_\_\_\_\_
- \_\_\_ Not specified

**Tumor Size (Note C)**

**Total Tumor Size (size of entire tumor)#**

*# The size of the entire tumor (total tumor size) applies to all tumors and includes the invasive component and the nonmucinous lepidic component of adenocarcinomas.*

- \_\_\_ Greatest dimension in Centimeters (cm): \_\_\_\_\_ cm

**+Additional Dimension in Centimeters (cm): \_\_\_ x \_\_\_ cm**

- \_\_\_ Cannot be determined: \_\_\_\_\_

**Size of Invasive Component## (required only if invasive nonmucinous adenocarcinomas with lepidic component is present)**

*## The size of the invasive component applies only to invasive nonmucinous adenocarcinomas with lepidic component. For all tumor types other than invasive nonmucinous adenocarcinoma with lepidic component, invasive tumor size equals total tumor size.*

- \_\_\_ Not applicable
- \_\_\_ Greatest dimension in Centimeters (cm): \_\_\_\_\_ cm

**+Additional Dimension in Centimeters (cm): \_\_\_ x \_\_\_ cm**

**+Percentage of Total Tumor Size (above)**

- \_\_\_ Specify percentage: \_\_\_\_\_ %
- \_\_\_ Other (specify): \_\_\_\_\_
- \_\_\_ Cannot be determined
- \_\_\_ Cannot be determined: \_\_\_\_\_

**Histologic Type (Note A)**

- \_\_\_ Adenocarcinoma in situ (AIS), nonmucinous
- \_\_\_ Adenocarcinoma in situ (AIS), mucinous
- \_\_\_ Minimally invasive adenocarcinoma, nonmucinous
- \_\_\_ Minimally invasive adenocarcinoma, mucinous
- \_\_\_ Invasive lepidic adenocarcinoma
- \_\_\_ Invasive acinar adenocarcinoma
- \_\_\_ Invasive papillary adenocarcinoma
- \_\_\_ Invasive micropapillary adenocarcinoma

Approved

- Invasive solid adenocarcinoma
- Invasive mucinous adenocarcinoma
- Mixed invasive mucinous and non-mucinous adenocarcinoma
- Colloid adenocarcinoma
- Fetal adenocarcinoma
- Enteric-type adenocarcinoma
- Squamous cell carcinoma in situ (SCIS)
- Invasive squamous cell carcinoma, keratinizing
- Invasive squamous cell carcinoma, non-keratinizing
- Invasive squamous cell carcinoma, basaloid
- Lymphoepithelial carcinoma
- Large cell carcinoma
- Adenosquamous carcinoma
- Pleomorphic carcinoma

**Histologic Component(s) Present (may include percentages) (select all that apply)**

- Spindle cell carcinoma: \_\_\_\_\_ %
- Giant cell carcinoma: \_\_\_\_\_ %
- Adenocarcinoma: \_\_\_\_\_ %
- Squamous cell carcinoma: \_\_\_\_\_ %
- Large cell carcinoma: \_\_\_\_\_ %
- Other (specify): \_\_\_\_\_
- Pulmonary blastoma
- Carcinosarcoma
- NUT carcinoma
- Thoracic SMARCA4-deficient undifferentiated tumor
- Adenoid cystic carcinoma
- Epithelial-myoeplithelial carcinoma
- Mucoepidermoid carcinoma
- Hyalinizing clear cell carcinoma
- Myoepithelial carcinoma
- Typical carcinoid / Neuroendocrine tumor, grade 1
- Atypical carcinoid / Neuroendocrine tumor, grade 2
- Carcinoid tumor, NOS / Neuroendocrine tumor, NOS
- Small cell carcinoma
- Combined small cell carcinoma (small cell carcinoma and non-small cell component) (specify type of non-small cell component): \_\_\_\_\_
- Large cell neuroendocrine carcinoma
- Combined large cell neuroendocrine carcinoma (LCNEC and other non-small cell component) (specify other type of non-small cell component): \_\_\_\_\_
- Carcinoma, type cannot be determined: \_\_\_\_\_
- Non-small cell carcinoma, subtype cannot be determined: \_\_\_\_\_
- Other histologic type not listed (specify): \_\_\_\_\_

**Histologic Patterns Present (may include percentages in 5-10% increments totaling 100%)# (select all that apply)**

# Applicable for invasive nonmucinous adenocarcinomas

- Not applicable
- Acinar: \_\_\_\_\_ %
- Papillary: \_\_\_\_\_ %
- Lepidic: \_\_\_\_\_ %

CAP  
Approved

Lung\_4.2.0.0.REL\_CAPCP

\_\_\_ Solid: \_\_\_\_\_ %  
\_\_\_ Micropapillary: \_\_\_\_\_ %  
\_\_\_ Complex glands (cribriform and fused glands): \_\_\_\_\_ %  
\_\_\_ Other (specify): \_\_\_\_\_  
**+Histologic Type Comment:** \_\_\_\_\_

**+Histologic Grade (Note [B](#))**

\_\_\_ G1, well differentiated  
\_\_\_ G2, moderately differentiated  
\_\_\_ G3, poorly differentiated  
\_\_\_ G4, undifferentiated  
\_\_\_ Other (specify): \_\_\_\_\_  
\_\_\_ GX, cannot be assessed: \_\_\_\_\_  
\_\_\_ Not applicable

**+Spread Through Air Spaces (STAS) (Note [A](#))**

\_\_\_ Not identified  
\_\_\_ Present

**Visceral Pleura Invasion (Note [E](#))**

\_\_\_ Not identified  
\_\_\_ Present  
\_\_\_ Cannot be determined: \_\_\_\_\_

**Direct Invasion of Adjacent Structures (Note [F](#))**

\_\_\_ Not applicable (no adjacent structures present)  
\_\_\_ Not identified  
\_\_\_ Present

**Involved Adjacent Structures (select all that apply)**

\_\_\_ Main bronchus  
\_\_\_ Hilar soft tissues  
\_\_\_ Carina  
\_\_\_ Parietal pleura  
\_\_\_ Chest wall (specify involved structure(s), if possible): \_\_\_\_\_  
\_\_\_ Phrenic nerve  
\_\_\_ Parietal pericardium  
\_\_\_ Diaphragm  
\_\_\_ Mediastinum (specify involved structure(s), if possible): \_\_\_\_\_  
\_\_\_ Heart  
\_\_\_ Great vessels  
\_\_\_ Trachea  
\_\_\_ Recurrent laryngeal nerve  
\_\_\_ Esophagus  
\_\_\_ Vertebral body  
\_\_\_ Other (specify): \_\_\_\_\_  
\_\_\_ Cannot be determined (explain): \_\_\_\_\_

**Treatment Effect (Note [G](#))**

\_\_\_ No known presurgical therapy

Not identified

Present

**Percentage of Residual Viable Tumor**

Specify percentage: \_\_\_\_\_ %

Other (specify): \_\_\_\_\_

Cannot be determined: \_\_\_\_\_

**+Percentage of Necrosis**

Specify percentage: \_\_\_\_\_ %

Other (specify): \_\_\_\_\_

Cannot be determined: \_\_\_\_\_

**+Percentage of Stroma (includes fibrosis and inflammation)**

Specify percentage: \_\_\_\_\_ %

Other (specify): \_\_\_\_\_

Cannot be determined: \_\_\_\_\_

Cannot be determined: \_\_\_\_\_

**Lymphovascular Invasion (select all that apply)**

Not identified

Present (not otherwise specified)

Lymphatic invasion present

Arterial invasion present

Venous invasion present

Cannot be determined: \_\_\_\_\_

**+Tumor Comment:** \_\_\_\_\_

**MARGINS (Note !)**

**Margin Status for Invasive Carcinoma**

All margins negative for invasive carcinoma

**Closest Margin(s) to Invasive Carcinoma (select all that apply)**

Bronchial: \_\_\_\_\_

Vascular: \_\_\_\_\_

Parenchymal: \_\_\_\_\_

Other attached tissue margin(s) (specify): \_\_\_\_\_

Cannot be determined (explain): \_\_\_\_\_

**+Distance from Invasive Carcinoma to Closest Margin**

*Specify in Centimeters (cm).*

Exact distance: \_\_\_\_\_ cm

Greater than: \_\_\_\_\_ cm

At least: \_\_\_\_\_ cm

Less than: \_\_\_\_\_ cm

Other (specify): \_\_\_\_\_

Cannot be determined: \_\_\_\_\_

Not applicable

Invasive carcinoma present at margin

**Margin(s) Involved by Invasive Carcinoma (select all that apply)**

Bronchial: \_\_\_\_\_

Vascular: \_\_\_\_\_

- Parenchymal: \_\_\_\_\_
- Other attached tissue margin(s) (specify): \_\_\_\_\_
- Cannot be determined (explain): \_\_\_\_\_
- Other (specify): \_\_\_\_\_
- Cannot be determined (explain): \_\_\_\_\_
- Not applicable

**Margin Status for Non-Invasive Tumor (select all that apply)**

- All margins negative for non-invasive tumor: \_\_\_\_\_
- Carcinoma in situ present at bronchial margin: \_\_\_\_\_
- Carcinoma in situ present at parenchymal margin: \_\_\_\_\_
- Lepidic component of invasive carcinoma present at parenchymal margin: \_\_\_\_\_
- Other (specify): \_\_\_\_\_
- Cannot be determined (explain): \_\_\_\_\_
- Not applicable

**+Margin Comment:** \_\_\_\_\_

**REGIONAL LYMPH NODES**

**Lymph Node(s) from Prior Procedures**

- No known prior lymph node sampling performed
- Not included
- Included

**Prior Lymph Node Procedure(s) Included (describe and specify case ID):** \_\_\_\_\_

**Regional Lymph Node Status**

- Not applicable (no regional lymph nodes submitted or found)
- Regional lymph nodes present
  - All regional lymph nodes negative for tumor
  - Tumor present in regional lymph node(s)

**Number of Lymph Nodes with Tumor**

- Exact number (specify): \_\_\_\_\_
- At least (specify): \_\_\_\_\_
- Other (specify): \_\_\_\_\_
- Cannot be determined (explain): \_\_\_\_\_

**Nodal Site(s) with Tumor (select all that apply)**

*Right Nodal Stations Involved*

- 1R: Low cervical, supraclavicular, scalene and sternal notch
- 2R: Upper paratracheal
- 4R: Lower paratracheal
- 8R: Para-esophageal (below carina)
- 9R: Pulmonary ligament
- 10R: Hilar
- 11R: Interlobar
- 12R: Lobar
- 13R: Segmental
- 14R: Subsegmental
- Other right nodes (specify): \_\_\_\_\_



*Central Nodal Stations Involved*

- 3a: Pre-vascular
- 3p: Retrotracheal
- 7: Subcarinal
- Other central nodes (specify): \_\_\_\_\_

*Left Nodal Stations Involved*

- 1L: Low cervical, supraclavicular, scalene and sternal notch
- 2L: Upper paratracheal
- 4L: Lower paratracheal
- 5: Subaortic / aortopulmonary (AP) / AP window
- 6: Para-aortic (ascending aorta or phrenic)
- 8L: Para-esophageal
- 9L: Pulmonary ligament
- 10L: Hilar
- 11L: Interlobar
- 12L: Lobar
- 13L: Segmental
- 14L: Subsegmental
- Other left nodes (specify): \_\_\_\_\_
- Cannot be determined: \_\_\_\_\_

**+Extranodal Extension (Note J)**

- Not identified
- Present
- Cannot be determined: \_\_\_\_\_
- Other (specify): \_\_\_\_\_
- Cannot be determined (explain): \_\_\_\_\_

**Number of Lymph Nodes Examined**

- Exact number (specify): \_\_\_\_\_
- At least (specify): \_\_\_\_\_
- Other (specify): \_\_\_\_\_
- Cannot be determined (explain): \_\_\_\_\_

**Nodal Site(s) Examined (select all that apply)**

*Right Nodal Stations Examined*

- 1R: Low cervical, supraclavicular, scalene and sternal notch
- 2R: Upper paratracheal
- 4R: Lower paratracheal
- 8R: Para-esophageal (below carina)
- 9R: Pulmonary ligament
- 10R: Hilar
- 11R: Interlobar
- 12R: Lobar
- 13R: Segmental
- 14R: Subsegmental
- Other right nodes (specify): \_\_\_\_\_

*Central Nodal Stations Examined*

- 3a: Pre-vascular
- 3p: Retrotracheal
- 7: Subcarinal
- Other central nodes (specify): \_\_\_\_\_

*Left Nodal Stations Examined*

- 1L: Low cervical, supraclavicular, scalene and sternal notch
- 2L: Upper paratracheal
- 4L: Lower paratracheal
- 5: Subaortic / aortopulmonary (AP) / AP window
- 6: Para-aortic (ascending aorta or phrenic)
- 8L: Para-esophageal
- 9L: Pulmonary ligament
- 10L: Hilar
- 11L: Interlobar
- 12L: Lobar
- 13L: Segmental
- 14L: Subsegmental
- Other left nodes (specify): \_\_\_\_\_
- Cannot be determined: \_\_\_\_\_

**+Regional Lymph Node Comment:** \_\_\_\_\_

#### **DISTANT METASTASIS**

##### **Distant Site(s) Involved, if applicable (select all that apply)**

- Not applicable
- Separate tumor nodule(s) in contralateral lobe: \_\_\_\_\_
- Pleural nodules: \_\_\_\_\_
- Pericardial nodules: \_\_\_\_\_
- Malignant pleural effusion: \_\_\_\_\_
- Malignant pericardial effusion: \_\_\_\_\_
- Single extrathoracic metastasis in one organ (including a single nonregional lymph node):  
\_\_\_\_\_
- Multiple extrathoracic metastases in a single organ: \_\_\_\_\_
- Multiple extrathoracic metastasis in multiple organs: \_\_\_\_\_
- Other (specify): \_\_\_\_\_
- Cannot be determined: \_\_\_\_\_

##### **PATHOLOGIC STAGE CLASSIFICATION (pTNM, AJCC 8th Edition) (Note [J](#))**

*The suffix m (or a specific number) should only be used in the setting of multifocal ground-glass / lepidic nodules that histologically present as adenocarcinomas with prominent lepidic component or multifocal tumors of same histologic type that are too numerous for individual separate synoptic report and that are not better classified as intrapulmonary metastases (e.g. numerous carcinoid tumors). Multiple primary lung cancers showing different histologic type or different morphology based on comprehensive histologic subtyping are better staged as independent tumors without m suffix.*

##### **TNM Descriptors (select all that apply)**

- Not applicable
- m (multiple primary tumors)
- r (recurrent)
- y (post-treatment)

##### **pT Category**

- pT not assigned (cannot be determined based on available pathological information)
- pT0: No evidence of primary tumor
- pTis (SCIS): Squamous cell carcinoma in situ (SCIS)

## Approved

\_\_\_ pTis (AIS): Adenocarcinoma in situ (AIS): adenocarcinoma with pure lepidic pattern, less than or equal to 3 cm in greatest dimension

*pT1: Tumor less than or equal to 3 cm in greatest dimension, surrounded by lung or visceral pleura, without bronchoscopic evidence of invasion more proximal than the lobar bronchus (i.e., not in the main bronchus)*

\_\_\_ pT1mi: Minimally invasive adenocarcinoma: adenocarcinoma (less than or equal to 3 cm in greatest dimension) with a predominantly lepidic pattern and less than or equal to 5 mm invasion in greatest dimension

\_\_\_ pT1a: Tumor less than or equal to 1 cm in greatest dimension. A superficial, spreading tumor of any size whose invasive component is limited to the bronchial wall and may extend proximal to the main bronchus also is classified as T1a, but these tumors are uncommon

\_\_\_ pT1b: Tumor greater than 1 cm but less than or equal to 2 cm in greatest dimension

\_\_\_ pT1c: Tumor greater than 2 cm but less than or equal to 3 cm in greatest dimension

\_\_\_ pT1 (subgroup cannot be determined)

*pT2: Tumor greater than 3 cm but less than or equal to 5 cm or having any of the following features: Involves the main bronchus regardless of distance to the carina, but without involvement of the carina; OR Invades visceral pleura (PL1 or PL2); OR Associated with atelectasis or obstructive pneumonitis that extends to the hilar region, involving part or all of the lung*

*T2 tumors with these features are classified as T2a if less than or equal to 4 cm or if the size cannot be determined and T2b if greater than 4 cm but less than or equal to 5 cm.*

\_\_\_ pT2a: Tumor greater than 3 cm, but less than or equal to 4 cm in greatest dimension

\_\_\_ pT2b: Tumor greater than 4 cm, but less than or equal to 5 cm in greatest dimension

\_\_\_ pT2 (subgroup cannot be determined)

\_\_\_ pT3: Tumor greater than 5 cm but less than or equal to 7 cm in greatest dimension; or directly invading any of the following: parietal pleura (PL3), chest wall (including superior sulcus tumors), phrenic nerve, parietal pericardium; or separate tumor nodule(s) in the same lobe as the primary

\_\_\_ pT4: Tumor greater than 7 cm in greatest dimension; or tumor of any size invading one or more of the following: diaphragm, mediastinum, heart, great vessels, trachea, recurrent laryngeal nerve, esophagus, vertebral body or carina; or separate tumor nodule(s) in an ipsilateral lobe different from that of the primary

### **pN Category**

\_\_\_ pN not assigned (no nodes submitted or found)

\_\_\_ pN not assigned (cannot be determined based on available pathological information)

\_\_\_ pN0: No regional lymph node metastasis

\_\_\_ pN1: Metastasis in ipsilateral peribronchial and / or ipsilateral hilar lymph nodes, and intrapulmonary nodes including involvement by direct extension

\_\_\_ pN2: Metastasis in ipsilateral mediastinal and / or subcarinal lymph node(s)

\_\_\_ pN3: Metastasis in contralateral mediastinal, contralateral hilar, ipsilateral or contralateral scalene, or supraclavicular lymph node(s)

### **pM Category (required only if confirmed pathologically)**

\_\_\_ Not applicable - pM cannot be determined from the submitted specimen(s)

*# Most pleural (pericardial) effusions with lung cancer are a result of the tumor. In a few patients, however, multiple microscopic examinations of pleural (pericardial) fluid are negative for tumor, and the fluid is nonbloody and not an exudate. If these elements and clinical judgment dictate that the effusion is not related to the tumor, the effusion should be excluded as a staging descriptor.*

\_\_\_ pM1a: Separate tumor nodule(s) in contralateral lobe; tumor with pleural or pericardial nodules or malignant pleural (or pericardial) effusion#

\_\_\_ pM1b: Single extrathoracic metastasis in a single organ (including involvement of a single nonregional node)

\_\_\_ pM1c: Multiple extrathoracic metastases in single organ or in multiple organs

**ADDITIONAL FINDINGS**

**+Additional Findings (select all that apply)**

- None identified
- Atypical adenomatous hyperplasia
- Squamous dysplasia
- Metaplasia (specify type): \_\_\_\_\_
- Diffuse neuroendocrine hyperplasia
- Inflammation (specify type): \_\_\_\_\_
- Fibrosis (specify pattern if discernable): \_\_\_\_\_
- Emphysema
- Other (specify): \_\_\_\_\_

**SPECIAL STUDIES**

*For reporting cancer biomarker testing results, the CAP Lung Biomarker Template may be used. Pending biomarker studies should be listed in the Comments section of this report.*

**COMMENTS**

Comment(s): \_\_\_\_\_

## Explanatory Notes

---

### A. Histologic Type

For consistency in reporting, the histologic classification published by the World Health Organization (WHO) for tumors of the lung, including carcinoids, is recommended.<sup>1</sup> Although acceptable in small biopsies, a designation of non-small cell lung carcinoma, not otherwise specified (NSCLC, NOS), is not acceptable in resection specimens.

Lung carcinomas should be adequately sampled in order to ensure defining features are satisfactorily represented in the sections examined histologically and the presence or absence of invasion can be thoroughly assessed. The WHO defines invasion in adenocarcinoma as: (1) any histologic subtype other than a lepidic pattern (ie, acinar, papillary, micropapillary, and/or solid), (2) tumor cells infiltrating myofibroblastic stroma, (3) vascular or pleural invasion, or (4) spread through air spaces (STAS).<sup>1</sup>

STAS is a recently described concept which is defined as micropapillary clusters, solid nests or single cells of tumor extending beyond the edge of the tumor into the air spaces of the surrounding lung parenchyma. Initial studies have shown that the presence of STAS is associated with an increased incidence of recurrence in tumors that have undergone limited resection (eg, segmentectomy, wedge resection).<sup>1</sup> At the present time, STAS should not be incorporated into the measurement of tumor size.<sup>1</sup>

For cases in which a diagnosis of adenocarcinoma in situ (AIS) or minimally invasive adenocarcinoma (MIA) is being considered, the lesion must be entirely submitted for histopathologic examination. A diagnosis of MIA is applied to a lepidic-predominant tumor  $\leq 3$  cm in size with an invasive component measuring  $\leq 0.5$  cm provided it does not exhibit any of the following: (1) tumor invades lymphatics, blood vessels or pleura, (2) tumor necrosis is present, (3) STAS is present.<sup>1</sup> Tumors  $\leq 3$  cm with  $\leq 0.5$  cm of invasion exhibiting 1 or more of these exclusionary features are classified as lepidic-predominant adenocarcinoma. A diagnosis of AIS or MIA should only be made on solitary lesions  $\leq 3$  cm in diameter. Specimens showing only AIS are categorized as Tis (AIS). MIA is classified as T1mi.<sup>2</sup>

For the uncommon occurrence of a lepidic-predominant tumor  $>3.0$  cm with either no invasion or  $\leq 0.5$  cm of invasion, it is recommended that such tumors be classified as lepidic-predominant adenocarcinoma and categorized as pT1a, as there is insufficient data to conclude they have the same prognostic features as  $\leq 3.0$  cm tumors meeting criteria for AIS or MIA.<sup>2</sup>

Classification of adenocarcinomas by predominant histologic pattern can be useful for assessing pathologic grade and distinguishing separate independent tumors from intrapulmonary metastases. The WHO recommends classifying invasive nonmucinous adenocarcinomas according to the predominant subtype and specifying non-predominant subtypes semi-quantitatively in 5% increments.<sup>1</sup> In poorly differentiated cases, immunohistochemistry can greatly aid in classification. This is particularly useful in making a diagnosis of solid-type adenocarcinoma or nonkeratinizing squamous cell carcinoma.

### References

1. WHO Classification of Tumours Editorial Board. *Thoracic tumours*. Lyon (France): International Agency for Research on Cancer; 2021. (WHO classification of tumours series, 5th ed.; vol. 5). <https://publications.iarc.fr/595>
2. Amin MB, Edge SB, Greene FL, et al., eds. *AJCC Cancer Staging Manual*. 8th ed. New York, NY: Springer; 2017.

## B. Histopathologic Grade

The predominant histological pattern of nonmucinous adenocarcinomas is associated with prognosis with lepidic-predominant tumors having the best prognosis, acinar and papillary-predominant tumors having an intermediate prognosis, and solid-predominant and micropapillary-predominant tumors having the worst prognosis.<sup>1</sup> A recent study by the International Association for the Study of Lung Cancer (IASLC) Pathology Committee found that a combination of predominant and worst histological pattern improves prediction of patient outcome.<sup>1</sup> The following grading scheme was recommended for resected early-stage nonmucinous lung adenocarcinoma.

### IASLC Histopathologic Grading Scheme for Nonmucinous Lung Adenocarcinoma:<sup>1</sup>

- Grade 1 (G1): Well-differentiated (lepidic-predominant with no or < 20% high-grade pattern)
- Grade 2 (G2): Moderately differentiated (acinar or papillary-predominant with no or < 20% high-grade pattern)
- Grade 3 (G3): Poorly differentiated (any tumor with ≥ 20% high-grade pattern (i.e. solid, micropapillary, cribriform, or complex glandular pattern).

Note: A complex glandular pattern is defined by fused glands or single cells infiltrating in a desmoplastic stroma.

Neuroendocrine tumors continue to be classified based on their diagnostic criteria as low-grade (typical carcinoid/neuroendocrine tumor, grade 1), intermediate-grade (atypical carcinoid/neuroendocrine tumor, grade 2) and neuroendocrine carcinoma (large cell carcinoma and small cell carcinoma).<sup>2</sup>

Use of the above grading schemes is recommended for nonmucinous adenocarcinoma and neuroendocrine tumors. There is currently no established grading scheme for invasive mucinous adenocarcinoma or squamous cell carcinoma of the lung.<sup>2</sup>

For other tumors, the four-tiered grading scheme for lung cancer (shown below) has been put forth by the American Joint Committee on Cancer (AJCC) may be used.<sup>1,3</sup> However, since grading systems have not been established for all histologic types of lung cancer, its reproducibility and prognostic significance have not been rigorously tested, and therefore histopathologic grade remains designated as an optional reporting element.

### AJCC Histopathologic Grading Scheme:<sup>3</sup>

- Grade X (GX): Cannot be assessed
- Grade 1 (G1): Well differentiated
- Grade 2 (G2): Moderately differentiated
- Grade 3 (G3): Poorly differentiated
- Grade 4 (G4): Undifferentiated

## References

1. Moreira AL, Ocampo PSS, Xia Y, et al. A Grading System for Invasive Pulmonary Adenocarcinoma: A Proposal From the International Association for the Study of Lung Cancer Pathology Committee. *J Thorac Oncol.* 2020 Oct;15(10):1599-1610
2. WHO Classification of Tumours Editorial Board. Thoracic tumours. Lyon (France): International Agency for Research on Cancer; 2021. (WHO classification of tumours series, 5th ed.; vol. 5). <https://publications.iarc.fr/595>

3. Amin MB, Edge SB, Greene FL, et al., eds. *AJCC Cancer Staging Manual*. 8th ed. New York, NY: Springer; 2017

### C. Tumor Size

Based on data showing prognosis correlates with invasive size in nonmucinous adenocarcinomas with lepidic and invasive components, the AJCC has adopted a rule that for nonmucinous adenocarcinomas with a lepidic component, only the size of the invasive component is used to assign T category.<sup>1,2,3,4</sup> This rule aligns with the recommendation previously set forth by the Union for International Cancer Control (UICC) of using invasive size for T descriptor size.<sup>5</sup> This rule does not apply to other histologic types of lung cancer, including invasive mucinous lung adenocarcinoma.

The invasive component to be measured in nonmucinous adenocarcinomas with a lepidic component includes any histologic subtype other than a lepidic pattern (ie, acinar, papillary, micropapillary, and/or solid) and/or tumor cells infiltrating myofibroblastic stroma.<sup>6</sup> In tumors where the invasive component is not a single discrete measurable focus, estimating the percentage of the total tumor that is invasive and then multiplying by the total tumor size to estimate invasive tumor size is recommended.<sup>1</sup>

### References

1. Amin MB, Edge SB, Greene FL, et al., eds. *AJCC Cancer Staging Manual*. 8th ed. New York, NY: Springer; 2017.
2. Tsutani Y, Miyata Y, Nakayama H, et al. Prognostic significance of using solid versus whole tumor size on high-resolution computed tomography for predicting pathologic malignant grade tumors in clinical stage IA lung adenocarcinoma: a multicenter study. *J Thorac Cardiovasc Surg*. 2012;143(3):607-612.
3. Yoshizawa A, Motoi N, Riely GJ, et al. Impact of proposed IASLC/ATS/ERS classification of lung adenocarcinoma: prognostic subgroups and implications for further revision of staging based on analysis of 514 stage I cases. *Mod Pathol*. 2011;24(5):653-664.
4. Maeyashiki T, Suzuki K, Hattori A, et al. The size of consolidation on thin-section computed tomography is a better predictor of survival than the maximum tumour dimension in resectable lung cancer. *Eur J Cardiothorac Surg*. 2013;43(5):915-918.
5. Wittekind C, Greene FL, Henson DE, Hutter RVP, Sobin LH, eds. *TNM Supplement: A Commentary on Uniform Use*. 3rd ed. New York, NY: Wiley-Liss; 2001.
6. Travis WD, Asamura H, Bankier AA, et al. The IASLC lung cancer staging project: proposals for coding T categories for subsolid nodules and assessment of tumor size in part-solid tumors in the forthcoming eighth edition of the TNM classification of lung cancer. *J Thorac Onc*. 2016;11(8):1204-1223.

### D. Tumor Focality

When more than one tumor nodule is identified in resection specimens, it is important to attempt distinction of synchronous primary tumors from a tumor with intrapulmonary metastasis. These scenarios have different prognoses and are staged differently. Multiple tumor nodules of different histologic types (eg, one squamous cell carcinoma and one adenocarcinoma) are considered synchronous primaries and should be recorded as such in the pathology report with an individual TNM category assigned to each tumor.<sup>1</sup> In such cases, required reporting elements should be recorded for each primary tumor, and this is most easily achieved by issuing two synoptic reports (one for each of the cancers). For lung adenocarcinomas, comprehensive histologic assessment has been proposed for the distinction of synchronous primaries from separate tumor nodules (intrapulmonary metastasis).<sup>2</sup> Other pathologic criteria for distinguishing synchronous primary lung adenocarcinomas from separate tumor nodules (intrapulmonary metastasis) that are not based strictly on histologic assessment (eg, assessing similarity of breakpoints using comparative genomic hybridization) are detailed in the 8th edition of the AJCC staging manual.<sup>3</sup>

Multifocal lung adenocarcinoma with lepidic features is the designation applied to multiple discrete foci of lepidic-predominant adenocarcinoma (LPA), minimally invasive adenocarcinoma (MIA), or adenocarcinoma in situ (AIS) with or without other subtypes of adenocarcinoma as lesser components that manifest on computed tomography (CT) as multiple subsolid (either pure ground glass or part solid) nodules.<sup>4</sup> This designation applies whether a detailed histologic assessment shows a matching or different appearance among the tumor foci. Data suggest that in most cases, the multiple lesions represent synchronous primary tumors.<sup>5</sup> Assignment of T category in these cases is based on the highest T lesion, followed by the suffix “m”, indicating multiplicity, or the number of tumors in parentheses (eg, T1b(m) or T1b(2)) (Table 1).<sup>3</sup> It should be noted that foci of atypical adenomatous hyperplasia (AAH) are not counted for the purpose of TNM classification.

In some patients, adenocarcinoma manifests radiographically as diffuse consolidation, which has been designated as “pneumonic-type” lung adenocarcinoma. Such imaging findings typically correspond pathologically to invasive mucinous adenocarcinoma, but mixed mucinous and nonmucinous patterns may also be seen.<sup>5</sup> Invasive mucinous adenocarcinoma often exhibits lepidic-predominant growth, but robust sampling usually discloses invasive foci. Occasionally, invasive mucinous adenocarcinoma shows a heterogeneous mixture of other growth patterns. To qualify as pneumonic-type adenocarcinoma, tumor should be diffusely distributed throughout a region(s) of lung, as opposed to forming discrete single or multiple well-demarcated nodules or masses.<sup>5</sup>

The size of diffuse pneumonic-type adenocarcinomas, as well as miliary forms of adenocarcinoma, is often difficult to measure. When a single tumor area is present, it is categorized according to standard TNM criteria. Multiple tumor areas are categorized according to the extent of lobar involvement: T3 when limited to a single lobe, T4 when there is involvement of other ipsilateral lobe, and M1a is used to indicate the presence of contralateral lung involvement.<sup>3</sup>

In the setting of multiple lung cancers other than adenocarcinoma, pathologists may use the suffix m for multiple tumors of same histology as long as those tumors are not better considered intrapulmonary metastases. In this situation, AJCC suggests assigning the T category based on the size of the largest tumor nodule and using the m suffix to indicate an increased tumor burden.



**Table 1. Schematic Summary of Disease Patterns and TNM Classification of Patients With Lung Cancer With Multiple Pulmonary Sites of Involvement**

	<b>Second Primary Lung Cancer</b>	<b>Multifocal GG/L Nodules</b>	<b>Pneumonic-type Adenocarcinoma</b>	<b>Separate Tumor Nodule</b>
Imaging features	Two or more distinct masses with imaging characteristic of lung cancer (eg, spiculated)	Multiple ground-glass or part-solid nodules	Patchy areas of ground glass and consolidation	Typical lung cancer (eg, solid, spiculated) with separate solid nodule
Pathological features	Different histotype or different morphology based on comprehensive histologic assessment	Adenocarcinomas with prominent lepidic component (typically varying degrees of AIS, MIA, LPA)	Same histology throughout (most often invasive mucinous adenocarcinoma)	Distinct masses with the same morphologic features based on comprehensive histologic assessment
TNM classification	Separate cTNM and pTNM for each cancer	T based on highest T lesion, with (#/m) indicating multiplicity; single N and M	T based on size or T3 if in single lobe, T4 or M1a if in different ipsilateral or contralateral lobes; single N and M	Location of separate nodule relative to primary site determines whether T3, T4, or M1a; single N and M
Conceptual view	Unrelated tumors	Separate tumors, albeit with similarities	Single tumor, diffuse pulmonary involvement	Single tumor with intrapulmonary metastasis

AIS, adenocarcinoma in situ; GG/L, ground-glass/lepidic; LPA, lepidic-predominant adenocarcinoma; MIA, minimally invasive adenocarcinoma. From AJCC Cancer Staging Manual, 8th edition. Used with permission.

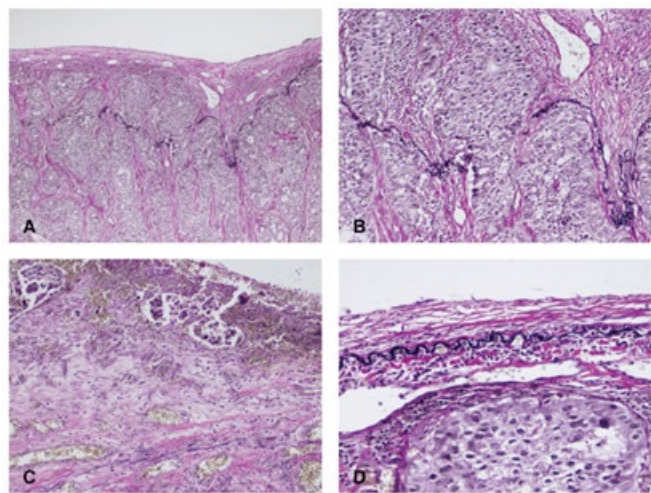
## References

1. Detterbeck FC, Franklin WA, Nicholson AG, et al. The IASLC lung cancer staging project: background data and proposed criteria to distinguish separate primary lung cancers from metastatic foci in patients with two lung tumors in the forthcoming eighth edition of the TNM classification of lung cancer. *J Thorac Onc.* 2016;11(5):651-665.
2. WHO Classification of Tumours Editorial Board. *Thoracic tumours*. Lyon (France): International Agency for Research on Cancer; 2021. (WHO classification of tumours series, 5th ed.; vol. 5). <https://publications.iarc.fr/595>
3. Amin MB, Edge SB, Greene FL, et al., eds. *AJCC Cancer Staging Manual*. 8th ed. New York, NY: Springer; 2017.
4. Detterbeck FC, Nicholson AG, Franklin WA, et al. The IASLC lung cancer staging project: summary of proposals for revisions of the classification of lung cancers with multiple pulmonary sites of involvement in the forthcoming eighth edition of the TNM classification of lung cancer. *J Thorac Onc.* 2016;11(5):639-650.
5. Detterbeck FC, Marom EM, Arenberg DA, et al. The IASLC lung cancer staging project: background data and proposals for the application of TNM staging rules to lung cancer presenting as multiple nodules with ground glass or lepidic features or a pneumonic type of involvement in the forthcoming eighth edition of the TNM classification of lung cancer. *J Thorac Onc.* 2016;11(5):666-680.

## E. Visceral Pleural Invasion

The presence of visceral pleural invasion by tumors  $\leq 3$  cm changes the T category from pT1 to pT2a.<sup>1</sup> Studies have shown that tumors  $\leq 3$  cm that penetrate beyond the elastic layer of the visceral pleura behave similarly to similar-size tumors that extend to the visceral pleural surface.<sup>2,3</sup> Visceral pleural invasion

should therefore be considered present not only in tumors that extend to the visceral pleural surface, but also in tumors that penetrate beyond the elastic layer of the visceral pleura (Figure 1).<sup>4,5,6</sup> To qualify for visceral pleural invasion, tumor cells must have crossed the thickest visceral pleural elastic layer, which is usually the outermost (external) elastic layer in the visceral pleura (the layer closest to the visceral pleural mesothelial-lined surface). In many patients, a thinner, sometimes discontinuous, elastic layer (internal visceral pleural elastic layer) can be appreciated closer to the lung parenchyma. Penetration of tumor through this thinner, variably discontinuous internal (i.e., closer to the lung parenchyma) elastic layer does not qualify as visceral pleura invasion.<sup>7</sup> The pleural elastic layers can be difficult to appreciate in hematoxylin-eosin stains. Elastic stains may facilitate the assessment of visceral pleural invasion.<sup>2,3,7</sup>



**Figure 1.** Types of visceral pleural invasion. Staining for elastin (eg, elastic-Van Gieson [EVG] stain) can aid in detection of visceral pleural invasion where it is indeterminate by hematoxylin-eosin (H&E) stain. A and B. Visceral pleural invasion is present when a tumor penetrates beyond the thick (external) elastic layer of the visceral pleura (type PL1 pleural invasion) C. Tumor extension to the visceral pleural surface is also categorized as visceral pleural invasion (type PL2). Both types of visceral pleural invasion raise the T category of otherwise T1 tumors to T2a. D. Visceral pleural invasion is categorized as absent in tumors that do not penetrate the visceral pleural elastic layer (type PL0). (Original magnifications x200 [A], x400 [B and C], x600 [D]).

Based on available data, a tumor with direct invasion across a fissure or directly if the fissure is incomplete into an adjacent ipsilateral lobe should be classified as T2a unless the size of the tumor or other criteria that would dictate a higher T category are met.<sup>7</sup>

Pleural tumor nodules, including same lobe visceral pleural nodules, separate from the primary tumor (non-contiguous) should be categorized as M1a.<sup>1</sup>

#### References

1. Amin MB, Edge SB, Greene FL, et al., eds. *AJCC Cancer Staging Manual*. 8th ed. New York, NY: Springer; 2017.
2. Bunker ML, Raab SS, Landreneau RJ, et al. The diagnosis and significance of visceral pleura invasion in lung carcinoma: histologic predictors and the role of elastic stains. *Am J Clin Pathol*. 1999;112(6):777-783.
3. Shimizu K, Yoshida J, Nagai K, et al. Visceral pleural invasion classification in non-small cell lung cancer: a proposal on the basis of outcome assessment. *J Thorac Cardiovasc Surg*. 2004;127(6):1574-1578.

4. Maeyashiki T, Suzuki K, Hattori A, et al. The size of consolidation on thin-section computed tomography is a better predictor of survival than the maximum tumour dimension in resectable lung cancer. *Eur J Cardiothorac Surg*. 2013;43(5):915-918.
5. Wittekind C, Greene FL, Henson DE, Hutter RVP, Sobin LH, eds. *TNM Supplement: A Commentary on Uniform Use*. 3rd ed. New York, NY: Wiley-Liss; 2001.
6. Travis WD, Asamura H, Bankier AA, et al. The IASLC lung cancer staging project: proposals for coding T categories for subsolid nodules and assessment of tumor size in part-solid tumors in the forthcoming eighth edition of the TNM classification of lung cancer. *J Thorac Onc*. 2016;11(8):1204-1223.
7. Travis WD, Brambilla E, Rami-Porta R, et al. Visceral pleural invasion: pathologic criteria and use of elastic stains: proposal for the 7th edition of the TNM classification for lung cancer. *J Thorac Oncol*. 2008;3(12):1384-1390.

#### **F. Direct Invasion of Adjacent Structures**

In pneumonectomy specimens, centrally located tumors sometimes exhibit direct invasion of the hilar fat and/or other hilar soft tissues. Direct hilar fat/soft tissue invasion without evidence of direct extension into other structures that would meet a higher T designation is categorized as T2a.<sup>1</sup>

Occasionally, lung cancer specimens consist of en bloc resections that incorporate extrapulmonary structures directly invaded by tumor. Accurate assessment of such specimens requires communication with the surgeon regarding the nature and location of any attached extrapulmonary structures. According to the AJCC, direct invasion of the parietal pleura is categorized as T3, as is direct invasion of the chest wall (including the superior sulcus).<sup>1</sup> Although not required, specifying the chest wall structures directly invaded by tumor (eg, intercostal muscle[s], rib[s], pectoralis muscle, latissimus muscle, serratus muscle) may facilitate patient management. Direct phrenic nerve and parietal pericardial invasion are also categorized as T3. Tumor extension into the visceral pericardium (epicardium) is categorized as T4.

Direct invasion of central thoracic structures, including the heart, great vessels, mediastinum, trachea, recurrent laryngeal nerve, esophagus, vertebral body, and carina is considered T4. Direct invasion of the diaphragm is also categorized as T4.

#### **References**

1. Amin MB, Edge SB, Greene FL, et al., eds. *AJCC Cancer Staging Manual*. 8th ed. New York, NY: Springer; 2017.

#### **G. Treatment Effect**

For patients who have received neoadjuvant chemotherapy, immunotherapy and/or radiation therapy before surgical resection, quantifying the extent of therapy-induced tumor regression provides prognostically relevant information.<sup>1,2</sup> Measuring residual tumor size in patients with a partial response can be challenging, as there are often discontinuous clusters of viable tumor at the peripheral edges of an irregular area of treatment-related necrosis. The IASLC recently published multidisciplinary recommendations for the pathologic assessment of lung cancer resection specimens after neoadjuvant therapy.<sup>2</sup> To evaluate treatment effect, the resection specimen should be sectioned in the plane that shows the maximum dimension of the tumor bed and its relationship to structures relevant for determining pT category and margin status. Three-dimensional size of the tumor bed and an estimated percentage of gross necrosis should be recorded. Tumor beds up to 3.0 cm may be submitted entirely for microscopic examination. For larger tumors, the IASLC recommends complete sampling of an entire cross section of tumor bed with mapping of each section to a gross photograph. The percentages of viable tumor, stromal tissue (i.e., fibrosis and inflammation) and necrosis (in increments of 10% totaling 100%) should be determined based on review of all microscopic sections of tumor bed. If a component amounts to less than

5%, an estimate of single percentages should be recorded. This approach to evaluating residual tumor refines that suggested by the AJCC of multiplying the percentage of the mass that is composed of viable tumor by the size of the total mass to estimate postneoadjuvant tumor size.<sup>3,4</sup> A “y” prefix is applied to the TNM classification in resections following multimodality therapy (see Note J). If no viable tumor is identified on resection, ypT0 is the appropriate designation.

#### References

1. Junker K, Langer K, Klinker F, Bosse U, Thomas M. Grading of tumor regression in non-small cell lung cancer: morphology and prognosis. *Chest*. 2001;120(5):1584-1591.
2. Travis WD, Dacic S, Wistuba I, et al. IASLC Multidisciplinary Recommendations for Pathologic Assessment of Lung Cancer Resection Specimens After Neoadjuvant Therapy. *J Thorac Oncol*. 2020 May;15(5):709-740.
3. Amin MB, Edge SB, Greene FL, et al., eds. *AJCC Cancer Staging Manual*. 8th ed. New York, NY: Springer; 2017.
4. Travis WD, Asamura H, Bankier AA, et al. The IASLC lung cancer staging project: proposals for coding T categories for subsolid nodules and assessment of tumor size in part-solid tumors in the forthcoming eighth edition of the TNM classification of lung cancer. *J Thorac Onc*. 2016;11(8):1204-1223.

#### H. Vascular/Lymphatic Invasion

There are data showing lymphatic invasion by tumor represents an unfavorable prognostic finding, but studies on the role of large vessel invasion have produced somewhat conflicting results.<sup>1,2</sup> The presence of lymphovascular invasion is exclusionary of adenocarcinoma in situ (AIS) and minimally invasive adenocarcinoma (MIA).<sup>3</sup> Angiolymphatic invasion does not alter the pT and pN classifications or the TNM stage grouping.

#### References

1. Amin MB, Edge SB, Greene FL, et al., eds. *AJCC Cancer Staging Manual*. 8th ed. New York, NY: Springer; 2017.
2. Tsutani Y, Miyata Y, Nakayama H, et al. Prognostic significance of using solid versus whole tumor size on high-resolution computed tomography for predicting pathologic malignant grade tumors in clinical stage IA lung adenocarcinoma: a multicenter study. *J Thorac Cardiovasc Surg*. 2012;143(3):607-612.
3. Travis WD, Brambilla E, Burke AP, Marx A, Nicholson AG, eds. *World Health Organization (WHO) Classification of Tumours of the Lung, Pleura, Thymus and Heart*. Geneva, Switzerland: WHO Press; 2015.

#### I. Margins

Surgical margins represent sites that have either been cut or bluntly dissected by the surgeon to resect the specimen. The presence of tumor at a surgical margin is an important finding, because there is the potential for residual tumor remaining in the patient in the area surrounding a positive margin. Peripheral wedge resections contain a parenchymal margin, which is represented by the tissue at the staple line(s). Lobectomy and pneumonectomy specimens contain bronchial and vascular margins and, depending on the completeness of the interlobar fissures and other anatomic factors, may also contain parenchymal margins in the form of staple lines. En bloc resections that contain extrapulmonary structures as part of the specimen have additional margins (eg, parietal pleura, chest wall), which should be designated by the surgeon for appropriate handling. Note that the visceral pleura is not a surgical margin.

## **J. Pathologic Stage Classification**

The TNM staging system of the AJCC and the UICC is recommended for both non-small cell lung cancer and small cell lung cancer.<sup>1</sup> Typical carcinoid and atypical carcinoid tumors should also be classified according to the TNM staging system.

By AJCC/UICC convention, the designation “T” refers to a primary tumor that has not been previously treated. The symbol “p” refers to the pathologic classification of the TNM, as opposed to the clinical classification, and is based clinical stage information modified/refined by operative findings and pathological evaluation of the resected specimen. The pTNM classification is applicable when surgery is performed before adjuvant systemic or radiation therapy is initiated<sup>1</sup>. pT entails a resection of the primary tumor or biopsy adequate to evaluate the highest pT category, pN entails removal of nodes adequate to validate lymph node metastasis, and pM implies microscopic examination of distant lesions.

### **TNM Descriptors**

For identification of special cases of TNM or pTNM classifications, the “m” suffix and “y,” and “r” prefixes are used. Although they do not affect the stage grouping, they indicate cases needing separate analysis.

The “m” suffix indicates the presence of multiple ground-glass/lepidic tumors in a single site and is recorded in parentheses: pT(m)NM (see Note D).

The “y” prefix indicates those cases in which classification is performed during or following initial multimodality therapy (ie, neoadjuvant chemotherapy, radiation therapy, or both chemotherapy and radiation therapy). The cTNM or pTNM category is identified by a “y” prefix. The ycTNM or ypTNM categorizes the extent of tumor actually present at the time of that examination. The “y” categorization is not an estimate of tumor prior to multimodality therapy (ie, before initiation of neoadjuvant therapy) (see Note I).

The “r” prefix indicates a recurrent tumor when staged after a documented disease-free interval and is identified by the “r” prefix: rTNM.

### **T Category Considerations**

The uncommon superficial spreading tumor of any size with its invasive component limited to the bronchial wall, which may extend proximal to the main bronchus, is classified as T1.<sup>1</sup>

Although obstructive pneumonitis associated with tumor is sometimes seen histologically, accurate assessment of tumor-associated obstructive pneumonitis as well as atelectasis requires integration of clinical and radiographic information. Atelectasis and obstructive pneumonitis recognized by pathology only should not be used for TNM staging.

### **N Category Considerations**

Lymph node metastases are an adverse prognostic factor, the extent of which is dependent on the location of the involved lymph nodes. The involved lymph node stations should be recorded according to the International Association for the Study of Lung Cancer (IASLC) lymph node map. Given the nature of the procedure, lymph nodes obtained by mediastinoscopy are often received fragmented, and it may not be possible to distinguish a single fragmented lymph node from fragments of multiple lymph nodes. For this reason, only if the actual number of nodes is known or provided should it be quantified. Otherwise, it is permissible to report the sites of nodal metastases without specifying the number involved.

Although extranodal extension of a positive mediastinal lymph node may represent an unfavorable prognostic finding, it does not change the pN classification or the TNM stage grouping. Extranodal extension refers to the extension of metastatic intranodal tumor beyond the lymph node capsule into the surrounding tissue. Direct extension of a primary tumor into a nearby lymph node does not qualify as extranodal extension.

The anatomic classification of regional lymph nodes proposed by the IASLC is shown below. A complete description of the anatomic limits of each nodal station can be found in the AJCC Staging Manual.<sup>1</sup>

Station 1	Lower cervical, supraclavicular, and sternal notch nodes
Station 2	Upper paratracheal nodes
Station 3	Prevascular and retrotracheal nodes
Station 4	Lower paratracheal nodes:
Station 5	Subaortic nodes (aorto-pulmonary window)
Station 6	Paraortic nodes (ascending aorta or phrenic)
Station 7	Subcarinal nodes
Station 8	Paraesophageal nodes (below carina)
Station 9	Pulmonary ligament nodes
Station 10	Hilar nodes
Station 11	Interlobar nodes
Station 12	Lobar nodes
Station 13	Segmental nodes
Station 14	Subsegmental nodes

Metastasis to nonregional lymph nodes (ie, lymph nodes that are not included in the IASLC lymph node map) are assigned to the M1b or M1c category depending on whether single or multiple metastases are present.

### **M Category Considerations**

With respect to this protocol, reporting a pM designation (ie, pM1a, pM1b, or pM1c) is required only if metastasis is pathologically confirmed in the specimen(s) being examined. The designation pMX should not be used.

In addition to malignant pleural effusion, malignant pericardial effusion, as well as separate tumor nodule(s) in a contralateral lobe are categorized as M1a.<sup>1</sup> Visceral or parietal ipsilateral pleural tumor nodules and pericardial tumor nodules that are not in direct continuity with the primary lung tumor are also categorized as M1a. Discontinuous tumor nodules in the chest wall or diaphragm are categorized as M1b or M1c depending on whether there are single or multiple nodules.

### **References**

1. Amin MB, Edge SB, Greene FL, et al., eds. *AJCC Cancer Staging Manual*. 8th ed. New York, NY: Springer; 2017.