



Protocol for the Examination of Specimens From Patients With Primary Tumors of the Ovary, Fallopian Tube, or Peritoneum

Version: 1.3.0.2

Protocol Posting Date: March 2022

CAP Laboratory Accreditation Program Protocol Required Use Date: May 2022

The changes included in this current protocol version do not affect the prior accreditation date.

For accreditation purposes, this protocol should be used for the following procedures AND tumor types:

| Procedure | Description |
|---|--|
| Resection | Includes oophorectomy, salpingo-oophorectomy, salpingectomy, subtotal resection, or removal of tumor in fragments |
| Tumor Type | Description |
| Primary malignant tumors of ovary, fallopian tube or peritoneum | Includes all primary epithelial borderline tumors and carcinomas, carcinosarcoma, malignant germ cell tumors, malignant sex cord-stromal tumors, and ovarian sarcomas. |

This protocol is NOT required for accreditation purposes for the following:

| Procedure |
|--|
| Biopsy |
| Primary resection specimen with no residual cancer (eg, following neoadjuvant therapy) |
| Cytologic specimens |

The following tumor types should NOT be reported using this protocol:

| Tumor Type |
|---|
| Peritoneal mesothelioma |
| Lymphoma (consider the Hodgkin or non-Hodgkin Lymphoma protocols) |

Authors

Uma G. Krishnamurti, MD, PhD*; Barbara A. Crothers, DO*; Veronica Klepeis, MD, PhD; Christopher N. Otis, MD; George G. Birdsong, MD; Saeid Movahedi-Lankarani, MD.

With guidance from the CAP Cancer and CAP Pathology Electronic Reporting Committees.

* Denotes primary author.

Accreditation Requirements

This protocol can be utilized for a variety of procedures and tumor types for clinical care purposes. For accreditation purposes, only the definitive primary cancer resection specimen is required to have the core and conditional data elements reported in a synoptic format.

- Core data elements are required in reports to adequately describe appropriate malignancies. For accreditation purposes, essential data elements must be reported in all instances, even if the response is “not applicable” or “cannot be determined.”
- Conditional data elements are only required to be reported if applicable as delineated in the protocol. For instance, the total number of lymph nodes examined must be reported, but only if nodes are present in the specimen.
- Optional data elements are identified with “+” and although not required for CAP accreditation purposes, may be considered for reporting as determined by local practice standards.

The use of this protocol is not required for recurrent tumors or for metastatic tumors that are resected at a different time than the primary tumor. Use of this protocol is also not required for pathology reviews performed at a second institution (ie, secondary consultation, second opinion, or review of outside case at second institution).

Synoptic Reporting

All core and conditionally required data elements outlined on the surgical case summary from this cancer protocol must be displayed in synoptic report format. Synoptic format is defined as:

- Data element: followed by its answer (response), outline format without the paired Data element: Response format is NOT considered synoptic.
- The data element should be represented in the report as it is listed in the case summary. The response for any data element may be modified from those listed in the case summary, including “Cannot be determined” if appropriate.
- Each diagnostic parameter pair (Data element: Response) is listed on a separate line or in a tabular format to achieve visual separation. The following exceptions are allowed to be listed on one line:
 - Anatomic site or specimen, laterality, and procedure
 - Pathologic Stage Classification (pTNM) elements
 - Negative margins, as long as all negative margins are specifically enumerated where applicable
- The synoptic portion of the report can appear in the diagnosis section of the pathology report, at the end of the report or in a separate section, but all Data element: Responses must be listed together in one location

Organizations and pathologists may choose to list the required elements in any order, use additional methods in order to enhance or achieve visual separation, or add optional items within the synoptic report. The report may have required elements in a summary format elsewhere in the report IN ADDITION TO but not as replacement for the synoptic report ie, all required elements must be in the synoptic portion of the report in the format defined above.

Summary of Changes

v 1.3.0.2

- Adjusted text in the Peritoneal Ascitic Fluid answers
- Changed Other Lesions to Additional Findings in Explanatory Note L

Reporting Template**Protocol Posting Date: March 2022****Select a single response unless otherwise indicated.****CASE SUMMARY: (OVARY or FALLOPIAN TUBE or PRIMARY PERITONEUM)****Standard(s):** AJCC-UICC 8, FIGO Cancer Report 2018

Applies to primary tumors of ovarian or fallopian tube origin. If bilateral tumors of 2 different histologic types are present, separate case protocols should be used for each tumor. If borderline and malignant tumors are present in separate ovaries, the malignant tumor synoptic report takes precedence and the borderline tumor is reported separately in synoptic form.

CLINICAL**+Clinical History (select all that apply)**

- BRCA1 / 2 family history
 Hereditary breast / ovarian cancer
 Lynch syndrome
 Other (specify): _____

SPECIMEN (Notes [A](#),[B](#))**Procedure (select all that apply)**

For information about lymph node sampling, please refer to the Regional Lymph Node section.

- Total hysterectomy and bilateral salpingo-oophorectomy
 Radical hysterectomy
 Simple hysterectomy
 Supracervical hysterectomy
 Bilateral salpingo-oophorectomy
 Right salpingo-oophorectomy
 Left salpingo-oophorectomy
 Salpingo-oophorectomy, side not specified
 Right oophorectomy
 Left oophorectomy
 Oophorectomy, side not specified
 Bilateral salpingectomy
 Right salpingectomy
 Left salpingectomy
 Salpingectomy, side not specified
 Omentectomy
 Peritoneal biopsies
 Peritoneal tumor debulking
 Peritoneal washing
 Pleurocentesis (pleural fluid)
 Other (specify): _____

+Hysterectomy Type

- Abdominal
 Vaginal
 Vaginal, laparoscopic-assisted

- Laparoscopic
- Laparoscopic, robotic-assisted
- Other (specify): _____
- Not specified

Specimen Integrity (select all that apply)

For primary ovarian tumors, if the ovary containing primary tumor is removed intact into a laparoscopy bag and ruptured in the bag by the surgeon without spillage into the peritoneal cavity (to allow for removal via laparoscopy port site or small incision), the specimen integrity should be listed as "capsule intact" with a comment explaining this in the report. For primary peritoneal tumors in women with prior salpingo-oophorectomy, select "Not applicable".

- Not applicable
- Right ovary

Right Ovary Integrity

- Capsule intact
- Capsule ruptured
- Fragmented
- Other (specify): _____

- Left ovary

Left Ovary Integrity

- Capsule intact
- Capsule ruptured
- Fragmented
- Other (specify): _____

- Ovary, laterality not specified

Ovary Integrity

- Capsule intact
- Capsule ruptured
- Fragmented
- Other (specify): _____

- Right fallopian tube

Right Fallopian Tube Integrity

- Serosa intact
- Serosa ruptured
- Fragmented
- Other (specify): _____

- Left fallopian tube

Left Fallopian Tube Integrity

- Serosa intact
- Serosa ruptured
- Fragmented
- Other (specify): _____

- Fallopian tube, laterality not specified

Fallopian Tube Integrity

- Serosa intact
- Serosa ruptured
- Fragmented
- Other (specify): _____

+Uterus Integrity

- Intact
- Opened
- Morcellated
- Other (specify): _____

TUMOR

Tumor Site (Notes [C,D,E](#))

Please select the primary tumor site only. For bilateral ovarian tumors with identical histology, choose "bilateral ovaries".

- Right ovary: _____
- Left ovary: _____
- Bilateral ovaries: _____
- Ovary, laterality cannot be determined (explain): _____
- Right fallopian tube: _____
- Left fallopian tube: _____
- Bilateral fallopian tubes: _____
- Fallopian tube, laterality cannot be determined (explain): _____
- Right tubo-ovarian: _____
- Left tubo-ovarian: _____
- Bilateral tubo-ovarian: _____
- Tubo-ovarian, laterality cannot be determined (explain): _____
- Primary peritoneum: _____
- Other (specify): _____

Tumor Size

For bilateral tumors, please report maximum dimension for the malignant or largest tumor.

- Greatest dimension in Centimeters (cm): _____ cm
- +Additional Dimension in Centimeters (cm): ____ x ____ cm**
- Cannot be determined (explain): _____

Histologic Type (Notes [F,G](#)) (select all that apply)

- Serous borderline tumor
- Serous borderline tumor, micropapillary / cribriform variant
- Serous borderline tumor with microinvasion
- Microinvasive low grade serous carcinoma
- Low grade serous carcinoma
- High grade serous carcinoma
- Mucinous borderline tumor
- Mucinous borderline tumor with intraepithelial carcinoma
- Mucinous borderline tumor with microinvasion
- Mucinous adenocarcinoma
- Endometrioid borderline tumor
- Endometrioid carcinoma
- Endometrioid carcinoma, seromucinous type
- Seromucinous borderline tumor
- Clear cell borderline tumor

- Clear cell carcinoma
- Borderline Brenner tumor
- Malignant Brenner tumor
- Mesonephric-like adenocarcinoma
- Small cell carcinoma, hypercalcemic type
- Dedifferentiated carcinoma
- Undifferentiated carcinoma NOS
- Carcinoma, subtype cannot be determined
- Mixed epithelial borderline tumor (specify types and percentages): _____
- Mixed carcinoma (specify types and percentages): _____
- Carcinosarcoma (malignant mixed Mullerian tumor)
- Endometrioid stromal sarcoma, low grade
- Endometrioid stromal sarcoma, high grade
- Adenosarcoma
- Leiomyosarcoma
- Fibrosarcoma
- Granulosa cell tumor, adult type
- Granulosa cell tumor, juvenile type
- Steroid cell tumor
- Sertoli-Leydig cell tumor
- Other sex cord-stromal tumor (specify type): _____
- Immature teratoma
- Teratoma with malignant transformation (specify type): _____
- Malignant struma ovarii
- Dysgerminoma
- Yolk sac tumor
- Embryonal carcinoma
- Gonadoblastoma
- Choriocarcinoma, non-gestational type
- Mixed malignant germ cell tumor (specify types and percentages): _____

Primary Peritoneal Tumors

- Gastrointestinal stromal tumor
- Solitary fibrous tumor, malignant
- Desmoplastic small round cell tumor
- Other histologic type not listed (specify): _____

+Histologic Type Comment: _____

Histologic Grade (required for serous, endometrioid, mucinous, and seromucinous carcinomas, immature teratomas, and Sertoli-Leydig cell tumors) # (Note H)

Serous carcinomas are graded via a 2-tier system. Immature teratomas can be graded using a 2-tier or 3-tier system. Endometrioid and mucinous carcinomas are graded via a 3-tier FIGO system identical to their endometrial counterparts. Sertoli-Leydig cell tumors are graded via a modified 3-tier grading system with grade 2 tumors being termed "intermediate differentiated." Clear cell carcinomas, borderline epithelial neoplasms, carcinosarcomas, all other malignant sex-cord stromal and germ cell tumors are not graded. If there are mixed tumors, report the highest grade tumor and comment on all others.

WHO Grading System

- GB, borderline tumor
- G1, well differentiated
- G2, moderately differentiated

- G3, poorly differentiated
- GX, cannot be assessed: _____
- Two-Tier Grading System (required for serous carcinomas and immature teratomas only)*
- Low grade
- High grade
- Other (specify): _____
- Not applicable

Ovarian Surface Involvement

- Not identified
- Present, right
- Present, left
- Present, right and left
- Present
- Cannot be determined (explain): _____
- Not applicable

Fallopian Tube Surface Involvement

- Not identified
- Present, right
- Present, left
- Present, right and left
- Present
- Cannot be determined (explain): _____
- Not applicable

Implants (required for advanced stage serous / seromucinous borderline tumors only)# (Note !)

Serous borderline tumor implants that were formerly classified as "invasive implants" are now classified as extraovarian low-grade serous carcinoma. If the foci cannot be categorized as noninvasive or invasive, they are indeterminate.

- Not applicable
- Not sampled
- Not identified
- Present (specify sites): _____
- Indeterminate

Other Tissue / Organ Involvement (select all that apply)

Any organ not selected is either not involved or was not submitted.

- Not applicable
- Not identified
- Right ovary
- Left ovary
- Ovary (side not specified)
- Right fallopian tube
- Left fallopian tube
- Fallopian tube (side not specified)
- Uterine corpus
- Uterine cervix
- Pelvic peritoneum

- Abdominal peritoneum
- Omentum
- Other organs / tissue (specify): _____
- Cannot be determined (explain): _____

Largest Extrapelvic Peritoneal Focus

- Microscopic
- Macroscopic (2 cm or less) (specify site, if applicable): _____
- Macroscopic (greater than 2 cm) (specify site, if applicable): _____
- Cannot be determined (explain): _____
- Not applicable

Peritoneal / Ascitic Fluid Involvement

- Not submitted / unknown
 - Malignant cells not identified
- # Borderline tumor cells in fluids are classified as "atypia of undetermined significance"; if malignancy cannot be excluded, cells are classified as "suspicious for malignancy".*
- Atypical# (explain): _____
 - Suspicious# (explain): _____
 - Malignant cells present
 - Cannot be determined: _____
 - Results pending

Chemotherapy Response Score (CRS) (Note [J](#))

Required only for high-grade serous carcinomas. Treatment effect is based on assessment of residual tumor in the omentum.

- Not applicable
- No known presurgical therapy
- CRS1 (no definite or minimal response)
- CRS2 (moderate response)
- CRS3 (marked response with no or minimal residual cancer)
- Cannot be determined: _____

+Tumor Comment: _____

REGIONAL LYMPH NODES

Regional Lymph Node Status#

Lymph nodes designated as pelvic (parametrial, obturator, internal iliac (hypogastric), external iliac, common iliac, sacral, presacral) and para-aortic are considered regional lymph nodes. Any other involved nodes should be categorized as metastases (pM1) and commented on in the distant metastasis section. Presence of isolated tumor cells no greater than 0.2 mm in regional lymph node(s) is considered N0 (i+).

- Not applicable (no regional lymph nodes submitted or found)
- Regional lymph nodes present
 - All regional lymph nodes negative for tumor cells
 - Tumor present in regional lymph node(s)

Number of Nodes with Metastasis Greater than 10 mm

- Exact number (specify): _____
- At least (specify): _____

___ Other (specify): _____
___ Cannot be determined (explain): _____

Number of Nodes with Metastasis 10 mm or Less (excluding isolated tumor cells)

___ Exact number (specify): _____
___ At least (specify): _____
___ Other (specify): _____
___ Cannot be determined (explain): _____

Number of Nodes with Isolated Tumor Cells (ITCs) (0.2 mm or less)#

Reporting the number of lymph nodes with isolated tumor cells is required only in the absence of metastasis greater than 0.2 mm in other lymph nodes.

___ Not applicable
___ Exact number (specify): _____
___ At least (specify): _____
___ Other (specify): _____
___ Cannot be determined (explain): _____

+Nodal Site(s) with Tumor (select all that apply)

___ Right pelvic: _____
___ Left pelvic: _____
___ Pelvic, NOS: _____
___ Right para-aortic: _____
___ Left para-aortic: _____
___ Para-aortic, NOS: _____
___ Other (specify): _____
___ Cannot be determined: _____

+Size of Largest Nodal Metastatic Deposit

Specify in Millimeters (mm)

___ Exact size: _____ mm
___ At least: _____ mm
___ Greater than: _____ mm
___ Less than: _____ mm
___ Other (specify): _____
___ Cannot be determined (explain): _____

+Location of Largest Nodal Metastatic Deposit

___ Right pelvic: _____
___ Left pelvic: _____
___ Pelvic, NOS: _____
___ Right para-aortic: _____
___ Left para-aortic: _____
___ Para-aortic, NOS: _____
___ Other (specify): _____
___ Cannot be determined: _____
___ Other (specify): _____
___ Cannot be determined (explain): _____

Number of Lymph Nodes Examined

___ Exact number (specify): _____
___ At least (specify): _____
___ Other (specify): _____
___ Cannot be determined (explain): _____

+Nodal Site(s) Examined (select all that apply)

- Right pelvic: _____
 Left pelvic: _____
 Pelvic, NOS: _____
 Right para-aortic: _____
 Left para-aortic: _____
 Para-aortic, NOS: _____
 Other (specify): _____
 Cannot be determined: _____

+Regional Lymph Node Comment: _____

DISTANT METASTASIS**Distant Site(s) Involved, if applicable# (select all that apply)**

This excludes metastasis to pelvic or para-aortic lymph nodes.

- Not applicable
 Pleural effusion with positive cytology: _____
 Liver parenchyma: _____
 Splenic parenchyma: _____
 Extra-abdominal organ(s): _____
 Inguinal or retroperitoneal lymph node(s) and lymph node(s) outside the abdominal cavity:

 Transmural involvement of intestine: _____
 Other (specify): _____
 Cannot be determined: _____

PATHOLOGIC STAGE CLASSIFICATION (pTNM, AJCC 8th Edition) (Note [K](#))

Reporting of pT, pN, and (when applicable) pM categories is based on information available to the pathologist at the time the report is issued. As per the AJCC (Chapter 1, 8th Ed.) it is the managing physician's responsibility to establish the final pathologic stage based upon all pertinent information, including but potentially not limited to this pathology report.

TNM Descriptors (select all that apply)

- Not applicable
 m (multiple primary tumors)
 r (recurrent)
 y (post-treatment)

pT Category

- pT not assigned (cannot be determined based on available pathological information)
 pT0: No evidence of primary tumor

pT1: Tumor limited to ovaries (one or both) or fallopian tube(s)

Serous tubal intraepithelial carcinoma (STIC) should be staged as pT1a if it involves one tube only, as pT1b if it involves both tubes, and as pT1c3 if it is accompanied by positive peritoneal washing washings or ascites. Nonmalignant ascites is not classified. The presence of ascites does not affect staging unless malignant cells are present.

- pT1a: Tumor limited to one ovary (capsule intact) or fallopian tube, no tumor on ovarian or fallopian tube surface; no malignant cells in ascites or peritoneal washings#
 pT1b: Tumor limited to both ovaries (capsules intact) or fallopian tubes; no tumor on ovarian or fallopian tube surface; no malignant cells in ascites or peritoneal washings

___ pT1c: Tumor limited to one or both ovaries or fallopian tubes, with any of the following:

___ pT1c1: Surgical spill

___ pT1c2: Capsule ruptured before surgery or tumor on ovarian or fallopian tube surface

___ pT1c3: Malignant cells in ascites or peritoneal washings

___ pT1 (subcategory cannot be determined)

pT2: Tumor involves one or both ovaries or fallopian tubes with pelvic extension below pelvic brim or primary peritoneal cancer

___ pT2a: Extension and / or implants on the uterus and / or fallopian tube(s) and / or ovaries.

___ pT2b: Extension to and / or implants on other pelvic tissues

___ pT2 (subcategory cannot be determined)

pT3: Tumor involves one or both ovaries or fallopian tubes, or primary peritoneal cancer, with microscopically confirmed peritoneal metastasis outside the pelvis and / or metastasis to the retroperitoneal (pelvic and / or para-aortic) lymph nodes

___ pT3a: Microscopic extrapelvic (above the pelvic brim) peritoneal involvement with or without positive retroperitoneal lymph nodes

___ pT3b: Macroscopic peritoneal metastasis beyond pelvis 2 cm or less in greatest dimension with or without metastasis to the retroperitoneal lymph nodes

___ pT3c: Macroscopic peritoneal metastasis beyond pelvis more than 2 cm in greatest dimension with or without metastasis to the retroperitoneal lymph nodes (includes extension to capsule of liver and spleen without parenchymal involvement of either organ)

___ pT3 (subcategory cannot be determined)

pN Category#

For ovarian, fallopian tube, or primary peritoneal tumors, lymph nodes designated as pelvic [parametrial, obturator, internal iliac (hypogastric), external iliac, common iliac, sacral, presacral], para-aortic, and retroperitoneal are considered regional lymph nodes. Although not specifically named by AJCC or FIGO, intra-omental and peri-intestinal lymph nodes are also regarded as regional lymph nodes for staging purposes. Any other involved nodes should be categorized as metastases (pM1) and reported in the distant metastasis section. Presence of isolated tumor cells no greater than 0.2 mm in regional lymph node(s) is considered N0(i+).

___ pN not assigned (no nodes submitted or found)

___ pN not assigned (cannot be determined based on available pathological information)

___ pN0: No regional lymph node metastasis

___ pN0 (i+): Isolated tumor cells in regional lymph node(s) no greater than 0.2 mm

pN1: Positive retroperitoneal lymph nodes only (histologically confirmed)

___ pN1a: Metastasis up to 10 mm in greatest dimension

___ pN1b: Metastasis more than 10 mm in greatest dimension

___ pN1 (subcategory cannot be determined)

pM Category (required only if confirmed pathologically)

Parenchymal liver or splenic metastasis is classified as stage IV disease, whereas liver or splenic capsule metastasis is classified as stage III disease. Non-regional lymph node metastases (such as inguinal, supraclavicular, and axillary nodes) are considered M1. Involvement of diaphragm surface is considered pT3; however, involvement of diaphragm skeletal muscle or abdominal wall tissue beyond the peritoneum is considered distant metastasis (M1).

___ Not applicable - pM cannot be determined from the submitted specimen(s)

pM1: Distant metastasis, including pleural effusion with positive cytology; liver or splenic parenchymal metastasis; metastasis to extra-abdominal organs (including inguinal lymph nodes and lymph nodes outside the abdominal cavity); and transmural involvement of intestine

___ pM1a: Pleural effusion with positive cytology

___ pM1b: Liver or splenic parenchymal metastases; metastases to extra-abdominal organs (including inguinal lymph nodes and lymph nodes outside the abdominal cavity); transmural involvement of intestine

___ pM1 (subcategory cannot be determined)

FIGO STAGE**+FIGO Stage (2018 FIGO Cancer Report)**

I: Tumor limited to ovaries (one or both) or fallopian tube(s)

IA: Tumor limited to one ovary or fallopian tube(s), capsule intact; no tumor on ovarian surface or fallopian tube; no malignant cells in ascites or peritoneal washings

IB: Tumor limited to both ovaries or fallopian tube(s), capsules intact, no tumor on ovarian or fallopian tube surface; no malignant cells in the ascites or peritoneal washings

IC: Tumor limited to one or both ovaries or fallopian tube(s), with any of the following subcategories below

IC1: Surgical spill

IC2: Capsule ruptured before surgery or tumor on ovarian or fallopian tube surface

IC3: Malignant cells present in the ascites or peritoneal washings

II: Tumor involves one or both ovaries or fallopian tubes with pelvic extension (below pelvic brim) or peritoneal cancer

IIA: Extension and / or implants on the uterus and / or fallopian tube(s)

IIB: Extension to and / or implants in other pelvic tissues

III: Tumor involves one or both ovaries with microscopically confirmed peritoneal metastasis outside the pelvis and / or retroperitoneal lymph node involvement

IIIA: Metastasis to the retroperitoneal lymph nodes with or without microscopic peritoneal involvement beyond the pelvis

IIIA1: Positive (microscopically confirmed) retroperitoneal lymph nodes only

This is tumor dimension and not lymph node dimension.

IIIA1(i): Metastasis less than or equal to 10 mm in greatest dimension#

IIIA1(ii): Metastasis greater than 10 mm in greatest dimension#

IIIA2: Microscopic peritoneal metastasis beyond the pelvis with or without positive retroperitoneal lymph nodes

IIIB: Macroscopic peritoneal metastases beyond the pelvic brim less than or equal to 2 cm in greatest dimension with or without positive retroperitoneal lymph nodes

Includes extension of tumor to capsule of liver and spleen without parenchymal involvement of either organ.

IIIC: Macroscopic peritoneal metastases beyond the pelvic brim greater than 2 cm in greatest dimension including extension to liver capsule or spleen without parenchymal involvement of those organs and with or without positive retroperitoneal lymph nodes##

IV: Distant metastasis including cytology-positive pleural effusion; liver or splenic parenchymal involvement; extra-abdominal organ involvement excluding inguinal lymph nodes; transmural intestinal involvement

IVA: Pleural effusion with positive cytology

Parenchymal metastases are stage IVB. Disease invading through the bowel wall and into the mucosa increases the stage to IVB, and transmural involvement of a visceral structure also represents stage IVB disease.

IVB: Liver or splenic parenchymal metastasis; metastasis to extra-abdominal organs (including inguinal lymph nodes and lymph nodes outside the abdominal cavity); transmural involvement of intestine

###

ADDITIONAL FINDINGS (Note [L](#))**+Additional Findings (select all that apply)**

None identified

Serous tubal intraepithelial carcinoma (STIC)

- Endometriosis
- Endosalpingiosis
- Other (specify): _____

SPECIAL STUDIES (Note [M](#))

For reporting molecular testing, immunohistochemistry, and other cancer biomarker testing results, the appropriate CAP biomarker template should be used. Pending biomarker studies should be listed in the Comments section of this report.

+p53 Immunohistochemistry

- Normal (wild type)
- Abnormal (mutated)
 - Overexpression (strong, diffuse basilar nuclear expression)
 - Null (lack of nuclear or cytoplasmic expression)
 - Cytoplasmic only (lacks nuclear expression)

COMMENTS

Comment(s): _____

Explanatory Notes

A. Suggestions for Sampling for Microscopic Examination

Ovarian Surface

Involvement of the ovarian surface is an important element in staging tumors limited to the ovary, and the presence of surface involvement may influence treatment. Therefore, careful examination of the ovarian surface is crucial. Furthermore, in patients who undergo prophylactic (salpingo-) oophorectomy because of a family history of ovarian and/or breast cancer, very small foci of involvement of the ovarian surface may be present that may be potentially lethal and may be missed if the macroscopic inspection is not optimal.[1,2,3,4,5,6](#)

Ovarian/Adnexal Tumor

One section for each centimeter of the tumor's largest dimension is generally recommended, with modification based on the degree of heterogeneity of the tumor and the difficulty of diagnosis. Borderline (atypical proliferative) serous tumor, borderline serous tumors with micropapillary features/noninvasive low-grade serous carcinoma, and borderline (atypical proliferative) mucinous tumors require more sections (2 sections for each centimeter of the tumor's largest dimension is recommended in such cases). Some sections should include the ovarian surface where it is most closely approached by tumor on gross examination, with the number of sections depending on the degree of suspicion of surface involvement. Tumor adhesions and sites of rupture should be sampled and labeled specifically for microscopic identification.

Risk Reducing Salpingo-Oophorectomy Specimens

The ovary and fallopian tube should be submitted in toto in patients with *BRCA* mutations or suspected to be at increased risk of hereditary breast/ovarian cancer, even when grossly normal. This detailed examination results in an approximately 4-fold increase in detection of precursor lesions or early microscopic carcinoma.[7](#) Appropriate handling implies that all ovarian and tubal tissue should be serially sectioned and submitted.[8,9](#) For fallopian tubes, amputate the fimbriated ends and section parallel to the long axis of the fallopian tube to maximize the amount of tubal epithelium available for histological examination (SEE-FIM protocol)[10](#) (Figure 1). The remainder of the fallopian tube is submitted as serial cross-sections. Fixation for 1 to 2 hours prior to sectioning and/or manipulation may help prevent sloughing of the epithelium.

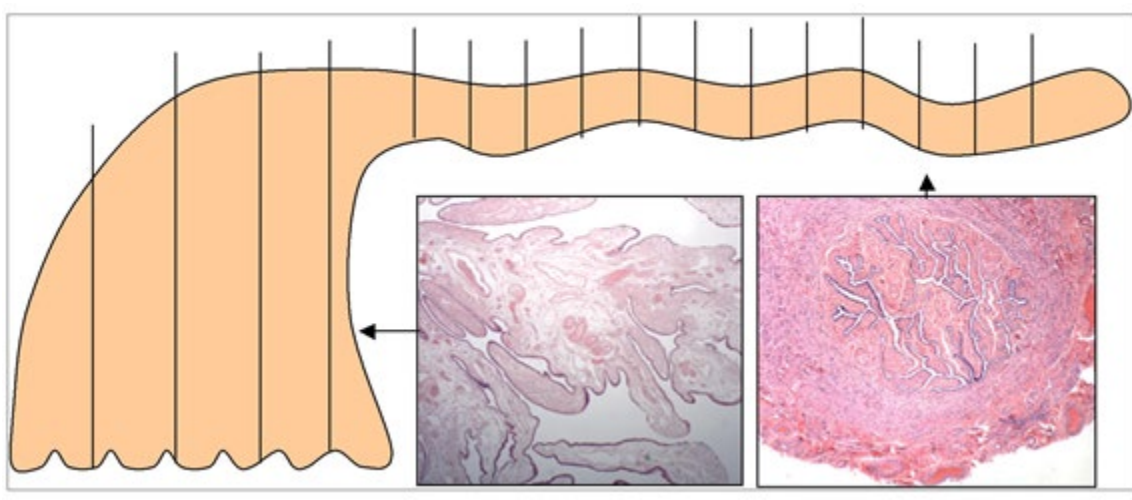


Figure 1. Protocol for Sectioning and Extensively Examining the Fimbriated End (SEE-FIM) of the Fallopian Tube. This protocol entails amputation and longitudinal sectioning of the infundibulum and fimbrial segment (distal 2 cm) to allow maximal exposure of the tubal plicae. The isthmus and ampulla are cut transversely at 2- to 3-mm intervals. From Crum et al.¹⁰ Copyright © 2007 Lippincott Williams & Wilkins. Reproduced with permission.

Sampling Issues

The recommendation for the number of sections to be taken of an ovarian/adnexal tumor is a general guideline, with the pathologist determining how many sections are necessary. If a tumor is obviously malignant and homogeneous throughout on gross examination, fewer sections may be needed. In contrast, if there is great variability in the gross appearance of the sectioned surfaces or opened cysts, it may be necessary to take more sections to sample the tumor adequately. In addition, as a general recommendation, borderline serous tumors with micropapillary foci or with microinvasion should be extensively sampled to ensure adequate assessment of the extent of invasion, when present. Mucinous tumors (particularly those with solid areas), solid teratomas, and malignant germ cell tumors often require careful gross examination and judicious sampling. Of note, additional sampling of a tumor that poses problems in differential diagnosis may be more informative than special studies.

Fallopian Tube(s)

For patients with high-grade serous carcinoma, if no gross lesion is present in the fimbrial end of each fallopian tube, complete microscopic examination is recommended. If a gross fimbrial lesion is present, representative sections of tumor to determine its distribution and relationship to tubal epithelium are recommended.

For patients with high-grade serous carcinoma, in contrast to other tumor histologic types covered by this protocol, a small, sometimes microscopic focus of tumor may be present in the mucosa of the fallopian tube that is the probable primary site (see Note C). The identification of tubal involvement can usually be accomplished by careful macroscopic examination and, if nothing is identified grossly, by submitting the fimbrial end of the fallopian tubes in toto for microscopic examination using the SEE-FIM protocol.¹⁰

Uterus

If tumor is grossly present, sections should be taken to determine its extent, including depth of invasion of myometrium if tumor possibly originated in endometrium, and to determine its relation to ovarian tumor

(metastatic to, metastatic from, independent primary). If uterine serosa is grossly involved, sections to show this should be taken.

Omentum

If tumor is grossly identifiable, representative sections are enough. Multiple sections are recommended when no tumor is detected grossly. Although there is no general consensus regarding the number of sections that should be taken on a grossly normal omentum of a patient with an ovarian serous borderline tumor, serous carcinoma, or immature teratoma, a general recommendation is to take 5 to 10 sections. One model demonstrated that 5 blocks produced a sensitivity of 82% whereas 10 blocks increased the sensitivity to 95%.¹¹ Implants in serous borderline tumors are no longer separated into noninvasive and invasive; all “invasive implants” are now considered peritoneal involvement with low-grade carcinoma.¹² Implants in serous borderline tumors and immature teratomas may vary from noninvasive to invasive low-grade serous carcinoma¹² and from mature to immature,¹³ respectively. Identification of invasive carcinoma or an immature implant may considerably alter the prognosis and therapy. For borderline tumors or immature teratoma with grossly apparent implants, multiple sections of the implants should be taken.

For patients who have received neoadjuvant chemotherapy for advanced stage tubo-ovarian carcinoma (typically of high-grade serous type), 4 to 6 sections of omentum, to sample the most abnormal areas, are recommended to allow assessment of response to chemotherapy (see Note J).

Lymph Nodes

If the lymph nodes are grossly involved by tumor, representative sections are enough. However, if the lymph nodes appear grossly free of tumor, they should be entirely submitted. In either case, the dimension of the largest metastatic deposit should be documented.

Other Staging Biopsy Specimens

Staging biopsy tissues should be entirely processed unless grossly positive for tumor. If tumor is grossly seen, representative sections are usually sufficient. For borderline tumors or immature teratomas with grossly apparent implants, multiple sections of the implants should be taken (as in omental sampling).

Other Organ or Tissue Removed

Sections should be taken to determine the presence or absence, as well as location and extent, of tumor, if present. Resection margins should be taken, if applicable.

References

1. Singh N, Gilks CB, Wilkinson N, et al. Assessment of a new system for primary site assignment in high-grade serous carcinoma of the fallopian tube, ovary, and peritoneum. *Histopathology*. 2015;67(3):331-337.
2. Gilks CB, Irving J, Kobel M, et al. Incidental nonuterine high-grade serous carcinomas arise in the fallopian tube in most cases: further evidence for the tubal origin of high-grade serous carcinomas. *Am J Surg Pathol*. 2015;39:357-364.
3. McCluggage WG, Judge MJ, Clarke BA, et al. Data set for reporting of ovary, fallopian tube and primary peritoneal carcinoma: recommendations from the International Collaboration on Cancer Reporting (ICCR). *Mod Pathol*. 2015;28(8):1101-1122.

4. Morrison JC, Blanco LZ Jr, Vang R, Ronnett BM. Incidental serous tubal intraepithelial carcinoma and early invasive serous carcinoma in the nonprophylactic setting: analysis of a case series. *Am J Surg Pathol*. 2015;39(4):442-53.
5. Singh N, Gilks CB, Hirschowitz L, et al. Adopting a uniform approach to site assignment in tubo-ovarian high grade serous carcinoma – the time has come. *Int J Gynecol Pathol*. 2016;35(3):230-237.
6. Bell DA, Scully RE. Early de novo ovarian carcinoma: a study of fourteen cases. *Cancer*. 1994;73(7):1859-1864.
7. Lamb JD, Garcia RL, Goff BA, Paley PJ, Swisher EM. Predictors of occult neoplasia in women undergoing risk-reducing salpingo-oophorectomy. *Am J Obstet Gynecol*. 2006;194(6):1702-1709.
8. Kindelberger DW, Lee Y, Miron A, et al. Intraepithelial carcinoma of the fimbria and pelvic serous carcinoma: evidence for a causal relationship. *Am J Surg Pathol*. 2007;31(2):161-169.
9. Medeiros F, Muto MG, Lee Y, et al. The tubal fimbria is a preferred site for early adenocarcinoma in women with familial ovarian cancer syndrome. *Am J Surg Pathol*. 2006;30(2):230-236.
10. Crum CP, Drapkin R, Miron A, et al. The distal fallopian tube: a new model for pelvic serous carcinogenesis. *Curr Opin Obstet Gynecol*. 2007;19(1):3-9.
11. Skala SL, Hagemann IS. Optimal sampling of grossly normal omentum in staging of gynecologic malignancies. *Int J Gynecol Pathol*. 2015; 34(3):281-287.
12. Hauptmann S, Friedrich K, Redline R, Avril S. Ovarian borderline tumors in the 2014 WHO classification: evolving concepts and diagnostic criteria. *Virchows Arch*. 2017;470:125-142.
13. Robboy SJ, Scully RE. Ovarian teratoma with glial implants on peritoneum: an analysis of 12 cases. *Hum Pathol*. 1970;1(4):643-653.

B. Rupture of Tumor

It is important to know if the tumor is intact or ruptured, because in the latter situation, malignant cells may have spilled into the abdominal cavity. In a meta-analysis of early stage epithelial ovarian cancer with rupture, pre-operative rupture decreased progression free survival when compared with intraoperative rupture, but both showed reduced progression free survival compared to no rupture.¹ In tumors that have an admixture of benign, borderline, and/or malignant areas, it may also be important to know which area ruptured.^{2,3}

References

1. Kim HS, Ahn JH, Chung HH, et al. Impact of intraoperative rupture of the ovarian capsule on prognosis in patients with early-stage epithelial ovarian cancer: a meta-analysis. *Eur J Surg Oncol*. 2013;39(3):179-89.
2. Vergote I, De Brabanter J, Fyles A, et al. Prognostic importance of degree of differentiation and cyst rupture in stage I invasive epithelial ovarian carcinoma. *Lancet*. 2001;357(9251):176-182.
3. Trimble EL. Prospects for improving staging of ovarian cancers. *Lancet*. 2001;357(9251):159-160.

C. Site of Origin

Determination of primary site for most histologic types of ovarian tumor is relatively straightforward when the tumor is confined to the ovary. When an ovarian tumor also involves the fallopian tube, uterus, and/or multiple intraperitoneal sites, it may be difficult or impossible to determine the primary site.

Historically, a primary site was assigned based on the dominant mass, but this resulted in ovarian metastases from a number of extra-ovarian primary sites (eg, stomach, vermiform appendix, colon,

pancreas, endocervix, endometrium) being mistaken for primary ovarian neoplasms. Increased awareness of the ability of small extra-ovarian primary tumors to metastasize to the ovary, their characteristic morphological features, and the introduction of immunostains that aid in primary site determination have led to improved recognition of ovarian metastases in practice. The origin of ovarian high grade serous carcinoma (HGSC) is under investigation, with evidence for both fallopian tube and ovarian surface epithelial cells as contenders.^{1,2} It is widely accepted that the fallopian tube is the likely origin of most HGSC.³ However, there remain challenges in assigning a primary site in some cases of HGSC.^{4,5,6} Table 1 reflects current recommendations for primary site designation in these cases.

Table 1. Criteria for Assignment of Primary Site in Tubo-Ovarian High-Grade Serous Carcinoma (HGSC)^{5,6,7}

| <i>Primary Site Designation</i> | <i>Criteria</i> |
|---------------------------------|---|
| Fallopian Tube | Serous tubal intraepithelial carcinoma (STIC) present OR Mucosal high grade serous carcinoma (HGSC) present, with or without STIC OR Part or entire length of fallopian tube inseparable from the tubo-ovarian mass |
| Ovary | Both fallopian tubes are separate from the mass AND No STIC or mucosa HGSC in either fallopian tube |
| Tubo-ovarian | Fallopian tubes and ovaries not available for complete examination AND Pathologic findings consistent with extrauterine HGSC |
| Peritoneal | Both fallopian tubes and ovaries are fully examined AND No gross or microscopic evidence of STIC or HGSC in tubes or ovaries |

(Adopted from Cheung AN, Ellenson LH, Gilks CB, et al. Tumours of the ovary. In: WHO Classification of Tumours Editorial Board. Female genital tumours [Internet]. Lyon (France): International Agency for Research on Cancer; 2020 [cited 2020 Dec 2]. (WHO classification of tumours series, 5th ed; vol 4). Available from <https://tumourclassification.iarc.who.int/chapters/1>.)

Site assignment as “undesignated” should be avoided as far as possible and used only in the rare event that a case does not fit into any of the above categories and/or there remains doubt over whether it is of tubo-ovarian or endometrial origin. These designations depend upon complete examination of grossly normal fallopian tubes using the SEE-FIM protocol. Assigning a “tubo-ovarian” primary site should be reserved for small biopsy samples or HGSC developing in patients with a prior salpingo-oophorectomy with incomplete tubal examination but may also be applicable in cases of previously treated tumor specimens.

It is important to note that serous carcinoma of endometrium may present with adnexal mass(es). In such cases, extensive omental involvement characteristic of primary tubo-ovarian high-grade serous carcinoma is usually lacking. Within the endometrium, there may be a co-existent precursor lesion (in situ serous carcinoma, serous endometrial intraepithelial carcinoma or SEIC), supporting primary endometrial origin of the tumor. WT-1 staining is typically strong and diffuse in tubo-ovarian high-grade serous carcinoma and weak/focal or negative in endometrial serous carcinoma. However, WT-1 is not completely sensitive or specific in determining primary site.^{4,5} Further study is needed to improve the ability to distinguish between high-grade serous carcinoma of endometrial versus tubo-ovarian origin; however, it is likely that most instances where high-grade serous carcinoma involves the endometrium, the tumor is a primary endometrial serous carcinoma.

References

1. Kim J, Park EU, Kim O, et al. Cell origins of high-grade serous ovarian cancer. *Cancers (Basel)*. 2018;10(11):433.
2. Zhang S, et al. Both fallopian tube and ovarian surface epithelium are cells-of-origin for high-grade serous ovarian carcinoma. *Nat Commun*. 2019;10(1):5367.
3. Singh N, McCluggage WG, Gilks CB. High-grade serous carcinoma of tubo-ovarian origin: recent developments. *Histopathol*. 2017;71(3):339-356.
4. Singh N, Gilks CB, Wilkinson N, et al. Assessment of a new system for primary site assignment in high-grade serous carcinoma of the fallopian tube, ovary, and peritoneum. *Histopathol*. 2015;67(3):331-337.
5. McCluggage WG, Judge MJ, Clarke BA, et al. Data set for reporting of ovary, fallopian tube and primary peritoneal carcinoma: recommendations from the International Collaboration on Cancer Reporting (ICCR). *Mod Pathol*. 2015;28(8):1101-1122.
6. Singh N, Benson JL, Gan C, et al. Disease distribution in low-stage tubo-ovarian high-grade serous carcinoma (HGSC): implication for assigning primary site and FIGO stage. *Int J Gynecol Pathol*. 2018;37(4):324-330.
7. Cheung AN, Ellenson LH, Gilks CB, et al. Tumours of the ovary. In: WHO Classification of Tumours Editorial Board. Female genital tumours [Internet]. Lyon (France): International Agency for Research on Cancer; 2020 [cited 2020 Dec 2]. (WHO classification of tumours series, 5th ed; vol 4). Available from <https://tumourclassification.iarc.who.int/chapters/1>.

D. Tumor Location

Distribution of tumor in the ovary may provide clues to its origin. Tumor present mainly on the ovarian surface without forming a discrete lesion is more likely to represent metastasis. A tumor centered on or mainly involving the ovarian hilum is more likely metastatic. Mucinous neoplasms, if bilateral or associated with mucinous ascites or peritoneal/ovarian surface involvement, are more likely to be metastatic.^{1,2}

References

1. Lee KR, Young RH. The distinction between primary and metastatic mucinous carcinomas of the ovary: gross and histologic findings in 50 cases. *Am J Surg Pathol*. 2003;27(3):281-292.
2. Yemelyanova AV, Vang R, Judson K, et al. Distinction of primary and metastatic mucinous tumors involving the ovary: analysis of size and laterality data by primary site with reevaluation of an algorithm for tumor classification. *Am J Surg Pathol*. 2008;32(1):128-38.

E. Contralateral Ovary

Contralateral ovary refers to the ovary that is non-dominant because it is either (1) involved by a tumor that is similar to but smaller than the dominant ovarian tumor, (2) contains only what appears to be metastatic tumor on gross examination, or (3) is negative for tumor. If the contralateral ovary contains only focal tumor, the gross and microscopic examination should concentrate on determining whether the tumor is an independent primary or is metastatic from the dominant ovary. Metastatic involvement is supported by the same criteria that are used to distinguish primary and metastatic cancers to the ovary (multiple nodules, surface implants, and hilar vascular space invasion favor metastasis). If the contralateral ovary is a borderline tumor in a case of a primary ovarian malignancy, the malignant tumor is reported first with a separate synoptic report for the borderline tumor. If the contralateral ovary is the same histologic type (whether malignant or borderline), then one synoptic report is sufficient, and the

contralateral ovary is reported under “Tumor Site” as “bilateral ovaries”. Only the largest ovarian tumor size is required if the tumor is bilateral.

F. Histologic Type

The World Health Organization (WHO) classification and nomenclature of ovarian tumors is recommended because of its wide acceptance.¹

The histologic type of ovarian carcinoma can be diagnosed with a high degree of reproducibility in routine practice and does have clinical implications.¹ For example, hereditary breast and ovarian cancer syndrome is associated with high-grade serous carcinoma, while Lynch syndrome is associated with endometrioid and clear cell tumors (both are frequently associated with endometriosis), so accurate diagnosis is important.

Ovarian borderline tumors are often surgically staged to include peritoneal washings, peritoneal biopsies and omental biopsies. Multiple studies have shown that omitting staging in borderline tumors may increase recurrence rates but has no effect on overall survival.² Although it is uncommon to have positive cytology with borderline tumors, in one study, serous borderline tumor was the most common finding after high grade serous carcinoma.³ *Atypia of undetermined significance (AUS)* is the proposed category for reporting the presence of borderline tumor cells in peritoneal fluid cytology specimens, even after the tumor is confirmed to be borderline.⁴ If there is a possibility that the surgical specimen is invasive or malignant, *suspicious for malignancy (SFM)* is the preferred designation for the cytology. Borderline tumors in women of childbearing age may be treated conservatively with unilateral salpingo-oophorectomy or cystectomy for ovarian preservation. Although the risk for recurrence is greater with conservative treatment, long-term survival is unaffected.²

If the ovary(ies) contain more than one malignant tumor type, report either “mixed carcinoma” or the most aggressive malignant tumor, with a clinical note that clarifies the presence of multiple tumors and the percentage of each. Although it is rare to have two malignant tumors in the separate ovaries, this circumstance requires separate synoptic reports. If a malignant tumor is arising from a borderline or benign tumor in the same site, one report with a note clarifying the co-existence of a borderline or benign tumor is sufficient with both tumor types selected under Histologic Type.

Serous Tumors

Serous borderline tumor (SBT) is synonymous with “noninvasive low grade serous carcinoma” but the latter term is not recommended for use. The micropapillary/cribriform variant of SBT shows elongated “snakes” of epithelial cells without fibrovascular cores arising from broad papillae, forming a “Medusa-head”, or densely packed cribriform arches of cells along papillary surfaces that are 5 mm or more in greatest dimension.⁵

Implants apply only to serous/seromucinous borderline tumors and, by definition, are all noninvasive (see Note I). Criteria for the previously-recognized “invasive implants” apply to metastasis of low grade serous carcinoma (LGSC). If the ovarian tumor is suspected to be SBT but shows “invasive implants”, additional sampling is warranted, but the tumor should be categorized as LGSC.⁵

Serous borderline tumor with microinvasion is the term to use when the overall histology is SBT, but there are foci of invasion less than 5mm in greatest dimension in any single focus. These stromal foci

present as individual or small clusters of plump eosinophilic cells, or small papillary clusters in lacunar spaces without a stromal reaction.⁵

LGSC has many morphologic appearances but is typically hyper-epithelial, forming small nests, glands, micropapillae and inverted macropapillae lying within clear spaces (retraction artifact). Psammoma bodies are often abundant. **Microinvasive low grade serous carcinoma** is the term used when the overall ovarian histology resembles a LGSC but only individual foci of invasion less than 5 mm in dimension can be found. Extensive sampling should be done to exclude larger invasive foci; otherwise, these tumors usually behave like SBTs at lower stages (I and II) and are often associated with areas of conventional SBT.^{6,7}

“Seromucinous carcinoma” shows poor interobserver reproducibility and is now considered a variant of endometrioid carcinoma that often shows mucinous differentiation.⁸ Seromucinous borderline tumor remains as a distinct entity showing a mix of Mullerian epithelium, including endometrioid, ciliated, hobnailed and endocervical mucinous epithelium with foci of squamous differentiation.^{6,7,9}

The distinction between high-grade serous carcinoma (HGSC) and low-grade serous carcinoma (LGSC) is not an assignment of grade based on a continuum of differentiation. These are distinct tumors that differ with respect to risk factors, precursor lesions, response to chemotherapy, and genetic events during oncogenesis, and merit consideration as separate histologic types. The criteria for distinguishing between LGSC and HGSC are primarily based on nuclear variability (>3-fold nuclear size variation for HGSC). In cases where the distinction is difficult, p16 and p53 immunostaining (strongly and diffusely positive in HGSC) and assessment of mitotic activity (>12 mitoses/10 high-power fields in HGSC) may be used. This system has molecular and prognostic validity and excellent inter-observer agreement.¹

Serous tubal intraepithelial carcinoma (STIC) is an unusual entity and a putative precursor for HGSC. Although an “in situ” neoplasm, it has the potential to metastasize throughout the peritoneal cavity.¹⁰ Therefore, when there is only fallopian tube involvement with STIC and peritoneal washings are negative, cases are staged as AJCC pT1a/ FIGO IA tumor.

Mucinous Tumors

Mucinous borderline tumors (MBT) have at least 10% of the total tumor with epithelial proliferation, often with small, branching papillae or tufts above the baseline single-layer epithelial lining of mucinous cystadenomas. Lesser degrees of proliferation are cystadenomas “with focal proliferation.” Differentiation is usually intestinal, with or without goblet cells, but may be endocervical. MBT and primary ovarian mucinous adenocarcinoma must be differentiated from metastatic carcinoma from the endocervix, appendix, colon, stomach, pancreaticobiliary system, and breast.^{11,12,13,14,15} Metastatic mucinous carcinoma is more common than primary ovarian mucinous carcinoma.¹⁶ There is significant histologic overlap of metastatic tumors to the ovary, which may “differentiate” (maturation phenomenon) to more benign-appearing epithelium, with ovarian mucinous tumors. Features that suggest metastatic carcinoma are listed below (see Table 2).¹⁶ Expansile growth is typical of primary mucinous carcinoma and consists of at least 5mm or more of back to back (cribriform) glands with minimal intervening stroma, without a desmoplastic reaction or stromal invasion. Infiltrative growth patterns, more common with metastases, demonstrate individual glands and cell clusters inciting a stromal (often desmoplastic) response.¹⁷

Histologic features that suggest particular primary sites include villoglandular growth with epithelial basal apoptosis and apical mitoses (endocervical origin); cribriform/“garland” growth and “dirty” luminal necrosis

with significant epithelial atypia (colon); and extensive poorly-cellular mucinous dissection of stroma (pseudomyxoma ovarii) with incomplete gland formation and subepithelial “clefts” (appendix). Metastatic pancreaticobiliary carcinoma is particularly likely to mimic ovarian mucinous tumors, even benign mucinous cystadenoma.¹⁸ Pseudomyxoma peritonei is most often associated with appendiceal mucinous tumors.¹⁹ An immunohistochemical panel may also be useful, but the patterns are highly variable and depend upon the tumor differentiation (intestinal or endocervical). Primary mucinous adenocarcinoma is usually reactive for PAX8 and/or PAX2 and CK7 with focal or weak CK7 and CEA expression, and usually nonreactive for SATB2 and CDX2.^{15,17,19,20} DPC4 expression, intact in primary ovarian mucinous carcinoma, lower gastrointestinal tract and stomach tumors, but absent in pancreaticobiliary tract mucin-producing tumors, may also be helpful.¹⁷

Mucinous borderline tumor with intraepithelial carcinoma displays excessively stratified epithelium with high nuclear grade and frequent mitoses but remains confined to the epithelium. These foci may show cellular micropapillae and cribriform architecture and are a trigger to sample the tumor more extensively for invasion.¹²

Mucinous borderline tumor with microinvasion is a MBT that has foci < 5mm of invasion, typically represented by small cellular nests or single cells inciting a desmoplastic response to the stroma.¹ Cell clusters often present in clear spaces, as nests surrounded by mucin, or as irregular glands inciting a stromal response. Focal cribriform patterns may also represent microinvasion but an extensive pattern is more characteristic of primary mucinous carcinoma.¹¹

Borderline Brenner tumors are cystic and highly papillary tumors lined by transitional epithelium but lacking stromal invasion; primary urothelial carcinoma should be excluded. “Transitional cell carcinoma” is now recognized as a variant of HGSC with TP53 mutations.²¹ Malignant Brenner tumors mimic urothelial neoplasia but show stromal invasion and frequently contain remnants of benign or borderline Brenner tumor.

Mesonephric-like adenocarcinoma is a solid or solid/cystic tumor with mesonephric differentiation and a variety of glandular patterns, including tubular, pseudoendometrioid, angulated, slit-like, and papillary. Lumens often contain colloid-like material. The cells are low-columnar, crowded and have inconspicuous nucleoli. Tumor cells are positive for GATA3, TTF1, CD10 luminal, and PAX8; with wild type p53 and negative for ER, PR and WT1.^{1,22}

Table 2. Features of Primary versus Metastatic Mucinous Tumors of Ovary¹⁶

| <i>Characteristic</i> | <i>Primary Ovarian</i> | <i>Metastatic</i> |
|--------------------------|------------------------|-------------------|
| Bilateral | Rare | Frequent; > 75% |
| Surface involvement | Rare | Possible |
| Nodular growth | Rare | Frequent |
| Size > 10-12 cm | Frequent | Possible |
| Lymphovascular invasion | Rare | Possible |
| Hilar involvement | Rare | Frequent |
| Infiltrative growth | Possible | Frequent |
| Expansile growth | Frequent | Possible |
| Single cell infiltration | Rare | Possible |

(Adopted from Buza N. Frozen section diagnosis of ovarian epithelial tumors: diagnostic pearls and pitfalls. Arch Pathol. Lab Med. 2019;143:47-64.)

Sarcomas

Apart from ovarian epithelial carcinomas, ovarian sarcomas are the tumor category most likely to metastasize.²³ Sarcomas are added to this protocol because the WHO Classification of Tumours recommends the use of the conventional ovarian tumor staging system for ovarian sarcomas.¹

Primary Peritoneal Tumors

These tumors are rare. Most tumors previously designated as primary peritoneal serous carcinoma are likely of tubo-ovarian origin, but exceptions occur.^{24,25,26} To designate a serous tumor as primary peritoneal, there must be no ovarian stromal or fallopian tube epithelial involvement, and no serous tubal intraepithelial carcinoma (STIC).

Other Tumors

High-grade tumors with ambiguous features, such that one of the specific histologic types listed cannot be assigned, should be classified as “carcinoma, subtype cannot be determined”. This is an infrequent situation and every effort should be made to subclassify these tumors.

Undifferentiated carcinoma refers to a malignant tumor that lacks any evidence of a line of differentiation. **Dedifferentiated carcinoma** shows foci of identifiable epithelial differentiation, usually endometrioid carcinoma or, less often, serous carcinoma.¹

Table 3. Molecular Associations with Ovarian Tumors^{1,17}

| <i>Ovarian Tumor</i> | <i>Molecular Associations</i> |
|---|---|
| Low grade serous carcinoma | BRAF, KRAS, HER2 mutations |
| High grade serous carcinoma | TP53 mutation; BRCA1, BRCA2 |
| Endometrioid and clear cell carcinoma | CTNNB1, ARID1A, PTEN mutations |
| Clear cell carcinoma | ARID1A, PIK3CA mutations; deletion PTEN |
| Mucinous carcinoma | KRAS, CDKN2A, TP53 mutations |
| Malignant Brenner tumor | PIK3CA mutation; MDM2 amplification |
| Endometrial stromal sarcoma, low grade | JAZF1-SUZ12, EPC1-PHF1, PHF1 rearrangements |
| Granulosa cell tumor, adult type | FOXL2 missense mutation |
| Granulosa cell tumor, juvenile type | AKT1 and GNAS mutations |
| Dysgerminoma, yolk sac tumor, embryonal carcinoma | Chromosome 12 abnormalities |

References

- Cheung AN, Ellenson LH, Gilks CB, et al. Tumours of the ovary. In: WHO Classification of Tumours Editorial Board. Female genital tumours [Internet]. Lyon (France): International Agency for Research on Cancer; 2020 [cited 2020 Dec 2]. (WHO classification of tumours series, 5th ed; vol 4). Available from <https://tumourclassification.iarc.who.int/chapters/1>.
- Hacker KE, Uppal S, Johnston C. Principles of treatment for borderline, micropapillary serous, and low-grade ovarian cancer. *J Nat Comp Canc Netw*. 2016;14(9):1175-82.
- Hou Y, Bruehl FK, McHugh KE, Reynolds J. Primary tumor types and origins in positive abdominopelvic washing cytology, a single institution experience. *J Am Soc Cytopathol*. 2020;9(2):89-94.
- Chandra A, Crothers B, Kurtycz D, Schmitt F, eds. The International System for Serous Fluid Cytopathology. Springer, Switzerland, 2020.

5. Hauptmann S, Friedrich K, Redline R, Avril S. Ovarian borderline tumors in the 2014 WHO classification: evolving concepts and diagnostic criteria. *Virchows Arch*. 2017;470:125-142.
6. Slomavitz B, Gourley C, Carey MS, et al. Low-grade serous ovarian cancer: state of the science. *Gynecol Oncol*. 2020;156(3):715-725.
7. Hatano Y, Hatano K, Morishige TM, et al. A comprehensive review of ovarian serous carcinoma. *Adv Anat Pathol*. 2019;26(5):329-339.
8. Rambau PF, McIntyre JB, Taylor J, et al. Morphologic reproducibility, genotyping, and immunohistochemical profiling do not support a category of seromucinous carcinoma of the ovary. *Am J Surg Pathol*. 2017;41(5):685-695.
9. Kurman RJ, Shih IM. Seromucinous tumors of the ovary: what's in a name? *Int J Gynecol Pathol*. 2015;35:78-81.
10. Schneider S, Heikaus S, Harter P, et al. Serous tubal intraepithelial carcinoma associated with extraovarian metastases. *Int J Gynecol Cancer*. 2017;27(3):444-451.
11. Mills AM, Shanes ED. Mucinous ovarian tumors. *Surg Pathol*. 2019;12:565-585.
12. Young RH. Ovarian tumors: a survey of selected advances of note during the life of this journal. *Hum Pathol*. 2020;95:169-206.
13. Young RH. From Krukenberg to today: the ever present problems posed by metastatic tumors in the ovary. Part I: Historical perspective, general principles, mucinous tumors including the Krukenberg tumor. *Adv Anat Pathol*. 2006;13:205-227.
14. Young RH. From Krukenberg to today: the ever present problems posed by metastatic tumors in the ovary. Part II. *Adv Anat Pathol*. 2007;14(3):149-177.
15. Hu A, Li H, Zhang L, et al. Differentiating primary and extragenital metastatic mucinous ovarian tumours: an algorithm combining PAX8 with tumor size and laterality. *J Clin Pathol*. 2015;68:522-528.
16. Buza N. Frozen section diagnosis of ovarian epithelial tumors: diagnostic pearls and pitfalls. *Arch Pathol. Lab Med*. 2019;143:47-64.
17. Ramalingam P. Morphologic, immunophenotypic, and molecular features of epithelial ovarian cancer. *Oncology*. 2016;30(2):166-176.
18. Meridan Z, Yemelyanova AV, Vang R, Ronnett BM. Ovarian metastases of pancreaticobiliary tract adenocarcinomas: analysis of 35 cases, with emphasis on the ability of metastases to simulate primary ovarian mucinous tumors. *Am J Surg Pathol*. 2011;35(2):276-288.
19. Carr NJ, Cecil TD, Mohamed F, et al for the Peritoneal Surface Oncology Group International. A consensus for classification and pathologic reporting of pseudomyxoma peritonei and associated appendiceal neoplasia: the results of the peritoneal surface oncology group international (PSOGI) modified Delphi process. *Am J Surg Pathol*. 2016;40(1):14-26.
20. Ates Ozdemir D, Usubutun A. PAX2, PAX8 and CDX2 expression in metastatic mucinous, primary ovarian mucinous and seromucinous tumors and review of the literature. *Pathol Oncol Res*. 2016;22(3):595-599.
21. Ali RH, Seidman JD, Luk M, et al. Transitional cell carcinoma of the ovary is related to high-grade serous carcinoma and is distinct from malignant Brenner tumor. *Int J Gynecol Pathol*. 2012;31:499-506.
22. Chen Q, Shen Y, Xie C. Mesonephric-like adenocarcinoma of the ovary: a case report and review of the literature. *Medicine*. 2020;99(48):e23450.
23. Rose PG, Piver MS, Tsukada Y, Lau T. Metastatic patterns in histologic variants of ovarian cancer: an autopsy study. *Cancer*. 1989;64:1508-1513.
24. Yun WS, Jung-Min, B. Primary peritoneal serous carcinoma, an extremely rare malignancy: a case report and review of the literature. *Oncol Lett*. 2016 Jun;11(6):4063-4065.

25. Blontzos N, Vafias E, Vorgias G, Kalinoglou N, Iavazzo C. Primary peritoneal serous papillary carcinoma: a case series. *Arch Gynecol Obstet*. 2019 Oct;300(4):1023-1028.
26. Komiyama S, Nishijima Y, Kondo H, et al. Multicenter clinicopathological study of high-grade serous carcinoma presenting as primary peritoneal carcinoma. *Int J Gynecol Cancer*. 2018 May;28(4):657-665.

G. Mixtures of Histologic Types of Tumors

The term *mixed carcinoma* should only be used when 2 or more distinctive subtypes of epithelial carcinomas are identified and preferably confirmed by ancillary testing. There is no minimal percentage of tumor required for reporting a second component. When a carcinoma is classified as “mixed,” the major and minor types and their relative proportions (percentages) should be specified.

The diagnosis of mixed carcinoma was relatively common in the past, but with application of current histopathologic criteria, less than 1% of tubo-ovarian carcinomas are mixed, and the most common admixture is of endometrioid and clear cell carcinoma.¹ It is now appreciated that high-grade serous carcinomas show a wide range of histopathologic features. Glandular (pseudoendometrioid) differentiation, solid architecture, transitional growth pattern, or clear cell change are now accepted as being within the spectrum of high-grade serous carcinoma, and the presence of these variants does not warrant diagnosis as mixed carcinoma.^{1,2} Therefore, a mixed carcinoma should only be used when there are 2 or more distinct and separate histologic types in the tumor. Quantitation of various epithelial cell types within a carcinoma, as well as quantitation of tumor types within primitive germ cell tumors, may be prognostically important.^{3,4}

References

1. MacKenzie R, Talhouk A, Eshragh S, et al. Morphologic and molecular characteristics of ovarian mixed epithelial cancers. *Am J Surg Pathol*. 2015;39:1548-1557.
2. Cheung AN, Ellenson LH, Gilks CB, et al. Tumours of the ovary. In: WHO Classification of Tumours Editorial Board. Female genital tumours [Internet]. Lyon (France): International Agency for Research on Cancer; 2020 [cited 2020 Dec 2]. (WHO classification of tumours series, 5th ed; vol 4). Available from <https://tumourclassification.iarc.who.int/chapters/1>.
3. Kurman RJ, Norris HJ. Malignant mixed germ-cell tumors of the ovary: a clinical and pathologic analysis of 30 cases. *Obstet Gynecol*. 1976;48(5):579-589.
4. Ulbright TM. Germ cell tumors of the gonads: a selective review emphasizing problems in differential diagnosis, newly appreciated and controversial issues. *Mod Pathol*. 2005; 18(Suppl2):S61-79.

H. Histologic Grade

Epithelial Carcinomas

Clear cell carcinoma and carcinosarcomas are not graded; at present there is no grading system that has consistently been shown to prognosticate for these histologic types. Serous carcinomas are stratified into low grade and high grade. Endometrioid carcinomas may be graded according to the FIGO system used for endometrioid carcinomas of the endometrium, as shown below.

| | |
|---------|--|
| Grade 1 | 5% or less of nonsquamous solid growth |
| Grade 2 | 6% to 50% of nonsquamous solid growth |
| Grade 3 | Over 50% of nonsquamous solid growth |

For endometrioid carcinoma, notable nuclear atypia, evident on low power and inappropriate for the architectural grade, raises the grade of a grade 1 or grade 2 tumor by one grade.

There are no defined grading systems in widespread use for the remaining histologic types of ovarian epithelial carcinoma (eg, mucinous), but a 3-tier grading system may be used, acknowledging that it is not a validated system.

| | |
|---------|---|
| Grade X | Cannot be assessed |
| Grade 1 | Well differentiated |
| Grade 2 | Moderately differentiated |
| Grade 3 | Poorly differentiated (tumors with minimal differentiation seen in very small foci) |

Germ Cell Tumors

Immature teratomas are the only malignant germ cell tumors that are graded. They are classically graded on the basis of the quantity of immature/embryonal elements (almost always neuroectodermal tissue) that are present.¹ Immature elements other than embryonic neuroepithelial elements are not considered for grading purposes. The most widely implemented grading system to classify immature teratomas is a 3-tier system (see table below). However, a 2-tier grading system (low versus high grade) has been proposed by some experts as being more reproducible.² Grade 1 tumors are low grade and curable with resection while grade 2 and 3 tumors are considered high grade. Implants associated with immature teratomas must be assessed for the presence of immature elements. While immature neuroepithelium is most common, implants may be entirely comprised of mature glial tissue (gliomatosis).

Table 4. Grading Immature Teratomas

| Grade of Immature Teratoma (immature neural component only) | Total fields (include all slides) involved |
|---|--|
| Grade 1 | Less than 1 low power field (40X) |
| Grade 2 | Between 1 and 3 low power fields (40X) |
| Grade 3 | 4 or more low power fields (40X) |

Sertoli-Leydig Cell Tumors

Sertoli-Leydig cell tumors are graded with a 3-tier grading system, as described in the WHO 2020 classification.³ As differentiation decreases, so does the extent of tubular differentiation and number of Leydig cells, while the amount of primitive gonadal stroma increases. Briefly, in well differentiated (grade 1) tumors, the Sertoli cells are present in open or closed tubules; in moderately differentiated (grade 2) tumors, the Sertoli cells are present in mostly lobular aggregates, although there may be some tubular architecture present; and in poorly differentiated (grade 3) tumors, there are sarcomatous sheets of stroma and the lobulated Sertoliform growth typical of grade 2 tumors, if present, is only focal. Retiform Sertoli-Leydig tumor is a grade 1 tumor that is often mistaken for a serous tumor.

References

1. Norris HJ, Zirkin HJ, Benson WL. Immature (malignant) teratoma of the ovary: a clinical and pathologic study of 58 cases. *Cancer*. 1976;37(5):2359-2372.
2. O'Connor DM, Norris HJ. The influence of grade on the outcome of stage I ovarian immature (malignant) teratomas and the reproducibility of grading. *Int J Gynecol Pathol*. 1994;13(4):283-289.

3. Cheung AN, Ellenson LH, Gilks CB, et al. Tumours of the ovary. In: WHO Classification of Tumours Editorial Board. Female genital tumours [Internet]. Lyon (France): International Agency for Research on Cancer; 2020 [cited 2020 Dec 2]. (WHO classification of tumours series, 5th ed; vol 4). Available from <https://tumourclassification.iarc.who.int/chapters/1>.

I. Implants (Serous/Seromucinous Borderline Tumors Only)

The term “implant” is reserved for serous and seromucinous borderline tumors; malignant tumor involvement of peritoneal surfaces and organs constitutes metastatic carcinoma. “**Invasive implant**” is a term no longer applied to serous/seromucinous borderline tumors. “Invasive implants” in low grade serous carcinoma are rare, but when present, are typically sharply demarcated from the surrounding tissue due to retraction artifact. Tumor cells occur as haphazardly arranged tight nests, “inverted” macropapillae or cellular micropapillae. They may produce no stromal response or show desmoplasia with scant to no inflammation. These foci invade into peritoneal tissue, organs and/or omental fat. “Invasive implants” often show destruction of the normal organ architecture. If a serous “borderline” tumor has “invasive implants”, the ovarian tumor is classified as a low grade serous carcinoma and the implants are metastases.

Noninvasive implants can be subdivided into epithelial and desmoplastic types and both are associated with a favorable prognosis. Noninvasive epithelial implants are complex papillary structures and detached cell clusters on tissue surfaces or within peritoneal invaginations, without a stromal reaction. Noninvasive desmoplastic implants are small groups or single cells confined to the surface, producing a significant granulation-type stromal reaction, but not infiltrating fat. There is no retraction artifact around these cell nests, which differentiates them from invasive implants.¹ Distinction between subtypes of noninvasive implants is academic and of no clinical significance. Invasive implants are associated with a shorter overall survival, supporting their designation as metastases from low grade serous carcinoma.²

References

1. Hauptmann S, Friedrich K, Redline R, Avril S. Ovarian borderline tumors in the 2014 WHO classification: evolving concepts and diagnostic criteria. *Virchows Arch.* 2017;470:125-142.
2. Cheung AN, Ellenson LH, Gilks CB, et al. Tumours of the ovary. In: WHO Classification of Tumours Editorial Board. Female genital tumours [Internet]. Lyon (France): International Agency for Research on Cancer; 2020 [cited 2020 Dec 2]. (WHO classification of tumours series, 5th ed; vol 4). Available from <https://tumourclassification.iarc.who.int/chapters/1>.

J. Chemotherapy Response Score

A system for histopathologic assessment of response to neoadjuvant chemotherapy (chemotherapy response score or CRS) for high-grade serous carcinoma has been developed and validated, and shown to be highly reproducible.^{1,2} This 3-tiered scoring system is based on assessment of the section of *omentum* that shows the *least* response to chemotherapy. The criteria are shown in Table 5.

Table 5. Criteria of the Chemotherapy Response Score

CRS 1: No or minimal tumor response

Mainly viable tumor with no or minimal regression-associated fibro-inflammatory changes#, limited to a few foci; cases in which it is difficult to decide between regression and tumor-associated desmoplasia or inflammatory cell infiltration

CRS 2: Appreciable tumor response amidst viable tumor, both readily identifiable and tumor *regularly* distributed

Ranging from multifocal or diffuse regression associated fibro-inflammatory changes#, with viable tumor in sheets, streaks, or nodules, to extensive regression associated fibro-inflammatory changes with multifocal residual tumor which is easily identifiable

CRS 3: Complete or near-complete response with no residual tumor OR minimal *irregularly* scattered tumor foci seen as individual cells, cell groups, or nodules up to 2 mm in maximum size

Mainly regression-associated fibro-inflammatory changes or, in rare cases, no/very little residual tumor in complete absence of any inflammatory response; advisable to record whether “no residual tumor” or “microscopic residual tumor present”

Regression-associated fibro-inflammatory changes: Fibrosis associated with macrophages, including foam cells, mixed inflammatory cells, and psammoma bodies; to distinguish from tumor-related inflammation or desmoplasia.

References

1. Böhm S, Faruqi A, Said I, et al. Chemotherapy response score: development and validation of a system to quantify histopathologic response to neoadjuvant chemotherapy in tubo-ovarian high-grade serous carcinoma. *J Clin Oncol*. 2015;33(22):2457-2463.
2. Cohen PA, Powell A, Böhm S, et al. Pathological chemotherapy response score is prognostic in tubo-ovarian high-grade serous carcinoma: a systematic review and meta-analysis of individual patient data. *Gynecol Oncol*. 2019;154(2):441-448.

K. Pathologic Stage Classification

In view of the role of the pathologist in the staging of cancers, the staging system for ovarian cancer endorsed by the American Joint Committee on Cancer (AJCC) and the International Union Against Cancer (UICC), as well as the parallel system formulated by the International Federation of Gynecology and Obstetrics (FIGO), are recommended.[1,2,3,4](#)

According to AJCC/UICC convention, the designation “T” refers to a primary tumor that has not been previously treated. The symbol “p” refers to the pathologic classification of the TNM, as opposed to the clinical classification, and is based on gross and microscopic examination. pT entails a resection of the primary tumor or biopsy adequate to evaluate the highest pT category, pN entails removal of nodes adequate to validate lymph node metastasis, and pM implies microscopic examination of distant lesions. Clinical classification (cTNM) is usually carried out by the referring physician before treatment during initial evaluation of the patient or when pathologic classification is not possible.

Pathologic staging is usually performed after surgical resection of the primary tumor. Biopsies of all frequently involved sites, such as the omentum, mesentery, diaphragm, peritoneal surfaces, pelvic nodes, and para-aortic nodes, are required for ideal staging of early disease. For example, a patient can be confidently coded as stage IA (T1 N0 M0), if negative biopsies of all of the aforementioned sites are obtained to exclude microscopic metastases. Pathologic staging depends on pathologic documentation of the anatomic extent of disease, whether or not the primary tumor has been completely removed. If a biopsied tumor is not resected for any reason (eg, when technically infeasible), and if the highest T and N categories or the M1 category of the tumor can be confirmed microscopically, the criteria for pathologic classification and staging have been satisfied without total removal of the primary cancer.

TNM Descriptors

For identification of special cases of TNM or pTNM classifications, the “m” suffix and “y,” “r,” and “a” prefixes are used. Although they do not affect the stage grouping, they indicate cases needing separate analysis.

The “m” suffix indicates the presence of multiple primary tumors in a single site and is recorded in parentheses: pT(m)NM.

The “y” prefix indicates those cases in which classification is performed during or after initial multimodality therapy (ie, neoadjuvant chemotherapy, radiation therapy, or both chemotherapy and radiation therapy). The cTNM or pTNM category is identified by a “y” prefix. The ycTNM or ypTNM categorizes the extent of tumor actually present at the time of that examination. The “y” categorization is not an estimate of tumor before multimodality therapy (ie, before initiation of neoadjuvant therapy).

The “r” prefix indicates a recurrent tumor when staged after a documented disease-free interval and is identified by the “r” prefix: rTNM.

The “a” prefix designates the stage determined at autopsy: aTNM.

N Category Considerations

Isolated tumor cells (ITCs) are single cells or small clusters of cells not more than 0.2 mm in greatest dimension. Lymph nodes or distant sites with ITCs found by either histologic examination (eg, immunohistochemical evaluation for cytokeratin) or nonmorphological techniques (eg, flow cytometry, DNA analysis, polymerase chain reaction [PCR] amplification of a specific tumor marker) should be so identified. There is currently no guidance in the literature as to how these patients should be coded; until more data are available, they should be coded as “N0(i+)” with a comment noting how the cells were identified.

There is little data to assign risk for non-sentinel lymph node metastasis based on the size of the metastasis. However, the size criteria for micrometastasis and macrometastasis is adopted from the experience in breast carcinoma sentinel nodes. Micrometastasis is defined as a metastasis measuring greater than 0.2 mm but less than 2 mm. Sentinel lymph node evaluation in early stage ovarian carcinoma is under investigation and not universally applied.^{5,6}

References

1. Amin MB, Edge SB, Greene FL, et al, eds. *AJCC Cancer Staging Manual*. 8th ed. New York, NY: Springer; 2017.
2. Brierley JD, Gospodarowicz M, Wittekind Ch, eds. *TNM Classification of Malignant Tumors*. 8th ed. Oxford, UK: Wiley; 2016.
3. Wittekind CH, Henson DE, Hutter RVP, Sobin LH. *TNM Supplement: A Commentary on Uniform Use*. 2nd ed. New York, NY: Wiley-Liss; 2001.
4. Bhatla N, Denny L. eds. FIGO Cancer Report 2018. *Int J Gynaecol Obstet*. 2018;143.
5. Scambia G, Nero C, Uccella S, et al. Sentinel-node biopsy in early stage ovarian cancer: a prospective multicentre study (SELLY). *Int J Gynecol Cancer*. 2019;29(9):1437-1439.
6. Uccella S, Zorzato PC, Lanzo G, et al. The role of sentinel node in early ovarian cancer: a systematic review. *Minerva Med*. 2019;110(4):358-366.

L. Additional Findings

The presence of endometriosis, particularly if it is in continuity with an endometrioid or clear cell carcinoma, is an important clue as to the primary nature of the ovarian tumor. It is associated with endometrioid, clear cell, mesonephric-like adenocarcinomas and seromucinous borderline tumor.

M. Special Studies

Special studies including histochemical, immunohistochemical, and molecular genetic studies may be used in some cases. The appropriate biomarker template is suggested for reporting the results of prognostic or therapeutic tests. Evaluation for BRCA1/BRCA2 testing on patients with high-grade serous carcinoma of tubal/ovarian/peritoneal origin should be performed at the discretion of genetic counselors with assessment of other risk factors. Immunohistochemical stains for DNA mismatch repair enzymes MLH1, MS2, MSH6, and PMS2 for Lynch syndrome screening is recommended on all endometrioid and clear cell carcinomas of the ovary.^{1,2,3} A p53 should be performed on ovarian serous carcinoma, whether histologically low grade or high grade. An aberrant immunohistochemical pattern serves as a surrogate marker for TP53 gene mutations. The most common aberrant patterns are overexpression (diffuse, strong nuclear positivity), a missense mutation, and null type (complete absence of nuclear reactivity) that usually arises from insertion or deletion of the TP53 gene. Another aberrant pattern is cytoplasmic only reactivity, resulting from a mutation at the nuclear localized domain that does not allow p53 to enter the nucleus, thereby resulting in loss of function. The normal or “wild type” pattern of reactivity, which is variable nuclear staining of varying intensity, can rarely be associated with HGSC when the TP53 mutation is the result of truncated or 3' splicing mutation. When unusual aberrant patterns occur, TP3 mutation analysis may be considered.⁴ To prevent confusion, it is preferred that p53 expression be reported as normal (wild type) or abnormal with the pattern of aberrant expression in parenthesis.⁵

References

1. Lu FI, Gilks CB, Mulligan AM, et al. Prevalence of loss of expression of DNA mismatch repair proteins in primary epithelial ovarian tumors. *Int J Gynecol Pathol.* 2012;31(6):524-31.
2. Bennett JA, Morales-Oyarvide V, Campbell S, et al. Mismatch repair protein expression in clear cell carcinoma of the ovary: incidence and morphologic associations in 109 cases. *Am J Surg Pathol.* 2016;40(5):656-663.
3. Tajima Y, Eguchi H, Chika N, et al. Prevalence and molecular characteristics of defective mismatch repair epithelial ovarian cancer in Japanese hospital-based population. *Jpn J Clin Oncol.* 2018;48(8):728-735.
4. Hatano Y, Hatano K, Tamada M, et al. A comprehensive review of ovarian serous carcinoma. *Adv Anat Pathol.* 2019; 26(5):329-339.
5. Köbel M, Kang EY. The many uses of p53 immunohistochemistry in gynecologic pathology: proceedings of the ISGyP Companion Society session at the 2020 USCAP annual meeting. *Int J Gynecol Pathol.* 2021; 40(1):32-40.