



## Protocol for the Examination of Excision Specimens From Patients With Melanoma of the Skin

**Version:** 4.3.0.0

**Protocol Posting Date:** June 2021

**CAP Laboratory Accreditation Program Protocol Required Use Date:** March 2022

The changes included in this current protocol version affect accreditation requirements. The new deadline for implementing this protocol version is reflected in the above accreditation date.

**For accreditation purposes, this protocol should be used for the following procedures AND tumor types:**

Procedure	Description
Excision	
Tumor Type	Description
Melanoma	Limited to melanoma of cutaneous surfaces only

**This protocol is NOT required for accreditation purposes for the following:**

Procedure
Biopsy (consider Skin Melanoma Biopsy protocol)
Primary resection specimen with no residual melanoma (eg, following neoadjuvant therapy)
Cytologic specimens

### Authors

Wonwoo Shon, MD\*; David P. Frishberg, MD\*; Jeffery Gershenwald, MD\*; Pavandeep Gill, MD\*; Jeffrey North, MD\*; Victor G. Prieto, MD, PhD\*; Richard A. Scolyer, BMedSci, MBBS, MD; Bonnie L. Balzer, MD, PhD; Thomas J. Flotte, MD; Timothy H. McCalmont, MD; Bruce Robert Smoller, MD.

With guidance from the CAP Cancer and CAP Pathology Electronic Reporting Committees.

\* Denotes primary author.

### **Accreditation Requirements**

This protocol can be utilized for a variety of procedures and tumor types for clinical care purposes. For accreditation purposes, only the definitive primary cancer resection specimen is required to have the core and conditional data elements reported in a synoptic format.

- Core data elements are required in reports to adequately describe appropriate malignancies. For accreditation purposes, essential data elements must be reported in all instances, even if the response is “not applicable” or “cannot be determined.”
- Conditional data elements are only required to be reported if applicable as delineated in the protocol. For instance, the total number of lymph nodes examined must be reported, but only if nodes are present in the specimen.
- Optional data elements are identified with “+” and although not required for CAP accreditation purposes, may be considered for reporting as determined by local practice standards.

The use of this protocol is not required for recurrent tumors or for metastatic tumors that are resected at a different time than the primary tumor. Use of this protocol is also not required for pathology reviews performed at a second institution (ie, secondary consultation, second opinion, or review of outside case at second institution).

### **Synoptic Reporting**

All core and conditionally required data elements outlined on the surgical case summary from this cancer protocol must be displayed in synoptic report format. Synoptic format is defined as:

- Data element: followed by its answer (response), outline format without the paired Data element: Response format is NOT considered synoptic.
- The data element should be represented in the report as it is listed in the case summary. The response for any data element may be modified from those listed in the case summary, including “Cannot be determined” if appropriate.
- Each diagnostic parameter pair (Data element: Response) is listed on a separate line or in a tabular format to achieve visual separation. The following exceptions are allowed to be listed on one line:
  - Anatomic site or specimen, laterality, and procedure
  - Pathologic Stage Classification (pTNM) elements
  - Negative margins, as long as all negative margins are specifically enumerated where applicable
- The synoptic portion of the report can appear in the diagnosis section of the pathology report, at the end of the report or in a separate section, but all Data element: Responses must be listed together in one location

Organizations and pathologists may choose to list the required elements in any order, use additional methods in order to enhance or achieve visual separation, or add optional items within the synoptic report. The report may have required elements in a summary format elsewhere in the report IN ADDITION TO but not as replacement for the synoptic report ie, all required elements must be in the synoptic portion of the report in the format defined above.

### **Summary of Changes**

#### **v 4.3.0.0**

- General Reformatting
- Revised Margins Section
- Revised Lymph Nodes Section
- Added Distant Metastasis Section
- Removed pTX and pNX Staging Classification

## Reporting Template

---

**Protocol Posting Date: June 2021**

**Select a single response unless otherwise indicated.**

**CASE SUMMARY: (MELANOMA OF THE SKIN: Excision, Re-Excision)**

**Standard(s): AJCC-UICC 8**

### **SPECIMEN (Note [A](#))**

#### **Procedure (select all that apply)**

- Excision
- Re-excision
- Sentinel node(s) biopsy
- Lymphadenectomy, regional nodes (specify): \_\_\_\_\_
- Other (specify): \_\_\_\_\_
- Not specified

#### **Specimen Laterality**

- Right
- Left
- Midline
- Not specified

### **TUMOR**

#### **Tumor Site (Note [B](#))**

- Skin, NOS: \_\_\_\_\_
- Skin of lip: \_\_\_\_\_
- External ear: \_\_\_\_\_
- Skin of other and unspecified parts of face: \_\_\_\_\_
- Skin of scalp and neck: \_\_\_\_\_
- Skin of trunk: \_\_\_\_\_
- Skin of upper limb and shoulder: \_\_\_\_\_
- Skin of lower limb and hip: \_\_\_\_\_
- Overlapping lesion of skin (specify sites): \_\_\_\_\_
- Penis: \_\_\_\_\_
  - Prepuce
  - Glans penis
  - Body of penis
  - Penis, NOS
- Scrotum: \_\_\_\_\_
- Vulva: \_\_\_\_\_
  - Labium majus
  - Labium minus
  - Clitoris
  - Vulva, NOS
- Not specified

**Multiple Primary Sites**

- Not applicable (no additional primary site(s) present)
- Present: \_\_\_\_\_

*Please complete a separate checklist for each primary site*

**Invasiveness**

- Melanoma In Situ (anatomic level I)

**+Histologic Type (Note C)**

- No residual melanoma identified
- Melanoma in situ, superficial spreading type (low-cumulative sun damage (CSD) melanoma in situ)
- Melanoma in situ, lentigo maligna type
- Acral melanoma in situ
- Melanoma in situ arising in a giant congenital nevus
- Melanoma in situ, not otherwise classified
- Other histologic type not listed (specify): \_\_\_\_\_

**+Histologic Type Comment:** \_\_\_\_\_

**+Ulceration (Note D)**

- Not identified
- Present

**+Extent of Ulceration in Millimeters (mm):** \_\_\_\_\_ mm

- Cannot be determined

**+Tumor Regression (Note E)**

- Not identified
- Present, involving less than 75% of lesion
- Present, involving 75% or more of lesion
- Cannot be determined: \_\_\_\_\_

**MARGINS (Note F)**

**Margin Status for Melanoma in Situ<sup>#</sup>**

*<sup>#</sup> Margin involvement by melanoma in situ should be recorded if in situ disease is present in the specimen, and if margins are uninvolved by invasive melanoma.*

- Not applicable (in situ disease is absent and margins are uninvolved by invasive carcinoma)
- All margins negative for melanoma in situ

**+Closest Peripheral Margin Location(s) to Melanoma in Situ:** \_\_\_\_\_

**+Distance from Melanoma in Situ to Peripheral Margin**

*Specify in Millimeters (mm)*

- Exact distance: \_\_\_\_\_ mm
- Greater than: \_\_\_\_\_ mm
- At least: \_\_\_\_\_ mm
- Less than: \_\_\_\_\_ mm
- Less than 1 mm
- Other (specify): \_\_\_\_\_
- Cannot be determined: \_\_\_\_\_

- Melanoma in situ present at margin

**+Margin(s) Involved by Melanoma in situ (select all that apply)**

- Peripheral (specify location(s), if possible): \_\_\_\_\_
- Deep: \_\_\_\_\_
- Other (specify): \_\_\_\_\_
- Cannot be determined (explain): \_\_\_\_\_
- Other (specify): \_\_\_\_\_
- Cannot be determined (explain): \_\_\_\_\_

**+Margin Comment:** \_\_\_\_\_

**PATHOLOGIC STAGE CLASSIFICATION (pTNM, AJCC 8th Edition) (Note G)**

*Reporting of pT, pN, and (when applicable) pM categories is based on information available to the pathologist at the time the report is issued. As per the AJCC (Chapter 1, 8th Ed.) it is the managing physician's responsibility to establish the final pathologic stage based upon all pertinent information, including but potentially not limited to this pathology report.*

*In general, CAP cancer protocol case summaries are intended to guide reporting on the specimen that the pathologist is evaluating at that time. However, melanoma cases frequently include multiple procedures. Because of this, a prior procedure that was performed may affect the pathologic classification of the tumor. In order to represent this appropriately in the pathology report, information from prior procedures may be incorporated into the assignment of pathologic classification if it is available. When information from a prior procedure is included in this report, details of that procedure should be documented in the report as well.*

Classification assigned in this report includes information from a prior procedure (explain):  
\_\_\_\_\_

**TNM Descriptors (select all that apply)**

- Not applicable: \_\_\_\_\_
- m (multiple)
- r (recurrence or retreatment)
- y (posttherapy or post neoadjuvant therapy)

**pT Category**

- pT0: No evidence of primary tumor (e.g., unknown primary or completely regressed melanoma)
- pTis: Melanoma in situ (i.e., not an invasive tumor: anatomic level I)

Invasive Melanoma

**Histologic Type (Note C)**

- No residual melanoma identified
- Superficial spreading melanoma (low-cumulative sun damage (CSD) melanoma)
- Lentigo maligna melanoma
- Desmoplastic melanoma
  - Pure desmoplastic melanoma
  - Mixed desmoplastic melanoma
- Acral melanoma
- Melanoma arising in a blue nevus (blue nevus-like melanoma)
- Melanoma arising in a giant congenital nevus
- Spitz melanoma (malignant Spitz tumor)
- Nodular melanoma
- Nevoid melanoma
- Melanoma, not otherwise classified
- Other histologic type not listed (specify): \_\_\_\_\_

**+Histologic Type Comment:** \_\_\_\_\_

**Maximum Tumor (Breslow) Thickness in Millimeters (mm) (Note H)**

\_\_\_ Specify in Millimeters (mm): \_\_\_\_\_ mm

\_\_\_ At least in Millimeters (mm): \_\_\_\_\_ mm

**Explain:** \_\_\_\_\_

\_\_\_ Cannot be determined (explain): \_\_\_\_\_

**Macroscopic Satellite Nodule(s)**

\_\_\_ Not identified

\_\_\_ Present

\_\_\_ Cannot be determined: \_\_\_\_\_

**Ulceration (Note [D](#))**

\_\_\_ Not identified

\_\_\_ Present

**+Extent of Ulceration in Millimeters (mm):** \_\_\_\_\_ mm

\_\_\_ Cannot be determined

**+Anatomic (Clark) Level (Note [H](#))**

\_\_\_ At least level: \_\_\_\_\_

**Explain:** \_\_\_\_\_

\_\_\_ II (Melanoma present in but does not fill and expand papillary dermis)

\_\_\_ III (Melanoma fills and expands papillary dermis)

\_\_\_ IV (Melanoma invades reticular dermis)

\_\_\_ V (Melanoma invades subcutis)

\_\_\_ Cannot be determined: \_\_\_\_\_

**Mitotic Rate (Note [I](#))**

\_\_\_ None identified: \_\_\_\_\_

\_\_\_ Specify number of mitoses per square Millimeter (mm): \_\_\_\_\_ mitoses per mm<sup>2</sup>

\_\_\_ Cannot be determined

**Microsatellite(s) (Note [J](#))**

\_\_\_ Not identified

\_\_\_ Present

\_\_\_ Cannot be determined: \_\_\_\_\_

**Lymphovascular Invasion (Note [K](#))**

\_\_\_ Not identified

\_\_\_ Present

\_\_\_ Cannot be determined: \_\_\_\_\_

**Neurotropism (Note [L](#))**

\_\_\_ Not identified

\_\_\_ Present

\_\_\_ Cannot be determined: \_\_\_\_\_

**+Tumor-Infiltrating Lymphocytes (Note [M](#))**

\_\_\_ Not identified

\_\_\_ Present, nonbrisk

\_\_\_ Present, brisk

Cannot be determined

**+Tumor Regression (Note E)**

- Not identified
- Present, involving less than 75% of lesion
- Present, involving 75% or more of lesion
- Cannot be determined: \_\_\_\_\_

**MARGINS (Note F)**

**Margin Status for Invasive Melanoma**

All margins negative for invasive melanoma

**+Closest Margin Location(s) to Invasive Melanoma:** \_\_\_\_\_

**+Distance from Invasive Melanoma to Peripheral Margin**

*Specify in Millimeters (mm)*

- Exact distance: \_\_\_\_\_ mm
- Greater than: \_\_\_\_\_ mm
- At least: \_\_\_\_\_ mm
- Less than: \_\_\_\_\_ mm
- Less than 1 mm
- Other (specify): \_\_\_\_\_
- Cannot be determined: \_\_\_\_\_

**+Distance from Invasive Melanoma to Deep Margin**

*Specify in Millimeters (mm)*

- Exact distance: \_\_\_\_\_ mm
- Greater than: \_\_\_\_\_ mm
- At least: \_\_\_\_\_ mm
- Less than: \_\_\_\_\_ mm
- Less than 1 mm
- Other (specify): \_\_\_\_\_
- Cannot be determined: \_\_\_\_\_

Invasive melanoma present at margin

**+Margin(s) Involved by Invasive Melanoma (select all that apply)**

- Peripheral: \_\_\_\_\_
- Deep: \_\_\_\_\_
- Other (specify): \_\_\_\_\_
- Cannot be determined (explain): \_\_\_\_\_
- Other (specify): \_\_\_\_\_
- Cannot be determined (explain): \_\_\_\_\_

**Margin Status for Melanoma in situ<sup>#</sup>**

<sup>#</sup> Margin involvement by melanoma in situ should be recorded if in situ disease is present in the specimen, and if margins are uninvolved by invasive melanoma.

Not applicable (in situ disease is absent and margins are uninvolved by invasive carcinoma)

All margins negative for melanoma in situ

**+Distance from Melanoma in Situ to Peripheral Margin**

*Specify in Millimeters (mm)*

- Exact distance: \_\_\_\_\_ mm

- Greater than: \_\_\_\_\_ mm
- At least: \_\_\_\_\_ mm
- Less than: \_\_\_\_\_ mm
- Less than 1 mm
- Other (specify): \_\_\_\_\_
- Cannot be determined: \_\_\_\_\_

**+Distance from Melanoma in Situ to Deep Margin**

*Specify in Millimeters (mm)*

- Exact distance: \_\_\_\_\_ mm
- Greater than: \_\_\_\_\_ mm
- At least: \_\_\_\_\_ mm
- Less than: \_\_\_\_\_ mm
- Less than 1 mm
- Other (specify): \_\_\_\_\_
- Cannot be determined: \_\_\_\_\_

Melanoma in situ present at margin

**+Margin(s) Involved by Melanoma in Situ (select all that apply)**

- Peripheral: \_\_\_\_\_
- Deep: \_\_\_\_\_
- Other (specify): \_\_\_\_\_
- Cannot be determined (explain): \_\_\_\_\_
- Other (specify): \_\_\_\_\_
- Cannot be determined (explain): \_\_\_\_\_

**+Margin Comment:** \_\_\_\_\_

**REGIONAL LYMPH NODES (Note [N](#))**

If nodes from more than one nodal basin are included, each nodal basin should be reported separately.

**Regional Lymph Node Status**

- Not applicable (no regional lymph nodes submitted or found)
- Regional lymph nodes present
  - All regional lymph nodes negative for tumor
  - Tumor present in regional lymph node(s)

**Total Number of Lymph Nodes with Tumor**

- Exact number (specify): \_\_\_\_\_
- At least (specify): \_\_\_\_\_
- Other (specify): \_\_\_\_\_
- Cannot be determined (explain): \_\_\_\_\_

**Number of Sentinel Lymph Nodes with Tumor**

- Not applicable (no sentinel lymph nodes examined)
- Exact number (specify): \_\_\_\_\_
- At least (specify): \_\_\_\_\_
- Other (specify): \_\_\_\_\_
- Cannot be determined (explain): \_\_\_\_\_



**+Nodal Site(s) with Tumor (select all that apply)**

- Subcapsular
- Intramedullary
- Other (specify): \_\_\_\_\_
- Cannot be determined: \_\_\_\_\_

**+Size of Largest Sentinel Node Metastatic Deposit**

*Specify in Millimeters (mm)*

- Exact number: \_\_\_\_\_ mm
- At least: \_\_\_\_\_ mm
- Greater than: \_\_\_\_\_ mm
- Less than: \_\_\_\_\_ mm
- Other (specify): \_\_\_\_\_
- Cannot be determined (explain): \_\_\_\_\_

**Size of Largest Nodal Metastatic Deposit**

*Relevant only if larger than sentinel lymph node metastatic deposits.*

*Specify in Millimeters (mm)*

- Exact size: \_\_\_\_\_ mm
- At least: \_\_\_\_\_ mm
- Greater than: \_\_\_\_\_ mm
- Less than: \_\_\_\_\_ mm
- Other (specify): \_\_\_\_\_
- Cannot be determined (explain): \_\_\_\_\_

**Extranodal Extension**

- Not identified
- Present
- Cannot be determined: \_\_\_\_\_

**Matted Nodes**

- Not identified
- Present
- Other (specify): \_\_\_\_\_
- Cannot be determined (explain): \_\_\_\_\_

**Total Number of Lymph Nodes Examined (sentinel and non-sentinel)**

- Exact number (specify): \_\_\_\_\_
- At least (specify): \_\_\_\_\_
- Other (specify): \_\_\_\_\_
- Cannot be determined (explain): \_\_\_\_\_

**Number of Sentinel Nodes Examined**

- Exact number (specify): \_\_\_\_\_
- At least (specify): \_\_\_\_\_
- Other (specify): \_\_\_\_\_
- Cannot be determined (explain): \_\_\_\_\_

**+Regional Lymph Node Comment:** \_\_\_\_\_

## DISTANT METASTASIS

### Distant Site(s) Involved, if applicable (select all that apply)

- Not applicable
- Skin, subcutaneous tissues, soft tissues including muscle and / or nonregional lymph nodes:  
\_\_\_\_\_
- Lung: \_\_\_\_\_
- Liver: \_\_\_\_\_
- Other non-CNS sites: \_\_\_\_\_
- CNS sites: \_\_\_\_\_
- Other (specify): \_\_\_\_\_
- Cannot be determined: \_\_\_\_\_

## PATHOLOGIC STAGE CLASSIFICATION (pTNM, AJCC 8th Edition) (Note G)

Reporting of pT, pN, and (when applicable) pM categories is based on information available to the pathologist at the time the report is issued. As per the AJCC (Chapter 1, 8th Ed.) it is the managing physician's responsibility to establish the final pathologic stage based upon all pertinent information, including but potentially not limited to this pathology report.

In general, CAP cancer protocol case summaries are intended to guide reporting on the specimen that the pathologist is evaluating at that time. However, melanoma cases frequently include multiple procedures. Because of this, a prior procedure that was performed may affect the pathologic classification of the tumor. In order to represent this appropriately in the pathology report, information from prior procedures may be incorporated into the assignment of pathologic classification if it is available. When information from a prior procedure is included in this report, details of that procedure should be documented in the report as well.

- Classification assigned in this report includes information from a prior procedure (explain):  
\_\_\_\_\_

### TNM Descriptors (select all that apply)

- Not applicable: \_\_\_\_\_
- m (multiple)
- r (recurrence or retreatment)
- y (posttherapy or post neoadjuvant therapy)

### pT Category

- pT not assigned (cannot be determined based on available pathological information)
- pT0: No evidence of primary tumor (e.g., unknown primary or completely regressed melanoma)  
*pT1: Melanoma 1.0 mm or less in thickness, ulceration status unknown or unspecified (see Note D)*
- pT1a: Melanoma less than 0.8 mm in thickness, no ulceration
- pT1b: Melanoma less than 0.8 mm in thickness with ulceration; or Melanoma 0.8 to 1.0 mm in thickness with or without ulceration
- pT1 (subcategory cannot be determined)  
*pT2: Melanoma greater than 1.0 to 2.0 mm in thickness, ulceration status unknown or unspecified*
- pT2a: Melanoma greater than 1.0 to 2.0 mm in thickness, no ulceration
- pT2b: Melanoma greater than 1.0 to 2.0 mm in thickness, with ulceration
- pT2 (subcategory cannot be determined)  
*pT3: Melanoma greater than 2.0 to 4.0 mm in thickness, ulceration status unknown or unspecified*
- pT3a: Melanoma greater than 2.0 to 4.0 mm in thickness, no ulceration
- pT3b: Melanoma greater than 2.0 to 4.0 mm in thickness, with ulceration
- pT3 (subcategory cannot be determined)  
*pT4: Melanoma greater than 4.0 mm in thickness, ulceration status unknown or unspecified*
- pT4a: Melanoma greater than 4.0 mm in thickness, no ulceration
- pT4b: Melanoma greater than 4.0 mm in thickness, with ulceration
- pT4 (subcategory cannot be determined)

### pN Category

Approved

# pN1b, 2b, and 3b subcategories are dependent on clinical information that may be unavailable to the pathologist. If this information is not available, the parent category (pN1, pN2 or pN3) should be selected.

pN not assigned (no nodes submitted or found)

pN not assigned (cannot be determined based on available pathological information)

pN0: No regional lymph node metastasis detected

*pN1: One tumor-involved node or in-transit, satellite, and / or microsatellite metastases with no tumor-involved nodes*

pN1a: One clinically occult tumor-involved node (i.e., detected by sentinel node biopsy) with no in-transit, satellite and / or microsatellite metastases

pN1b: One clinically detected tumor-involved node with no in-transit, satellite and / or microsatellite metastases#

pN1c: Presence of in-transit, satellite and / or microsatellite metastases with no regional lymph node disease

pN1 (subcategory cannot be determined)

*pN2: Metastasis in two to three regional nodes or in-transit, satellite, and / or microsatellite with one tumor-involved node*

pN2a: Two to three clinically occult tumor-involved node (i.e., detected by sentinel node biopsy) with no in-transit, satellite and / or microsatellite metastases

pN2b: Two to three tumor-involved nodes at least one of which was clinically detected with no in-transit, satellite and / or microsatellite metastases#

pN2c: One clinically occult or clinically detected tumor-involved node with presence of in-transit, satellite and / or microsatellite

pN2 (subcategory cannot be determined)

*pN3: Metastasis in four or more regional lymph nodes, or in-transit, satellite or microsatellite metastases with two or more tumor-involved nodes or any number of matted nodes with or without in-transit, satellite or microsatellite metastases*

pN3a: Four or more clinically occult tumor-involved nodes (i.e., detected by sentinel node biopsy) with no in-transit, satellite and / or microsatellite metastases

pN3b: Four or more tumor-involved nodes, at least one of which was clinically detected, with no in-transit, satellite and / or microsatellite metastases#

pN3c: Two or more clinically occult or clinically detected tumor-involved nodes with in-transit, satellite and / or microsatellite metastases and / or any number of matted nodes with in-transit, satellite and / or microsatellite metastases

pN3 (subcategory cannot be determined)

### **pM Category (required only if confirmed pathologically)**

*AJCC pM category suffixes "(0)" and "(1)", which denote LDH level of elevation, are NOT included in the surgical pathology report. LDH levels, as with other clinical parameters, may be included in the final classification by clinicians with access to this data.*

Not applicable - pM cannot be determined from the submitted specimen(s)

*pM1: Distant metastasis (documented in this specimen)*

pM1a: Distant metastasis in skin, subcutaneous tissues, soft tissues including muscle and / or nonregional lymph nodes

pM1b: Distant metastasis to lung with or without M1a sites of disease

pM1c: Distant metastasis to non-CNS visceral sites with or without M1a or M1b sites of disease

pM1d: Distant metastasis to CNS with or without M1a, M1b or M1c sites of disease

pM1 (subcategory cannot be determined)

### **ADDITIONAL FINDINGS**

#### **+Additional Findings (select all that apply)**

Associated nevus (specify type): \_\_\_\_\_

Other (specify): \_\_\_\_\_

CAP  
Approved

Skin.Melanoma\_4.3.0.0.REL\_CAPCP

**SPECIAL STUDIES**

*For molecular genetic reporting, the CAP Melanoma Biomarker Template should be used. Pending biomarker studies should be listed in the Comments section of this report.*

**COMMENTS**

Comment(s): \_\_\_\_\_

## Explanatory Notes

---

### A. Procedure

Optimal pathologic evaluation of melanocytic lesions requires complete excision that incorporates the full thickness of the lesion removed intact.<sup>1</sup> 'Shave' procedures that do not include the intact base of the lesion are suboptimal for pathologic evaluation and should be avoided unless clinically indicated. Similarly, "punch" procedures may not include intact peripheral borders of the lesion thereby limiting assessment of symmetry and lateral circumscription, which can be essential for distinction of melanoma from melanocytic nevus.<sup>2,3</sup> Partial biopsies of melanocytic tumors are associated with an increased risk of misdiagnosis with possible consequent adverse clinical outcomes.<sup>4</sup> Nevertheless, clinical factors are also important in determining the most appropriate biopsy technique for any lesion. For example, an excision biopsy of a large lesion on a cosmetically or functionally sensitive site may cause cosmetic disfigurement or alter reconstructive options.

The use of frozen sections for evaluation of biopsy or excision of melanocytic lesions is strongly discouraged.<sup>5,6</sup> Optimal histologic evaluation of cutaneous melanoma requires well-cut, well-stained hematoxylin-and-eosin (H&E) sections prepared from formalin-fixed paraffin-embedded tissue. Frozen sections of sentinel lymph nodes are similarly discouraged, because the manipulation required for intraoperative handling may decrease the sensitivity of the procedure.<sup>7</sup>

### References

1. Sober AJ, Chuang TY, Duvic M, et al. Guidelines of care for primary cutaneous melanoma. *J Am Acad Dermatol.* 2001;45(4):579-586.
2. Stell VH, Norton HJ, Smith KS, Salo JC, White RL, Jr. Method of biopsy and incidence of positive margins in primary melanoma. *Ann Surg Oncol.* 2007;14(2):893-898.
3. Sober AJ, Balch CM. Method of biopsy and incidence of positive margins in primary melanoma. *Ann Surg Oncol.* 2007;14(2):274-275.
4. Ng JC, Swain S, Dowling JP, Wolfe R, Simpson P, Kelly JW. The impact of partial biopsy on histopathologic diagnosis of cutaneous melanoma: experience of an Australian tertiary referral service. *Arch Dermatol.* 2010;146(3):234-239.
5. Smith-Zagone MJ, Schwartz MR. Frozen section of skin specimens. *Arch Pathol Lab Med.* 2005;129(12):1536-1543.
6. Prieto VG, Argenyi ZB, Bamhill RL, et al. Are en face frozen sections accurate for diagnosing margin status in melanocytic lesions? *Am J Clin Pathol.* 2003;120(2):203-208.
7. Scolyer RA, Thompson JF, McCarthy SW, Gershenwald JE, Ross MI, Cochran AJ. Intraoperative frozen-section evaluation can reduce accuracy of pathologic assessment of sentinel nodes in melanoma patients. *J Am Coll Surg.* 2005;201(5):821-823; author reply 823-824.

### B. Anatomic Site

For cutaneous melanoma, prognosis may be affected by primary anatomic site.<sup>1,2</sup>

### References

1. Balch CM, Soong SJ, Gershenwald JE, et al. Prognostic factors analysis of 17,600 melanoma patients: validation of the American Joint Committee on Cancer melanoma staging system. *J Clin Oncol.* 2001;19(16):3622-3634.
2. Elder DE, Massi D, Scolyer RA, Willemze R. eds. WHO Classification of Skin Tumors. World Health Organization of Tumors, 4<sup>th</sup> ed Volume 11. Lyon France; 2018, ISBN-13 978-92-832-2440-2.

### C. Melanoma Subtypes

Superficial spreading melanoma (low cumulative sun damage (CSD) melanoma)  
 Lentigo maligna melanoma  
 Desmoplastic melanoma (pure and mixed)  
 Acral melanoma  
 Melanoma arising in a blue nevus (blue nevus-like melanoma)  
 Melanoma arising in a giant congenital nevus  
 Spitz melanoma (malignant Spitz tumor)  
 Nodular melanoma  
 Nevoid melanoma  
 Melanoma, not otherwise classified

The recent WHO 2018 classification<sup>1</sup> introduced multidimensional pathway classification of melanocytic tumors based on the extent of ultraviolet (UV) radiation damage, the cell of origin, and characteristic genomic findings (Table 1).

**Table 1. Classification of melanoma**

Extent of UV radiation damage	Subtypes
Melanomas found in skin with low cumulative sun damage (low-CSD)	Superficial spreading melanoma (low cumulative sun damage (CSD) melanoma)
Melanomas found in skin with high cumulative sun damage (high-CSD)	Lentigo maligna melanoma
	Desmoplastic melanoma
	Malignant Spitz tumor (Spitz melanoma)
Melanomas on site with no sun exposure or without known etiological associations with sun exposure	Acral melanoma
	Mucosal melanoma
	Melanoma arising in congenital nevus
	Melanoma arising in a blue nevus
	Uveal melanoma
Various sun exposure	Nodular melanoma
	Nevoid melanoma

**References**

1. Elder DE, Massi D, Scolyer RA, Willemze R. eds. WHO Classification of Skin Tumors. World Health Organization of Tumors, 4th ed Volume 11. Lyon France; 2018, ISBN-13 978-92-832-2440-2.

**D. Ulceration**

Primary tumor ulceration has been shown to be a dominant independent prognostic factor in invasive cutaneous melanoma,<sup>1,2</sup> and if present, changes the pT stage from T1a to T1b, T2a to T2b, etc., depending on the thickness of the tumor. The presence or absence of ulceration must be confirmed on microscopic examination.<sup>2</sup> Melanoma ulceration is defined as the combination of the following features: full-thickness epidermal defect (including absence of stratum corneum and basement membrane); evidence of reactive changes (ie, fibrin deposition, neutrophils); and thinning, effacement, or reactive hyperplasia of the surrounding epidermis in the absence of trauma or a recent surgical procedure. Ulcerated melanomas typically show invasion through the epidermis, whereas nonulcerated melanomas tend to lift the overlying epidermis.

Only nontraumatic (“tumorigenic”) ulceration should be recorded as ulceration. If ulceration is present related to a prior biopsy, the tumor should not be recorded as ulcerated for staging purposes. If a lesion has been recently biopsied or there is only focal loss of the epidermis, assessment of ulceration may be difficult or impossible; in this instance it may be difficult to determine whether the epidermal deficiency is

due to true ulceration or to sectioning artifact.<sup>2</sup> Absence of fibrin, neutrophils, or granulation tissue from putative areas of ulceration would be clues that the apparent ulceration is actually due to sectioning of only part of the epidermis and this should not be designated as ulceration. If non-traumatic (“tumorigenic”) ulceration is present in either an initial partial biopsy or a re-excision specimen, then for staging purposes, the tumor should be recorded as ulcerated.

Ulceration may be present in an in situ melanoma but does not affect the staging.

A number of studies have demonstrated that the extent of ulceration (measured either as a percentage of the width of the dermal invasive component of the tumor or as a diameter) more accurately predicts outcome than the presence or absence of ulceration alone.<sup>3,4</sup>

#### References

1. Gershenwald JE, Scolyer RA, Hess KR, Sondak VK, Long GV, Ross MI et al. Melanoma staging: Evidence-based changes in the American Joint Committee on Cancer eighth edition cancer staging manual. *CA Cancer J Clin.* 2017;67(6):472-92.
2. Gershenwald JE, Scolyer RA, Hess KR, et al. Melanoma of the skin, In: Amin MB, Edge SB, Greene FL, et al. eds. *AJCC Cancer Staging Manual.* 8th ed. New York, NY: Springer; 2017.
3. Hout FE, Haydu LE, Murali R, Bonenkamp JJ, Thompson JF, Scolyer RA. Prognostic importance of the extent of ulceration in patients with clinically localized cutaneous melanoma. *Ann Surg.* 2012;255(6):1165-1170.
4. Namikawa K, Aung PP, Gershenwald JE, Milton DR, Prieto VG. Clinical impact of ulceration width, lymphovascular invasion, microscopic satellitosis, perineural invasion, and mitotic rate in patients undergoing sentinel lymph node biopsy for cutaneous melanoma: a retrospective observational study at a comprehensive cancer center. *Cancer Med.* 2018;7(3):583-593.

#### E. Tumor Regression

Characteristic features of regression include replacement of tumor cells by lymphocytic inflammation, as well as attenuation of the epidermis and nonlaminated dermal fibrosis with inflammatory cells, melanophagocytosis, and telangiectasia.

#### F. Margins

Microscopically measured distances between tumor and labeled peripheral (lateral) or deep margins are appropriately recorded for melanoma excision specimens, whenever possible. If a margin is involved by tumor, it should be stated whether the tumor is in situ or invasive. Occasionally, in situ melanoma can extend down an adnexal structure like a hair follicle and cause a deep positive margin.<sup>1</sup>

#### References

1. Pozdnyakova O, Grossman J, Barbagallo, B, Lyle S. The hair follicle barrier to involvement by malignant melanoma. *Cancer* 2009;115:1267–1275.

#### G. Pathologic Stage Classification

Changes in the 8<sup>th</sup> edition AJCC Cancer Staging Manual<sup>1</sup> of importance to practicing pathologists include:

- T1a melanoma now defined as non-ulcerated melanomas less than 0.8mm thick
- T1b melanomas now defined as melanoma between 0.8mm and 1.0mm in thickness OR ulcerated melanomas less than 0.8mm thick
- Tumor mitotic rate no longer used as a T category criterion but remains an important prognostic factor and should be reported in all invasive primary melanomas
- Recommendation to record tumor thickness to the nearest 0.1mm (not the nearest 0.01mm)

Approved

- Regarding regional lymph node metastasis, the previously empirically defined terms “microscopic” and “macroscopic” replaced with “clinically occult” (ie, detected by sentinel node biopsy) and “clinically detected”
- Non-nodal regional metastatic disease (ie, microsatellites, satellites and in transit metastases) now formally stratified by N category according to the number of tumor-involved nodes
- Gross extranodal extension no longer used as an N-category criterion (but presence of “matted nodes” retained)
- M1 now defined by both anatomic site of distant metastasis and serum LDH levels for all anatomic subsite categories of metastasis
- New M1d designation added for distant metastasis to central nervous system
- pT1bN0M0 is now pathologic stage IA in contrast to cT1N0M0 which remains clinical stage IB disease
- N category now defines four stage subgroups and takes into account both T category elements and N category elements

Pathologic staging includes microstaging of the primary melanoma and pathologic information about the regional lymph nodes after partial or complete lymphadenectomy.

In virtually all studies of cutaneous melanoma, tumor thickness has been shown to be a dominant prognostic factor, and it forms the basis for the stratification of pT. Although anatomic (Clark) levels are also commonly used to indicate depth of invasion of the primary tumor, they are less predictive of clinical outcome than mitotic activity or ulceration.<sup>1,2,3</sup>

By AJCC convention, the designation “T” refers to a primary tumor that has not been previously treated. Similarly by convention, clinical staging is performed after biopsy of the primary melanoma (including utilizing pathologic information on microstaging of the primary melanoma) with clinical or biopsy assessment of regional lymph nodes and distant sites. Pathologic staging uses information gained from pathologic evaluation of both the primary melanoma after biopsy and wide excision as well as pathological evaluation of the regional node basin after SLN biopsy (required for N categorization of all greater than T1 melanomas) and/or complete regional lymphadenectomy.<sup>1,2</sup> In addition, for pathological staging, if information from any prior biopsy is known and is relevant for staging, this should be documented in the pathology report (in the staging section) and used for assigning T, N and M categories and staging purposes.

### **T Category Considerations**

Pathologic (microscopic) assessment of the primary tumor is required for accurate staging. Therefore, excision of the primary tumor, rather than incisional biopsy, is advised. The T classification of melanoma is based on the thickness of the primary tumor and presence or absence of ulceration (see also Notes D, and E).

### **N Category Considerations (see also Note M)**

The regional lymph nodes are the most common sites of metastasis. The widespread use of cutaneous lymphoscintigraphy, lymphatic mapping, and sentinel lymph node biopsies has greatly enhanced the ability to identify the presence of lymph node metastasis. By convention, the term regional lymph nodal metastasis refers to disease confined to one draining nodal basin or 2 contiguous draining nodal basins, as in patients with nodal disease in combinations of femoral/iliac, axillary/supraclavicular, cervical/supraclavicular, axillary/femoral, or bilateral axillary or femoral metastases. In some patients, lymphoscintigraphic imaging may define multiple regional lymph node basins and disease identified in any of such basins also constitutes regional disease. Metastasis to nondraining nodal basin(s) is considered M1 disease.



### Sentinel Lymph Nodes

Sentinel lymph node identification and evaluation is often included in the surgical approach to cutaneous melanoma.<sup>1,2</sup> A sentinel lymph node is defined as any lymph node receiving direct lymphatic drainage from a primary tumor site. There is often more than 1 sentinel node per draining basin and in some patients, lymphatic fluid may drain to more than one regional nodal basin.<sup>4</sup> The clinical rationale for sentinel lymph node identification and separate evaluation assumes that metastatic involvement of a sentinel node is more likely than in regional nodes in the same nodal basin that do receive lymphatic drainage from the primary melanoma. Conversely, if sentinel nodes are negative, other regional nodes in the same basin would be less likely to contain metastasis.

### **M Category Considerations**

The category “MX” has been eliminated from the AJCC/UICC TMN system.<sup>1</sup> Unless there is clinical or pathologic evidence of distant metastasis the stage is classified as clinical M0 (ie, no distant metastasis). pM should only be reported when metastases have been documented by pathologic examination, that is, pM1 disease. pMX and pM0 should not be reported by the pathologist.

### **TNM Descriptors**

For identification of special cases of TNM or pTNM classifications, the “y,” “r,” and “a” prefixes are used. Although they do not affect the stage grouping, they indicate cases needing separate analysis.

Post-therapy or post neoadjuvant therapy classification (yTNM) documents the extent of the disease for patients whose first course of therapy includes systemic or radiation treatment prior to surgical resection or when systemic therapy or radiation is primary treatment with no surgical resection. The extent of disease is classified using the same T, N, and M definitions and identified as post-treatment with a “yc” or “yp” prefix (ycT, ycN, ycTNM; ypT, ypN, ypTNM).

Recurrence or retreatment classification (rTNM) may be used to define used because information gleaned from therapeutic procedures and from extent of disease defined clinically may be prognostic for patients with recurrent cancer after a disease-free interval. It is important to understand that the rTNM classification does not change the original clinical or pathologic staging of the case and that this classification schema is not yet widely used in melanoma.<sup>1,2</sup>

Autopsy classification (aTNM) is used to stage cases of cancer not recognized during life and only recognized postmortem.

### **Lymphovascular Invasion**

Lymphovascular invasion (LVI) indicates whether microscopic lymphatic or vascular invasion is identified and includes lymphatic invasion, blood vessel invasion, or invasion of a vessel for which it cannot be determined whether it is a blood or lymphatic vessel (Lymphovascular invasion). By AJCC/UICC convention, LVI does not affect the T category indicating local extent of tumor, ie, foci of Lymphovascular invasion should not be included in the measurement of tumor (Breslow) thickness.

### **Pretreatment Serum Lactate Dehydrogenase and Serum Albumin**

Data from numerous studies have indicated that an elevated serum level of lactate dehydrogenase (LDH) is an independent predictor of decreased survival in AJCC stage IV melanoma patients. In the AJCC eighth edition, serum LDH is now recorded as “non-elevated” or “elevated” for each M category using the suffix, “(0)” or “(1)”, respectively.<sup>1,2</sup>

### References

Approved

1. Gershenwald JE, Scolyer RA, Hess KR, et al. Melanoma of the skin, In: Amin MB, Edge SB, Greene FL, et al. eds. AJCC Cancer Staging Manual. 8th ed. New York, NY: Springer; 2017.
2. Gershenwald JE, Scolyer RA, Hess KR, Sondak VK, Long GV, Ross MI et al. Melanoma staging: Evidence-based changes in the American Joint Committee on Cancer eighth edition cancer staging manual. CA Cancer J Clin. 2017;67(6):472-92.
3. Elder DE, Massi D, Scolyer RA, Willemze R. eds. WHO Classification of Skin Tumors. World Health Organization of Tumors, 4th ed Volume 11. Lyon France; 2018, ISBN-13 978-92-832-2440-2.
4. Gershenwald JE, Ross MI. Sentinel lymph node biopsy for cutaneous melanoma. N Eng J Med 364(18):1738-45, 2011. e-Pub 5/2011.

#### H. Primary Tumor (Breslow) Thickness and Anatomic (Clark) Levels

Maximum tumor thickness is measured with a calibrated ocular micrometer at a right angle to the adjacent normal skin. The upper point of reference is the upper edge of the granular layer of the epidermis of the overlying skin or, if the lesion is ulcerated overlying the entire dermal component, the base of the ulcer. The lower reference point is the deepest point of tumor invasion (ie, the leading edge of a single mass or an isolated group of cells deep to the main mass).

If the tumor is transected by the deep margin of the specimen, the depth may be indicated as “at least \_\_\_ mm” with a comment explaining the limitation of thickness assessment. For example, “The maximum tumor thickness cannot be determined in this specimen because the deep plane of the biopsy transects the tumor.” Tumor thickness measurements should not be based on periadnexal extension (either periadnexal adventitial or extra-adventitial extension), except when it is the only focus of invasion. In that circumstance, Breslow thickness may be measured from the inner layer of the outer root sheath epithelium or inner luminal surface of sweat glands, to the furthest extent of infiltration into the periadnexal dermis. Microsatellites or foci of neurotropism or lymphovascular invasion should not be included in tumor thickness measurements.

In the 8<sup>th</sup> edition of the AJCC melanoma staging system,<sup>1</sup> it is recommended that tumor thickness measurements be recorded to the nearest 0.1 mm, not the nearest 0.01 mm, because of the impracticality and imprecision of measurements, particularly for tumors greater than 1 mm thick. Tumors less than or equal to 1 mm thick may be measured to the nearest 0.01 mm if practical, but should be reported to the nearest 0.1mm (eg, melanomas measured to be in the range of 0.75 mm to 0.84 mm are reported as 0.8 mm in thickness and hence T1b, and tumors 1.01 to 1.04 mm in thickness are reported as 1.0 mm).

While the principal T category tumor thickness ranges have been maintained in the AJCC 8<sup>th</sup> edition, T1 is now subcategorized by tumor thickness strata at a 0.8 mm threshold. Tumor mitotic rate as a dichotomous variable is no longer used as a staging category criterion for T1 tumors. T1a melanomas are now defined as non-ulcerated and less than 0.8 mm in thickness. T1b melanomas are defined as 0.8-1.0mm in thickness or ulcerated melanomas less than 0.8 mm in thickness.

Anatomic (Clark) levels are defined as follows:

- I Intraepidermal tumor only (ie, melanoma in situ)
- II Tumor present in but does not fill and expand papillary dermis
- III Tumor fills and expands papillary dermis
- IV Tumor invades into reticular dermis
- V Tumor invades subcutis

Anatomic (Clark) level of invasion remains an independent predictor of outcome and is recommended by the AJCC to be reported as a primary tumor characteristic.<sup>1</sup> However, assessment of Clark levels is less

reproducible among pathologists than is tumor thickness, and Clark levels are not used in the AJCC staging system for pT status. Accordingly, Clark levels are included in this checklist as an optional data item.

#### References

1. Gershenwald JE, Scolyer RA, Hess KR, et al. Melanoma of the skin, In: Amin MB, Edge SB, Greene FL, et al. eds. AJCC Cancer Staging Manual. 8th ed. New York, NY: Springer; 2017.

#### I. Mitotic Rate

Tumor mitotic rate (of the invasive component of a melanoma) is a strong independent predictor of outcome across its dynamic range in all thickness categories and should be assessed and recorded in all primary melanomas including in both initial and excision biopsies (the highest value in any specimen should be used for prognostic purposes). Although tumor mitotic rate is no longer used as a T1-category criterion in the 8<sup>th</sup> edition of the AJCC melanoma staging system (due to the more significant prognostic significance of the new tumor thickness strata within T1 melanoma), mitotic rate will likely be an important parameter in prognostic models developed in the future that will provide personalized prediction of prognosis for individual patients.<sup>1</sup> The method recommended for enumerating the tumor mitotic rate in the 8<sup>th</sup> edition of the AJCC staging system is provided below:

“The recommended approach to enumerating mitoses is to first find the regions in the dermis containing the most mitotic figures, the so-called 'hot spot' or 'dermal hot spot.' After counting the mitoses in the initial high-power field, the count is extended to immediately adjacent nonoverlapping fields until an area of tissue corresponding to 1 mm<sup>2</sup> is assessed. If no hot spot is found and mitoses are sparse and/or randomly scattered throughout the lesion, then a representative mitosis is chosen and, beginning with that field, the count is then extended to immediately adjacent nonoverlapping fields until an area corresponding to 1 mm<sup>2</sup> of tissue is assessed. The count then is expressed as the (whole) number of mitoses/mm<sup>2</sup>. If the invasive component of the tumor involves an area less than 1 mm<sup>2</sup>, the number of mitoses should be assessed and recorded as if they were found within square millimeter. For example, if the entire dermal component of a tumor occupies 0.5 mm<sup>2</sup> and only one mitosis is identified, the mitotic rate should be recorded as 1/mm<sup>2</sup> (not 2/mm<sup>2</sup>). The number of mitoses should be listed as a whole number per square millimeter. If no mitoses are identified, the mitotic rate may be recorded as “none identified” or “0/mm<sup>2</sup>.” Only mitotic figures in invasive melanoma cells should be counted. This methodology for determining the mitotic rate of a melanoma has been shown to have excellent interobserver reproducibility, including among pathologists with widely differing experience in the assessment of melanocytic tumors.<sup>2</sup>

To obtain accurate measurement, calibration of individual microscopes is recommended using a stage micrometer to determine the number of high-power fields that equates to a square millimeter.

The data that demonstrated the strong prognostic significance of mitotic rate were obtained from the melanoma pathology reports of routinely assessed H&E stained sections. It therefore is recommended that no additional sections be cut and examined in excess of those that would normally be used to report and diagnose the melanoma to determine the mitotic count (ie, no additional sections should be cut and examined for the sole purpose of determining the mitotic rate, including in situations in which no mitoses are identified on the initial, routinely examined sections). Immunohistochemical stains for identifying mitoses are not used for determining mitotic rate for staging and/ or reporting purposes. A possible exception is the use to dual immunohistochemistry (eg, MART1 and pHH3) to determine if a cell in mitosis is a melanocyte or not (macrophage, endothelial cell, etc).<sup>3</sup>

Although the AJCC recommends reporting “0” rather than “none identified” or “less than 1,” for the purposes of cancer registry reporting all of these terms should be considered equivalent.

#### References

1. Gershenwald JE, Scolyer RA, Hess KR, et al. Melanoma of the skin, In: Amin MB, Edge SB, Greene FL, et al. eds. AJCC Cancer Staging Manual. 8th ed. New York, NY: Springer; 2017.
2. Scolyer RA, Shaw HM, Thompson JF, et al. Interobserver reproducibility of histopathologic prognostic variables in primary cutaneous melanomas. *Am J Surg Pathol.* 2003;27(12):1571-1576.
3. Tetzlaff MT, Curry JL, Ivan D, et al. Immunodetection of phosphohistone H3 as a surrogate of mitotic figure count and clinical outcome in cutaneous melanoma. *Mod Pathol.* 2013;26(9):1153-1160.

#### **J. Microsatellite(s)**

A microsatellite(s) is defined as the presence of a microscopic cutaneous metastasis found adjacent or deep to a primary melanoma on pathological examination of the primary tumor site.<sup>1</sup> The metastatic tumor cells must be discontinuous from the primary tumor. If the tissue between the apparently separate nodule and the primary tumor is only fibrous scarring and/or inflammation, this does not indicate a microsatellite, because the aforementioned changes may represent regression of the intervening tumor (but not separated only by fibrosis or inflammation because the features could signify regression of the intervening tumor). There is no minimum size threshold or distance from the primary tumor to define a microsatellite. Before diagnosing the presence of a microsatellite, it is generally recommended that multiple sections from the same tissue block being examined to verify that the microsatellite is indeed discontinuous from the primary tumor. For example, periadnexal extension of tumor or the irregular shape of the peripheral or deep extent of the tumor may result in tumor that is contiguous with the primary tumor appear discontinuous on single sections.

#### References

1. Gershenwald JE, Scolyer RA, Hess KR, et al. Melanoma of the skin, In: Amin MB, Edge SB, Greene FL, et al. eds. AJCC Cancer Staging Manual. 8th ed. New York, NY: Springer; 2017.

#### **K. Lymphovascular Invasion**

Lymphovascular invasion is identified by the demonstration of melanoma cells within the lumina of blood vessels or lymphatics, or both.<sup>1</sup> Immunohistochemistry for vascular endothelial cell markers CD31, CD34 or ERG or the lymphatic marker D2-40 may assist in the identification of the presence of intravascular or intralymphatic tumor by highlighting vascular lumina. Vascular invasion by melanoma correlates independently with worsened overall survival.<sup>2</sup> The detection of LVI is increased in primary melanomas when double labeling of tumor cells and lymphatic endothelium is applied.<sup>3</sup>

#### References

1. Gershenwald JE, Scolyer RA, Hess KR, et al. Melanoma of the skin, In: Amin MB, Edge SB, Greene FL, et al. eds. AJCC Cancer Staging Manual. 8th ed. New York, NY: Springer; 2017.
2. Petersson F, Diwan AH, Ivan D, Gershenwald JE, Johnson MM, Harrell R, Prieto VG. Immunohistochemical detection of lymphovascular invasion with D2-40 in melanoma correlates with sentinel lymph node status, metastasis and survival. *J Cutan Pathol.* 2009;36(11):1157-1163.
3. Feldmeyer L, Tetzlaff M, Fox P, et al. Prognostic Implication of Lymphovascular Invasion Detected by Double Immunostaining for D2-40 and MITF1 in Primary Cutaneous Melanoma. *Am J Dermatopathol.* 2016;38(7):484-491.

#### **L. Neurotropism**

Neurotropism is defined as the presence of melanoma cells abutting nerve sheaths usually circumferentially (perineural invasion) or within nerves (intra-neural invasion).<sup>1</sup> Occasionally, the tumor itself may form

neuroid structures (termed 'neural transformation' and this is also regarded as neurotropism). Neurotropism is best identified at the periphery of the tumor; the presence of melanoma cells around nerves in the main tumor mass caused by "entrapment" of nerves in the expanding tumor does not represent neurotropism.

Neurotropism is most commonly identified in desmoplastic melanomas (sometimes termed desmoplastic neurotropic melanoma) but may occur in any melanoma subtype.<sup>2</sup> Neurotropism may correlate with an increased risk for local recurrence.

#### References

1. Gershenwald JE, Scolyer RA, Hess KR, et al. Melanoma of the skin, In: Amin MB, Edge SB, Greene FL, et al. eds. AJCC Cancer Staging Manual. 8th ed. New York, NY: Springer; 2017.
2. Elder DE, Massi D, Scolyer RA, Willemze R. eds. WHO Classification of Skin Tumors. World Health Organization of Tumors, 4th ed Volume 11. Lyon France; 2018, ISBN-13 978-92-832-2440-2.

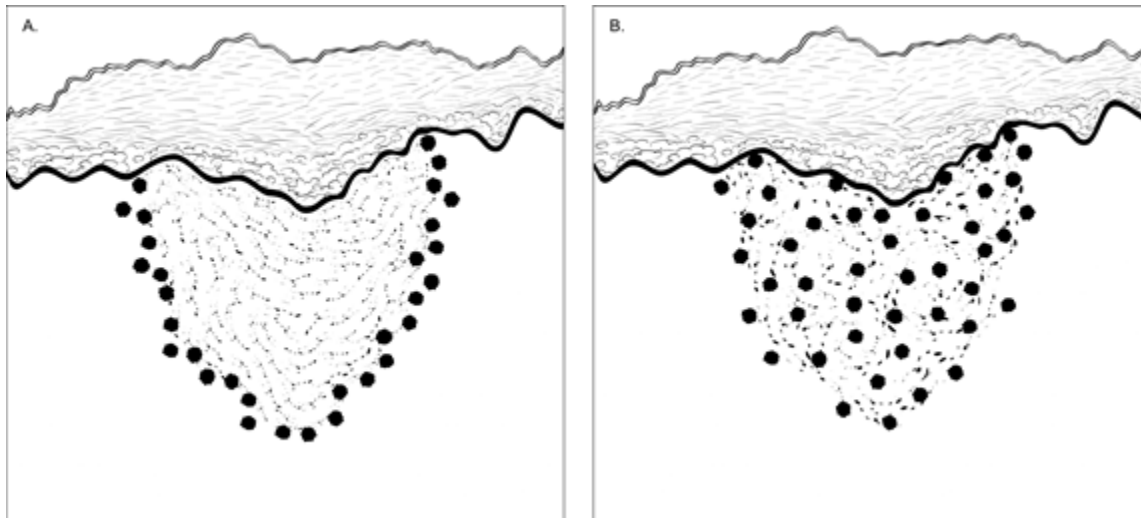
#### M. Tumor-Infiltrating Lymphocytes

A paucity of tumor-infiltrating lymphocytes (TILs) is an adverse prognostic factor for cutaneous melanoma.<sup>1</sup> Tumor-infiltrating lymphocytes may be assessed in a semiquantitative way, as defined below. To qualify as TILs, lymphocytes need to surround and disrupt tumor cells of the invasive component of the tumor.

TILs Not Identified: No lymphocytes present, or lymphocytes present but do not infiltrate tumor at all.

TILs Nonbrisk: Lymphocytes infiltrate melanoma only focally or not along the entire base of the invasive tumor.

TILs Brisk: Lymphocytes diffusely infiltrate the entire base of the invasive tumor (Figure 1, A) or show diffuse permeation of the invasive tumor (Figure 1, B).



**Figure 1.** Brisk tumor-infiltrating lymphocytes. A. Lymphocytes diffusely infiltrate the entire base of the invasive tumor. B. Lymphocytes diffusely infiltrate the entire invasive component of the melanoma.

## References

1. Crowson AN, Magro CM, Mihm MC. Prognosticators of melanoma, the melanoma report, and the sentinel lymph node. *Mod Pathol.* 2006;19(Suppl 2):S71-87.

## N. Regional Lymph Nodes

Removal of sentinel lymph nodes may be performed for patients with clinically localized primary cutaneous melanomas with a thickness of 1 mm or greater, or in selected patients with thinner tumors with other adverse prognostic features.<sup>1,2</sup> Frozen section analysis of sentinel lymph nodes is not advised.<sup>1</sup> Review of the H&E-stained slides from multiple levels through serially sliced sentinel lymph nodes increases the sensitivity of detecting microscopic melanoma metastasis; routine analysis (H&E-stained sections of the cut surfaces of a simply bisected lymph node) may lead to a false-negative rate of 10%-15%. The use of immunohistochemical stains (eg, for HMB-45 or MART-1) further increases the sensitivity of detection of microscopic melanoma metastases and should also be considered in the examination of sentinel lymph nodes. Although immunohistochemical staining should be used in conjunction with and not in place of standard H&E histologic examination, immunohistochemically identified micrometastases are accepted as representing greater than N0 disease by the 8<sup>th</sup> edition of the AJCC staging system (as in the 7<sup>th</sup> edition), ie, a lymph node in which any metastatic tumor cells are identified, irrespective of the number of cells or whether they were identified on H&E or immunostained sections, should be designated as a tumor-positive node.<sup>2</sup>

For histologic examination, whether for sentinel node analysis or for routine regional lymph node evaluation, the entire node, except tissue collected for consented research protocols, should be submitted. For routine evaluation, large lymph nodes may be bisected or sliced at 2-3 mm intervals, whereas smaller nodes (less than 5 mm) may be submitted whole.

Data from multiple studies<sup>3,4,5</sup> indicated that the sentinel lymph node tumor burden and/or the microanatomical region/compartiment of the sentinel node occupied by the metastasis may be useful in predicting patients who have additional disease in nonsentinel nodes as well as disease outcome. Because sentinel node tumor burden is considered a regional disease prognostic factor, it should be reported in all patients with a positive sentinel node but it is not used to determine N-category groupings in the 8<sup>th</sup> edition of the AJCC staging system. The current National Comprehensive Cancer Network (NCCN) guidelines<sup>6</sup> also recommend recording the size and location of tumor present in a positive sentinel node.

## References

1. Scolyer RA, Thompson JF, McCarthy SW, Gershenwald JE, Ross MI, Cochran AJ. Intraoperative frozen-section evaluation can reduce accuracy of pathologic assessment of sentinel nodes in melanoma patients. *J Am Coll Surg.* 2005;201(5):821-823; author reply 823-824.
2. Gershenwald JE, Scolyer RA, Hess KR, et al. Melanoma of the skin, In: Amin MB, Edge SB, Greene FL, et al. eds. *AJCC Cancer Staging Manual.* 8th ed. New York, NY: Springer; 2017.
3. Gershenwald JE, Andtbacka RH, Prieto VG, et al. Microscopic tumor burden in sentinel lymph nodes predicts synchronous nonsentinel lymph node involvement in patients with melanoma. *J Clin Oncol.* 2008;26(26):4296-4303.
4. van Akkooi AC, Nowecki ZI, Voit C, et al. Sentinel node tumor burden according to the Rotterdam criteria is the most important prognostic factor for survival in melanoma patients: a multicenter study in 388 patients with positive sentinel nodes. *Ann Surg.* 2008;248(6):949-955.
5. Dewar DJ, Newell B, Green MA, Topping AP, Powell BW, Cook MG. The microanatomic location of metastatic melanoma in sentinel lymph nodes predicts nonsentinel lymph node involvement. *J Clin Oncol.* 2004;22(16):3345-3349.
6. Coit DG, Andtbacka R, Bichakjian CK, et al. Melanoma. *J Natl Compr Canc Netw.* 2009;7(3):250-275.