



Protocol for the Examination of Specimens From Patients With Carcinoma and Carcinosarcoma of the Endometrium

Version: 4.3.0.0

Protocol Posting Date: June 2022

CAP Laboratory Accreditation Program Protocol Required Use Date: March 2023

The changes included in this current protocol version affect accreditation requirements. The new deadline for implementing this protocol version is reflected in the above accreditation date.

For accreditation purposes, this protocol should be used for the following procedures AND tumor types:

Procedure	Description
Hysterectomy	
Tumor Type	Description
Carcinoma	Includes carcinomas, carcinosarcomas (malignant mixed Müllerian tumor) and neuroendocrine carcinomas arising in the endometrium

This protocol is NOT required for accreditation purposes for the following:

Procedure
Endometrial biopsy
Endometrial curettage
Primary resection specimen with no residual cancer (eg, following previous biopsy or curettage)
Cytologic specimens

The following tumor types should NOT be reported using this protocol

Tumor Type
Carcinomas arising in the uterine cervix (consider the Uterine Cervix protocol)
Uterine sarcoma, including adenosarcoma (consider the Uterine Sarcoma protocol)
Lymphoma (consider the Hodgkin or non-Hodgkin Lymphoma protocols)

Authors

Uma G. Krishnamurti, MD, PhD*; Barbara A. Crothers, DO*.

With guidance from the CAP Cancer and CAP Pathology Electronic Reporting Committees.

* Denotes primary author.

Accreditation Requirements

This protocol can be utilized for a variety of procedures and tumor types for clinical care purposes. For accreditation purposes, only the definitive primary cancer resection specimen is required to have the core and conditional data elements reported in a synoptic format.

- Core data elements are required in reports to adequately describe appropriate malignancies. For accreditation purposes, essential data elements must be reported in all instances, even if the response is “not applicable” or “cannot be determined.”
- Conditional data elements are only required to be reported if applicable as delineated in the protocol. For instance, the total number of lymph nodes examined must be reported, but only if nodes are present in the specimen.
- Optional data elements are identified with “+” and although not required for CAP accreditation purposes, may be considered for reporting as determined by local practice standards.

The use of this protocol is not required for recurrent tumors or for metastatic tumors that are resected at a different time than the primary tumor. Use of this protocol is also not required for pathology reviews performed at a second institution (ie, secondary consultation, second opinion, or review of outside case at second institution).

Synoptic Reporting

All core and conditionally required data elements outlined on the surgical case summary from this cancer protocol must be displayed in synoptic report format. Synoptic format is defined as:

- Data element: followed by its answer (response), outline format without the paired Data element: Response format is NOT considered synoptic.
- The data element should be represented in the report as it is listed in the case summary. The response for any data element may be modified from those listed in the case summary, including “Cannot be determined” if appropriate.
- Each diagnostic parameter pair (Data element: Response) is listed on a separate line or in a tabular format to achieve visual separation. The following exceptions are allowed to be listed on one line:
 - Anatomic site or specimen, laterality, and procedure
 - Pathologic Stage Classification (pTNM) elements
 - Negative margins, as long as all negative margins are specifically enumerated where applicable
- The synoptic portion of the report can appear in the diagnosis section of the pathology report, at the end of the report or in a separate section, but all Data element: Responses must be listed together in one location

Organizations and pathologists may choose to list the required elements in any order, use additional methods in order to enhance or achieve visual separation, or add optional items within the synoptic report. The report may have required elements in a summary format elsewhere in the report IN ADDITION TO but not as replacement for the synoptic report ie, all required elements must be in the synoptic portion of the report in the format defined above.

Summary of Changes

v 4.3.0.0

- Deleted Tumor Modifier question and combined answer list with TNM Descriptors question

Reporting Template**Protocol Posting Date: June 2022****Select a single response unless otherwise indicated.****CASE SUMMARY: (ENDOMETRIUM)****Standard(s):** AJCC-UICC 8, FIGO Cancer Report 2018**CLINICAL****+Clinical History (Note [A](#)) (select all that apply)** Lynch syndrome Other (specify): _____**SPECIMEN (Note [B](#))****Procedure (select all that apply)***For information about lymph node sampling, please refer to the Regional Lymph Node section.* Total hysterectomy and bilateral salpingo-oophorectomy Radical hysterectomy Simple hysterectomy Supracervical hysterectomy Bilateral salpingo-oophorectomy Right salpingo-oophorectomy Left salpingo-oophorectomy Salpingo-oophorectomy, side not specified Right oophorectomy Left oophorectomy Oophorectomy, side not specified Bilateral salpingectomy Right salpingectomy Left salpingectomy Salpingectomy, side not specified Vaginal cuff resection Omentectomy Peritoneal biopsy(ies) Peritoneal washing Other (specify): _____**+Hysterectomy Type** Abdominal Vaginal Vaginal, laparoscopic-assisted Laparoscopic Laparoscopic, robotic-assisted Other (specify): _____ Not specified

+Specimen Integrity

- Intact
- Opened
- Morcellated
- Other (specify): _____

TUMOR

+Tumor Site (select all that apply)

- Endometrium: _____
- Lower uterine segment: _____
- Endometrial polyp: _____
- Other (specify): _____
- Cannot be determined: _____

+Tumor Size

- Greatest dimension in Centimeters (cm): _____ cm
- +Additional Dimension in Centimeters (cm): ____ x ____ cm**
- Cannot be determined (explain): _____

Histologic Type (Note C)

- Endometrioid carcinoma, NOS
 - POLE-ultramutated endometrioid carcinoma
 - Mismatch repair-deficient endometrioid carcinoma
 - p53-mutant endometrioid carcinoma
 - No specific molecular profile (NSMP) endometrioid carcinoma
- Serous carcinoma
- Carcinosarcoma
- Mucinous carcinoma, intestinal type
- Clear cell adenocarcinoma, NOS
- Small cell neuroendocrine carcinoma
- Large cell neuroendocrine carcinoma
- Mixed neuroendocrine non-neuroendocrine carcinoma
- Mixed cell adenocarcinoma (specify types and percentages): _____
- Dedifferentiated carcinoma
- Undifferentiated carcinoma, NOS
- Mesonephric adenocarcinoma
- Squamous cell carcinoma, NOS
- Mesonephric-like adenocarcinoma
- Other histologic type not listed (specify): _____

+Histologic Type Comment: _____

Histologic Grade# (Note D)

International Federation of Gynecology and Obstetrics (FIGO) Grading System applies to endometrioid and mucinous carcinomas only. Serous, clear cell, transitional, small cell and large cell neuroendocrine carcinomas, undifferentiated / dedifferentiated carcinomas, and carcinosarcomas are generally considered to be high grade and it is not recommended to assign a histologic grade to these tumor types.

- FIGO grade 1
- FIGO grade 2
- FIGO grade 3
- Other (specify): _____
- Cannot be assessed (explain): _____
- Not applicable

+Two-Tier Grading System (for endometrioid carcinomas only)

- Low grade (encompassing FIGO 1 and 2)
- High grade (FIGO 3)
- Other (specify): _____
- Cannot be assessed: _____
- Not applicable

Myometrial Invasion (Note E)

- Not identified
- Present

Depth of Myometrial Invasion

- Specify in Millimeters (mm): _____ mm
- Other (specify): _____
- Cannot be determined (explain): _____

Myometrial Thickness

- Specify in Millimeters (mm): _____ mm
- Other (specify): _____
- Cannot be determined (explain): _____

Percentage of Myometrial Invasion

- Specify Percentage: _____ %
- Estimated to be less than 50%
- Estimated to be 50% or greater
- Cannot be determined (explain): _____
- Cannot be determined (explain): _____
- Not applicable

+Adenomyosis

- Not identified
- Present, uninvolved by carcinoma
- Present, involved by carcinoma
- Cannot be determined: _____

Uterine Serosa Involvement

- Not identified
- Present
- Cannot be determined (explain): _____

+Lower Uterine Segment Involvement (Note F)

- Not identified
- Present, superficial (non-myoinvasive)
- Present, myoinvasive
- Present: _____
- Cannot be determined (explain): _____

Cervical Stroma Involvement (Note G)

- Not identified
- Present
- +Depth of Cervical Stroma Invasion**
- Specify in Millimeters (mm): _____ mm
- Other (specify): _____
- Cannot be determined: _____
- +Cervical Stroma Thickness**
- Specify in Millimeters (mm): _____ mm
- Other (specify): _____
- Cannot be determined: _____
- Cannot be determined (explain): _____
- Not applicable

Other Tissue / Organ Involvement# (select all that apply)

Any organ not selected is either not involved or was not submitted.

- Not applicable
- Not identified
- Right ovary
- Left ovary
- Ovary (side not specified)
- Right fallopian tube
- Left fallopian tube
- Fallopian tube (side not specified)
- Vagina
- Right parametrium
- Left parametrium
- Parametrium (side not specified)
- Pelvic wall
- Bladder wall
- Bladder mucosa##
- Rectal wall
- Bowel mucosa##
- Other organs / tissue (specify): _____
- Cannot be determined (explain): _____

Tumor must involve the mucosal surface

Peritoneal / Ascitic Fluid (Note H)

- Not submitted / unknown
- Malignant cells not identified
- # Borderline tumor cells in fluids are classified as "atypia of undetermined significance"; if malignancy cannot be excluded, cells are classified as "suspicious for malignancy".*
- Atypical# (explain): _____
- Suspicious# (explain): _____
- Malignant cells present
- Cannot be determined: _____
- Results pending

Lymphovascular Invasion (LVI) (Note I)

- Not identified
- Present
 - Low (less than 3 vessel involvement) (specify location, if possible): _____
 - Extensive (greater than or equal to 3 vessel involvement) (specify location, if possible): _____
- Equivocal (explain): _____
- Cannot be determined: _____

+Tumor Comment: _____

MARGINS (Note J)

Margin Status

Margin section is required only if cervix and / or parametrium / paracervix is involved by carcinoma.

- Not applicable
- All margins negative for invasive carcinoma

+Closest Margin(s) to Invasive Carcinoma (select all that apply)

- Ectocervical / vaginal cuff (specify location, if possible): _____
- Parametrial / paracervical (specify location, if possible): _____
- Other (specify): _____
- Cannot be determined: _____

+Distance from Invasive Carcinoma to Closest Margin

Specify in Millimeters (mm)

- Exact distance: _____ mm
- Greater than: _____ mm
- At least: _____ mm
- Less than: _____ mm
- Less than 1 mm
- Other (specify): _____
- Cannot be determined: _____

Invasive carcinoma present at margin

Margin(s) Involved by Invasive Carcinoma (select all that apply)

- Ectocervical / vaginal cuff (specify location, if possible): _____
- Parametrial / paracervical (specify location, if possible): _____
- Other (specify): _____
- Cannot be determined: _____

___ Other (specify): _____
___ Cannot be determined (explain): _____

+Margin Comment: _____

REGIONAL LYMPH NODES

Regional Lymph Node Status#

Lymph nodes designated as pelvic (parametrial, obturator, internal iliac (hypogastric), external iliac, common iliac, sacral, presacral) and para-aortic are considered regional lymph nodes. Any other involved nodes should be categorized as metastases (pM1) and reported in the distant metastasis section. Presence of isolated tumor cells no greater than 0.2 mm in regional lymph node(s) is considered N0 (i+).

___ Not applicable (no regional lymph nodes submitted or found)
___ Regional lymph nodes present
___ All regional lymph nodes negative for tumor cells
___ Tumor present in pelvic lymph node(s)

Macrometastases (greater than 2 mm), Micrometastases (greater than 0.2 mm to 2 mm), Isolated Tumor Cells (ITC: less than or equal to 0.2 mm or single cells or clusters of cells less than or equal to 200 cells in a single lymph node cross section). If pelvic and / or para-aortic lymph nodes are submitted and positive for tumor cells, reporting the number of nodes with or without macrometastases and micrometastases is required. Reporting isolated tumor cells is required only in the absence of macrometastasis or micrometastasis.

Pelvic Lymph Nodes (required only if present)

Total Number of Pelvic Nodes with Macrometastasis (greater than 2 mm) (sentinel and non-sentinel)

___ Exact number: _____
___ At least: _____
___ Other (specify): _____
___ Cannot be determined (explain): _____

+Number of Pelvic Sentinel Nodes with Macrometastasis

___ Exact number: _____
___ At least: _____
___ Other (specify): _____
___ Cannot be determined (explain): _____

Total Number of Pelvic Nodes with Micrometastasis (greater than 0.2 mm up to 2 mm and/or greater than 200 cells) (sentinel and non-sentinel)

___ Exact number: _____
___ At least: _____
___ Other (specify): _____
___ Cannot be determined (explain): _____

+Number of Pelvic Sentinel Nodes with Micrometastasis

___ Exact number: _____
___ At least: _____
___ Other (specify): _____
___ Cannot be determined (explain): _____

Total Number of Pelvic Nodes with Isolated Tumor Cells# (0.2 mm or less and not more than 200 cells)

Reporting the number of lymph nodes with isolated tumor cells is required only in the absence of macrometastasis or micrometastasis in other lymph nodes.

- Not applicable
- Exact number: _____
- At least: _____
- Other (specify): _____
- Cannot be determined (explain): _____

+Number of Pelvic Sentinel Nodes with ITCs

- Exact number: _____
- At least: _____
- Other (specify): _____
- Cannot be determined (explain): _____

Laterality of Pelvic Node(s) with Tumor (select all that apply)

- Right sentinel: _____
- Right non-sentinel: _____
- Left sentinel: _____
- Left non-sentinel: _____
- Cannot be determined: _____
- Not applicable

+Size of Largest Pelvic Nodal Metastatic Deposit

Specify in Millimeters (mm)

- Specify exact size: _____ mm
- Less than: _____ mm
- Greater than: _____ mm
- Other (specify): _____
- Cannot be determined (explain): _____

Tumor present in para-aortic lymph node(s)

Para-aortic Nodes (required only if present)

Total Number of Para-aortic Nodes with Macrometastasis (greater than 2 mm) (sentinel and non-sentinel)

- Exact number: _____
- At least: _____
- Other (specify): _____
- Cannot be determined (explain): _____
- Not applicable

+Number of Para-aortic Sentinel Nodes with Macrometastasis

- Exact number: _____
- At least: _____
- Other (specify): _____
- Cannot be determined (explain): _____

Total Number of Para-aortic Nodes with Micrometastasis (greater than 0.2 mm up to 2 mm and/or greater than 200 cells) (sentinel and non-sentinel)

- Exact number: _____
- At least: _____
- Cannot be determined (explain): _____
- Not applicable

+Number of Para-aortic Sentinel Nodes with Micrometastasis

- Exact number: _____
- At least: _____
- Other (specify): _____
- Cannot be determined (explain): _____

Total Number of Para-aortic Nodes with Isolated Tumor Cells# (0.2 mm or less and not more than 200 cells)

Reporting the number of lymph nodes with isolated tumor cells is required only in the absence of macrometastasis or micrometastasis in other lymph nodes.

- Not applicable
- Exact number: _____
- At least: _____
- Cannot be determined (explain): _____

+Number of Para-aortic Sentinel Nodes with ITCs

- Exact number: _____
- At least: _____
- Other (specify): _____
- Cannot be determined (explain): _____

Laterality of Para-aortic Node(s) with Tumor (select all that apply)

- Right sentinel: _____
- Right non-sentinel: _____
- Left sentinel: _____
- Left non-sentinel: _____
- Cannot be determined: _____
- Not applicable

+Size of Largest Para-aortic Nodal Metastatic Deposit

Specify in Millimeters (mm)

- Specify exact size: _____ mm
- Less than: _____ mm
- Greater than: _____ mm
- Other (specify): _____
- Cannot be determined (explain): _____
- Other (specify): _____
- Cannot be determined (explain): _____

Lymph Nodes Examined

Total Number of Pelvic Nodes Examined (sentinel and non-sentinel)

- Exact number: _____
- At least: _____
- Other (specify): _____
- Cannot be determined (explain): _____

Number of Pelvic Sentinel Nodes Examined

- Not applicable
- Exact number: _____
- At least: _____
- Other (specify): _____
- Cannot be determined (explain): _____

Total Number of Para-aortic Nodes Examined (sentinel and non-sentinel)

- Exact number: _____

- At least: _____
 Other (specify): _____
 Cannot be determined (explain): _____

Number of Para-aortic Sentinel Nodes Examined

- Not applicable
 Exact number: _____
 At least: _____
 Other (specify): _____
 Cannot be determined (explain): _____

+Regional Lymph Node Comment: _____

DISTANT METASTASIS

Distant Site(s) Involved, if applicable# (select all that apply)

This excludes metastasis to pelvic or para-aortic lymph nodes, vagina, uterine serosa, or adnexa

- Not applicable
 Inguinal lymph node(s): _____
 Omentum: _____
 Extrapelvic peritoneum: _____
 Lung: _____
 Liver: _____
 Bone: _____
 Other (specify): _____
 Cannot be determined: _____

PATHOLOGIC STAGE CLASSIFICATION (pTNM, AJCC 8th Edition) (Note [K](#))

Reporting of pT, pN, and (when applicable) pM categories is based on information available to the pathologist at the time the report is issued. As per the AJCC (Chapter 1, 8th Ed.), it is the managing physician's responsibility to establish the final pathologic stage based upon all pertinent information, including but potentially not limited to this pathology report.

TNM Descriptors (select all that apply)

- Not applicable: _____
 m (multiple)
 r (recurrent)
 y (post-treatment)

pT Category

- pT not assigned (cannot be determined based on available pathological information)
 pT0: No evidence of primary tumor
pT1: Tumor confined to the corpus uteri, including endocervical glandular involvement
 pT1a: Tumor limited to endometrium or invading less than half the myometrium
 pT1b: Tumor invading one half or more of the myometrium
 pT1 (subcategory cannot be determined)
 pT2: Tumor invading the stromal connective tissue of the cervix but not extending beyond the uterus.
 Does NOT include only endocervical glandular involvement.
pT3: Tumor involving serosa, adnexa, vagina, or parametrium
 pT3a: Tumor involving serosa and / or adnexa (direct extension or metastasis)
 pT3b: Vaginal involvement (direct extension or metastasis) or parametrial involvement

___ pT3 (subcategory cannot be determined)

___ pT4: Tumor invading bladder mucosa and / or bowel mucosa (bullous edema is not sufficient to classify a tumor as T4)#

Tumor must involve the mucosal surface

Regional Lymph Nodes Modifier

Suffix (sn) is added to the N category when metastasis is identified only by sentinel lymph node biopsy. If after a sentinel node biopsy, the patient then undergoes a complete lymph node dissection, the (sn) suffix is not used.

___ Not applicable

___ (sn)

pN Category

___ pN not assigned (no nodes submitted or found)

___ pN not assigned (cannot be determined based on available pathological information)

___ pN0: No regional lymph node metastasis

___ pN0(i+): Isolated tumor cells in regional lymph node(s) no greater than 0.2 mm

pN1: Regional lymph node metastasis to pelvic lymph nodes

Even one metastasis greater than 2.0 mm would qualify the classification as pN1a and pN2a.

___ pN1mi: Regional lymph node metastasis (greater than 0.2 mm but not greater than 2.0 mm in diameter) to pelvic lymph nodes#

___ pN1a: Regional lymph node metastasis (greater than 2.0 mm in diameter) to pelvic lymph nodes

___ pN1 (subcategory cannot be determined)

pN2: Regional lymph node metastasis to para-aortic lymph nodes, with or without positive pelvic lymph nodes

___ pN2mi: Regional lymph node metastasis (greater than 0.2 mm but not greater than 2.0 mm in diameter) to para-aortic lymph nodes, with or without positive pelvic lymph nodes#

___ pN2a: Regional lymph node metastasis (greater than 2.0 mm in diameter) to para-aortic lymph nodes, with or without positive pelvic lymph nodes

___ pN2 (subcategory cannot be determined)

pM Category

___ Not applicable - pM cannot be determined from the submitted specimen(s)

___ pM1: Distant metastasis (includes metastasis to inguinal lymph nodes, intraperitoneal disease, lung, liver, or bone. It excludes metastasis to pelvic or para-aortic lymph nodes, vagina, uterine serosa, or adnexa)

FIGO STAGE

+FIGO Stage (2018 FIGO Cancer Report)

- I: Tumor confined to the corpus uteri
- IA: No or less than half myometrial invasion
- IB: Invasion equal to or more than half of the myometrium
- II: Tumor invades cervical stroma, but does not extend beyond the uterus
- III: Local and / or regional spread of the tumor
- IIIA: Tumor invades the serosa of the corpus uteri and / or adnexae
- IIIB: Vaginal and / or parametrial involvement
- IIIC: Metastases to pelvic and / or para-aortic lymph nodes
- IIIC1: Positive pelvic nodes
- IIIC2: Positive para-aortic nodes with or without positive pelvic lymph nodes
- IV: Tumor invades bladder and / or bowel mucosa, and / or distant metastases
- IVA: Tumor invasion of bladder and / or bowel mucosa
- IVB: Distant metastasis, including intra-abdominal metastases and / or inguinal nodes

ADDITIONAL FINDINGS (Note [L](#))

+Additional Findings (select all that apply)

- None identified
- Atypical hyperplasia / endometrial intraepithelial neoplasia (EIN)
- Other (specify): _____

SPECIAL STUDIES

For reporting molecular testing, immunohistochemistry, and other cancer biomarker testing results, the CAP endometrium biomarker template should be used. Pending biomarker studies should be listed in the Comments section of this report.

COMMENTS

Comment(s): _____

Explanatory Notes

A. Clinical History and Biomarker Testing

Colon carcinoma is the most common malignancy in hereditary nonpolyposis colon cancer [HNPCC; Lynch syndrome (LS)], which is caused by germline mutations in DNA mismatch repair genes (MLH1, MLH2, MLH6, and PMS2). However, endometrial carcinoma develops before colon carcinoma in >50% of women with HNPCC.^{1,2,3,4} 3% to 5% of endometrial carcinomas can be attributed to Lynch syndrome (LS). Patients with LS have a 40-60% lifetime risk for endometrial and colon cancer.⁵ Histopathologic features suggestive of HNPCC/LS-related carcinoma are well characterized in the colon, but not as well in the uterus. While lower uterine segment tumors and high grade tumors in the endometrium seem to have a higher rate of being LS-associated tumors, tumor morphology and anatomic location of tumor cannot be used to select patients for screening for LS. Many LS-associated endometrial carcinomas are seen in probands that do not meet Bethesda or Amsterdam personal/family history criteria for Lynch Syndrome. However, when examining an endometrial carcinoma in a patient under 50 years of age or with a personal or family history of colon carcinoma, it is important to consider the possibility of an HNPCC/LS-related endometrial carcinoma.

According to the NCCN guidelines, there should be universal testing of endometrial carcinomas for mismatch repair (MMR) proteins/microsatellite instability (MSI). This can be tested on the hysterectomy specimen or the pre-surgical biopsy. Testing for defective DNA mismatch repair proteins by immunohistochemistry is the most cost-effective method (MLH1, MSH2, MSH6, and PMS2 antibodies are commercially available).⁶ Loss of MSH2 or MSH6 expression essentially always indicates Lynch syndrome. HNPCC/LS-related endometrial carcinoma is predominantly associated with MSH2 mutations and MSH6 mutations.^{1,2,3,4} PMS2 loss is often associated with loss of MLH1 and is only independently meaningful if MLH1 is intact. MLH1 hypermethylation analysis should be completed on tumors that show loss of MLH1 on IHC to help triage appropriate cases for germline testing. There should be genetic counseling and testing for all other MMR abnormalities. PCR assays can be used to detect high levels of microsatellite alterations (MSI), a condition that is definitional for defective DNA mismatch repair. This testing is performed on paraffin-embedded tissue and compares the results of tumor DNA to those of non-neoplastic tissues from the same patient.

In addition, Estrogen receptor (ER) testing is recommended for stage III, IV, and recurrent disease and may be requested by the treating clinician in order to predict response to endocrine therapy. HER2 immunohistochemistry (with reflex test to HER2 FISH for equivocal IHC) should be considered for serous endometrial cancer. Please refer to the CAP endometrial cancer biomarker reporting template on www.cap.org/cancerprotocols for further details.

References

1. Aarnio M, Sankila R, Pukkala E, Salovaara R, Aaltonen LA, de la Chapelle A, Peltomäki P, Mecklin JP, Järvinen HJ. Cancer risk in mutation carriers of DNA-mismatch-repair genes. *Int J Cancer*. 1999;81:214-218.
2. Watson P, Vasen HF, Mecklin JP, Järvinen H, Lynch HT. The risk of endometrial cancer in hereditary nonpolyposis colorectal cancer. *Am J Med*. 1994;96:516-520.
3. Wijnen J, de Leeuw W, Vasen H, et al. Familial endometrial cancer in female carriers of MSH6 germline mutations. *Nat Genet*. 1999;23:142-144.
4. Charames GS, Millar AL, Pal T, Narod S, Bapat B. Do MSH6 mutations contribute to double primary cancers of the colorectum and endometrium? *Hum Genet*. 2000;107:623-629.

5. Cho KR, Cooper K, Croce S: International Society of Gynecological Pathologists (ISGyP): Guidelines from the special techniques and ancillary studies group. *Int J Gynecol Pathol*. 2019; 38(suppl 1):S114-122.
6. Mills AM, Liou S, Ford JM, Berek JS, Pai RK, Longacre TA. Lynch syndrome screening should be considered for all patients with newly diagnosed endometrial cancer. *Am J Surg Pathol*. 2014;38:1501-1509.

B. Specimen Type

In rare occasions when an endometrial carcinoma is not suspected, the pathologist may receive a supracervical hysterectomy specimen removed by laparoscopy. It has been reported that hysterectomies performed using certain laparoscopic techniques result in the finding of venous tumor emboli that are likely to be iatrogenic.¹ The FDA discourages morcellation for removal of uterus in women with suspected or known uterine cancer because there is risk of spreading tumor cells to the pelvis and peritoneal cavity. Therefore, if applicable, reporting of such a procedure is recommended (and listed under Specimen Integrity in the case summary).

References

1. Logani S, Herdman AV, Little JV, Moller KA. Vascular 'pseudo invasion' in laparoscopic hysterectomy specimens: a diagnostic pitfall. *Am J Surg Pathol*. 2008;32:560-565.

C. Histologic Type

Endometrial endometrioid carcinoma (EEC) displays varying proportions of glandular, papillary, and solid architecture, with the malignant cells showing endometrioid differentiation.¹ There are four molecular subtypes: POLE-ultramutated endometrioid carcinoma, mismatch repair-deficient endometrioid carcinoma, p53-mutant endometrioid carcinoma, and no specific molecular profile (NSMP) endometrioid carcinoma.² For a diagnosis of endometrioid carcinoma it is essential to have invasive endometrial carcinoma with endometrioid differentiation and desirable to have some degree of squamous, secretory, or mucinous differentiation. In high-grade tumors, squamous differentiation strongly favors endometrioid carcinoma over other histological types. Loss of immunoreactivity for ARID1A, PTEN, or one of the mismatch repair proteins favors high-grade EEC. Abnormal p53 expression is reported in 2–5% of low-grade and 20% of high-grade EECs.¹

For a diagnosis of serous carcinoma, it is essential to have a cytologic high-grade endometrial carcinoma with complex papillary and/or glandular architecture and desirable to have abnormal p53 and diffuse p16 immunohistochemistry. The vast majority of serous carcinomas tumors demonstrate TP53 mutations.³ ERBB2 (HER2) amplification is present in 30% of cases, frequently distributed heterogeneously.⁴ In the total cancer genome atlas (TCGA) cohort, all serous carcinomas were within the copy-number-high subgroup.²

To distinguish clear cell carcinoma from histological mimics it is important to adhere to architectural and cytological criteria. An admixture of tubulocystic, papillary, and/or solid patterns with clear to eosinophilic cuboidal, polygonal, hobnail, or flat cells is required. Confirmation by immunoreactivity, usually in the majority of cells, for stains such as HNF1 β , napsin A, and AMACR (P504S) is desirable.

Undifferentiated carcinoma of the endometrium is an epithelial malignancy with no overt cell lineage differentiation. Dedifferentiated carcinoma is composed of an undifferentiated carcinoma and a differentiated component. Almost 40% of monomorphic undifferentiated carcinomas contain a second

component of differentiated carcinoma, which is most frequently a FIGO grade 1 or 2 endometrioid carcinoma. In rare situations, undifferentiated carcinoma may be associated with a high-grade carcinoma (e.g., FIGO grade 3 endometrioid carcinoma and serous carcinoma).^{5,6} A discohesive cell morphology, lack or focal PAX8 positivity by IHC, typically very focal staining for EMA and keratin (particularly CK8/18), and < 10 % reactivity for neuroendocrine markers are features that support a diagnosis of undifferentiated carcinoma. Diffuse strong staining with pan cytokeratin should not be present. Tumor cells express vimentin but not ER, PR, or E-cadherin. Half to two thirds of dedifferentiated and half of undifferentiated carcinomas are mismatch repair–deficient /microsatellite unstable. About one third of endometrial undifferentiated carcinomas show loss of SMARCA4 (BRG1) expression.

Carcinosarcoma is a biphasic tumor composed of high-grade carcinomatous and sarcomatous components. The carcinomatous component most often shows endometrioid or serous differentiation, but clear cell and undifferentiated carcinoma may be encountered. The mesenchymal component most commonly consists of high-grade sarcoma NOS, but heterologous elements (including rhabdomyosarcoma, chondrosarcoma, and rarely osteosarcoma) may be seen.¹

Mixed cell adenocarcinomas are endometrial carcinoma with two distinct histological types, in which at least one component is either serous or clear cell. Any amount of serous or clear cell carcinoma that can be confidently recognized on routine H&E sections in an endometrioid carcinoma qualifies for a mixed carcinoma. These are graded as high-grade carcinoma irrespective of the relative percentages of serous or clear cell carcinoma present. Dedifferentiated carcinoma and carcinosarcoma are not mixed carcinomas. Immunohistochemical demonstration of the two distinct carcinoma types is desirable.¹

Other types: Mesonephric adenocarcinoma is an adenocarcinoma originating from mesonephric remnants. Mesonephric-like adenocarcinoma, a newly described entity, is an adenocarcinoma resembling mesonephric differentiation and limited data suggest an aggressive behavior.^{7,8} Primary squamous carcinoma is a carcinoma with exclusive squamous differentiation. Primary gastric (gastrointestinal)–type mucinous carcinoma is a carcinoma with mucinous gastric/gastrointestinal features. The diagnosis of these rare carcinomas is based on morphology and it is important to exclude an endometrioid component, a cervical origin, (and/or metastasis from the gastrointestinal tract in case of mucinous carcinoma), before rendering these as the histologic type. Small cell and large cell neuroendocrine carcinomas (NEC) account for less than 1% of all gynecological malignancies. Endometrial NEC are typically seen in postmenopausal women and the etiology is unknown. Abnormal mismatch repair protein expression has been described in endometrial SCNECs. In mixed NEC and non-NEC the percentages of individual tumor types should be given.

Stromal invasion, which is defined by loss of intervening stroma (a confluent glandular, cribriform, or labyrinthine pattern), altered fibroblastic stroma (desmoplastic stromal reaction), a complex (mostly villoglandular) or a non-squamous solid architecture distinguishes well differentiated EEC from endometrial atypical hyperplasia / endometrioid intraepithelial neoplasia. It may be difficult to distinguish EEC with mucinous differentiation from atypical mucinous glandular proliferations; cribriform or confluent architecture and cytological atypia are distinguishing features.⁹

References

1. Matias-Guiu X, Oliva E, McCluggage WG, et al. Tumours of the uterine corpus. In: WHO Classification of Tumours Editorial Board. Female genital tumours [Internet]. Lyon (France): International Agency for Research on Cancer; 2020 [cited 2020 Nov 20]. (WHO classification of

tumours series, 5th ed.; vol. 4). Available from: <https://tumourclassification.iarc.who.int/chapters/34>.

2. Cancer Genome Atlas Research Network; Kandoth C, Schultz N, et al. Integrated genomic characterization of endometrial carcinoma. *Nature*. 2013;497:67-73.
3. Schultheis AM, Martelotto LG, De Filippo MR, et al. TP53 mutational spectrum in endometrioid and serous endometrial cancers. *Int J Gynecol Pathol*. 2016;35:289-300.
4. Cuevas D, Velasco A, Vaquero M, et al. Intratumoural heterogeneity in endometrial serous carcinoma assessed by targeted sequencing and multiplex ligation-dependent probe amplification: a descriptive study. *Histopathology*. 2020;76:447-460.
5. Rosa-Rosa JM, Leskelä S, Cristóbal-Lana E, et al. Molecular genetic heterogeneity in undifferentiated endometrial carcinomas. *Mod Pathol*. 2016;29:1390-1398.
6. Hoang LN, Lee Y-S, Karnezis AN, et al. Immunophenotypic features of dedifferentiated endometrial carcinoma - insights from BRG1/INI1-deficient tumours. *Histopathology*. 2016;69:560-569.
7. Kolin DL, Costigan DC, Dong F, et al. A combined morphologic and molecular approach to retrospectively identify KRAS-mutated mesonephric-like adenocarcinomas of the endometrium. *Am J Surg Pathol*. 2019;43:389-398.
8. Euscher ED, Bassett B, Duose DY, et al. Mesonephric-like carcinoma of the endometrium: a subset of endometrial carcinoma with an aggressive behavior. *Am J Surg Pathol*. 2020;44:429-443.
9. Murali R, Davidson B, Fadare O, et al. High-grade endometrial carcinomas: morphologic and immunohistochemical features, diagnostic challenges and recommendations. *Int J Gynecol Pathol*. 2019;38(suppl 1):S40–S63.

D. Histologic Grading

The International Federation of Gynecology and Obstetrics (FIGO) grading system for carcinomas of the uterine corpus is only officially designated for endometrioid carcinomas and is based on architectural features as follows:^{1,2}

Grade 1	5% or less non-squamous solid growth pattern
Grade 2	6% to 50% non-squamous solid growth pattern
Grade 3	>50% non-squamous solid growth pattern

Severe cytologic atypia in the majority of cells (> 50%), which exceeds that which is routinely expected for the architectural grade, increases the tumor grade by 1.^{2,3} Generally, most tumors can be graded on architecture alone; cytologic atypia should be pronounced from a low power.

In addition, the following guidelines should be used in grading:

- (1) The squamous component of endometrioid adenocarcinoma should not be graded because the degree of differentiation typically parallels that of the glandular component.²
- (2) Because mucinous carcinomas are closely related to endometrioid carcinomas, they can be graded by the same criteria. However, FIGO grading should NOT be used when endometrioid or mucinous differentiation is in doubt or cannot be established.³
- (3) Serous, clear cell, transitional, small cell and large cell neuroendocrine carcinomas, undifferentiated/ dedifferentiated carcinomas, and carcinosarcomas are generally considered to be high grade and it is not recommended to assign a FIGO grade to these tumor

types.^{2,3} When the case summary is being completed, these should be designated as “not applicable” for histologic grade.

(4) In mixed carcinomas, the highest grade should be assigned.

References

1. Amant F, Mirza MR, Koskas M. Cancer of the corpus uteri. FIGO Cancer Report 2018. *Int J Gynecol Obstet.* 2018;143(suppl 2):37-50.
2. Matias-Guiu X, Oliva E, McCluggage WG, et al. Tumours of the uterine corpus. In: WHO Classification of Tumours Editorial Board. Female genital tumours [Internet]. Lyon (France): International Agency for Research on Cancer; 2020 [cited 2020 Nov 20]. (WHO classification of tumours series, 5th ed.; vol. 4). Available from: <https://tumourclassification.iarc.who.int/chapters/34>.
3. Soslow RA, Tornos C, Park KJ, et al. Endometrial carcinoma diagnosis: use of FIGO grading and genomic subcategories in clinical practice: recommendations of the International Society of Gynecological Pathologists. *Int J Gynecol Pathol.* 2019;38(suppl 1):S64-74.

E. Myometrial Invasion

Assessing myometrial invasion may be difficult. Depth of invasion should be measured from the endomyometrial junction to the deepest point of invasion, which may not be easy because the endomyometrial junction in normal conditions is often irregular. In these cases, it is always helpful to look for compressed, non-neoplastic endometrial glands at the nearby endomyometrial junction or even at the base of the tumor. Carcinoma involving adenomyosis foci should not be interpreted as invasive carcinoma. However, the distinction between invasive carcinoma and carcinoma involving adenomyosis may be difficult, because in some cases invasive carcinoma may not elicit stromal response. In the absence of adenomyosis uninvolved by tumor in other sections of the specimen, a diagnosis of adenomyosis involved by adenocarcinoma should be made with caution. CD10 staining is not helpful in this differential diagnosis because stromal cells surrounding foci of invasive carcinoma are also frequently CD10 positive. There are no rules for determining how to measure the depth of invasion in the rare cases where myoinvasive carcinoma is only encountered in foci of adenomyosis involved by carcinoma. In such cases, it is advised that the distance from the adenomyotic focus to the deepest area of invasion be measured (Figure 1).¹ Therefore, if there is a tumor with a 2-mm focus of myoinvasion from a focus of adenomyosis in the deep myometrium, it is still considered as having <50% myometrial invasion (FIGO stage IA). In EEC with a MELF (microcystic, elongated and fragmented) pattern of invasion, desmoplasia alone should not be a criteria to measure the depth of invasion. Depth of invasion should be measured as the deepest extent with malignant cells present. LVI should not be used in measuring depth of myometrial invasion; only carcinoma infiltrating the myometrium is to be measured.²

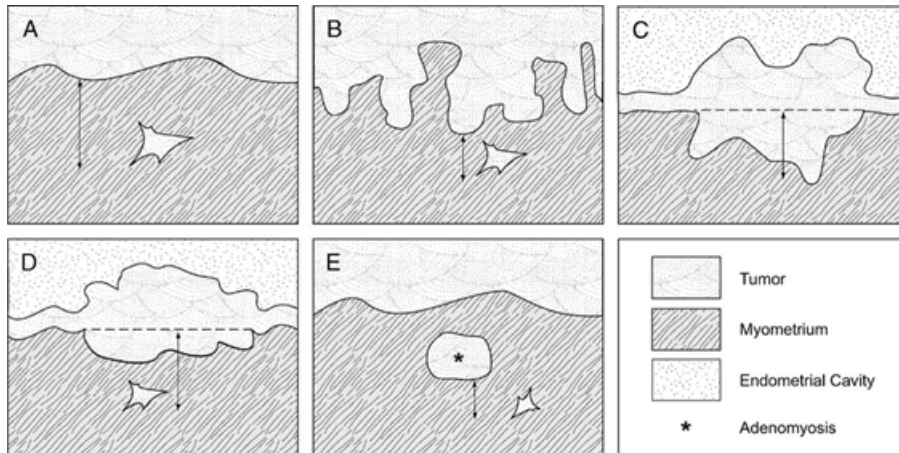


Figure 1. Schematic of measurement of depth of invasion in (A) tumor with a regular interface; (B) tumor with an irregular endomyometrial interface; (C) and (D) tumor with an exophytic growth; (E) tumor arising from adenomyosis. From Ali A, Black D, Soslow RA. Difficulties in assessing the depth of myometrial invasion in endometrial carcinoma. *Int J Gynecol Pathol.* 2007;26:115-123. Copyright © 2007, Wolters Kluwer Health. Reproduced with permission.

References

1. Ali A, Black D, Soslow RA. Difficulties in assessing the depth of myometrial invasion in endometrial carcinoma. *Int J Gynecol Pathol.* 2007;26:115-123.
2. Singh N, Hirschowitz L, Zaino R et al. Pathologic prognostic factors in endometrial carcinoma (other than tumor type and grade). *Int J Gynecol Pathol.* 2019;38(suppl 1):S93-S113.

F. Lower Uterine Segment Involvement

The prevalence of Lynch syndrome in patients with LUS endometrial carcinoma (29%) has been reported to be much greater than that of the general endometrial cancer patient population (1.8%) or in endometrial cancer patients younger than age 50 years (8% to 9%).¹

References

1. Westin SN, Lacour RA, Urbauer DL, et al. Carcinoma of the lower uterine segment: a newly described association with Lynch syndrome. *J Clin Oncol.* 2008;26:5965-5971.

G. Cervical Involvement

The American Joint Committee on Cancer (AJCC)/FIGO staging system considers stage II disease only when cervical stromal involvement is seen. Involvement of the surface endocervical epithelium and/or endocervical glands (by either direct extension or drop metastases) does not have any prognostic significance and is not T2/Stage II.

H. Peritoneal Washings or Ascites Fluid

The prognostic significance of presence of tumor cells in peritoneal washings or ascites fluid is controversial. There are studies that indicate either a worse prognosis or no alteration of prognosis on the basis of positive cytology. Consequently, staging systems no longer utilize positive cytology to alter stage. When collected, however, cytology results should be reported.

I. Lymphovascular Invasion

Presence or absence of LVSI should be recorded in the pathology report. Before diagnosing LVSI, mimics should be excluded, such as retraction, MELF pattern of invasion, and artifactual displacement of tumor cells. Immunohistochemistry is of limited use in the identification of LVSI. The presence of actual tumor emboli within the vessels is required for a diagnosis of LVSI. Studies have shown extensive LVI to be a strong independent prognostic factor for pelvic regional recurrence, distant recurrence, and overall survival. When present, extent of LVSI may be semi-quantified as low (less than 3 vessel involvement) or as extensive (greater than or equal to 3-vessel involvement).^{1,2} The location of LVI (eg, deep myometrial, cervical, adnexal, parametrial, etc.) may allow future studies to assess their significance.³

References

1. Winer I, Ahmed QF, Mert I. Significance of lymphovascular space invasion in uterine serous carcinoma: what matters more; extent or presence? *Int J Gynecol Pathol*. 2015;34:47-56.
2. Bosse T, Peters EE, Creutzberg CL, et al. Substantial lymphovascular space invasion (LVSI) is a significant risk factor for recurrence in endometrial cancer—a pooled analysis of PORTEC 1 and 2 trials. *Eur J Cancer*. 2015;51:1742-50.
3. Singh N, Hirschowitz L, Zaino R, et al. Pathologic prognostic factors in endometrial carcinoma (other than tumor type and grade). *Int J Gynecol Pathol*. 2019;38(suppl 1):S93-S113.

J. Margins

The parametrial/paracervical soft tissue and the vaginal cuff are the only true margins in total hysterectomy specimens. These margins should be reported if the cervix and/or parametrium/paracervix is involved by carcinoma. If not, reporting the status of the vaginal and parametrial margins in a hysterectomy specimen is optional.

K. Pathologic Stage Classification

The TNM staging system for endometrial cancer endorsed by the AJCC and the UICC,^{1,2} and the parallel system formulated by FIGO³ are recommended.

According to AJCC/UICC convention, the designation “T” refers to a primary tumor that has not been previously treated. The symbol “p” refers to the pathologic classification of the TNM, as opposed to the clinical classification, and is based on gross and microscopic examination. pT entails a resection of the primary tumor or biopsy adequate to evaluate the highest pT category, pN entails removal of nodes adequate to validate lymph node metastasis, and pM implies microscopic examination of distant lesions. The referring physician usually carries out clinical classification (cTNM) before treatment during initial evaluation of the patient or when pathologic classification is not possible.

Pathologic staging is usually performed after surgical resection of the primary tumor. Pathologic staging depends on pathologic documentation of the anatomic extent of disease, whether or not the primary tumor has been completely removed. If a biopsied tumor is not resected for any reason (eg, when technically infeasible) and if the highest T and N categories or the M1 category of the tumor can be confirmed microscopically, the criteria for pathologic classification and staging have been satisfied without total removal of the primary cancer.

TNM Descriptors

For identification of special cases of TNM or pTNM classifications, the “m” suffix and “y,” “r,” and “a” prefixes are used. Although they do not affect the stage grouping, they indicate cases needing separate analysis.

The “y” prefix indicates those cases in which classification is performed during or after initial multimodality therapy (ie, neoadjuvant chemotherapy, radiation therapy, or both chemotherapy and radiation therapy). The cTNM or pTNM category is identified by a “y” prefix. The ycTNM or ypTNM categorizes the extent of tumor actually present at the time of that examination. The “y” categorization is not an estimate of tumor before multimodality therapy (ie, before initiation of neoadjuvant therapy).

The “r” prefix indicates a recurrent tumor when staged after a documented disease-free interval and is identified by the “r” prefix: rTNM.

The “a” prefix designates the stage determined at autopsy: aTNM.

T Category Considerations

It is important to note that in endometrial cancer, as in cancer of other organs, the validity of T stage depends upon the adequacy and completeness of the surgical staging.

N Category Considerations

Isolated tumor cells (ITCs) are single cells or small clusters of cells not more than 0.2 mm in greatest dimension. Lymph nodes or distant sites with ITCs found by either histologic examination (eg, immunohistochemical evaluation for cytokeratin) or non-morphological techniques (eg, flow cytometry, DNA analysis, polymerase chain reaction [PCR] amplification of a specific tumor marker) should be so identified. There is currently no guidance in the literature as to how these patients should be coded; until more data are available, they should be coded as “N0(i+)” with a comment noting how the cells were identified.

Sentinel nodes should be sliced at 2.0 mm intervals. The sentinel nodes should undergo ultrastaging; currently, there is no universal ultrastaging protocol. However, all institutions undertaking sentinel lymph node examination should have a standard procedure in place for sentinel lymph nodes. Protocols used at the 2 largest cancer centers in the United States are as follows:

- 1) Memorial Sloan Kettering Cancer Center Protocol:⁴ If the initial H&E-stained slide is negative for carcinoma and the endometrial cancer is myo-invasive or associated with vascular/lymphatic invasion, 2 additional levels at 50 µm apart are examined, at each level 2 slides are obtained, one for H&E and the second for keratin cocktail IHC if the H&E-stained slide is negative.
- 2) The University of Texas M.D. Anderson Cancer Center Protocol:⁵ If the H&E-stained slide is negative for tumor, 3 consecutive sections at 250 µm into the paraffin block are obtained (one for H&E and one of the remaining 2 is to be used for keratin cocktail IHC if the additional H&E-stained slide is negative).

There is little data to assign risk for nonsentinel lymph node metastasis based on the size of the metastasis in the sentinel lymph node. However, the size criteria for micrometastasis and macrometastasis is adopted from the experience in breast carcinoma. Micrometastasis is defined as a metastasis measuring greater than 0.2 mm but less than 2 mm.

Primary Tumor (T)

FIGO		
T Category	Stage	Definition
T1	I	Tumor confined to corpus uteri
T1a	IA	Tumor limited to endometrium or invades less than one-half of the myometrium
T1b	IB	Tumor invades one-half or more of the myometrium
T2	II	Tumor invades stromal connective tissue of the cervix
T3	III	Tumor involving serosa, adnexa, vagina, or parametrium, ie, local and/or regional spread as specified in T3a and T3b, and in FIGO IIIA and IIIB
T3a	IIIA	Tumor involving the serosa and/or adnexa (direct extension or metastasis)
T3b	IIIB	Vaginal involvement (direct extension or metastasis) or parametrial involvement
T4 [#]	IVA	Tumor invading bladder mucosa [#] and/or bowel mucosa [#]

[#] Tumor must involve the mucosal surface; Presence of bullous edema is not sufficient evidence to classify a tumor as T4.

Regional Lymph Nodes (N):[#] TNM Staging System

FIGO		
N Category	Stage	Definition
NX		Regional lymph nodes cannot be assessed
N0		No regional lymph node metastasis
N0(i+)		Isolated tumor cells in regional lymph node(s) no greater than 0.2 mm
N1	IIIC1	Regional lymph node metastasis to pelvic lymph nodes
N1mi [#]	IIIC1	Regional lymph node metastasis (greater than 0.2 mm but not greater than 2 mm in diameter) to pelvic lymph nodes
N1a	IIIC1	Regional lymph node metastasis (greater than 2 mm in diameter) to pelvic lymph nodes
N2	IIIC2	Regional lymph node metastasis to para-aortic lymph nodes with or without positive pelvic lymph nodes
N2mi [#]	IIIC2	Regional lymph node metastasis (greater than 0.2 mm but not greater than 2 mm in diameter) to para-aortic lymph nodes, with or without positive pelvic lymph nodes
N2a	IIIC2	Regional lymph node metastasis (greater than 2 mm in diameter) to para aortic lymph nodes, with or without positive pelvic lymph nodes

[#] Regional lymph nodes include the pelvic, obturator, internal iliac (hypogastric), external iliac, common iliac, para-aortic, presacral, and parametrial lymph nodes. Even one metastasis >2.0 mm would qualify the classification as pN1a and pN2a.

Distant Metastasis (M): TNM Staging System

FIGO		
M Category	Stage	Definition
M0		No distant metastasis
M1	IVB	Distant metastasis (includes metastasis to abdominal lymph nodes [other than para-aortic], and/or inguinal lymph nodes, intraperitoneal disease, lung, liver, or bone; excludes metastasis to vagina, pelvic serosa, or adnexa)

References

1. Amin MB, Edge SB, Greene FL, et al, eds. *AJCC Cancer Staging Manual*. 8th ed. New York, NY: Springer; 2017.
2. Brierley JD, Gospodarowicz MK, Wittekind C, et al, eds. *TNM Classification of Malignant Tumours*. 8th ed. Oxford, UK: Wiley; 2016.
3. FIGO Cancer Report. Cancer of the corpus uteri. *Int J Gynecol Obstet*. 2018;143(suppl 2):37-50.
4. Abu-Rustum NR. Sentinel lymph node mapping for endometrial cancer: a modern approach to surgical staging. *J Natl Compr Canc Netw*. 2014;12:288-97.
5. Euscher E, Sui D, Soliman P, et al. Ultrastaging of sentinel lymph nodes in endometrial carcinoma according to use of 2 different methods. *Int J Gynecol Pathol*. 2018;37:242-251.

L. Additional FindingsAtypical Hyperplasia/Endometrioid Intraepithelial Neoplasia^{1,2,3}

It is essential to see a crowded architecture of cytologically altered glands that are distinct from both the background architecture and cytology of adjacent or entrapped normal glands from low power. The volume of crowded glands exceeds that of the stroma. In addition, there is nuclear atypia in the form of nuclear enlargement, pleomorphism, rounding, loss of polarity, and nucleoli.¹ A size of at least 1.0 mm is recommended. Loss of immunoreactivity for PTEN, PAX2, or mismatch repair proteins may be a helpful diagnostic tool.³ Common mimics such as metaplasia, basaloid, polyp, or dys-synchronous-phase endometrium must be excluded.

Proposed criteria distinguishing Well-Differentiated Endometrioid Endometrial Adenocarcinoma from EIN or Atypical Endometrial Hyperplasia

- (1) Irregular infiltration of myometrium associated with an altered fibroblastic stroma (desmoplastic response), **or**
- (2) Confluent glandular pattern (cribriform growth, or complex folded maze-like epithelium), **or**
- (3) Solid non-squamous epithelial growth

References

1. Matias-Guiu X, Oliva E, McCluggage WG, et al. Tumours of the uterine corpus. In: WHO Classification of Tumours Editorial Board. Female genital tumours [Internet]. Lyon (France): International Agency for Research on Cancer; 2020 [cited 2020 Nov 20]. (WHO classification of tumours series, 5th ed.; vol. 4). Available from: <https://tumourclassification.iarc.who.int/chapters/34>.
2. Mutter GL, Baak JP, Crum CP, et al. Endometrial precancer diagnosis by histopathology, clonal analysis, and computerized morphometry. *J Pathol*. 2000;190:462-9.
3. Chapel DB, Patil SA, Plagov A. Quantitative next-generation sequencing-based analysis indicates progressive accumulation of microsatellite instability between atypical hyperplasia/endometrial intraepithelial neoplasia and paired endometrioid endometrial carcinoma. *Mod Pathol*. 2019;32:1508-1520.