



cap

Protocol for the Examination of Specimens From Patients With Neuroendocrine Tumors (Carcinoid Tumors) of the Appendix

Protocol applies to well-differentiated neuroendocrine tumors of the appendix. Goblet cell carcinoids, poorly differentiated carcinomas with neuroendocrine features, and small cell carcinomas are not included.

Based on AJCC/UICC TNM, 7th Edition

Protocol web posting date: June 2012

Procedures

- Excision (Appendectomy)
- Appendectomy With Segmental Resection (Right Hemicolectomy)

Authors

Laura H. Tang, MD, PhD, FCAP*

Department of Pathology, Memorial Sloan-Kettering Cancer Center, New York, NY

Jordan Berlin, MD

Department of Medicine, Vanderbilt University Medical Center, Nashville, TN

Philip Branton, MD, FCAP

Department of Pathology, Inova Fairfax Hospital, Falls Church, VA

Lawrence J. Burgart, MD, FCAP

Allina Laboratories, Abbott Northwestern Hospital, Minneapolis, MN

David K. Carter, MD, FCAP

Department of Pathology, St. Mary's/Duluth Clinic Health System, Duluth, MN

Carolyn C. Compton, MD, PhD, FCAP

Critical Path Institute, Tucson, AZ

Patrick Fitzgibbons, MD, FCAP

Department of Pathology, St. Jude Medical Center, Fullerton, CA

Wendy L. Frankel, MD, FCAP

Department of Pathology, Ohio State University Medical Center, Columbus, OH

John Jessup, MD

Division of Cancer Treatment and Diagnosis, National Cancer Institute, Bethesda, MD

Sanjay Kakar, MD, FCAP

Department of Pathology, University of California San Francisco and the Veterans Affairs Medical Center, San Francisco, CA

Bruce Minsky, MD

Department of Radiation Oncology, University of Chicago, Chicago, IL

Raouf Nakhleh, MD, FCAP

Department of Pathology, Mayo Clinic, Jacksonville, FL

Kay Washington, MD, PhD, FCAP†

Department of Pathology, Vanderbilt University Medical Center, Nashville, TN

For the Members of the Cancer Committee, College of American Pathologists

* Denotes primary author. † Denotes secondary author. All other contributing authors are listed alphabetically.

© 2012 College of American Pathologists (CAP). All rights reserved.

The College does not permit reproduction of any substantial portion of these protocols without its written authorization. The College hereby authorizes use of these protocols by physicians and other health care providers in reporting on surgical specimens, in teaching, and in carrying out medical research for nonprofit purposes. This authorization does not extend to reproduction or other use of any substantial portion of these protocols for commercial purposes without the written consent of the College.

The CAP also authorizes physicians and other health care practitioners to make modified versions of the Protocols solely for their individual use in reporting on surgical specimens for individual patients, teaching, and carrying out medical research for non-profit purposes.

The CAP further authorizes the following uses by physicians and other health care practitioners, in reporting on surgical specimens for individual patients, in teaching, and in carrying out medical research for non-profit purposes: (1) **Dictation** from the original or modified protocols for the purposes of creating a text-based patient record on paper, or in a word processing document; (2) **Copying** from the original or modified protocols into a text-based patient record on paper, or in a word processing document; (3) The use of a **computerized system** for items (1) and (2), provided that the Protocol data is stored intact as a single text-based document, and is not stored as multiple discrete data fields.

Other than uses (1), (2), and (3) above, the CAP does not authorize any use of the Protocols in electronic medical records systems, pathology informatics systems, cancer registry computer systems, computerized databases, mappings between coding works, or any computerized system without a written license from CAP. Applications for such a license should be addressed to the SNOMED Terminology Solutions division of the CAP.

Any public dissemination of the original or modified Protocols is prohibited without a written license from the CAP.

The College of American Pathologists offers these protocols to assist pathologists in providing clinically useful and relevant information when reporting results of surgical specimen examinations of surgical specimens. The College regards the reporting elements in the "Surgical Pathology Cancer Case Summary" portion of the protocols as essential elements of the pathology report. However, the manner in which these elements are reported is at the discretion of each specific pathologist, taking into account clinician preferences, institutional policies, and individual practice.

The College developed these protocols as an educational tool to assist pathologists in the useful reporting of relevant information. It did not issue the protocols for use in litigation, reimbursement, or other contexts. Nevertheless, the College recognizes that the protocols might be used by hospitals, attorneys, payers, and others. Indeed, effective January 1, 2004, the Commission on Cancer of the American College of Surgeons mandated the use of the required data elements of the protocols as part of its Cancer Program Standards for Approved Cancer Programs. Therefore, it becomes even more important for pathologists to familiarize themselves with these documents. At the same time, the College cautions that use of the protocols other than for their intended educational purpose may involve additional considerations that are beyond the scope of this document.

The inclusion of a product name or service in a CAP publication should not be construed as an endorsement of such product or service, nor is failure to include the name of a product or service to be construed as disapproval.

CAP Appendix NET Protocol Revision History

Version Code

The definition of the version code can be found at www.cap.org/cancerprotocols.

Version: AppendixNET 3.2.0.0

Summary of Changes

The following changes have been made since the February 2011 release.

Excision (Appendectomy) or Resection

Procedure

Deleted "Length" elements.

Histologic Type; Alternate Histologic Classification; Histologic Grade

These three reporting elements were combined into one, and the word "checklist" was changed to "protocol" as follows:

Histologic Type and Grade[#]

- Not applicable
- Well-differentiated neuroendocrine tumor; GX: Grade cannot be assessed
- Well-differentiated neuroendocrine tumor; G1: Low grade (carcinoid)
- Well-differentiated neuroendocrine tumor; G2: Intermediate grade (atypical carcinoid)
- Other (specify): _____

[#] For poorly differentiated (high-grade) neuroendocrine carcinomas (G3), the College of American Pathologists (CAP) protocol for carcinoma of the appendix should be used.

Margins

Reporting on distal margin was removed. "Not applicable" was added under mesenteric (mesoappendiceal) margin. Reporting on circumferential (radial) margin was removed. Reporting on other margins was added, as follows:

Other Margin(s) (required only if applicable)

Specify margin(s): _____

- Cannot be assessed
- Uninvolved by neuroendocrine tumor
- Involved by neuroendocrine tumor

Pathologic Staging (pTNM)

Primary Tumor (pT)

pT1 was changed from a selectable to a nonselectable element.

Ancillary Studies

Reporting on Ki-67 was updated, changing >2% to 3% and adding "specify," as follows:

- + Ki-67 labeling index (specify: _____)
- + ≤2%
- + 3% to 20%
- + >20%

Explanatory Notes

"Neoplasms" was changed to "tumors."

A. Application and Tumor Location

The first sentence was modified to clarify that the protocol encompasses tumors "of any size."

C. Histologic Type

The second paragraph was changed to the following:

Alternate classification schemes based upon the World Health Organization (WHO) classification categorize neuroendocrine neoplasms as well-differentiated neuroendocrine tumors (either the primary tumor or metastasis) and poorly differentiated neuroendocrine carcinomas.⁶⁻⁹ Classification of neuroendocrine tumors is based upon size, functionality, site, and invasion, and tumor proliferative activity (mitosis and Ki67 index). Functioning tumors are those associated with clinical manifestations of hormone production or secretion of measurable amounts of active hormone; immunohistochemical demonstration of hormone production is not equivalent to clinically apparent functionality.

Alternative Classification Based Upon WHO Classification: Neuroendocrine Tumors of the Appendix

This section was deleted.

D. Histologic Grade

"Mitotic count" was changed to "mitotic rate."

Ki-67 Index (%): >2 was changed to 3.

The second to last paragraph was changed to:

This grading system, while based upon that proposed by European Neuroendocrine Tumour Society (ENETS) and the WHO, differs from their system in the designation of G2 tumors as showing mitotic rates of up to 10 per 10 HPF, rather than 20 per 10 HPF,⁸ in order to harmonize criteria for "atypical carcinoid" tumors as proposed in the seventh edition of the *AJCC TNM Cancer Staging Manual*² with criteria for G2 designation.

In the last paragraph, the word "checklist" was changed to "protocol."

References

Reference #8 was updated.

Surgical Pathology Cancer Case Summary

Protocol web posting date: June 2012

APPENDIX: Excision (Appendectomy) or Resection

Select a single response unless otherwise indicated.

Specimen (select all that apply) (Note A)

- Appendix
- Cecum
- Right colon
- Terminal ileum
- Other (specify): _____
- Not specified

Procedure

- Appendectomy
- Appendectomy and right colectomy
- Other (specify): _____

Specimen Integrity

- Intact
- Fragmented
 - + Number of pieces in fragmented specimens: ____
- Other (specify): _____

+ Specimen Size

+ Specify: ____ (length) x ____ x ____ cm

Tumor Site

- Proximal half of appendix
- Distal half of appendix
- Diffusely involving appendix
- Appendix, not otherwise specified
- Unknown
- Other (specify): _____

Tumor Size (Note B)

- Greatest dimension: ____ cm
- + Additional dimensions: ____ x ____ cm
- Cannot be determined (see "Comment")

Histologic Type and Grade (Notes C and D)#

- Not applicable
 Well-differentiated neuroendocrine tumor; GX: Grade cannot be assessed
 Well-differentiated neuroendocrine tumor; G1: Low grade (carcinoid)
 Well-differentiated neuroendocrine tumor; G2: Intermediate grade (atypical carcinoid)
 Other (specify): _____

For poorly differentiated (high-grade) neuroendocrine carcinomas (G3), the College of American Pathologists (CAP) protocol for carcinoma of the appendix¹ should be used.

Mitotic Rate (Note D)

- Specify: ___ /10 high-power fields (HPF)
 Cannot be determined

Microscopic Tumor Extension

- Cannot be assessed
 No evidence of primary tumor
 Tumor invades lamina propria
 Tumor invades submucosa
 Tumor invades muscularis propria
 Tumor invades subserosal tissue without involvement of visceral peritoneum
 Tumor extends into mesoappendix
 Tumor penetrates serosa (visceral peritoneum)
 Tumor directly invades adjacent structures (specify: _____)
 Tumor penetrates to the surface of the visceral peritoneum (serosa) and directly invades adjacent structures (specify: _____)

Margins (select all that apply) (Note E)

- If all margins uninvolved by neuroendocrine tumor:
 Distance of tumor from closest margin: ___ mm or ___ cm
 Specify margin: _____

Proximal Margin

- Cannot be assessed
 Uninvolved by tumor
 Involved by tumor

Mesenteric (Mesoappendiceal) Margin

- Not applicable
 Cannot be assessed
 Uninvolved by tumor
 Distance of tumor from closest mesenteric margin: ___ mm or ___ cm
 Involved by tumor

Other Margin(s) (required only if applicable)

- Specify margin(s): _____
 Cannot be assessed
 Uninvolved by neuroendocrine tumor
 Involved by neuroendocrine tumor

+ Data elements preceded by this symbol are not required. However, these elements may be clinically important but are not yet validated or regularly used in patient management.

Lymph-Vascular Invasion

- Not identified
- Present
- Indeterminate

+ Perineural Invasion

- + Not identified
- + Present
- + Indeterminate

Pathologic Staging (pTNM) (Note F)

TNM Descriptors (required only if applicable) (select all that apply)

- m (multiple primary tumors)
- r (recurrent)
- y (posttreatment)

Primary Tumor (pT)

- pTX: Primary tumor cannot be assessed
- pT0: No evidence of primary tumor
- pT1: Tumor 2 cm or less in greatest dimension
 - pT1a: Tumor 1 cm or less in greatest dimension
 - pT1b: Tumor more than 1 cm but not more than 2 cm
- pT2: Tumor more than 2 cm but not more than 4 cm or with extension to the cecum
- pT3: Tumor more than 4 cm or with extension to the ileum
- pT4: Tumor directly invades other adjacent organs or structures, eg, abdominal wall and skeletal muscle

Regional Lymph Nodes

- Cannot be assessed
- pN0: No regional lymph node metastasis
- pN1: Metastasis in regional lymph nodes
- No nodes submitted or found

Number of Lymph Nodes Examined

- Specify: _____
- Number cannot be determined (explain): _____

Number of Lymph Nodes Involved

- Specify: _____
- Number cannot be determined (explain): _____

Distant Metastasis

- Not applicable
- pM1: Distant metastasis
 - + Specify site(s), if known: _____

+ Data elements preceded by this symbol are not required. However, these elements may be clinically important but are not yet validated or regularly used in patient management.

+ Ancillary Studies (select all that apply) (Notes D and G)

- + Ki-67 labeling index (specify: _____)
 - + $\leq 2\%$
 - + 3% to 20%
 - + $> 20\%$
- + Other (specify): _____
- + Not performed

+ Additional Pathologic Findings (select all that apply) (Note H)

- + Tumor necrosis
- + Acute appendicitis
- + Other (specify): _____

+ Comment(s)

+ Data elements preceded by this symbol are not required. However, these elements may be clinically important but are not yet validated or regularly used in patient management.

Explanatory Notes

A. Application and Tumor Location

This protocol applies to well-differentiated neuroendocrine tumors (carcinoid tumors) of the appendix of any size. Poorly differentiated neuroendocrine carcinomas, small cell carcinomas, and goblet cell carcinoids are not included.

The appendix is a common site of gastrointestinal neuroendocrine tumors, usually presenting as small solitary lesions incidentally discovered after appendectomy. A separate staging system for appendiceal neuroendocrine tumors (NETs) is included in the *AJCC Cancer Staging Manual*² because of the substantial differences in behavior between appendiceal carcinomas and NETs and between appendiceal NETs and other gastrointestinal (GI) NETs. Neuroendocrine tumors arising in the appendix have no *in situ* state and arise in the deep mucosa or submucosa. Unlike for adenocarcinomas, for appendiceal NETs, tumor size is a more important predictor of patient outcome than depth of tumor invasion.

B. Tumor Size

Appendiceal neuroendocrine tumors smaller than 1.0 cm do not recur or metastasize, whereas those between 1.0 and 2.0 cm rarely do.³ Tumor size >2.0 cm and mesoappendiceal invasion⁴ have been correlated with nodal metastasis, but not with poor outcome.⁵ For these reasons, appendectomy is sufficient for tumors 1.0 cm or smaller, as well as many tumors between 1.0 and 2.0 cm. More extensive procedures (eg, right hemicolectomy) are usually reserved for patients with tumors larger than 2.0 cm or with invasion beyond the muscularis propria.

C. Histologic Type

Most appendiceal NETs are low grade, with few mitoses and no necrosis, and have traditionally been classified as "carcinoids." While the term "atypical carcinoid" is not well defined for GI NETs, the *AJCC Cancer Staging Manual*² recommends using this terminology for appendiceal NETs with a mitotic rate of 2 to 10 mitoses per 10 high-power fields and/or focal necrosis. Although the term "carcinoid tumor" remains in widespread use, this term may cause confusion for clinicians, who might view a carcinoid tumor as a serotonin-producing tumor associated with functional manifestations of carcinoid syndrome.

Alternate classification schemes based upon the World Health Organization (WHO) classification categorize neuroendocrine neoplasms as well-differentiated neuroendocrine tumors, well-differentiated neuroendocrine carcinomas, and poorly differentiated neuroendocrine carcinomas.⁶⁻⁹ Classification of neuroendocrine tumors is based upon size, functionality, site, and invasion. Functioning tumors are those associated with clinical manifestations of hormone production or secretion of measurable amounts of active hormone; immunohistochemical demonstration of hormone production is not equivalent to clinically apparent functionality.

Alternative Classification Based Upon WHO Classification: Neuroendocrine Tumors of the Appendix

Well-Differentiated Neuroendocrine Tumor

Benign: Nonfunctioning cytologically bland tumors measuring not more than 1 cm in greatest dimension, without extension into mesoappendix.

Uncertain malignant potential: Nonfunctioning cytologically bland tumors measuring 1 to 2 cm with extension into mesoappendix.

Well-Differentiated Neuroendocrine Carcinoma

Low-grade malignant potential: Nonfunctioning tumors measuring greater than 2 cm and deeply invading the mesoappendix; functioning tumors of any type.

Histologic Patterns

Although specific histologic patterns in well-differentiated neuroendocrine neoplasms, such as trabecular, insular, and glandular, roughly correlate with tumor location,¹⁰ these patterns have not been clearly shown independently to predict response to therapy or risk of nodal metastasis and are rarely reported in clinical practice.

Most appendiceal neuroendocrine tumors are derived from enterochromaffin cells. Rarely, L-cell neuroendocrine tumors of the appendix are encountered; because of their distinctive growth pattern of tear-dropped shaped tubules embedded in a fibrous stroma,¹¹ these lesions are sometimes called tubular neuroendocrine tumors. It should be noted that these tumors are negative for chromogranin A but express enteroglucagon, peptide YY, and pancreatic polypeptide. Tubular neuroendocrine tumors are usually small lesions confined to the appendix and are found in female patients. These lesions exhibit benign behavior and should not be confused with adenocarcinoma.

D. Histologic Grade

Cytologic atypia in low-grade neuroendocrine tumors has no impact on clinical behavior of these tumors. The following grading system is recommended:

Grade	Mitotic Rate (per 10 HPF) #	Ki-67 Index (%)##
G1	<2	≤2
G2	2 to 10	3 to 20
G3	>10	>20

Mitotic rate should be based upon counting 50 high-power (40x objective) fields and in the area of highest mitotic activity, and reported as number of mitoses per 10 HPF.

Ki-67 index is reported as percent positive tumor cells in area of highest nuclear labeling. It has been recommended that 2000 tumor cells be counted to determine the Ki-67 index¹²; however, this practice may not be practical for routine clinical purposes, and it is acceptable to estimate the labeling index.

This grading system, while based upon that proposed by European Neuroendocrine Tumour Society (ENETS) and the WHO, differs from their system in the designation of G2 tumors as showing mitotic rates of up to 10 per 10 HPF, rather than 20 per 10 HPF,^{8,13} in order to harmonize criteria for "atypical carcinoid" tumors as proposed in the seventh edition of the *AJCC TNM Cancer Staging Manual*² with criteria for G2 designation.

G1 and G2 are well-differentiated tumors with diffuse intense chromogranin/synaptophysin positivity. Punctate necrosis is more typical of G2 tumors. G3 tumors are high-grade neuroendocrine carcinomas (the CAP carcinoma protocol for appendiceal carcinoma¹ should be used for poorly differentiated neuroendocrine carcinomas of appendix).

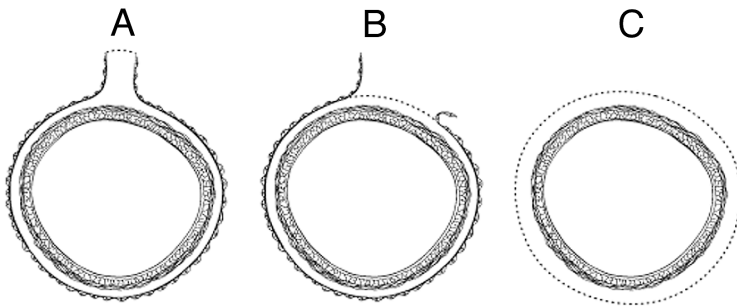
E. Margins

Margins in a simple appendectomy specimen include the proximal and mesenteric or radial margin. It is recommended that the proximal margin on a simple appendectomy specimen should be taken en face in order to evaluate the entire appendiceal mucosa and muscularis circumferentially. In the vast majority of cases, the appendix is entirely peritonealized, and the closest distance between the invasive carcinoma and the mesenteric resection margin represents the radial margin and should be measured. Even retrocecal appendices are usually invested by peritoneum but have adhered to the posterior cecum, either because of inflammation or tumor. Exceptionally, a retrocecal appendix may be retroperitoneal, in which case the distance between the tumor and the nonperitonealized radial resection margin is the "surgical clearance" and should be measured.

In general, the circumferential (radial) margin must be assessed for any segment of gastrointestinal tract either incompletely encased or unencased by peritoneum (Figure, B and C). The posterior surface of

the ascending colon portion of a right hemicolectomy specimen lacks a peritoneal covering and thus constitutes a circumferential margin, which in rare cases may be relevant in right hemicolectomy specimens resected for treatment of appendiceal neuroendocrine tumors. The circumferential (radial) margin represents the adventitial soft tissue margin closest to the deepest penetration of tumor and is created surgically by blunt or sharp dissection of the retroperitoneal or subperitoneal aspect, respectively. The distance between the tumor and circumferential (radial) margin should be reported, if applicable. The circumferential (radial) margin is considered negative if the tumor is more than 1 mm from the inked nonperitonealized surface, but should be recorded as positive if the tumor is located 1 mm or less from the nonperitonealized surface. This assessment includes tumor within a lymph node as well as direct tumor extension, but if circumferential (radial) margin positivity is based solely on intranodal tumor, this should be so stated.

The mesenteric resection margin is the only relevant circumferential margin in segments completely encased by peritoneum (eg, appendix and cecum) (Figure, A). Involvement of this margin should be reported even if tumor does not penetrate the serosal surface.



A, Mesenteric margin in viscus completely encased by peritoneum (dotted line). B, Circumferential (radial) margin (dotted line) in viscus incompletely encased by peritoneum. C, Circumferential (radial) margin (dotted line) in viscus completely unencased by peritoneum. Reproduced with permission from Washington et al.¹⁵ Copyright 2008. College of American Pathologists.

F. TNM and Anatomic Stage/Prognostic Groupings

The TNM staging system for appendiceal NETs of the American Joint Committee on Cancer (AJCC) and the International Union Against Cancer (UICC) is recommended.²

By AJCC/UICC convention, the designation "T" refers to a primary tumor that has not been previously treated. The symbol "p" refers to the pathologic classification of the TNM, as opposed to the clinical classification, and is based on gross and microscopic examination. pT entails a resection of the primary tumor or biopsy adequate to evaluate the highest pT category, pN entails removal of nodes adequate to validate lymph node metastasis, and pM implies microscopic examination of distant lesions. Clinical classification (cTNM) is usually carried out by the referring physician before treatment during initial evaluation of the patient or when pathologic classification is not possible.

Pathologic staging is usually performed after surgical resection of the primary tumor. Pathologic staging depends on pathologic documentation of the anatomic extent of disease, whether or not the primary tumor has been completely removed. If a biopsied tumor is not resected for any reason (eg, when technically unfeasible) and if the highest T and N categories or the M1 category of the tumor can be confirmed microscopically, the criteria for pathologic classification and staging have been satisfied without total removal of the primary cancer.

TNM Descriptors

For identification of special cases of TNM or pTNM classifications, the “m” suffix and “y,” “r,” and “a” prefixes are used. Although they do not affect the stage grouping, they indicate cases needing separate analysis.

The “m” suffix indicates the presence of multiple primary tumors in a single site and is recorded in parentheses: pT(m)NM.

The “y” prefix indicates those cases in which classification is performed during or following initial multimodality therapy (ie, neoadjuvant chemotherapy, radiation therapy, or both chemotherapy and radiation therapy). The cTNM or pTNM category is identified by a “y” prefix. The ycTNM or ypTNM categorizes the extent of tumor actually present at the time of that examination. The “y” categorization is not an estimate of tumor prior to multimodality therapy (ie, before initiation of neoadjuvant therapy).

The “r” prefix indicates a recurrent tumor when staged after a documented disease-free interval, and is identified by the “r” prefix: rTNM.

The “a” prefix designates the stage determined at autopsy: aTNM.

T Category Considerations

Tumor that is adherent to other organs or structures, macroscopically, is classified T4. However, if no tumor is present in the adhesion, microscopically the classification should be pT1 to pT3.

N Category Considerations

The regional lymph nodes for the appendix are the ileocolic lymph nodes.

pTNM Pathological Classification

The pT, pN, and pM categories correspond to the T, N, and M categories except that pM0 (no distant metastasis) does not exist as a category.

pN0. Histologic examination of a regional lymphadenectomy specimen will ordinarily include 12 or more lymph nodes. If the lymph node results are negative, but the number ordinarily examined is not met, classify as pN0.

Histopathologic Grading

Histologic grading is not required for carcinoid tumors, but a mitotic rate of 2 to 10 per 10 HPF and/or focal necrosis are features of atypical carcinoids (well-differentiated neuroendocrine carcinomas), a type seen much more commonly in the lung than in the appendix.

Goblet cell carcinoids are classified according to the carcinoma scheme.

TNM Anatomic Stage/Prognostic Groupings

Stage I	T1	N0	M0
Stage II	T2 or T3	N0	M0
Stage III	T4	N0	M0
	Any T	N1	M0
Stage IV	Any T	Any N	M1

G. Ancillary Studies

Immunohistochemistry and other ancillary techniques are generally not required to diagnose well-differentiated neuroendocrine tumors. Specific markers that may be used to establish neuroendocrine differentiation include chromogranin A, neuron-specific enolase, synaptophysin, and CD56.⁹ Because of their relative sensitivity and specificity, chromogranin A and synaptophysin are recommended. It should be noted that hindgut neuroendocrine tumors often do not express appreciable amounts of

chromogranin A. Rectal neuroendocrine tumors express prostatic acid phosphatase, a potential diagnostic pitfall for tumors arising in male patients.¹⁴

Immunohistochemistry for Ki-67 may be useful in establishing tumor grade (Note D) and prognosis¹² but is not currently considered standard of care.⁹

H. Additional Pathologic Findings

Coagulative tumor necrosis, usually punctate, may indicate more aggressive behavior¹³ and should be reported. Appendiceal NETs are often an incidental finding in specimens removed for acute appendicitis.

References

1. Washington K, Berlin J, Branton P, et al. Protocol for the examination of specimens from patients with carcinoma of the appendix. In: *Reporting on Cancer Specimens: Case Summaries and Background Documentation*. Northfield, IL: College of American Pathologists; 2009.
2. Edge SB, Byrd DR, Carducci MA, Compton CC. *AJCC Cancer Staging Manual*. 7th ed. New York, NY: Springer; 2009.
3. Carr NJ, Sobin LH. Neuroendocrine tumors of the appendix. *Semin Diagn Pathol*. 2004;21(2):108-119.
4. Syracuse DC, Perzin KH, Price JB, Wiedel PD, Mesa-Tejada R. Carcinoid tumors of the appendix: mesoappendiceal extension and nodal metastases. *Ann Surg*. 1979;190(1):58-63.
5. Rossi G, Valli R, Bertolini F, et al. Does mesoappendix infiltration predict a worse prognosis in incidental neuroendocrine tumors of the appendix? A clinicopathologic and immunohistochemical study of 15 cases. *Am J Clin Pathol*. 2003;120(5):706-711.
6. Graeme-Cook F. Neuroendocrine tumors of the GI tract and appendix. In: Odze RD, Goldblum JR, Crawford JM, eds. *Surgical Pathology of the GI Tract, Liver, Biliary Tract, and Pancreas*. Philadelphia, PA: WB Saunders; 2004: 483-504.
7. Kloppel G, Perren A, Heitz PU. The gastroenteropancreatic neuroendocrine cell system and its tumors: the WHO classification. *Ann N Y Acad Sci*. 2004;1014:13-27.
8. Bosman FT, Carneiro F, Hruban RH, Theise ND, eds. *WHO Classification of Tumours of the Digestive System*. Geneva, Switzerland: WHO Press; 2010.
9. Williams GT. Endocrine tumours of the gastrointestinal tract: selected topics. *Histopathology*. 2007;50(1):30-41.
10. Soga J. Carcinoids of the colon and ileocecal region: a statistical evaluation of 363 cases collected from the literature. *J Exp Clin Cancer Res*. 1998;17(2):139-148.
11. Iwafuchi M, Watanabe H, Ajioka Y, Shimoda T, Iwashita A, Seiki I. Immunohistochemical and ultrastructural studies of twelve argentaffin and six argyrophil carcinoids of the appendix vermiformis. *Hum Pathol*. 1990;21(7):773-780.
12. Rindi G, Kloppel G, Alhman H, et al; and all other Frascati Consensus Conference participants; European Neuroendocrine Tumor Society (ENETS). TNM staging of foregut (neuro)endocrine tumors: a consensus proposal including a grading system. *Virchows Arch*. 2006;449(4):395-401.
13. Rindi G, Kloppel G, Couvelard A, et al. TNM staging of midgut and hindgut (neuro) endocrine tumors: a consensus proposal including a grading system. *Virchows Arch*. 2007;451(4):757-762.
14. Sobin LH, Hjermstad BM, Sesterhenn IA, Helwig EB. Prostatic acid phosphatases activity in carcinoid tumors. *Cancer*. 1986;58(1):136-138.
15. Washington MK, Berlin J, Branton PA, et al. Protocol for the examination of specimens from patients with primary carcinomas of the colon and rectum. *Arch Pathol Lab Med*. 2008;132(7):1182-1193.