

# Protocol for the Examination of Specimens From Patients With Neuroendocrine Tumors (Carcinoid Tumors) of the Colon and Rectum

Protocol applies to well-differentiated neuroendocrine tumors of the large bowel and rectum. Carcinomas with mixed endocrine/glandular differentiation, poorly differentiated carcinomas with neuroendocrine features, and small cell carcinomas are not included.

---

Based on AJCC/UICC TNM, 7<sup>th</sup> Edition

Protocol web posting date: October 2013

## Procedures

- Local Excision (Transanal Disk Excision)
- Colectomy (Total, Partial, or Segmental Resection)
- Rectal Resection

## Authors

Kay Washington, MD, PhD, FCAP\*

Department of Pathology, Vanderbilt University Medical Center, Nashville, TN

Laura H. Tang, MD, PhD, FCAP†

Department of Pathology, Memorial Sloan-Kettering Cancer Center, New York, NY

Jordan Berlin, MD

Department of Medicine, Vanderbilt University Medical Center, Nashville, TN

Philip Branton, MD, FCAP

Department of Pathology, Inova Fairfax Hospital, Falls Church, VA

Lawrence J. Burgart, MD, FCAP

Allina Laboratories, Abbott Northwestern Hospital, Minneapolis, MN

David K. Carter, MD, FCAP

Department of Pathology, St. Mary's/Duluth Clinic Health System, Duluth, MN

Carolyn C. Compton, MD, PhD, FCAP

Critical Path Institute, Tucson, AZ

Patrick Fitzgibbons, MD, FCAP

Department of Pathology, St. Jude Medical Center, Fullerton, CA

Wendy L. Frankel, MD, FCAP

Department of Pathology, Ohio State University Medical Center, Columbus, OH

John Jessup, MD

Division of Cancer Treatment and Diagnosis, National Cancer Institute, Bethesda, MD

Sanjay Kakar, MD, FCAP

Department of Pathology, University of California San Francisco and the Veterans Affairs Medical Center, San Francisco, CA

Bruce Minsky, MD

Department of Radiation Oncology, University of Chicago, Chicago, IL

Raouf Nakhleh, MD, FCAP

Department of Pathology, Mayo Clinic, Jacksonville, FL

For the Members of the Cancer Committee, College of American Pathologists

\* Denotes primary author. † Denotes secondary author. All other contributing authors are listed alphabetically.

© 2013 College of American Pathologists (CAP). All rights reserved.

The College does not permit reproduction of any substantial portion of these protocols without its written authorization. The College hereby authorizes use of these protocols by physicians and other health care providers in reporting on surgical specimens, in teaching, and in carrying out medical research for nonprofit purposes. This authorization does not extend to reproduction or other use of any substantial portion of these protocols for commercial purposes without the written consent of the College.

The CAP also authorizes physicians and other health care practitioners to make modified versions of the Protocols solely for their individual use in reporting on surgical specimens for individual patients, teaching, and carrying out medical research for non-profit purposes.

The CAP further authorizes the following uses by physicians and other health care practitioners, in reporting on surgical specimens for individual patients, in teaching, and in carrying out medical research for non-profit purposes: (1) **Dictation** from the original or modified protocols for the purposes of creating a text-based patient record on paper, or in a word processing document; (2) **Copying** from the original or modified protocols into a text-based patient record on paper, or in a word processing document; (3) The use of a **computerized system** for items (1) and (2), provided that the protocol data is stored intact as a single text-based document, and is not stored as multiple discrete data fields.

Other than uses (1), (2), and (3) above, the CAP does not authorize any use of the Protocols in electronic medical records systems, pathology informatics systems, cancer registry computer systems, computerized databases, mappings between coding works, or any computerized system without a written license from the CAP.

Any public dissemination of the original or modified protocols is prohibited without a written license from the CAP.

The College of American Pathologists offers these protocols to assist pathologists in providing clinically useful and relevant information when reporting results of surgical specimen examinations of surgical specimens. The College regards the reporting elements in the "Surgical Pathology Cancer Case Summary" portion of the protocols as essential elements of the pathology report. However, the manner in which these elements are reported is at the discretion of each specific pathologist, taking into account clinician preferences, institutional policies, and individual practice.

The College developed these protocols as an educational tool to assist pathologists in the useful reporting of relevant information. It did not issue the protocols for use in litigation, reimbursement, or other contexts. Nevertheless, the College recognizes that the protocols might be used by hospitals, attorneys, payers, and others. Indeed, effective January 1, 2004, the Commission on Cancer of the American College of Surgeons mandated the use of the required data elements of the protocols as part of its Cancer Program Standards for Approved Cancer Programs. Therefore, it becomes even more important for pathologists to familiarize themselves with these documents. At the same time, the College cautions that use of the protocols other than for their intended educational purpose may involve additional considerations that are beyond the scope of this document.

The inclusion of a product name or service in a CAP publication should not be construed as an endorsement of such product or service, nor is failure to include the name of a product or service to be construed as disapproval.

## CAP Colon and Rectum NET Protocol Revision History

---

### **Version Code**

The definition of the version code can be found at [www.cap.org/cancerprotocols](http://www.cap.org/cancerprotocols).

**Version:** ColonRectumNET 3.2.0.1

### **Summary of Changes**

The following changes have been made since the June 2012 release.

### **Resection, Including Transanal Disk Excision of Rectal Neoplasms**

#### **Histologic Type and Grade**

Deleted "(G3)" from the note.

#### **Mitotic Rate**

A note regarding high-power fields was added, as follows:

#### **Mitotic Rate**

Specify: \_\_\_/10 high-power fields (HPF)#

\_\_\_ Cannot be determined

*# Published criteria that rely upon determination of mitotic rate for grading of gastrointestinal and pancreatic neuroendocrine tumors have been reported using counts per HPF, and do not specify microscopic field size or number of mitoses per mm<sup>2</sup>.*

### **Explanatory Notes**

#### **D. Histologic Grade**

The second note was changed, as follows:

## Ki-67 index is reported as percent positive tumor cells in area of highest nuclear labeling although the precise method of assessment has not been standardized.<sup>10</sup> It has been recommended that 500-2000 tumor cells be counted to determine the Ki-67 index.<sup>6</sup> Published criteria that rely upon determination of mitotic count for grading of GI and pancreatic NETs have been reported using counts per high-power field and do not specify microscopic field size or number of mitoses per mm<sup>2</sup>. Grade assigned based on Ki-67 index may be higher than that based on mitotic count. Thus, reporting the higher grade [by either method] is preferred if both are performed.<sup>6</sup>

#### **References**

Reference #10 was added and the remaining references renumbered accordingly.

## Surgical Pathology Cancer Case Summary

---

Protocol web posting date: October 2013

### COLON AND RECTUM: Resection, Including Transanal Disk Excision of Rectal Tumors (Note A)

Select a single response unless otherwise indicated.

#### Specimen (select all that apply)

- Large intestine
  - Cecum
  - Ascending colon
  - Transverse colon
  - Descending colon
  - Sigmoid colon
- Rectum
- Anus
- Terminal ileum
- Appendix
- Other (specify): \_\_\_\_\_
- Not specified

#### Procedure

- Right hemicolectomy
- Transverse colectomy
- Left hemicolectomy
- Sigmoidectomy
- Rectal/rectosigmoid colon (low anterior resection)
- Total abdominal colectomy
- Abdominoperineal resection
- Transanal disk excision (local excision)
- Other (specify): \_\_\_\_\_
- Not specified

#### + Specimen Size (applicable to transanal disk excision)

+ Specify: \_\_\_ (length) x \_\_\_ x \_\_\_ cm

#### Tumor Site (select all that apply) (Note B)

- Large bowel
  - Cecum
  - Right (ascending) colon
  - Hepatic flexure
  - Transverse colon
  - Splenic flexure
  - Left (descending) colon
  - Sigmoid colon
- Rectum
- Other (specify): \_\_\_\_\_
- Not specified

+ Data elements preceded by this symbol are not required. However, these elements may be clinically important but are not yet validated or regularly used in patient management.

**+ Tumor Location**

- + \_\_\_ Tumor is located above peritoneal reflection
- + \_\_\_ Tumor is located below the peritoneal reflection
- + \_\_\_ Not specified

**Tumor Size (Note C)**

Greatest dimension: \_\_\_ cm (specify size of largest tumor if multiple tumors are present)

- + Additional dimensions: \_\_\_ x \_\_\_ cm
- \_\_\_ Cannot be determined (see "Comment")

**Tumor Focality**

- \_\_\_ Unifocal
- \_\_\_ Multifocal (specify number of tumors: \_\_\_\_\_)
- \_\_\_ Cannot be determined

**Histologic Type and Grade (Notes D and E) #**

- \_\_\_ Not applicable
- \_\_\_ Well-differentiated neuroendocrine tumor; GX: Grade cannot be assessed
- \_\_\_ Well-differentiated neuroendocrine tumor; G1: Low grade
- \_\_\_ Well-differentiated neuroendocrine tumor; G2: Intermediate grade
- \_\_\_ Other (specify): \_\_\_\_\_

# For poorly differentiated neuroendocrine carcinomas, the College of American Pathologists (CAP) protocol for carcinoma of the colon and rectum<sup>1</sup> should be used.

**Mitotic Rate**

- Specify: \_\_\_/10 high-power fields (HPF)#
- \_\_\_ Cannot be determined

# Published criteria that rely upon determination of mitotic rate for grading of gastrointestinal and pancreatic neuroendocrine tumors have been reported using counts per HPF, and do not specify microscopic field size or number of mitoses per mm<sup>2</sup>.

**Microscopic Tumor Extension**

- \_\_\_ Cannot be assessed
- \_\_\_ No evidence of primary tumor
- \_\_\_ Tumor invades lamina propria
- \_\_\_ Tumor invades into but not through muscularis mucosae
- \_\_\_ Tumor invades submucosa
- \_\_\_ Tumor invades muscularis propria
- \_\_\_ Tumor invades through the muscularis propria into the subserosal adipose tissue or the nonperitonealized pericolic or perirectal soft tissues but does not extend to the serosal surface (visceral peritoneum)
- \_\_\_ Tumor penetrates serosa (visceral peritoneum)
- \_\_\_ Tumor directly invades adjacent structures (specify: \_\_\_\_\_)
- \_\_\_ Tumor penetrates to the surface of the visceral peritoneum (serosa) and directly invades adjacent structures (specify: \_\_\_\_\_)

+ Data elements preceded by this symbol are not required. However, these elements may be clinically important but are not yet validated or regularly used in patient management.

**Margins**

If all margins uninvolved by neuroendocrine tumor:

Distance of tumor from closest margin: \_\_\_ mm *or* \_\_\_ cm

Specify margin: \_\_\_\_\_

Proximal Margin

- Cannot be assessed  
 Uninvolved by neuroendocrine tumor  
 Involved by neuroendocrine tumor

Distal Margin

- Cannot be assessed  
 Uninvolved by neuroendocrine tumor  
 Involved by neuroendocrine tumor

Circumferential (Radial) Margin (Note F)

- Cannot be assessed  
 Uninvolved by neuroendocrine tumor  
 Involved by neuroendocrine tumor  
 Not applicable

Other Margin(s) (required only if applicable)

Specify margin(s): \_\_\_\_\_

- Cannot be assessed  
 Uninvolved by neuroendocrine tumor  
 Involved by neuroendocrine tumor

**Lymph-Vascular Invasion**

- Not identified  
 Present  
 Indeterminate

**+ Perineural Invasion**

- +  Not identified  
 +  Present  
 +  Indeterminate

**Pathologic Staging (pTNM) (Note G)**

TNM Descriptors (required only if applicable) (select all that apply)

- m (multiple primary tumors)  
 r (recurrent)  
 y (posttreatment)

Primary Tumor (pT)

- pTX: Primary tumor cannot be assessed
- pT0: No evidence of primary tumor
- pT1: Tumor invades lamina propria or submucosa and size 2 cm or less
- pT1a: Tumor size less than 1 cm in greatest dimension
- pT1b: Tumor size 1 to 2 cm in greatest dimension
- pT2: Tumor invades muscularis propria or size more than 2 cm with invasion of lamina propria or submucosa
- pT3: Tumor invades through the muscularis propria into the subserosa, or into nonperitonealized pericolic or perirectal tissues
- pT4: Tumor invades peritoneum or other organs

Regional Lymph Nodes (pN)

- Cannot be assessed
- pN0: No regional lymph node metastasis
- pN1: Metastasis in regional lymph nodes
  
- No nodes submitted or found

*Number of Lymph Nodes Examined*

- Specify:  \_\_\_\_\_  
 Number cannot be determined (explain): \_\_\_\_\_

*Number of Lymph Nodes Involved*

- Specify:  \_\_\_\_\_  
 Number cannot be determined (explain): \_\_\_\_\_

Distant Metastasis (pM)

- Not applicable
- pM1: Distant metastasis  
 + Specify site(s), if known: \_\_\_\_\_

**+ Ancillary Studies (select all that apply) (Notes E and H)**

- +  Ki-67 labeling index (specify: \_\_\_\_\_)
  - +  ≤2%
  - +  3% to 20%
  - +  >20%
- +  Other (specify): \_\_\_\_\_
- +  Not performed

**+ Additional Pathologic Findings (select all that apply) (Note I)**

- +  Tumor necrosis
- +  Other (specify): \_\_\_\_\_

**+ Comment(s)**

+ Data elements preceded by this symbol are not required. However, these elements may be clinically important but are not yet validated or regularly used in patient management.

## Explanatory Notes

### A. Application and Tumor Location

This protocol applies to low- and intermediate-grade neuroendocrine tumors (carcinoid tumors) of the colon and rectum. Poorly differentiated neuroendocrine carcinomas, small cell carcinomas, and tumors with mixed glandular/neuroendocrine differentiation are not included.

Because of site-specific similarities in histology, immunohistochemistry, and histochemistry, neuroendocrine tumors of the digestive tract have traditionally been subdivided into those of foregut, midgut, and hindgut origin (Table). In general, the distribution pattern along the gastrointestinal (GI) tract parallels that of the progenitor cell type, and the anatomic site of origin of GI neuroendocrine tumors is an important predictor of clinical behavior.<sup>2</sup>

#### Site of Origin of Gastrointestinal Neuroendocrine Tumors

	Foregut Tumors	Midgut Tumors	Hindgut Tumors
<i>Site</i>	<i>Stomach, Proximal Duodenum</i>	<i>Jejunum, Ileum, Appendix, Proximal Colon</i>	<i>Distal Colon, Rectum</i>
Immunohistochemistry			
Chromogranin A	86%-100% +	82%-92% +	40%-58% +
Neuron-Specific Enolase (NSE)	90%-100% +	95%-100% +	80%-87% +
Synaptophysin	50% +	95%-100% +	94%-100% +
Serotonin	33% + <sup>15</sup>	86% + <sup>15</sup>	45%-83% + <sup>3,5,6,15</sup>
Other Immunohistochemical Markers	Rarely, + for pancreatic polypeptide, histamine, gastrin, vasoactive intestinal peptide (VIP), or adrenocorticotrophic hormone (ACTH)	Prostatic acid phosphatase + in 20%-40% <sup>14,15</sup>	Prostatic acid phosphatase + in 20%-82% <sup>14</sup>
Carcinoid syndrome	Rare	5%-39% <sup>6,7</sup>	Rare

### B. Site-Specific Features

Rectal neuroendocrine tumors are common and constitute approximately one-quarter of GI neuroendocrine tumors.<sup>3</sup> They are usually small, solitary, and clinically silent, most commonly occurring 4 to 13 cm from the anal verge. Mitotically inactive rectal neuroendocrine tumors or those smaller than 2.0 cm are almost always clinically benign.<sup>4</sup> Metastases and carcinoid syndrome are very rare. Large intestinal neuroendocrine tumors outside the ileocecal region and rectum are extremely rare; most reported tumors have been large (average 5.0 cm) and high grade, with a poor prognosis. Many low-grade neuroendocrine tumors involving the ileocecal valve represent tumors arising in the terminal ileum, rather than in the large bowel.

### C. Tumor Size

For neuroendocrine tumors in any part of the gastrointestinal tract, size greater than 2.0 cm is associated with a higher risk of lymph node metastasis. Rectal carcinoids smaller than 1.0 cm are almost always clinically benign, and local excision is generally considered sufficient for tumors 1.0 cm or smaller, as well as many tumors between 1.0 and 2.0 cm. More extensive procedures (eg, right hemicolectomy and abdominoperineal resection) are usually reserved for patients with tumors larger than 2.0 cm.



## D. Histologic Type

The World Health Organization (WHO) classifies neuroendocrine tumors as well-differentiated neuroendocrine tumors (either the primary tumor or metastasis) and poorly differentiated neuroendocrine carcinomas.<sup>5-8</sup> Historically, well-differentiated neuroendocrine tumors have been referred to as carcinoid tumors, a term which may cause confusion because clinically a carcinoid tumor is a serotonin-producing tumor associated with functional manifestations of carcinoid syndrome.

Classification of neuroendocrine tumors (NETs) is based upon size, functionality, site, and invasion. Functioning tumors are those associated with clinical manifestations of hormone production or secretion of measurable amounts of active hormone; immunohistochemical demonstration of hormone production is not equivalent to clinically apparent functionality.

All colonic neuroendocrine tumors are considered potentially malignant. Most are large, bulky, high-grade, highly invasive tumors that are metastatic at presentation. Two-thirds arise within the cecum or right colon.

Rectal neuroendocrine tumors, in contrast to colonic neuroendocrine tumors, are relatively common and generally behave in a benign fashion.

## Histologic Patterns

Although specific histologic patterns in well-differentiated neuroendocrine tumors, such as trabecular, insular, and glandular, roughly correlate with tumor location,<sup>4</sup> these patterns have not been clearly shown independently to predict response to therapy or risk of nodal metastasis and are rarely reported in clinical practice.

## E. Histologic Grade

Cytologic atypia in low-grade neuroendocrine tumors has no impact on clinical behavior of these tumors. However, a grading system based on mitotic activity has been proposed for NETs of the ileum, appendix, colon, and rectum<sup>9</sup>:

Grade	Mitotic Rate (per 10 HPF) #	Ki-67 Index (%) ##
G1	<2	≤2
G2	2 to 20	3 to 20
G3	>20	>20

# Mitotic rate should be based upon counting 50 high-power (40x objective) fields in the area of highest mitotic activity and reported as number of mitoses per 10 HPF.

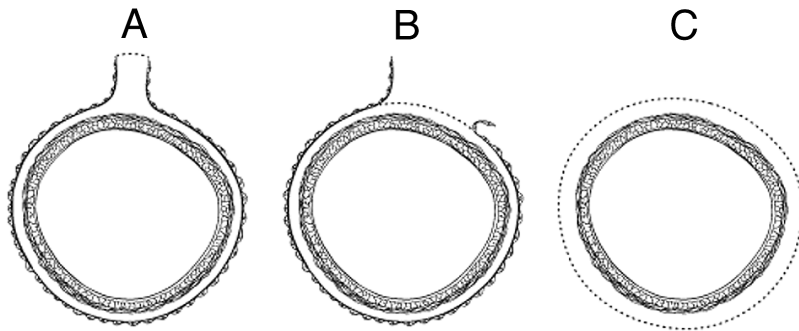
## Ki-67 index is reported as percent positive tumor cells in area of highest nuclear labeling although the precise method of assessment has not been standardized.<sup>10</sup> It has been recommended that 500-2000 tumor cells be counted to determine the Ki-67 index.<sup>6</sup> Published criteria that rely upon determination of mitotic count for grading of GI and pancreatic NETs have been reported using counts per high-power field and do not specify microscopic field size or number of mitoses per mm<sup>2</sup>. Grade assigned based on Ki-67 index may be higher than that based on mitotic count. Thus, reporting the higher grade [by either method] is preferred if both are performed.<sup>6</sup>

G1 and G2 are well-differentiated tumors with diffuse intense chromogranin/synaptophysin positivity. Punctate necrosis is more typical of G2 tumors. G3 tumors are high-grade neuroendocrine carcinomas (the CAP protocol for carcinomas of the colon and rectum<sup>1</sup> should be used for poorly differentiated neuroendocrine carcinomas arising in these sites).

#### F. Circumferential (Radial or Mesenteric) Margin

In addition to addressing the proximal and distal margins, assessment of the circumferential (radial) margin is necessary for any segment of gastrointestinal tract either unencased (Figure, C) or incompletely encased by peritoneum (Figure, B). The circumferential margin represents the adventitial soft-tissue margin closest to the deepest penetration of tumor and is created surgically by blunt or sharp dissection of the retroperitoneal or subperitoneal aspect, respectively. The distance between the tumor and circumferential (radial) margin should be reported. The circumferential (radial) margin is considered negative if the tumor is more than 1 mm from the inked nonperitonealized surface but should be recorded as positive if the tumor is located 1 mm or less from the nonperitonealized surface. This assessment includes tumor within a lymph node as well as direct tumor extension, but if circumferential (radial) margin positivity is based solely on intranodal tumor, this should be so stated.

The mesenteric resection margin is the only relevant circumferential margin in segments completely encased by peritoneum (eg, transverse colon) (Figure, A). Involvement of this margin should be reported even if tumor does not penetrate the serosal surface.



A, Mesenteric margin in viscus completely encased by peritoneum (dotted line). B, Circumferential (radial) margin (dotted line) in viscus incompletely encased by peritoneum. C, Circumferential (radial) margin (dotted line) in viscus completely unencased by peritoneum. Reproduced with permission from Washington et al.<sup>1</sup> Copyright 2008. College of American Pathologists.

#### G. TNM and Anatomic Stage/Prognostic Groupings

The TNM staging system for neuroendocrine tumors of the colon and rectum of the American Joint Committee on Cancer (AJCC) and the International Union Against Cancer (UICC) is recommended.<sup>12</sup>

By AJCC/UICC convention, the designation "T" refers to a primary tumor that has not been previously treated. The symbol "p" refers to the pathologic classification of the TNM, as opposed to the clinical classification, and is based on gross and microscopic examination. pT entails a resection of the primary tumor or biopsy adequate to evaluate the highest pT category, pN entails removal of nodes adequate to validate lymph node metastasis, and pM implies microscopic examination of distant lesions. Clinical classification (cTNM) is usually carried out by the referring physician before treatment, during initial evaluation of the patient or when pathologic classification is not possible.

Pathologic staging is usually performed after surgical resection of the primary tumor. Pathologic staging depends on pathologic documentation of the anatomic extent of disease, whether or not the primary tumor has been completely removed. If a biopsied tumor is not resected for any reason (eg, when technically unfeasible) and if the highest T and N categories or the M1 category of the tumor can be confirmed microscopically, the criteria for pathologic classification and staging have been satisfied without total removal of the primary cancer.

### TNM Descriptors

For identification of special cases of TNM or pTNM classifications, the “m” suffix and “y,” “r,” and “a” prefixes are used. Although they do not affect the stage grouping, they indicate cases needing separate analysis.

The “m” suffix indicates the presence of multiple primary tumors in a single site and is recorded in parentheses: pT(m)NM.

The “y” prefix indicates those cases in which classification is performed during or following initial multimodality therapy (ie, neoadjuvant chemotherapy, radiation therapy, or both chemotherapy and radiation therapy). The cTNM or pTNM category is identified by a “y” prefix. The ycTNM or ypTNM categorizes the extent of tumor actually present at the time of that examination. The “y” categorization is not an estimate of tumor prior to multimodality therapy (ie, before initiation of neoadjuvant therapy).

The “r” prefix indicates a recurrent tumor when staged after a documented disease-free interval and is identified by the “r” prefix: rTNM.

The “a” prefix designates the stage determined at autopsy: aTNM.

### N Category Considerations

The regional lymph nodes of the colon and rectum are as follows:

Cecum: Pericolic, anterior cecal, posterior cecal, ileocolic, right colic

Ascending colon: Pericolic, ileocolic, right colic, middle colic

Hepatic flexure: Pericolic, middle colic, right colic

Transverse colon: Pericolic, middle colic

Splenic flexure: Pericolic, middle colic, left colic, inferior mesenteric

Descending colon: Pericolic, left colic, inferior mesenteric, sigmoid

Sigmoid colon: Pericolic, inferior mesenteric, superior rectal (hemorrhoidal), sigmoidal, sigmoid mesenteric

Rectosigmoid: Pericolic, perirectal, left colic, sigmoid mesenteric, sigmoidal, inferior mesenteric, superior rectal (hemorrhoidal), middle rectal (hemorrhoidal)

Rectum: Perirectal, sigmoid mesenteric, inferior mesenteric, lateral sacral, presacral, internal iliac, sacral promontory (Gerota's), internal iliac, superior rectal (hemorrhoidal), middle rectal (hemorrhoidal), inferior rectal (hemorrhoidal)

### TNM Anatomic Stage/Prognostic Groupings

Stage I	T1	N0	M0 <sup>#</sup>
Stage IIa	T2	N0	M0
Stage IIb	T3	N0	M0
Stage IIIa	T4	N0	M0
Stage IIIb	Any T	N1	M0
Stage IV	Any T	Any N	M1

# M0 is defined as no distant metastasis.

### H. Ancillary Studies

Immunohistochemistry and other ancillary techniques are generally not required to diagnose well-differentiated neuroendocrine tumors. Specific markers that may be used to establish neuroendocrine differentiation include chromogranin A, neuron-specific enolase, synaptophysin, and CD56.<sup>7</sup> Because of their relative sensitivity and specificity, chromogranin A and synaptophysin are recommended. It should be noted that hindgut neuroendocrine tumors often do not express appreciable amounts of chromogranin A. Rectal neuroendocrine tumors express prostatic acid phosphatase, a potential

diagnostic pitfall for tumors arising in male patients.<sup>11</sup>

Immunohistochemistry for Ki-67 may be useful in establishing tumor grade (Note E) and prognosis<sup>11</sup> but is not currently considered standard of care.<sup>7</sup>

Immunohistochemistry for specific hormone products, such as glucagon, gastrin, and somatostatin, may be of interest in some cases. However, immunohistochemical demonstration of hormone production does not equate with clinical functionality of the tumor.

### I. Additional Pathologic Findings

Coagulative tumor necrosis, usually punctate, may indicate more aggressive behavior<sup>13</sup> and should be reported.

### References

1. Washington MK, Berlin J, Branton PA, et al. Protocol for the examination of specimens from patients with primary carcinomas of the colon and rectum. *Arch Pathol Lab Med.* 2008;132(7):1182-1193.
2. Rorstad O. Prognostic indicators for carcinoid neuroendocrine tumors of the gastrointestinal tract. *J Surg Oncol.* 2005;89(3):151-160.
3. Modlin IM, Lye KD, Kidd M. A 5-decade analysis of 13,715 carcinoid tumors. *Cancer.* 2003;97(4):934-959.
4. Soga J. Carcinoids of the colon and ileocecal region: a statistical evaluation of 363 cases collected from the literature. *J Exp Clin Cancer Res.* 1998;17(2):139-148.
5. Graeme-Cook F. Neuroendocrine tumors of the GI tract and appendix. In: Odze RD, Goldblum JR, Crawford JM, eds. *Surgical Pathology of the GI Tract, Liver, Biliary Tract, and Pancreas.* Philadelphia, PA: Saunders; 2004: 483-504.
6. Bosman FT, Carneiro F, Hruban RH, Theise ND, eds. *WHO Classification of Tumours of the Digestive System.* Geneva, Switzerland: WHO Press; 2010.
7. Williams GT. Endocrine tumours of the gastrointestinal tract: selected topics. *Histopathology.* 2007;50(1):30-41.
8. Kloppel G, Perren A, Heitz PU. The gastroenteropancreatic neuroendocrine cell system and its tumors: the WHO classification. *Ann N Y Acad Sci.* 2004;1014:13-27.
9. Rindi G, Kloppel G, Couvelard A, et al. TNM staging of midgut and hindgut (neuro) endocrine tumors: a consensus proposal including a grading system. *Virchows Arch.* 2007;451(4):757-762.
10. Tang LH, Gonen M, Hedvat C, Modlin I, Klimstra DS. Objective quantification of the Ki67 proliferative index in neuroendocrine tumors of gastroenteropancreatic system: a comparison of digital image analysis with manual methods. *Am J Surg Pathol.* 2012;36(12):1761-1770.
11. Sobin LH, Hjermstad BM, Sesterhenn IA, Helwig EB. Prostatic acid phosphatases activity in carcinoid tumors. *Cancer.* 1986;58(1):136-138.
12. Edge SB, Byrd DR, Carducci MA, Compton CC. *AJCC Cancer Staging Manual.* 7th ed. New York, NY: Springer; 2009.
13. Rindi G, Kloppel G, Alhman H, et al; and all other Frascati Consensus Conference participants; European Neuroendocrine Tumor Society (ENETS). TNM staging of foregut (neuro)endocrine tumors: a consensus proposal including a grading system. *Virchows Arch.* 2006;449(4):395-401.
14. Kimura N, Sasano N. Prostate-specific acid phosphatase in carcinoid tumors. *Virchows Arch A Pathol Anat Histopathol.* 1986;410(3):247-251.
15. Nash SV, Said JW. Gastroenteropancreatic neuroendocrine tumors: a histochemical and immunohistochemical study of epithelial (keratin proteins, carcinoembryonic antigen) and neuroendocrine (neuron-specific enolase, bombesin and chromogranin) markers in foregut, midgut, and hindgut tumors. *Am J Clin Pathol.* 1986;86(2):415-422.