



Protocol for the Examination of Specimens From Patients With Carcinoma of the Adrenal Gland

Version: Adrenal Gland 4.0.2.0

Protocol Posting Date: February 2019

CAP Laboratory Accreditation Program Protocol Required Use Date: November 2019

Includes pTNM requirements from the 8th Edition, AJCC Staging Manual

For accreditation purposes, this protocol should be used for the following procedures AND tumor types:

Procedure	Description
Resection	Adrenalectomy
Tumor Type	Description
Adrenal cortical carcinoma	

This protocol is NOT required for accreditation purposes for the following:

Procedure
Biopsy (includes needle and incisional biopsies)
Primary resection specimen with no residual cancer (eg, following neoadjuvant therapy)
Cytologic specimens

The following tumor types should NOT be reported using this protocol:

Tumor Type
Tumors of the adrenal medulla (eg, pheochromocytoma)
Pediatric adrenal cortical neoplasms (≤ 18 years) [#]
Sarcoma (consider the Soft Tissue protocol)
Lymphoma (consider the Hodgkin or non-Hodgkin Lymphoma protocols)

[#]This protocol applies principally to adrenal carcinomas in adults. Pediatric adrenal cortical tumors have different criteria for malignancy and are, in general, treated under protocols that may differ significantly from the recommendations for adult-type tumors.

Authors

Ozgur Mete, MD*; Lester D.R. Thompson, MD*; Sylvia L. Asa, MD, PhD; Thomas Baker, MD; Michael Berman, MD; Lori Erickson, MD; Thomas J. Giordano, MD, PhD; Lawrence M. Weiss, MD; Arthur Tischler, MD

With guidance from the CAP Cancer and CAP Pathology Electronic Reporting Committees.

* Denotes primary author. All other contributing authors are listed alphabetically.

Accreditation Requirements

This protocol can be utilized for a variety of procedures and tumor types for clinical care purposes. For accreditation purposes, only the definitive primary cancer resection specimen is required to have the core and conditional data elements reported in a synoptic format.

- Core data elements are required in reports to adequately describe appropriate malignancies. For accreditation purposes, essential data elements must be reported in all instances, even if the response is “not applicable” or “cannot be determined.”
- Conditional data elements are only required to be reported if applicable as delineated in the protocol. For instance, the total number of lymph nodes examined must be reported, but only if nodes are present in the specimen.
- Optional data elements are identified with “+” and although not required for CAP accreditation purposes, may be considered for reporting as determined by local practice standards.

The use of this protocol is not required for recurrent tumors or for metastatic tumors that are resected at a different time than the primary tumor. Use of this protocol is also not required for pathology reviews performed at a second institution (ie, secondary consultation, second opinion, or review of outside case at second institution).

Synoptic Reporting

All core and conditionally required data elements outlined on the surgical case summary from this cancer protocol must be displayed in synoptic report format. Synoptic format is defined as:

- Data element: followed by its answer (response), outline format without the paired "Data element: Response" format is NOT considered synoptic.
- The data element should be represented in the report as it is listed in the case summary. The response for any data element may be modified from those listed in the case summary, including “Cannot be determined” if appropriate.
- Each diagnostic parameter pair (Data element: Response) is listed on a separate line or in a tabular format to achieve visual separation. The following exceptions are allowed to be listed on one line:
 - Anatomic site or specimen, laterality, and procedure
 - Pathologic Stage Classification (pTNM) elements
 - Negative margins, as long as all negative margins are specifically enumerated where applicable
- The synoptic portion of the report can appear in the diagnosis section of the pathology report, at the end of the report or in a separate section, but all Data element: Responses must be listed together in one location

Organizations and pathologists may choose to list the required elements in any order, use additional methods in order to enhance or achieve visual separation, or add optional items within the synoptic report. The report may have required elements in a summary format elsewhere in the report IN ADDITION TO but not as replacement for the synoptic report i.e. all required elements must be in the synoptic portion of the report in the format defined above.

CAP Adrenal Gland Protocol Summary of Changes

Version 4.0.2.0**The following data elements were modified:**

Lymphovascular Invasion

Ki-67 Labeling Index

Surgical Pathology Cancer Case Summary

Protocol posting date: February 2019

ADRENAL GLAND:

Select a single response unless otherwise indicated.

Procedure

- Percutaneous needle biopsy
- Endoscopic directed biopsy (specify radiographic technique): _____
- Adrenalectomy, total
- Adrenalectomy, partial
- Other (specify): _____
- Not specified

Specimen Laterality

- Right
- Left
- Bilateral
- Not specified
- Other (specify): _____

Tumor Size (Note A)

- Greatest dimension(centimeters): ____ cm
- + Additional dimensions(centimeters): ____ x ____ cm
- Cannot be determined (explain): _____

Tumor Weight (Note B)

- Specify: ____ g
- + Tumor Description (select all that apply)
- + Hemorrhagic
- + Necrotic
- + Other (specify): _____

Histologic Type (Notes C through E)

- Adrenal cortical carcinoma
- Adrenal cortical carcinoma, oncocytic type
- Adrenal cortical carcinoma, myxoid type
- Adrenal cortical carcinoma, sarcomatoid type

Histologic Grade (Notes C through E)

- Low grade (≤20 mitoses/50 high-power fields)
- High grade (>20 mitoses/50 high-power fields)
- Cannot be assessed (explain)[#]: _____

#Note: Generally due to core needle biopsy, with insufficient viable tumor to count 50 HPFs.

Lymphovascular Invasion (select all that apply) (Note F)

- Not identified
- Large vessel invasion, renal vein (including when identified clinically)
- Large vessel invasion, vena cava (including when identified clinically)
- Large vessel invasion, not otherwise specified
- Microscopic angioinvasion
- Lymphatic invasion

+ Data elements preceded by this symbol are not required. for accreditation purposes. These optional elements may be clinically important but are not yet validated or regularly used in patient management.

___ Cannot be determined

Tumor Extension (select all that apply)

- ___ No evidence of primary tumor
- ___ Tumor confined to adrenal cortex without invasion through tumor capsule (if present)
- ___ Tumor invades into or through the adrenal capsule
- ___ Tumor invades into extra-adrenal structures (specify): _____
- ___ Tumor invades into adjacent organs# (specify): _____
- ___ Cannot be assessed

Note: Adjacent organs may include kidney, pancreas, liver, spleen, diaphragm, stomach, and other organs.

Margins

- ___ Uninvolved by tumor
 - + Distance from closest margin(millimeters): ___ mm
 - Specify margin, if possible: _____
- ___ Involved by tumor
 - Specify margin(s), if possible: _____
- ___ Cannot be assessed
- ___ Not applicable

Regional Lymph Nodes

___ No lymph nodes submitted or found

Lymph Node Examination (required only if lymph nodes present in the specimen)

Number of Lymph Nodes Involved: ___
 ___ Number cannot be determined (explain): _____

Number of Lymph Nodes Examined: ___
 ___ Number cannot be determined (explain): _____

- + Extranodal Extension
- + ___ Not identified
- + ___ Present
- + ___ Cannot be determined

Pathologic Stage Classification (pTNM, AJCC 8th Edition) (Note G)

Note: Reporting of pT, pN, and (when applicable) pM categories is based on information available to the pathologist at the time the report is issued. Only the applicable T, N, or M category is required for reporting; their definitions need not be included in the report. The categories (with modifiers when applicable) can be listed on 1 line or more than 1 line.

TNM Descriptors (required only if applicable) (select all that apply)

- ___ m (multiple primary tumors)
- ___ r (recurrent)
- ___ y (posttreatment)

Primary Tumor (pT)

Note: There is no category of carcinoma in situ (pTis) relative to carcinomas of the adrenal gland.

- ___ pTX: Primary tumor cannot be assessed
- ___ pT0: No evidence of primary tumor
- ___ pT1: Tumor ≤5 cm in greatest dimension, no extra-adrenal invasion
- ___ pT2: Tumor >5 cm, no extra-adrenal invasion
- ___ pT3: Tumor of any size with local invasion but not invading adjacent organs
- ___ pT4: Tumor of any size that invades adjacent organs (kidney, diaphragm, pancreas, spleen, or liver) or large blood vessels (renal vein or vena cava)

+ Data elements preceded by this symbol are not required. for accreditation purposes. These optional elements may be clinically important but are not yet validated or regularly used in patient management.

Regional Lymph Nodes (pN) (Note H) pNX: Regional lymph nodes cannot be assessed pN0: No regional lymph node metastasis pN1: Metastasis in regional lymph node(s)**Distant Metastasis (pM) (Note I) (required only if confirmed pathologically in this case)** pM1: Distant metastasis

Specify site(s), if known: _____

+ Additional Pathologic Findings (select all that apply)

+ None identified+ Hemorrhage+ Cystic change+ Calcifications+ Other (specify): _____

+ Functional Status (select all that apply) (Notes J and K)

+ Urinary 17-ketosteroids increased (10 mg/g creatinine/24 hours)+ Cushing syndrome+ Conn syndrome+ Virilization+ Feminization+ Weight loss+ Other (specify): _____

+ Ancillary Studies (select all that apply) (Note L)

+ Ki-67 labeling index (%) (specify): _____+ Reticulin stain (specify type(s) and result(s)): _____+ Other (specify type and result): _____

+ Clinical History

+ Specify: _____

+ Comment(s)

Explanatory Notes

A. Primary Site and Laparoscopic Surgery

The adrenal glands sit in a supra-renal location (retroperitoneal) surrounded by connective tissue and a layer of adipose tissue. The adrenal glands are intimately associated with the kidneys and are enclosed within the renal fascia (Gerota's). Each gland has an outer cortex, which is lipid rich and on gross examination appears bright yellow, surrounding an inner "gray-white" medullary compartment composed of chromaffin cells. There is a rich vascular supply derived from the aorta, inferior phrenic arteries, and renal arteries. Veins emerge from the hila of the glands. The shorter right central vein opens into the inferior vena cava, and the left central vein opens into the renal vein. A single adrenal vein is present for each gland. The regional lymph nodes include the aortic lymph nodes (para-aortic, peri-aortic) and retroperitoneal lymph nodes.

An entire adrenal tumor may be removed laparoscopically, but with this technique, the gland may become fragmented. This anatomic information, including maximal diameter of the resected tumor, should be provided by the surgeon. A recent study¹ demonstrates a tumor size greater than 6.5 cm is likely to be malignant.

References:

1. Aubert S, Wacrenier A, Leroy X, et al. Weiss system revisited: a clinicopathologic and immunohistochemical study of 49 adrenocortical tumors. *Am J Surg Pathol.* 2002;26:1612-1619.

B. Weight

Accurate weights of adrenal cortical neoplasms are important.¹ Although tumor mass cannot be used as the sole criterion for malignancy, adrenal cortical neoplasms weighing less than 50 g are almost always benign, whereas the weight of malignant tumors is usually greater than 100 g. Weight is a reflection of gland weight rather than tumor weight because, in actuality, following surgically excision, the tumor is not dissected from the gland proper and weighed separately.

References:

1. Medeiros LJ, Weiss LM. New developments in the pathologic diagnosis of adrenal cortical neoplasms: a review. *Am J Clin Pathol.* 1992;97:73-83.

C. Histologic Type

The following histologic classification of adrenal tumors is from the World Health Organization (WHO) classification of tumors of the adrenal gland.¹ Thus, this protocol applies only to adrenal cortical carcinoma and does not apply to other tumor types.

Histologic Classification of Adrenal Tumors

Carcinoma

References:

1. DeLellis RA, Lloyd RV, Heitz PU, Eng C, eds. *World Health Organization Classification of Tumours: Pathology and Genetics of Tumours of Endocrine Organs.* Lyon, France: IARC Press; 2004: 136.

D. Histologic Grade

Adrenal cortical carcinomas are not usually graded on histologic grounds. Severe nuclear atypia, high mitotic count, vascular invasion, tumor necrosis, and other microscopic features may, in combination, support a diagnosis of adrenal cortical carcinoma and should be recorded. When several malignant features are present together (eg, highly atypical nuclei, trabecular growth, necrosis, and many mitoses), the risk of distant metastases is increased.¹⁻⁴ In some studies, specific combinations of features, such as mitotic rates of >5 per 50 high-power fields (HPF) along with atypical mitosis and venous invasion, have been found to correlate with metastasis or recurrence of adrenal cortical carcinomas.^{3,5}

Mitotic index has been identified as a prognostic factor that is independently predictive of behavior, with low- and high-grade categories applied based on ≤ 20 mitoses/50 HPF and > 20 mitoses/50 HPF.^{4,6,7} Other scoring systems are suggested that are able to predict metastatic potential, with 3 x mitotic rate ($> 5/50$ HPF) + 5 x presence of necrosis + proliferation index in the most proliferative areas.⁸ Further, Ki-67 has been found to show a superior

performance of estimating proliferative rate compared to mitotic count in hematoxylin-eosin sections, suggested to be a better prognostic indicator in overall patient survival.⁹ Finally, a reticulin algorithm has been recommended to assess change in reticulin pattern of staining based on necrosis, high mitotic rate, and vascular invasion.^{10,11}

The criteria used in adults to separate benign from malignant cortical tumors are not entirely applicable to adrenocortical tumors in pediatric age groups. Further, pediatric adrenocortical neoplasms showing histologic features worrisome for malignancy in adults (eg, capsular invasion, vascular invasion, increased mitotic activity, atypical mitoses, necrosis) may not be predictive of biologic behavior; such a pediatric adrenocortical neoplasm exhibiting such histologic features may have a clinically benign course. A number of classification schemes attempting to separate benign from malignant pediatric adrenocortical tumors have been proposed. One of these studies is based on the presence (carcinoma) or absence (adenoma) of 4 histologic features (modified Weiss system) including high nuclear grade, necrosis, mitotic rate greater than 5 per 50 HPF, and atypical mitoses⁷; another study found that tumor weight was the only reliable predictor of behavior, with tumors weighing over 500 g being malignant¹²; and another study correlated tumor volume of greater than 200 cm³ and weight greater than 80 g associated with an adverse outcome.¹³ Subsequent to these studies, another study proposed classifying pediatric adrenocortical neoplasms based on a series of 9 criteria including tumor weight greater than 400 g, tumor size greater than 10.5 cm, extension into periadrenal soft tissues and/or adjacent organs, invasion into the vena cava, venous invasion, capsular invasion, presence of tumor necrosis, mitotic rate greater than 15 per 20 HPF, and the presence of atypical mitoses¹⁴; based on this study, the presence of up to 2 of these criteria was associated with a benign outcome, 3 criteria were considered indeterminate for malignancy, and 4 or more criteria were associated with malignant behavior.

The Lin-Weiss-Bisceglia criteria are applied to oncocytic adrenocortical tumors^{15, 16}. The identification of one of the three major criteria (vascular invasion, atypical mitosis, and mitotic activity greater than 5 per 50 HPF) supports the diagnosis of oncocytic adrenocortical carcinoma, whereas the presence of any minor criteria (large tumor size greater than 10 cm and/or tumor weight greater than 200 gram, necrosis, capsular invasion and sinusoidal invasion) warrants the diagnosis of an oncocytic adrenocortical tumor of uncertain malignant potential. The diagnosis of an oncocytic adrenocortical adenoma requires absence of all major and minor criteria.

References:

1. Medeiros LJ, Weiss LM. New developments in the pathologic diagnosis of adrenal cortical neoplasms: a review. *Am J Clin Pathol*. 1992;97:73-83.
2. Hough AJ, Hollifield JW, Page DL, Hartmann WH. Prognostic factors in adrenocortical tumors: a mathematical analysis of clinical and morphologic data. *Am J Clin Pathol*. 1979;72:390-399.
3. Weiss LM. Comparative histologic study of 43 metastasizing and non-metastasizing adrenocortical tumors. *Am J Surg Pathol*. 1984;8:163-169.
4. Weiss LM, Medeiros LJ, Vickery AL. Pathologic features of prognostic significance in adrenal cortical carcinoma. *Am J Surg Pathol*. 1989;13:202-206.
5. Aubert S, Wacrenier A, Leroy X, et al. Weiss system revisited: a clinicopathologic and immunohistochemical study of 49 adrenocortical tumors. *Am J Surg Pathol*. 2002;26:1612-1619.
6. Giordano TJ. The argument for mitotic rate-based grading for the prognostication of adrenocortical carcinoma. *Am J Surg Pathol*. 2011;35(4):471-473.
7. Assie G, Antoni G, Tissier F, et al. Prognostic parameters of metastatic adrenocortical carcinoma. *J Clin Endocrinol Metab*. 2007;92:148-154.
8. Pennanan M, Heiskanen I, Sane T, et al. Helsinki score: a novel model for prediction of metastases in adrenocortical carcinomas. *Hum Pathol*. 2015;46:404-410.
9. Morimoto R, Satoh F, Murakami O, et al. Immunohistochemistry of a proliferation marker Ki67/MIB1 in adrenocortical carcinomas: Ki67/MIB1 labeling index is a predictor for recurrence of adrenocortical carcinomas. *Endocr J*. 2008;55:49-55.
10. Duregon E, Fassina A, Volante M, et al. The reticulin algorithm for adrenocortical tumor diagnosis: a multicentric validation study on 245 unpublished cases. *Am J Surg Pathol*. 2013;37:1433-1440.
11. Papotti M, Libe R, Duregon E, Volante M, Bertherat J, Tissier F. The Weiss score and beyond: histopathology for adrenocortical carcinoma. *Horm Cancer*. 2011;2:333-340.
12. Cagle PT, Hough AJ, Pysker TJ, et al. Comparison of adrenal cortical tumors in children and adults. *Cancer*. 1986;57:2235-2237.
13. Ribeiro RC, Sandrini Neto RS, Schell MJ, Lacerda L, Sambaio GA, Cat I. Adrenocortical carcinoma in children: a study of 40 cases. *J Clin Oncol*. 1990;8:67-74.

14. Wieneke JA, Thompson LD, Heffess CS. Adrenal cortical neoplasms in the pediatric population: a clinicopathologic and immunophenotypic analysis of 83 cases. *Am J Surg Pathol*. 2003;27:867-881.
15. Lin BT, Bonsib SM, Mierau GW, Weiss LM, Medeiros LJ. Oncocytic adrenocortical neoplasms: a report of seven cases and review of the literature. *Am. J. Surg. Pathol* 1998; 22; 603–614.
16. Bisceglia M, Ludovico O, Di Mattia A, et al. Adrenocortical oncocytic tumors: report of 10 cases and review of the literature. *Int J Surg Pathol* 2004; 12; 231–243.

E. Adrenal Incidentalomas

With the technical advancement and availability of radiographic imaging, many asymptomatic adrenal neoplasms are coming to clinical attention at much smaller limits. Such asymptomatic neoplasms are referred to as “adrenal incidentalomas.” Adrenal incidentalomas can present clinical dilemmas to the treating physician. A consensus statement on how to manage adrenal incidentalomas was proposed in 2002.^{1,2} Follow-up and treatment decisions are based on a combination of clinical/laboratory/radiologic parameters and tumor size (<4 cm, 4-6 cm, >6 cm).

References:

1. Grumbach MM, Biller BMK, Braunstein GD, et al. Management of the clinically inapparent adrenal mass (“incidentaloma”). *Ann Intern Med*. 2003;138:424-429.
2. NIH state-of-the-science statement on management of the clinically inapparent adrenal mass (“incidentaloma”). *NIH Consens State Sci Statements*. 2002;19:1-25.

F. Lymphovascular Invasion

According to the Weiss classification,¹ distinguishing between large vessel (venous) and small vessel (capillary/lymphatic) invasion may have an impact on prognosis, with large-caliber vascular space invasion portending a worse prognosis. A recent series also showed that microscopic angioinvasion (venous invasion) defined as tumor cells invading through a vessel wall and intravascular tumor cells admixed with thrombus proved to be the best prognostic parameter, predicting adverse outcome in all adrenal cortical carcinomas as well as within low-grade adrenal cortical carcinomas.² These findings underscore the importance of the identification of angioinvasion in these neoplasms.

References:

1. Weiss LM, Medeiros LJ, Vickery AL. Pathologic features of prognostic significance in adrenal cortical carcinoma. *Am J Surg Pathol*. 1989;13:202-206.
2. Mete O, Gucer H, Kefeli M, Asa SL. Diagnostic and Prognostic Biomarkers of Adrenal Cortical Carcinoma. *Am J Surg Pathol*. 2018;42(2):201-213.

G. Staging

There are several staging systems, including those proposed by MacFarlane¹ and modified by Sullivan et al² and Henley et al³ and the European Network for the Study of Adrenal Tumors (ENSAT) staging scheme^{4,5} with the American Joint Committee on Cancer (AJCC) and the International Union Against Cancer (UICC) accepting the ENSAT as part of the TNM staging system for adrenal cortical carcinoma.⁶

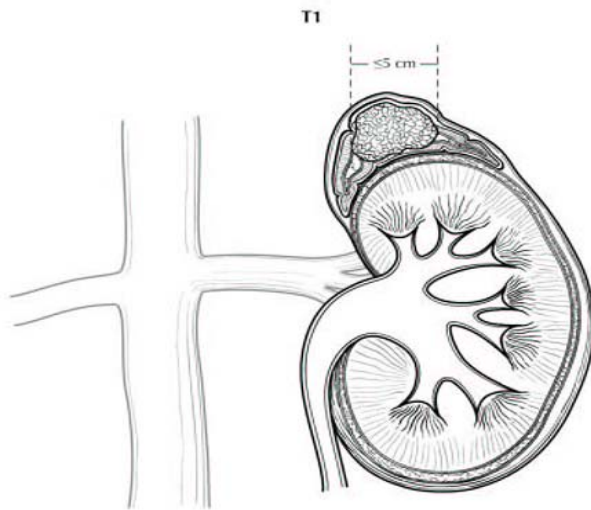


Figure 1. T1: Tumor ≤ 5 cm in greatest dimension, no extra-adrenal invasion. Used with the permission of the American Joint Committee on Cancer (AJCC), Chicago, Illinois. The original source for this material is the *AJCC Cancer Staging Manual*, 8th ed (2017) published by Springer Science and Business Media LLC, www.springerlink.com.

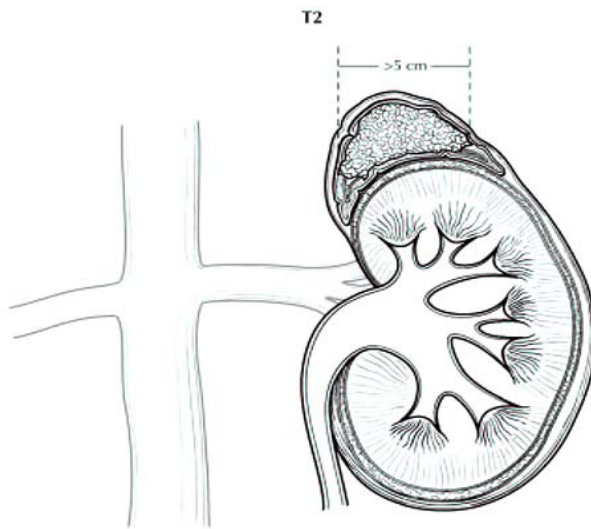


Figure 2. T2: Tumor > 5 cm, no extra-adrenal invasion. Used with the permission of the American Joint Committee on Cancer (AJCC), Chicago, Illinois. The original source for this material is the *AJCC Cancer Staging Manual*, 8th ed (2016) published by Springer Science and Business Media LLC, www.springerlink.com.

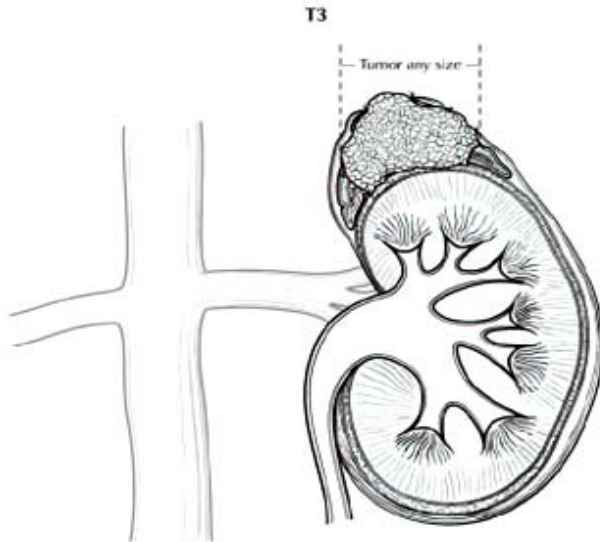


Figure 3. T3: Tumor of any size with local invasion, but not invading adjacent organs. Used with the permission of the American Joint Committee on Cancer (AJCC), Chicago, Illinois. The original source for this material is the *AJCC Cancer Staging Manual*, 8th ed (2017) published by Springer Science and Business Media LLC, www.springerlink.com.

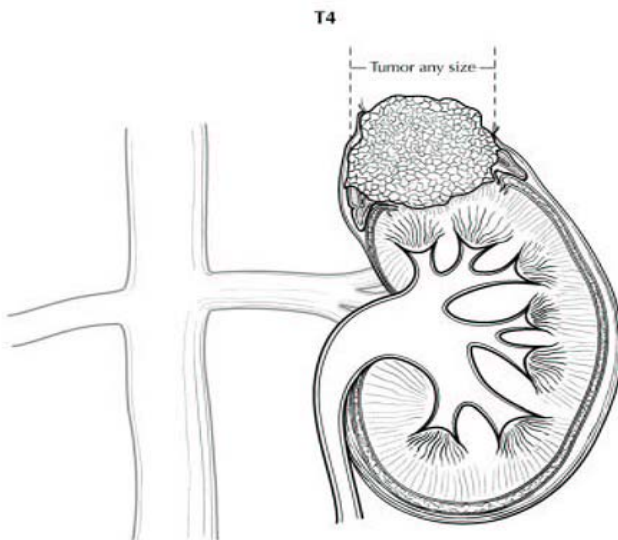


Figure 4. T4: Tumor of any size with invasion of adjacent organs. Used with the permission of the American Joint Committee on Cancer (AJCC), Chicago, Illinois. The original source for this material is the *AJCC Cancer Staging Manual*, 8th ed (2017) published by Springer Science and Business Media LLC, www.springerlink.com.

References:

1. MacFarlane DA. Cancer of the adrenal cortex: the natural history, prognosis, and treatment in a study of fifty-five cases. *Ann R Coll Surg Engl.* 1958;23:155-186.
2. Sullivan M, Boileau M, Hodges CV. Adrenal cortical carcinoma. *J Urol.* 1978;120:660-665.
3. Henley DJ, van Heerden JA, Grant CS, Carney JA, Carpenter PC. Adrenal cortical carcinoma: a continuing challenge. *Surgery.* 1983;94:926-931.
4. Fassnacht M, Johanssen S, Quinkler M, et al. Limited prognostic value of the 2004 International Union Against Cancer staging classification for adrenocortical carcinoma: proposal for a revised TNM classification. *Cancer.* 2009;115:243-250.

5. Lughezzani G, Sun M, Perrotte P, et al. The European Network for the Study of Adrenal Tumors staging system is prognostically superior to the International Union Against Cancer staging system: a North American validation. *Eur J Cancer*. 2010;46:713-719.
6. Amin MB, Edge SB, Greene FL, et al, eds. *AJCC Cancer Staging Manual*. 8th ed. New York, NY: Springer; 2017.

H. Regional Lymph Nodes

Regional lymph nodes include aortic (para-aortic and peri-aortic) and retroperitoneal (peri-nephric and peri-adrenal).

I. Metastatic Sites

Common metastatic sites include liver, lung, and retroperitoneum. Metastases to brain and skin are uncommon, although cutaneous involvement of the scalp can simulate angiosarcoma.¹

References:

1. Lack EE. *Tumors of the Adrenal Gland and Extra-Adrenal Paraganglia*. AFIP Fascicle No. 8. Fourth Series. Washington DC: American Registry of Pathology; 2007.

J. Relevant History

Endocrine manifestations, such as hypertension, change in body habitus, feminization, or virilism, are important, as is the knowledge of whether the patient suffers from an adrenal-related disease or syndrome (eg, Cushing disease, Conn syndrome).

Also of import are family history, previous surgery for adrenal tumors (both benign and malignant) or other endocrine organs, other tumors that may metastasize to the adrenal gland, and endocrine or other therapies. In addition, while the majority of adrenal cortical carcinomas occur sporadically, occasionally adrenal cortical carcinoma may be associated with hereditary cancer syndromes.^{1,2} Such hereditary cancer syndromes include Li-Fraumeni syndrome or SBLA (sarcoma; breast and brain tumors; leukemia, laryngeal carcinoma and lung cancer; and adrenal cortical carcinoma) syndrome,² Beckwith-Weidmann syndrome,¹ and Lynch syndrome^{3,4} Hyperplastic adrenal tissue may re-grow if previously excised incompletely.

References:

1. Hough AJ, Hollifield JW, Page DL, Hartmann WH. Prognostic factors in adrenocortical tumors: a mathematical analysis of clinical and morphologic data. *Am J Clin Pathol*. 1979;72:390-399.
2. Lack EE. *Tumors of the Adrenal Gland and Extra-Adrenal Paraganglia*. AFIP Fascicle No. 8. Fourth Series. Washington DC: American Registry of Pathology; 2007.
3. Raymond VM, Everett JN, Furtado LV, et al. Adrenocortical carcinoma is a Lynch syndrome-associated cancer. *J Clin Endocrinol Metab*. 2013;20:3012-3018.
4. Challis BG, Kandasamy, Powlson AS, et al. Familial adrenocortical carcinoma in association with lynch syndrome. *J Clin Endocrinol Metab*. 2016;101(6):2269-2272.

K. Endocrine Status

Laboratory findings are important in the evaluation of an adrenal mass. Tumors that are functional, ie, secrete cortisol, aldosterone, or sex hormones, tend to be discovered at an earlier stage than nonfunctional tumors. Virilizing tumors are more frequently identified as carcinomas than adenomas. Nonfunctional tumors come to attention due to mass effect and are usually larger.

Adrenal cortical neoplasms that secrete glucocorticoids can also be diagnosed by pathologists by checking the status of the non-tumorous adrenal cortex. In the absence of exogenous cortisol administration, the presence of atrophy in the non-tumorous cortex should prompt the attention of the pathologist to the possibility of glucocorticoid-secreting adrenal cortical neoplasm^{1,2}. This issue is of clinical significance especially in patients with subclinical Cushing syndrome as affected patients may develop Addisonian crisis if postoperative cortisol replacement is not considered. Therefore, the thickness of the nontumorous cortex should be checked in all adrenalectomy specimens. In addition, careful evaluation of the non-tumorous cortex may help to identify underlying pathologies like PPNAD (primary pigmented nodular adrenal cortical disease)³.

Evidence also suggests that functional adrenal cortical carcinomas are biologically more aggressive than non-functional carcinomas ⁴.

References:

1. Duan K, Gomez Hernandez K, Mete O. Clinicopathological correlates of adrenal Cushing's syndrome. *J Clin Pathol*. 2015;68(3):175-186.
2. Mete O, Asa SL. Morphological distinction of cortisol-producing and aldosterone-producing adrenal cortical adenomas: not only possible but a critical clinical responsibility. *Histopathology*. 2012;60(6):1015-1016.
3. Morin E, Mete O, Wasserman JD, Joshua AM, Asa SL, Ezzat S. Carney complex with adrenal cortical carcinoma. *J Clin Endocrinol Metab*. 2012;97(2):E202-206.
4. Zheng S, Cherniack AD, Dewal N, et al. Comprehensive Pan-Genomic Characterization of Adrenocortical Carcinoma. *Cancer Cell*. 2016;29(5):723-736.

L. Ancillary Studies

Special procedures may include frozen sections, cytologic imprints, immunohistochemical stains, histochemical stains, electron microscopy, flow cytometry, molecular studies, and cytogenetic studies. For non-functional tumors, it is important to confirm the adrenal cortical origin by using appropriate biomarkers ¹. Accurate assessment of Ki-67 labeling index is of clinical significance. ^{1,4} Ki-67 labeling index may be performed manually or via image analysis ¹⁻³; if the latter, specifying methodology, software, or technique is suggested. Mismatch repair proteins may be tested, as adrenal cortical carcinoma is recognized in approximately 3% of Lynch syndrome patients.^{5,6}

References:

1. Mete O, Asa SL, Giordano TJ, Papotti M, Sasano H, Volante M. Immunohistochemical Biomarkers of Adrenal Cortical Neoplasms. *Endocr Pathol*. 2018;29(2):137-149.
2. Papathomas TG, Pucci E, Giordano TJ, et al. An International Ki-67 Reproducibility Study in Adrenal Cortical Carcinoma. *Am J Surg Pathol*. 2016;40(4):569-576.
3. Lu H, Papathomas TG, van Zessen D, et al. Automated Selection of Hotspots (ASH): enhanced automated segmentation and adaptive step finding for Ki-67 hotspot detection in adrenal cortical cancer. *Diagn Pathol*. 2014;9:216.
4. Fassnacht M, Dekkers OM, Else T, et al. European Society of Endocrinology Clinical Practice Guidelines on the management of adrenocortical carcinoma in adults, in collaboration with the European Network for the Study of Adrenal Tumors. *Eur J Endocrinol*. 2018;179(4):G1-G46.
5. Raymond VM, Everett JN, Furtado LV, et al. Adrenocortical carcinoma is a Lynch syndrome-associated cancer. *J Clin Endocrinol Metab*. 2013;20:3012-3018.
6. Challis BG, Kandasamy, Powlson AS, et al. Familial adrenocortical carcinoma in association with lynch syndrome. *J Clin Endocrinol Metab*. 2016;101(6):2269-2272.