

## Protocol for the Examination of Specimens From Patients With Carcinoma of the Endometrium

---

Based on AJCC/UICC TNM, 7<sup>th</sup> edition, and FIGO 2014 Annual Report

Protocol web posting date: January 2016

### Procedure

- Hysterectomy

### Authors

Saeid Movahedi-Lankarani, MD\*

Department of Pathology, Abbott Northwestern Hospital, Minneapolis, MN

C. Blake Gilks, MD

Department of Pathology, Vancouver General Hospital, Vancouver, Canada

Christopher N. Otis, MD

Department of Pathology, Baystate Medical Center, Springfield, Massachusetts

Robert Soslow, MD

Department of Pathology, Memorial Sloan Kettering Cancer Center, New York, NY

Esther Oliva, MD†

Department of Pathology, Massachusetts General Hospital, Boston, MA

For the Members of the Cancer Committee, College of American Pathologists

\* Denotes primary author. † Denotes senior author. All other contributing authors are listed alphabetically.

**Previous lead contributors:** Philip A. Branton, MD; William F. Moore, MD; Steven G. Silverberg, MD

© 2016 College of American Pathologists (CAP). All rights reserved.

The College does not permit reproduction of any substantial portion of these protocols without its written authorization. The College hereby authorizes use of these protocols by physicians and other health care providers in reporting on surgical specimens, in teaching, and in carrying out medical research for nonprofit purposes. This authorization does not extend to reproduction or other use of any substantial portion of these protocols for commercial purposes without the written consent of the College.

The CAP also authorizes physicians and other health care practitioners to make modified versions of the Protocols solely for their individual use in reporting on surgical specimens for individual patients, teaching, and carrying out medical research for non-profit purposes.

The CAP further authorizes the following uses by physicians and other health care practitioners, in reporting on surgical specimens for individual patients, in teaching, and in carrying out medical research for non-profit purposes: (1) **Dictation** from the original or modified protocols for the purposes of creating a text-based patient record on paper, or in a word processing document; (2) **Copying** from the original or modified protocols into a text-based patient record on paper, or in a word processing document; (3) The use of a **computerized system** for items (1) and (2), provided that the protocol data is stored intact as a single text-based document, and is not stored as multiple discrete data fields.

Other than uses (1), (2), and (3) above, the CAP does not authorize any use of the Protocols in electronic medical records systems, pathology informatics systems, cancer registry computer systems, computerized databases, mappings between coding works, or any computerized system without a written license from the CAP.

Any public dissemination of the original or modified protocols is prohibited without a written license from the CAP.

The College of American Pathologists offers these protocols to assist pathologists in providing clinically useful and relevant information when reporting results of surgical specimen examinations of surgical specimens. The College regards the reporting elements in the "Surgical Pathology Cancer Case Summary" portion of the protocols as essential elements of the pathology report. However, the manner in which these elements are reported is at the discretion of each specific pathologist, taking into account clinician preferences, institutional policies, and individual practice.

The College developed these protocols as an educational tool to assist pathologists in the useful reporting of relevant information. It did not issue the protocols for use in litigation, reimbursement, or other contexts. Nevertheless, the College recognizes that the protocols might be used by hospitals, attorneys, payers, and others. Indeed, effective January 1, 2004, the Commission on Cancer of the American College of Surgeons mandated the use of the required data elements of the protocols as part of its Cancer Program Standards for Approved Cancer Programs. Therefore, it becomes even more important for pathologists to familiarize themselves with these documents. At the same time, the College cautions that use of the protocols other than for their intended educational purpose may involve additional considerations that are beyond the scope of this document.

The inclusion of a product name or service in a CAP publication should not be construed as an endorsement of such product or service, nor is failure to include the name of a product or service to be construed as disapproval.

## **CAP Endometrium Protocol Revision History**

---

### **Version Code**

The definition of version control and an explanation of version codes can be found at [www.cap.org](http://www.cap.org) (search: cancer protocol terms).

**Version:** Endometrium 3.3.0.0

### **Summary of Changes**

The following changes have been made since the October 2013 release.

The following data elements were modified:

- Specimen Integrity
- Tumor Site
- Tumor Size (changed from required to optional)
- Histologic Type
- Myometrial Invasion
- Tumor Involvement of Cervix
- Peritoneal Ascitic Fluid
- Lymph-Vascular Invasion
- Regional Lymph Nodes
- Distant Metastasis (changed to required only if confirmed pathologically)
- Additional Pathologic Findings

The following data element was added:

- FIGO Stage (not required)

**Surgical Pathology Cancer Case Summary**

---

Protocol web posting date: January 2016

**ENDOMETRIUM: Hysterectomy, With or Without Other Organs or Tissues****Select a single response unless otherwise indicated.****Specimen (select all that apply)**

- Uterine corpus
- Cervix
- Right ovary
- Left ovary
- Right fallopian tube
- Left fallopian tube
- Right parametrium
- Left parametrium
- Vaginal cuff
- Omentum
- Other (specify): \_\_\_\_\_
- Not specified

**Procedure (select all that apply) (Note A)**

- Supracervical hysterectomy
- Simple hysterectomy
- Radical hysterectomy
- Right oophorectomy
- Left oophorectomy
- Right salpingectomy
- Left salpingectomy
- Right salpingo-oophorectomy
- Left salpingo-oophorectomy
- Bilateral salpingo-oophorectomy
- Omentectomy
- Peritoneal biopsies
- Peritoneal washing
- Other (specify): \_\_\_\_\_
- Not specified

**Lymph Node Sampling (select all that apply)**

- Performed
  - Pelvic lymph nodes
  - Para-aortic lymph nodes
  - Other (specify): \_\_\_\_\_
- Not performed
- Not known

**Specimen Integrity (Note A)**

- Morcellated hysterectomy specimen
- Intact hysterectomy specimen
- Other (specify): \_\_\_\_\_

**+ Tumor Site (select all that apply)**

- +  Anterior endometrium
- +  Posterior endometrium
- +  Fundus
- +  Lower uterine segment
- +  Other (specify): \_\_\_\_\_

**+ Tumor Size**

- + Greatest dimension: \_\_\_\_ cm
- + Additional dimensions: \_\_\_\_ x \_\_\_\_ cm
- +  Cannot be determined (explain): \_\_\_\_\_

**Histologic Type (select all that apply) (Note B)**

- Endometrioid adenocarcinoma
- Endometrioid adenocarcinoma with squamous differentiation
- Endometrioid adenocarcinoma, villoglandular
- Endometrioid adenocarcinoma, secretory
- Mucinous adenocarcinoma
- Serous endometrial intraepithelial carcinoma
- Serous carcinoma
- Clear cell carcinoma
- Carcinoid
- Small cell carcinoma
- Large cell neuroendocrine carcinoma
- Mixed cell carcinoma (specify types and percentages): \_\_\_\_\_
- Undifferentiated carcinoma
- Dedifferentiated carcinoma
- Carcinosarcoma (malignant mixed Mullerian tumor)
  - Homologous type
  - Heterologous type (specify heterologous elements): \_\_\_\_\_
  - Epithelial component(s) (specify epithelial cell types and percentages): \_\_\_\_\_
- Other (specify): \_\_\_\_\_

**Histologic Grade (Note C)**

International Federation of Gynecology and Obstetrics (FIGO) Grading System  
(applies to endometrioid and mucinous adenocarcinomas only):

- FIGO grade 1
- FIGO grade 2
- FIGO grade 3

For other carcinomas:

- G1: Well differentiated
- G2: Moderately differentiated
- G3: Poorly differentiated
- Other (specify): \_\_\_\_\_
- Not applicable

**Myometrial Invasion (select all that apply) (Note D)**

- Not identified
- Present
  - Depth of invasion: \_\_\_ mm
  - OR, if exact depth of invasion cannot be determined, state:*
  - Extent of myometrial invasion cannot be determined (explain): \_\_\_\_\_
  - <50% myometrial invasion
  - ≥50% myometrial invasion
  - Myometrial thickness: \_\_\_ mm
  - Myometrial thickness cannot be determined (explain): \_\_\_\_\_

**Tumor Involvement of Cervix (Note E)**

- Not involved
- Involves cervix without stromal invasion
- Invasion of cervical stromal connective tissue
- Cannot be determined (explain): \_\_\_\_\_

**Extent of Involvement of Other Organs (select all that apply)**

- Right ovary
  - Involved
  - Not involved
  - Other (explain): \_\_\_\_\_
- Left ovary
  - Involved
  - Not involved
  - Other (explain): \_\_\_\_\_
- Right fallopian tube
  - Involved
  - Not involved
  - Other (explain): \_\_\_\_\_
- Left fallopian tube
  - Involved
  - Not involved
  - Other (explain): \_\_\_\_\_
- +  Vagina
  - +  Involved
  - +  Not involved
- +  Right parametrium
  - +  Involved
  - +  Not involved
- +  Left parametrium
  - +  Involved
  - +  Not involved
- +  Omentum
  - +  Involved
  - +  Not involved
- +  Rectal wall
  - +  Involved
  - +  Not involved
- +  Bladder wall
  - +  Involved
  - +  Not involved
- +  Pelvic wall
  - +  Involved
  - +  Not involved

+ Data elements preceded by this symbol are not required. However, these elements may be clinically important but are not yet validated or regularly used in patient management.

- + \_\_\_ Bladder mucosa and/or bowel mucosa
  - + \_\_\_ Involved
  - + \_\_\_ Not involved
- + \_\_\_ Other (specify): \_\_\_\_\_

**+ Peritoneal Ascitic Fluid (Note F)**

- + \_\_\_ Not performed/unknown
- + \_\_\_ Negative for malignancy (normal/benign)
- + \_\_\_ Atypical and/or suspicious (explain): \_\_\_\_\_
- + \_\_\_ Malignant (positive for malignancy)
- + \_\_\_ Unsatisfactory/nondiagnostic (explain): \_\_\_\_\_

**+ Margins (Note G)**

- + \_\_\_ Cannot be assessed
- + \_\_\_ Uninvolved by invasive carcinoma
  - + Distance of invasive carcinoma from closest margin: \_\_\_ mm
  - + Specify margin: \_\_\_\_\_
- + \_\_\_ Involved by invasive carcinoma
  - + Specify margin(s): \_\_\_\_\_

**Lymph-Vascular Invasion (Note H)**

- \_\_\_ Not identified
- \_\_\_ Present
- \_\_\_ Cannot be determined

**Pathologic Staging (pTNM) (Note I)**TNM Descriptors (required only if applicable) (select all that apply)

- \_\_\_ m (multiple primary tumors)
- \_\_\_ r (recurrent)
- \_\_\_ y (posttreatment)

Primary Tumor (pT)

- \_\_\_ pTX: Primary tumor cannot be assessed
- \_\_\_ pT0: No evidence of primary tumor
- \_\_\_ pT1a: Tumor limited to endometrium or invades less than one-half of the myometrium
- \_\_\_ pT1b: Tumor invades greater than or equal to one-half of the myometrium
- \_\_\_ pT2: Tumor invades stromal connective tissue of the cervix, but does not extend beyond uterus
- \_\_\_ pT3a: Tumor involves serosa and/or adnexa (direct extension or metastasis)
- \_\_\_ pT3b: Vaginal involvement (direct extension or metastasis) or parametrial involvement
- \_\_\_ pT4: Tumor invades bladder mucosa and/or bowel mucosa (bullous edema is not sufficient to classify a tumor as T4)

Regional Lymph Nodes (pN) (select all that apply) (Note I)

- + *Modifier*
- + \_\_\_ (sn)

Category (pN)

- \_\_\_ pNX: Cannot be assessed
- \_\_\_ pN0: No regional lymph node metastasis
- \_\_\_ pN1: Regional lymph node metastasis to pelvic lymph nodes
- \_\_\_ pN2: Regional lymph node metastasis to para-aortic lymph nodes, with or without positive pelvic lymph nodes

\_\_\_ No nodes submitted or found

Pelvic lymph nodes:

\_\_\_ No pelvic nodes submitted or found

*Number of Pelvic Lymph Nodes Examined*

Specify: \_\_\_

\_\_\_ Number cannot be determined (explain): \_\_\_\_\_

*Number of Pelvic Lymph Nodes Involved*

Specify: \_\_\_

\_\_\_ Number cannot be determined (explain): \_\_\_\_\_

Para-aortic lymph nodes:

\_\_\_ No para-aortic nodes submitted or found

*Number of Para-aortic Lymph Nodes Examined*

Specify: \_\_\_

\_\_\_ Number cannot be determined (explain): \_\_\_\_\_

*Number of Para-aortic Lymph Nodes Involved*

Specify: \_\_\_

\_\_\_ Number cannot be determined (explain): \_\_\_\_\_

Other lymph nodes:

Specify site: \_\_\_\_\_

*Number of Other Lymph Nodes Examined*

Specify: \_\_\_

\_\_\_ Number cannot be determined (explain): \_\_\_\_\_

*Number of Other Lymph Nodes Involved*

Specify: \_\_\_

\_\_\_ Number cannot be determined (explain): \_\_\_\_\_

Distant Metastasis (pM) (required only if confirmed pathologically in this case)

\_\_\_ pM1: Distant metastasis (includes metastasis to inguinal lymph nodes, intraperitoneal disease, or lung, liver, or bone metastasis. It excludes metastasis to para-aortic lymph nodes, vagina, pelvic serosa, or adnexa)

Specify site(s), if known: \_\_\_\_\_

+ FIGO Stage

+ I: Tumor confined to the corpus uteri

+ \_\_\_ IA: No or less than half myometrial invasion

+ \_\_\_ IB: Invasion equal to or more than half of the myometrium

+ \_\_\_ II: Tumor invades cervical stroma, but does not extend beyond the uterus

+ III: Local and/or regional spread of the tumor

+ \_\_\_ IIIA: Tumor invades the serosa of the corpus uteri and/or adnexae

+ \_\_\_ IIIB: Vaginal involvement and/ or parametrial involvement

+ IIIC: Metastases to pelvic and/or para-aortic lymph nodes

+ \_\_\_ IIIC1: Positive pelvic nodes

+ \_\_\_ IIIC2: Positive para-aortic nodes with or without positive pelvic lymph nodes

+ IV: Tumor invades bladder and/or bowel mucosa, and/or distant metastases

+ \_\_\_ IVA: Tumor invasion of bladder and/or bowel mucosa

+ \_\_\_ IVB: Distant metastasis, including intraabdominal metastases and/or inguinal nodes

+ Data elements preceded by this symbol are not required. However, these elements may be clinically important but are not yet validated or regularly used in patient management.



**+ Additional Pathologic Findings (select all that apply) (Note J)**

- + \_\_\_ None identified
- + \_\_\_ Hyperplasia without atypia
  - + \_\_\_ Simple without cytologic atypia
  - + \_\_\_ Complex without cytologic atypia
- + \_\_\_ Atypical hyperplasia
  - + \_\_\_ Simple
  - + \_\_\_ Complex
- + \_\_\_ Endometrial intraepithelial neoplasia (EIN)
- + \_\_\_ Other (specify): \_\_\_\_\_

**+ Ancillary Studies**

*Note: For reporting molecular testing, immunohistochemistry, and other cancer biomarker testing results, the CAP endometrium biomarker template should be used. Pending biomarker studies should be listed in the Comments section of this report.*

**+ Clinical History (select all that apply) (Note K)**

- + \_\_\_ Lynch syndrome
- + \_\_\_ Other (specify): \_\_\_\_\_

**+ Comment(s)**

## Explanatory Notes

---

### A. Specimen Type

In rare occasions when an endometrial carcinoma is not suspected, the pathologist may receive a supracervical hysterectomy specimen removed by laparoscopy. The type of procedure should be recorded. It has been reported that hysterectomies performed using certain laparoscopic techniques result in the finding of venous tumor emboli that are likely to be iatrogenic.<sup>1</sup> The significance of morcellation techniques in unsuspected endometrial cancer cases is not known, but there is theoretical risk of spreading tumor cells to the pelvis and peritoneal cavity. Therefore, reporting of such a procedure is important (and listed under Specimen Integrity in the case summary).

### B. Histologic Type

For consistency in reporting, the histologic classification of endometrial carcinoma and hyperplasia proposed by the World Health Organization (WHO), shown below, is recommended.<sup>2</sup>

Endometrioid adenocarcinoma  
 Endometrioid adenocarcinoma with squamous differentiation  
 Endometrioid adenocarcinoma, villoglandular  
 Endometrioid adenocarcinoma, secretory  
 Mucinous adenocarcinoma  
 Serous endometrial intraepithelial carcinoma  
 Serous carcinoma  
 Clear cell carcinoma  
 Low-grade neuroendocrine tumor (carcinoid)  
 High-grade neuroendocrine carcinoma (small cell neuroendocrine carcinoma)  
 High-grade neuroendocrine carcinoma (large cell neuroendocrine carcinoma)  
 Mixed cell carcinoma  
 Undifferentiated carcinoma  
 Dedifferentiated carcinoma  
 Carcinosarcoma (malignant mixed müllerian tumor)  
     Homologous type  
     Heterologous type  
     Epithelial components

# The term *mixed carcinoma* should only be used when 2 or more distinctive subtypes of endometrial carcinoma are identified, each representing more than 10% of the tumor. Optimally, the diagnosis is made on examination of a hysterectomy specimen, but if only a smaller specimen is available, any amount of a second tumor category suffices for the diagnosis. When a carcinoma is classified as “mixed,” the major and minor types and their relative proportions should be specified. High-grade tumors with ambiguous features should be classified as “carcinoma, subtype can not be determined”; however, this is a very infrequent situation and every effort should be made to subclassify such tumors. It should be noted that for mixed endometrioid and serous carcinomas, studies have found variable results regarding tumor behavior based on percentage of the serous component. Some studies have found that tumors with >25% serous component behave like pure serous carcinomas, whereas other studies have shown that tumors with <10% serous component also behave like pure serous carcinomas.<sup>3,4</sup> It is important to be aware that some serous carcinomas may display a glandular architecture.<sup>5</sup> Thus, when a gland-forming endometrial carcinoma shows high-grade nuclear features, the diagnosis of serous carcinoma should be considered. Finally, the term *endometrial intraepithelial carcinoma* is discouraged because it is not uncommon for these lesions to be associated with extrauterine spread.<sup>6-8</sup> Instead, the term *serous endometrial intraepithelial carcinoma* should be used.

In addition, carcinosarcoma (also referred to as malignant müllerian mixed tumor [MMMT]) has been added to the above list of tumors in the case summary. Carcinosarcoma is a high-grade endometrial neoplasm that is staged like endometrial carcinomas because it is thought to represent a high-grade metaplastic carcinoma. The diagnosis of carcinosarcoma requires presence of both a malignant epithelial component and a malignant mesenchymal (sarcomatous) component in the neoplasm, which should not merge.

Proposed Criteria Defining Endometrial Carcinoma versus Endometrial Hyperplasia

- (1) Irregular infiltration of glands associated with an altered fibroblastic stroma (desmoplastic response), or
- (2) Confluent glandular pattern (cribriform growth), or
- (3) Extensive papillary growth pattern, or
- (4) Severe cytologic atypia (G3 nuclear atypia)

Some investigators have offered specific measurements to assess confluent glandular growth more objectively. Kurman and Norris proposed 1.9 mm as a cutoff,<sup>9</sup> whereas Longacre and colleagues proposed 30% as a cutoff.<sup>10</sup> Extensive papillary growth has also been quantitatively measured in 1 study and defined to be at least 4.2 mm in diameter to warrant the diagnosis of carcinoma. However, it is important to note that different investigators did not find these parameters to have the same predictive value.

**C. Histologic Grading**

The International Federation of Gynecology and Obstetrics (FIGO) grading system for carcinomas of the uterine corpus is only officially designated for endometrioid carcinomas and is based on architectural features as follows<sup>11</sup>:

- |         |   |
|---------|---|
| Grade 1 | 5% or less nonsquamous solid growth pattern |
| Grade 2 | 6% to 50% nonsquamous solid growth pattern  |
| Grade 3 | >50% nonsquamous solid growth pattern       |

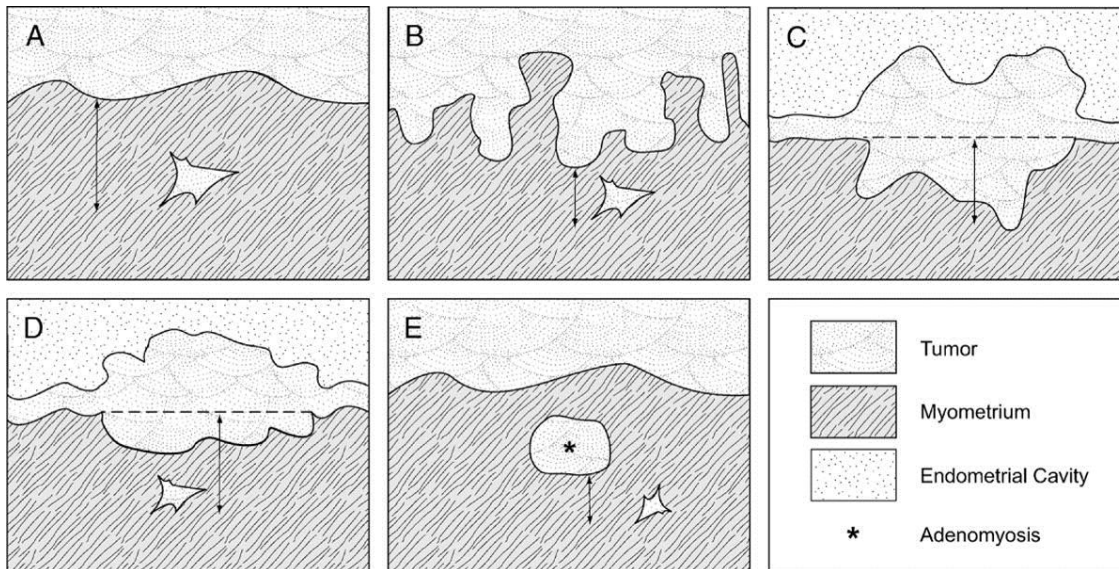
Notable nuclear atypica, which exceeds that which is routinely expected for the architectural grade, increases the tumor grade by 1.

In addition, the following guidelines should be used in grading:

- (1) The squamous component of endometrioid adenocarcinoma should not be graded because the degree of differentiation typically parallels that of the glandular component.<sup>12</sup>
- (2) Because mucinous carcinomas are closely related to endometrioid carcinomas, they can be graded by the same criteria.
- (3) Serous, clear cell, transitional, small cell, undifferentiated carcinomas, and carcinosarcomas are generally considered to be high grade and it is not recommended to assign a FIGO grade to these tumor types.<sup>2,11</sup> When the case summary is being completed, these should be designated as “not applicable” for histologic grade.
- (4) In mixed carcinomas, the highest grade should be assigned.

**D. Myometrial Invasion**

Assessing myometrial invasion may be difficult. Depth of invasion should be measured from the endomyometrial junction to the deepest point of invasion, which may not be easy because the endomyometrial junction in normal conditions is often irregular. In these cases, it is always helpful to look for compressed, nonneoplastic endometrial glands at the nearby endomyometrial junction or even at the base of the tumor. Carcinoma involving adenomyotic foci should not be interpreted as invasive carcinoma. However, the distinction between invasive carcinoma and carcinoma involving adenomyosis may be difficult, because in some cases invasive carcinoma may not elicit stromal response. In the absence of adenomyosis uninvolved by tumor in other sections of the specimen, a diagnosis of adenomyosis involved by adenocarcinoma should be made with caution. CD10 staining is not helpful in this differential diagnosis because stromal cells surrounding foci of invasive carcinoma are also frequently CD10 positive. There are no rules for determining how to measure the depth of invasion in the rare cases where myoinvasive carcinoma is only encountered in foci of adenomyosis involved by carcinoma. In such cases, it is advised that the distance from the adenomyotic focus to the deepest area of invasion be measured (Figure 1).<sup>13</sup> Therefore, if there is a tumor with a 2-mm focus of myoinvasion from a focus of adenomyosis in the deep myometrium, it is still considered as having <50% myometrial invasion (FIGO stage IA).



**Figure 1.** Schematic of measurement of depth of invasion in (A) tumor with a regular interface; (B) tumor with an irregular endomyometrial interface; (C) and (D) tumor with an exophytic growth; (E) tumor arising from adenomyosis. From Ali A, Black D, Soslow RA. Difficulties in assessing the depth of myometrial invasion in endometrial carcinoma. *Int J Gynecol Pathol.* 2007;26:115-123. Copyright © 2007, Wolters Kluwer Health. Reproduced with permission.

### E. Cervical Involvement

Cervical involvement by endometrial carcinoma has been traditionally divided into 2A when there was only secondary involvement of the endocervical epithelium and 2B when the endometrial carcinoma invaded the cervical stroma. Recently, it has been shown that involvement of the surface endocervical epithelium and/or endocervical glands (either by direct extension or drop metastases) does not have any prognostic significance. Therefore, the American Joint Committee on Cancer (AJCC)/FIGO staging system considers stage II disease only when cervical stromal involvement is seen.

### F. Peritoneal Washings or Ascites Fluid

The prognostic significance of presence of tumor cells in peritoneal washings or ascites fluid is controversial. There are studies that indicate either a worse prognosis or no alteration of prognosis on the basis of positive cytology. Consequently, the newly adopted staging system no longer utilizes positive cytology to alter stage. When collected, however, cytology results should be recorded.

### G. Margins

The paracervical soft tissue is the only true margin in total hysterectomy specimens, and reporting the status of this margin is usually not performed; conversely, reporting the status of the vaginal and parametrial margins in a radical hysterectomy specimen is optional.

### H. Lymph-Vascular Invasion

Lymph-vascular invasion (LVI) indicates whether microscopic lymph-vascular invasion is identified. LVI includes lymphatic invasion, vascular invasion, or lymph-vascular invasion. According to AJCC/International Union Against Cancer (UICC) convention, LVI does not affect the T category indicating local extent of tumor unless specifically included in the definition of a T category.

### I. TNM and FIGO Staging of Endometrial Carcinoma

The TNM staging system for endometrial cancer endorsed by the AJCC and the UICC,<sup>14-16</sup> and the parallel system formulated by FIGO are recommended, as shown below.

According to AJCC/UICC convention, the designation “T” refers to a primary tumor that has not been previously treated. The symbol “p” refers to the pathologic classification of the TNM, as opposed to the clinical classification, and is based on gross and microscopic examination. pT entails a resection of the primary tumor or biopsy

adequate to evaluate the highest pT category, pN entails removal of nodes adequate to validate lymph node metastasis, and pM implies microscopic examination of distant lesions. Clinical classification (cTNM) is usually carried out by the referring physician before treatment during initial evaluation of the patient or when pathologic classification is not possible.

Pathologic staging is usually performed after surgical resection of the primary tumor. Pathologic staging depends on pathologic documentation of the anatomic extent of disease, whether or not the primary tumor has been completely removed. If a biopsied tumor is not resected for any reason (eg, when technically infeasible) and if the highest T and N categories or the M1 category of the tumor can be confirmed microscopically, the criteria for pathologic classification and staging have been satisfied without total removal of the primary cancer.

It is important to note that in endometrial cancer, as in cancer of other organs, the validity of T stage depends upon the adequacy and completeness of the surgical staging.

### Primary Tumor (T)

TNM Category	FIGO Stage	Definition
TX	(--)	Primary tumor cannot be assessed
T0	(--)	No evidence of primary tumor
T1	I	Tumor confined to corpus uteri
T1a	IA	Tumor limited to endometrium or invades less than one-half of the myometrium
T1b	IB	Tumor invades one-half or more of the myometrium
T2	II	Tumor invades stromal connective tissue of the cervix
T3	III	Local and/or regional spread as specified in T3a and T3b, and in FIGO IIIA and IIIB
T3a	IIIA	Tumor involves serosa and/or adnexa (direct extension or metastasis)
T3b	IIIB	Vaginal involvement (direct extension or metastasis) or parametrial involvement
T4 <sup>#</sup>	IVA	Tumor invades bladder mucosa <sup>#</sup> and/or bowel mucosa <sup>#</sup>

<sup>#</sup> Presence of bullous edema is not sufficient evidence to classify a tumor as T4.

### Regional Lymph Nodes (N):<sup>#</sup> TNM Staging System

NX		Regional lymph nodes cannot be assessed
N0		No regional lymph node metastasis
N1	IIIC1	Regional lymph node metastasis to pelvic lymph nodes
N2	IIIC2	Regional lymph node metastasis to para-aortic lymph nodes with or without positive pelvic lymph nodes

<sup>#</sup> Regional lymph nodes include the pelvic, obturator, internal iliac (hypogastric), external iliac, common iliac, para-aortic, presacral, and parametrial lymph nodes.

### Distant Metastasis (M): TNM Staging System

M0		No distant metastasis
M1	IVB	Distant metastasis (includes metastasis to abdominal lymph nodes [other than para-aortic], and/or inguinal lymph nodes; excludes metastasis to vagina, pelvic serosa, or adnexa)

### TNM Stage Groupings

Stage 0	Tis	N0	M0
Stage IA	T1a	N0	M0
Stage IB	T1b	N0	M0
Stage II	T2	N0	M0
Stage IIIA	T3a	N0	M0
Stage IIIB	T3b	N0	M0
Stage IIIC1	T1-T3	N1	M0
Stage IIIC2	T1-T3	N2	M0
Stage IVA	T4	Any N	M0

Stage IVB      Any T              Any N              M1

### TNM Descriptors

For identification of special cases of TNM or pTNM classifications, the “m” suffix and “y,” “r,” and “a” prefixes are used. Although they do not affect the stage grouping, they indicate cases needing separate analysis.

The “m” suffix indicates the presence of multiple primary tumors in a single site and is recorded in parentheses: pT(m)NM.

The “y” prefix indicates those cases in which classification is performed during or after initial multimodality therapy (ie, neoadjuvant chemotherapy, radiation therapy, or both chemotherapy and radiation therapy). The cTNM or pTNM category is identified by a “y” prefix. The ycTNM or ypTNM categorizes the extent of tumor actually present at the time of that examination. The “y” categorization is not an estimate of tumor before multimodality therapy (ie, before initiation of neoadjuvant therapy).

The “r” prefix indicates a recurrent tumor when staged after a documented disease-free interval and is identified by the “r” prefix: rTNM.

The “a” prefix designates the stage determined at autopsy: aTNM.

### Additional Descriptors

#### Residual Tumor (R)

Tumor remaining in a patient after therapy with curative intent (eg, surgical resection for cure) is categorized by a system known as R classification, shown below.

RX	Presence of residual tumor cannot be assessed
R0	No residual tumor
R1	Microscopic residual tumor
R2	Macroscopic residual tumor

For the surgeon, the R classification may be useful to indicate the known or assumed status of the completeness of a surgical excision. For the pathologist, the R classification is relevant to the status of the margins of a surgical resection specimen. That is, tumor involving the resection margin on pathologic examination may be assumed to correspond to residual tumor in the patient and may be classified as macroscopic or microscopic according to the findings at the specimen margin(s).

#### Regional Lymph Nodes and Sentinel Lymph Nodes (sn): Isolated Tumor Cells

Isolated tumor cells (ITCs) are single cells or small clusters of cells not more than 0.2 mm in greatest dimension. Lymph nodes or distant sites with ITCs found by either histologic examination (eg, immunohistochemical evaluation for cytokeratin) or nonmorphological techniques (eg, flow cytometry, DNA analysis, polymerase chain reaction [PCR] amplification of a specific tumor marker) should be so identified. There is currently no guidance in the literature as to how these patients should be coded; until more data are available, they should be coded as “N0(i+)” with a comment noting how the cells were identified.

There is little data to assign risk for nonsentinel lymph node metastasis based on the size of the metastasis in the sentinel lymph node. However, the size criteria for micrometastasis and macrometastasis is adopted from the experience in breast carcinoma. Micrometastasis is defined as a metastasis measuring greater than 0.2 mm but equal to or less than 2 mm.

### J. Additional Findings

#### Endometrial Intraepithelial Neoplasia

In part because of poor agreement in the diagnosis of atypical hyperplasia of the endometrium under the WHO criteria,<sup>2,17,18</sup> a new diagnostic terminology, *endometrial intraepithelial neoplasia (EIN)*, has been proposed. EIN describes a clonal expansion of premalignant endometrial glands with endometrioid features, but without invasion. Microscopic criteria proposed to diagnose this lesion include<sup>19</sup>:

- (1) Architecturally crowded glands whose volume percentage stroma (VPS) is <55%
- (2) Measurement of at least 1 to 2 mm in diameter
- (3) Altered/demarcated cytology from the background endometrial glands; not part of a benign mimic with focal glandular crowding (such as a polyp).

### K. Clinical History

Colon carcinoma is the most common malignancy in hereditary nonpolyposis colon cancer (HNPCC; Lynch syndrome). However, endometrial carcinoma develops before colon carcinoma in >50% of women with HNPCC.<sup>20-23</sup> Still, the reported series of HNPCC-related endometrial carcinomas are much smaller in number than those reported for HNPCC colonic carcinoma. Histopathologic features suggestive of HNPCC-related carcinoma are well characterized in the colon, but not in the uterus. However, when examining an endometrial carcinoma in a patient under 50 years of age or with a personal or family history of colon carcinoma, it is important to consider the possibility of an HNPCC-related endometrial carcinoma. In these cases, testing for defective DNA mismatch repair may be performed by immunohistochemistry (MLH1, MSH2, MSH6, and PMS2 antibodies are commercially available). Loss of MSH2 expression essentially always indicates Lynch syndrome and MSH6 is related to MSH2. HNPCC-related endometrial carcinoma is predominantly associated with MSH2 mutations, and MSH6 mutations in particular.<sup>20-23</sup> PMS2 loss is often associated with loss of MLH1 and is only independently meaningful if MLH1 is intact. In addition, PCR assays can be used to detect high levels of microsatellite alterations (MSI), a condition that is definitional for defective DNA mismatch repair. This testing is performed on paraffin-embedded tissue and compares the results of tumor DNA to those of nonneoplastic tissues from the same patient. Please refer to the CAP endometrial cancer biomarker reporting template on [www.cap.org](http://www.cap.org) for further details.

### References

1. Logani S, Herdman AV, Little JV, Moller KA. Vascular "pseudo invasion" in laparoscopic hysterectomy specimens: a diagnostic pitfall. *Am J Surg Pathol*. 2008;32:560-565.
2. Kurman RJ, Carcangiu ML, Harrington CS, Young RH, eds. *WHO Classification of Tumors of the Female Reproductive Organs*. Geneva, Switzerland: WHO Press; 2014. *World Health Organization Classification of Tumors*. 4<sup>th</sup> edition.
3. Williams KE, Waters ED, Woolas RP, Hammond IG, McCartney AJ. Mixed serous-endometrioid carcinoma of the uterus: pathologic and cytopathologic analysis of a high-risk endometrial carcinoma. *Int J Gynecol Cancer*. 1994;4:7-18.
4. Lim P, Al Kushi A, Gilks B, Wong F, Aquino-Parsons C. Early stage papillary serous carcinoma of the endometrium: effect of adjuvant whole abdominal radiotherapy and pathologic parameters on outcome. *Cancer*. 2001;91:752-757.
5. Darvishian F, Hummer A, Thaler H, et al. Serous endometrial cancers that mimic endometrioid adenocarcinomas: a clinicopathologic and immunohistochemical study of a group of problematic cases. *Am J Surg Pathol*. 2004;28:1568-1578.
6. Soslow RA, Pirog E, Isacson C. Endometrial intraepithelial carcinoma with peritoneal dissemination. *Am J Surg Pathol*. 2000;24:726-732.
7. Ambros RA, Sherman ME, Zahn CM, Bitterman P, Kurman RJ. Endometrial intraepithelial carcinoma: a distinctive lesion specifically associated with tumors displaying serous differentiation. *Hum Pathol*. 1995;26:1260-1267.
8. Hui P, Kelly M, O'Malley DM, Tavassoli F, Schwartz PE. Minimal uterine serous carcinoma: a clinicopathological study of 40 cases. *Mod Pathol*. 2005;18:75-82.
9. Kurman RJ, Norris HJ. Evaluation of criteria for distinguishing atypical endometrial hyperplasia from well-differentiated carcinoma. *Cancer*. 1982;2547-2559.
10. Longacre TA, Chumg MH, Jensen DN, Hendrickson MR. Proposed criteria for the diagnosis of well-differentiated endometrial carcinoma: a diagnostic test for myoinvasion. *Am J Surg Pathol*. 1995;19:371-406.
11. Creasman W, Odicino F, Maisonneuve P, et al. Carcinoma of the corpus uteri: FIGO Annual Report. *J Epidemiol Biostat*. 2001;6:45-86.
12. Zaino RJ, Kurman RJ. Squamous differentiation in carcinoma of the endometrium: a critical appraisal of adenoacanthoma and adenosquamous carcinoma. *Sem Diagn Pathol*. 1988;5:154-171.
13. Ali A, Black D, Soslow RA. Difficulties in assessing the depth of myometrial invasion in endometrial carcinoma. *Int J Gynecol Pathol*. 2007;26:115-123.

14. Edge SB, Byrd DR, Carducci MA, Compton CA, eds. *AJCC Cancer Staging Manual*. 7th ed. New York, NY: Springer; 2009.
15. Sobin LH, Gospodarowicz M, Wittekind CH, eds. *UICC TNM Classification of Malignant Tumours*. 7th ed. New York, NY: Wiley-Liss; 2009.
16. Wittekind C, Henson DE, Hutter RVP, Sobin LH, eds. *TNM Supplement: A Commentary on Uniform Use*. 2<sup>nd</sup> ed. New York, NY: Wiley-Liss; 2001.
17. Kendall BS, Ronnett BM, Isacson D, et al. Reproducibility of the diagnosis of endometrial hyperplasia, atypical hyperplasia, and well-differentiated carcinoma. *Am J Surg Pathol*. 1998;22(8):1012-1019.
18. Zaino RJ. International Society of Gynecological Pathologists Symposium on Endometrial Hyperplasia. III. Endometrial hyperplasia - is it time for a quantum leap to a new classification? *Int J Gynecol Pathol*. 2000;19(4):314-321.
19. Mutter GL. International Society of Gynecological Pathologists Symposium on Endometrial Hyperplasia. I. Histopathology of genetically defined endometrial precancers. *Int J Gynecol Pathol*. 2000;19(4):301-309.
20. Aarnio M, Sankila R, Pukkala E, Salovaara R, Aaltonen LA, de la Chapelle A, Peltomäki P, Mecklin JP, Järvinen HJ. Cancer risk in mutation carriers of DNA-mismatch-repair genes. *Int J Cancer*. 1999;81:214-218.
21. Watson P, Vasen HF, Mecklin JP, Järvinen H, Lynch HT. The risk of endometrial cancer in hereditary nonpolyposis colorectal cancer. *Am J Med*. 1994;96:516-520.
22. Wijnen J, de Leeuw W, Vasen H, et al. Familial endometrial cancer in female carriers of MSH6 germline mutations. *Nat Genet*. 1999;23:142-144.
23. Charames GS, Millar AL, Pal T, Narod S, Bapat B. Do MSH6 mutations contribute to double primary cancers of the colorectum and endometrium? *Hum Genet*. 2000;107:623-629.

**Bibliography**

Oncology FCoG. FIGO staging for carcinoma of the vulva, cervix, and corpus uteri. *Int J Gynaecol Obstet*. 2014;125:97-98.