



Protocol for the Examination of Specimens From Pediatric Patients With Ewing Sarcoma*

Version: EwingSarcoma 3.2.0.1

Protocol Posting Date: August 2016

This protocol is **NOT** required for accreditation purposes.

*This protocol applies to pediatric patients with osseous and extraosseous Ewing sarcoma family of tumors, including peripheral primitive neuroectodermal tumor.

The following should **NOT** be reported using this protocol:

Tumor Type
Adult Ewing sarcoma [#] (consider using bone or soft tissue protocols)

[#]Ewing sarcoma in adults may be treated differently than pediatric Ewing sarcoma, and use of the AJCC TNM staging system remains appropriate for these patients.

Authors

Erin Rudzinski, MD*; Bruce Pawel, MD*; Armita Bahrami, MD; M. John Hicks, MD;

With guidance from the CAP Cancer and CAP Pathology Electronic Reporting Committees.

* Denotes primary author. All other contributing authors are listed alphabetically.

Accreditation Requirements

The use of this protocol is recommended for clinical care purposes, but is not required for accreditation purposes.

CAP Laboratory Accreditation Program Protocol Required Use Date: Not applicable

Important Note (Note A)

Ewing sarcoma family of tumors includes both peripheral primitive neuroectodermal tumor (PNET) and Ewing sarcoma (ES), which occur in children and adults. This malignancy may occur in bone or soft tissue sites, including unusual sites such as skin or leptomeninges.^{1,2} Because ES can occur in bone or soft tissue, AJCC/UICC staging systems for both are included.

First priority should always be given to formalin-fixed tissue for histomorphologic evaluation. Special studies (eg, cytogenetics, fluorescence in situ hybridization [FISH], reverse transcriptase polymerase chain reaction [RT-PCR], and less commonly next-generation sequencing, whole genome and exome analyses) are critical to the molecular workup of ES and require at least 100 mg of viable, fresh or snap-frozen tissue as the second priority for workup (Note A). Although molecular testing for FISH analysis of *EWSR1* rearrangement or for RT-PCR analysis of *EWSR1-FLI1*, *EWSR1-ERG*, and other ES translocations may be performed on formalin-fixed paraffin-embedded tissue, every attempt should be made to procure fresh tissue, as this may be a requirement for some treatment protocols.

This protocol is based on the experience of the Children's Oncology Group.
For more information, contact The Children's Oncology Group Biopathology Center.
Phone: (614) 722-2890 or (800) 347-2486.

Surgical Pathology Cancer Case Summary

Protocol posting date: August 2016

EWING SARCOMA: Biopsy

Note: This case summary is recommended for reporting Ewing Sarcoma, but is not required for accreditation purposes.

Select a single response unless otherwise indicated.

Procedure (Note B)

- Core needle biopsy
- Incisional biopsy
- Excisional biopsy
- Other (specify): _____
- Not specified

Tumor Site

- Specify site (if known): _____
- Not specified

Tumor Size (Note B)

- Greatest dimension: ___ cm
- + Additional dimensions: ___ x ___ cm
- Cannot be determined (explain): _____

+ Extent of Osseous Tumors (select all that apply)

- + Diaphysis
- + Metaphysis
- + Medullary cavity
- + Tumor extension into soft tissue
- + Other (specify): _____
- + Not specified
- + Cannot be determined

+ Extent of Primary Extrasseous Tumors (select all that apply) (Note C)

- + Dermal
- + Subcutaneous/suprafascial
- + Subfascial
- + Intramuscular
- + Intraabdominal/pelvic
- + Retroperitoneal
- + Chest wall
- + Other (specify): _____
- + Not specified
- + Cannot be determined

Margins (for excisional biopsy only) (Note D)

- Cannot be assessed
- Uninvolved by tumor
 - Distance of tumor from closest bone margin: ___ cm (required only if applicable)
 - Distance of tumor from closest soft tissue margin: ___ cm (required only if applicable)
 - Distance of tumor from closest other (eg, parenchymal) margin: ___ cm (required only if applicable)
- Involved by tumor

Specify margin(s): _____

+ Lymph-Vascular Invasion (Note E)

- + ___ Not identified
- + ___ Present
- + ___ Cannot be determined

Prebiopsy Treatment (select all that apply)

- ___ No known prebiopsy therapy
- ___ Chemotherapy performed
- ___ Radiation therapy performed
- ___ Therapy performed, type not specified
- ___ Not specified

Treatment Effect (required only if applicable) (Note F)

- ___ No known prebiopsy therapy (not applicable)
- ___ No necrosis identified
- ___ Necrosis present
 - + Percent tumor necrosis: ___%
- ___ Percent tumor necrosis cannot be determined

+ Additional Pathologic Findings

+ Specify: _____

+ Ancillary Studies (select all that apply) (Note G)

Note: Results of these studies may not be available at the time of the final report

- + ___ Not performed
- + ___ Pending
- + ___ EWSR1 rearrangement present
 - + ___ Fusion partner not known
 - + ___ Fusion partner known
 - + ___ FLI1
 - + ___ ERG
 - + ___ Other (specify): _____
- + ___ Other (non-EWSR1 variant translocation) (specify): _____
- + ___ No rearrangement identified

+ Method

- + ___ Conventional karyotyping
- + ___ Fluorescent in situ hybridization (FISH)
- + ___ Reverse transcriptase polymerase chain reaction (RT-PCR)
- + ___ Other (specify): _____

+ Comment(s)

Surgical Pathology Cancer Case Summary

Protocol posting date: August 2016

EWING SARCOMA: Resection**Note: This case summary is recommended for reporting Ewing Sarcoma, but is not required for accreditation purposes.****Select a single response unless otherwise indicated.****Procedure (Note B)**

- Resection
 Amputation (specify type): _____
 Limb salvage procedure (specify type): _____
 Other (specify): _____
 Not specified

Tumor Site

- Specify site(s): _____
 Not specified

Tumor Size (Note B)

- Greatest dimension: ___ cm
 + Additional dimensions: ___ x ___ cm
 Cannot be determined (explain): _____

+ Extent of Tumor (primary osseous tumors) (select all that apply)

- + Diaphysis
 + Metaphysis
 + Medullary cavity
 + Tumor extension into soft tissue
 + Other (specify): _____
 + Not specified
 + Cannot be determined

+ Extent of Tumor (primary extraosseous tumors) (select all that apply)

- + Dermal
 + Subcutaneous/subfascial
 + Subfascial
 + Intramuscular
 + Intraabdominal/pelvic
 + Retroperitoneal
 + Other (specify): _____
 + Not specified
 + Cannot be determined

Margins (Note D)

- Cannot be assessed
 Uninvolved by tumor
 Distance of tumor from closest bone margin: ___ cm (required only if applicable)
 Distance of tumor from closest soft tissue margin: ___ cm (required only if applicable)
 Distance of tumor from closest other (eg, parenchymal) margin: ___ cm (required only if applicable)
 Involved by tumor
 Specify margin(s): _____

+ Lymph-Vascular Invasion (Note E)

- + Not identified
- + Present
- + Cannot be determined

Preresection Treatment (select all that apply)

- No known preresection therapy
- Chemotherapy performed
- Radiation therapy performed
- Therapy performed, type not specified
- Not specified

Treatment effect (required only if applicable) (Note F)

- No known preresection therapy (not applicable)
- Necrosis not identified
- Necrosis present
 - + Percent tumor necrosis: _____%
- Percent tumor necrosis cannot be determined

+ Ancillary Studies (select all that apply) (Note G)

Note: Results of these studies may not be available at the time of the final report

- + Not performed
- + Pending
- + EWSR1 rearrangement present
 - + Fusion partner not known
 - + Fusion partner known
 - + FLI1
 - + ERG
 - + Other (specify): _____
- + Other (non-EWSR1 variant translocation) (specify): _____
- + No rearrangement identified

+Method

- + Conventional karyotyping
- + Fluorescent in situ hybridization (FISH)
- + Reverse transcriptase polymerase chain reaction (RT-PCR)
- + Other

Regional Lymph Nodes

- No nodes submitted or found

Number of Lymph Nodes Examined

- Specify: _____
- Number cannot be determined (explain): _____

Number of Lymph Nodes Involved

- Specify: _____
- Number cannot be determined (explain): _____

Distant Metastasis (pM) (required only if confirmed pathologically in this case)

- Present
 - Specify site(s), if known: _____

+Pathologic Staging (pTNM) (Note H)

Note: The AJCC staging systems for bone and soft tissue based tumors may be used for pathologic staging if desired. See Note H.

+ Additional Pathologic Findings

+ Specify: _____

+ Comment(s)

Explanatory Notes

A. Tissue Handling

Tissue specimens optimally are received fresh/unfixed because of the importance of ancillary studies, such as cytogenetics and molecular testing, which require fresh tissue. First priority should always be given to formalin-fixed tissues for morphologic evaluation, followed by submission of fresh tissue for cytogenetics and/or snap freezing a minimum of 100 mg of viable tumor for potential molecular studies.¹ Molecular testing on formalin-fixed paraffin-embedded tissue may be performed for FISH evaluation of *EWSR1* rearrangement and for RT-PCR evaluation of *EWSR1-FLI1*, *EWSR1-ERG*, and other ES translocations. When the amount of tissue is limited, the pathologist can keep the frozen tissue aliquot used for frozen section (usually done to determine sample adequacy and viability) in a frozen state (-70°C is preferable). Translocations may be detected using RT-PCR on frozen or fixed paraffin-embedded tissue, or FISH on touch preparations made from fresh tissue or formalin-fixed paraffin-embedded tissue.

Note that classification of many subtypes of sarcoma is not always dependent upon special studies, such as cytogenetics or molecular genetics, but frozen tissue may be required to enter patients into treatment protocols. Discretion should be used in triaging tissue from sarcomas. Adequate tissue should be submitted for conventional light microscopy before tissue has been taken for cytogenetics, electron microscopy, or molecular analysis.

B. Procedures

Cytologic Material

Cytological material is usually sufficient to diagnose ES (with supportive immunostains) (Note G).² An important limitation of fine-needle aspiration is the limited amount of tissue for additional molecular diagnostic studies¹ and tissue banking (see Note A). Evaluation by a pathologist at the time of the fine-needle biopsy procedure is important to assess the adequacy of the specimen for routine histomorphologic diagnosis and for ancillary studies.

If cytologic material includes fluid, such as pleural effusions or fluid from a liquefactive tumor, the fluid should be centrifuged and the resulting pellet fixed with formalin prior to making a paraffin cell block. The resulting cell block allows for histopathologic examination and immunocytochemical, RT-PCR, and FISH analyses.

Biopsy (Needle, Incisional, Excisional)

Core needle biopsies can obtain sufficient material for special studies and histomorphologic diagnosis. Open incisional biopsy is generally the preferred and most widely used technique, because it consistently provides a larger sample of tissue and maximizes the opportunity for a specific pathologic diagnosis.³ Excisional biopsy may not include an adequate margin of normal tissue, even with an operative impression of total gross removal.³

In cases of nonexcisional biopsy (eg, core biopsy, incisional biopsy), the tumor size cannot be determined on pathologic grounds; therefore, imaging data (computed tomography [CT], magnetic resonance imaging [MRI], etc) can be used instead.

Tumor Resection

Resection specimens may be intralesional, marginal, wide, or radical in extent.⁴ Intralesional resections extend through tumor planes, with gross or microscopic residual tumor identifiable at surgical margins. A marginal resection involves a margin formed by reactive tissue surrounding the tumor. A wide radical resection has surgical margins that extend through normal tissue, usually external to the anatomic compartment containing the tumor. For all types of resections, marking (tattoo with ink followed by use of a mordant) and orientation of the specimen (*prior to cutting*) by the surgeon are highly recommended for accurate pathologic evaluation.³ Full representative mapping of the specimen is also recommended,³ as discussed below.

A full sagittal section of a bone tumor resection specimen,⁵ as illustrated in Figure 1, allows for mapping of the entire central face of the tumor and adjacent marginal tissue. Sectioning the specimen in a longitudinal plane that allows for evaluation of the tumor in its greatest cross-sectional dimension is important. Soft tissue and bone marrow margins should be inked and taken prior to sectioning the specimen with both amputation and limb salvage specimens. Freezing of the specimen and cutting with a bone saw (with intraosseous specimens) is the

preferred method. This face of the specimen should be documented using digital imaging photography or alternatively by a photocopy of the specimen when sealed in a plastic bag. As shown in Figure 1 of an amputation specimen with soft tissue in place, the central full face of the specimen and lesional region can be mapped and blocked following fixation and with adequate decalcification for complete microscopic examination, including estimate of percentage of tumor necrosis. Use of a commercially available formic acid-formaldehyde decalcification solution is recommended, as this provides a less harsh decalcification method and allows for retention of antigens for immunohistochemistry and preservation of DNA for possible molecular studies on formalin-fixed paraffin-embedded tissue.

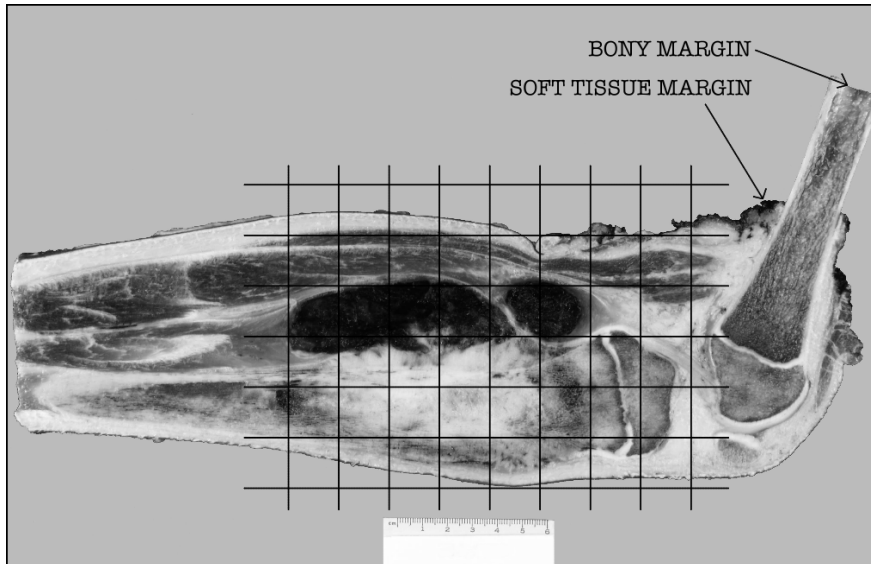


Figure 1. Grid diagram of histologic sections taken, superimposed on photograph of a sagittally-sectioned amputation specimen including the distal femur and proximal tibia.

C. Extent of Tumor

Tumors involving the soft tissue of the chest wall and/or the ribs, without conclusive evidence of origin from bone (Askin tumors), should be denoted as “chest wall.” Medulloblastomas and primitive neuroectodermal tumors of the central nervous system (CNS) are pathologically different neoplasms and should not be included in this protocol. However, intracranial ES originating in non-CNS soft tissues such as the meninges should be included.

D. Margins

The extent of resection (ie, gross residual disease versus complete resection with negative margins) has the strongest influence on local control of malignancy.^{6,7} The definition of what constitutes a sufficiently “wide” margin of normal tissue in the management of ES and the significance of reactive and/or necrotic tissue at the margin are current study questions for the Children’s Oncology Group, and may evolve in the future. Currently, any tumor at the margin, either viable, nonviable, or treated, is considered positive. The significance of treated tumor at the margin when there has been an excellent chemotherapeutic response (ie, >90% tumor necrosis) remains unclear. There is currently no consensus as to whether margins involved by treated tumor require further treatment, and this is considered a negative margin on some studies. The presence of treated tumor at the margin should be reported, however, and can be included in the comment section of the checklist. The following margins are considered adequate:

Bone margin: 2 to 5 cm
Fascia, periosteum, and intermuscular septa: 2 mm
Fat, muscle, and medullary bone: 5 mm

With Ewing sarcoma involving an encapsulated organ, surgical margins are considered to be negative if the organ’s capsule is not surgically violated or breached by the tumor.

E. Lymph-Vascular Invasion (LVI)

Lymphovascular invasion (LVI) indicates whether microscopic lymphovascular invasion is identified in the pathology report. LVI includes lymphatic invasion, vascular invasion, or lymphovascular invasion. Evaluation of LVI may require immunohistochemical staining for endothelial markers (CD31, CD34, D240, etc). By American Joint Committee on Cancer (AJCC) and International Union Against Cancer (UICC) convention, LVI does not affect the T category indicating local extent of tumor unless specifically included in the definition of the T category.

F. Prognostic Factors

Typically, ES has a lobular growth pattern consisting of tumor cells that are distinctly monotonous in their nuclear uniformity. Nuclei measure 10 µm to 15 µm in diameter with distinct nuclear membranes, finely granular chromatin, and 1 to 2 inconspicuous nucleoli. Cytoplasm is poorly defined, scant, pale-staining, and may be vacuolated due to irregular glycogen deposition. Atypical variants may show increased nuclear size, more pronounced atypia, and increased mitotic activity. Multinucleate giant cells are not seen. Large areas of tumor necrosis with “ghost-like tumor cells” may be striking and in some biopsy specimens may represent the majority of the tumor. Areas of neuroectodermal differentiation (Homer-Wright rosettes; rarely Flexner-Wintersteiner rosettes or primitive neuroepithelium) may be evident in some tumors.

Currently, extraosseous Ewing sarcoma receives identical therapy as intraosseous Ewing sarcoma. There are no histopathologic ES subtypes that possess an established prognostic importance.⁸

A summary of the prognostic factors is detailed below.⁹ Of all prognostic factors, age at onset, tumor size, site, and stage have proven to be the most important in predicting outcome.

Factor	Favorable Prognosis	Unfavorable Prognosis
Age	<10 years (EFS 69%); 10-17 years (EFS 74%)	≥18 years (EFS 44%)
Site	Distal extremity (EFS 74%); Proximal extremity (EFS 62%)	Pelvis (EFS 50%)
Size	<8 cm greatest diameter (EFS 75%)	≥8 cm in greatest dimension (EFS 55%)
Stage	Nonmetastatic tumor (EFS approximately 70%)	Metastatic tumor (EFS approximately 20%)

Definition: EFS, event-free survival.

Histologic response to chemotherapy is an excellent predictor of outcome in osteosarcomas and may also be of value in ES. However, the evaluation of percentage necrosis in ES can be difficult, because unlike osteosarcoma, there is no residual acellular osteoid framework left to demarcate the original tumor bed. Furthermore, data regarding correlation of necrosis with outcome in extraosseous ES is not available. Currently, histologic assessment of percentage necrosis is not used formally to guide therapy in ES; however, it is recommended that the report includes the estimated percentage of necrosis.

G. Ancillary StudiesImmunohistochemistry

Immunohistochemistry with monoclonal antibodies against the cell surface glycoprotein CD99 is positive in virtually all cases of ES.¹⁰ This glycoprotein is diffusely expressed in the vast majority of cases in a *membranous pattern* (Figure 2). The results of staining using monoclonal antibodies O13, HBA71, and 12E7 are similar, but individual tumors may exhibit better staining with one of these antibodies versus other antibodies.

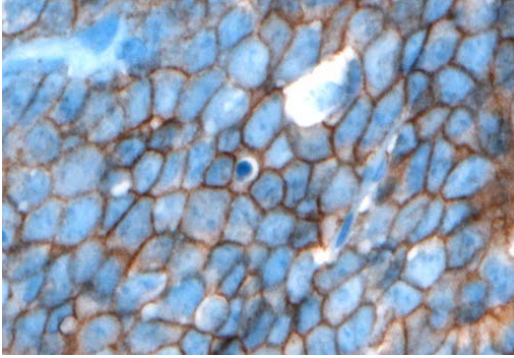


Figure 2. CD99 staining in Ewing sarcoma shows strong, diffuse, membranous staining. (CD99 antibody O13 with hematoxylin counterstain.)

Lymphoblastic lymphomas/leukemias, rhabdomyosarcomas, synovial sarcomas, solitary fibrous tumors, rhabdoid tumors, neuroendocrine tumors, desmoplastic small round cell tumors, and mesenchymal chondrosarcomas may also demonstrate immunoreactivity to CD99.⁸ In some of these tumors, CD99 immunostaining is often weakly granular and intracytoplasmic; in others (lymphoblastic lymphoma/leukemia, occasional cases of poorly differentiated synovial sarcoma, alveolar rhabdomyosarcoma), distinct membrane staining is present, as seen in ES. Because these other tumors with small round cell morphology can exhibit CD99 expression, it is very important to consider including other immunohistochemical stains such as muscle markers (desmin, muscle-specific actin, myoD1, myogenin), S-100, epithelial markers (epithelial membrane antigen, cytokeratin), INI-1, and lymphoid markers (CD45, CD30, Tdt, T-cell and/or B-cell markers) when CD99 is performed to properly exclude CD99-expressing tumors. Cytokeratin positivity may be seen in ES and may be diffusely positive in the adamantinoma-like variant of Ewing sarcoma.^{11,12} The value of other immunohistochemical markers for diagnosis, such as Ki-67, p53, and C-kit (CD117), has not been established. ES is almost always vimentin immunopositive.

Chromosomal Translocations

It is now generally accepted that Ewing sarcoma and PNET form a single group of bone and soft tissue tumors and the 2013 World Health Organization (WHO) classification of bone and soft tissue tumors uses the single terminology, *Ewing sarcoma*. The characteristic translocations involve the *EWSR1* gene at 22q12 and either the *FLI1* gene at 11q24 or the *ERG* gene at 21q22. The presence of t(11;22) (*EWSR1-FLI1*) and t(21;22) (*EWSR1-ERG*) is strongly correlated with ES. The most common gene fusion is the *EWSR1-FLI1* (90% to 95% of patients). It should be emphasized that there are numerous other *EWSR1* gene partners that occur in a minority (5% to 10%) of ES. The failure to identify an *EWSR1-FLI1* or *EWSR1-ERG* translocation by RT-PCR or cytogenetics does not exclude ES from the diagnosis. Cytogenetic studies are important for identification of the less common and rare ES translocations and for discovering novel *EWSR1* translocations in ES. FISH analysis for *EWSR1* is helpful as a first step and may confirm the diagnosis in those tumors with histomorphologic features and immunohistochemical phenotypes of ES. Because other small round cell tumors of childhood can have *EWSR1* rearrangements with specific tumor-defining partners, *EWSR1* FISH positivity alone is not diagnostic of ES. Some of these tumors with *EWSR1* rearrangement include angiomatoid fibrous histiocytoma, clear cell sarcoma of soft parts, desmoplastic round cell tumor, and extraskelatal myxoid chondrosarcoma, as well as a subset of myxoid liposarcomas and myoepithelial carcinoma. This underscores the necessity for histologic and immunohistochemical correlation with FISH and/or cytogenetic data.¹³

Some of the less common ES translocations include: t(7;22)(p22;q12) *EWSR1-ETV1*, t(17;22)(q12;q12) *EWSR1-E1AF*, t(2;22)(q33;q12) *EWSR1-FEV*, and t(1;22)(p36;q12) *EWSR1-ZSG*. In addition, rare cases of ES have been associated with gene rearrangements involving the *FUS* gene, and ES-like tumors have been described with *CIC-DUX4* and *BCOR-CCNB3*.¹⁴

The diagnosis of ES is not dependent upon identifying a “tumor-defining” translocation and may be rendered with the appropriate histomorphologic and immunohistochemical features. The specific *EWSR1* translocation and subtype based upon exon fusion type do not influence treatment, prognosis, or outcome.¹⁵

Electron Microscopy

Ultrastructural studies are valuable despite the putative diagnostic power of immunohistochemistry and molecular studies.¹⁶ ES tumor cells usually have limited cytoplasmic organelles. Some cytoplasmic regions may contain an increased amount of polyparticulate glycogen. The latter correspond to the classical “dot-positivity” noted with the periodic acid-Schiff stain. Furthermore, one may also find intermediate filaments corresponding to vimentin and cytokeratin. In those tumors with neuroendocrine differentiation, neurosecretory granules may occur, but they are pleomorphic and larger than the 100-nm diameter spherical granules of neuroblastoma. Intermediate-type junctions are often present, but true desmosomes are not usually seen.

H. TNM and Stage Groupings

The AJCC/UICC TNM staging system for bone or soft tissue tumors^{17,18} may be used for pathologic staging of Ewing sarcoma and can be reported in the Comment section. However, the presence or absence of metastatic disease (a feature that may not be known to the pathologist) is the primary factor in the staging and treatment of pediatric patients with Ewing sarcoma.

References

1. Qualman SJ, Morotti RA. Risk assignment in pediatric soft-tissue sarcoma: an evolving molecular classification. *Curr Oncol Rep.* 2002;4:123-130.
2. Sanati S, Lu DW, Schmidt E, Perry A, Dehner LP, Pfeifer JD. Cytologic diagnosis of Ewing sarcoma/peripheral neuroectodermal tumor with paired prospective molecular genetic analysis. *Cancer.* 2007;111:192-199.
3. Coffin CM, Dehner LP. Pathologic evaluation of pediatric soft tissue tumors. *Am J Clin Pathol.* 1998;109(suppl 1):S38-S52.
4. Conrad EU, Bradford L, Chonsky HA. Pediatric soft tissue sarcomas. *Orthop Clin North Am.* 1996;27:655-664.
5. Patterson K. The pathologic handling of skeletal tumors. *Am J Clin Pathol.* 1998;109(suppl 1):S53-S66.
6. Marcus KC, Grier HE, Shamberger RC, et al. Childhood soft tissue sarcoma: a 20-year experience. *J Pediatr.* 1997;131:603-607.
7. Fletcher C, Kempson RL, Weiss S. Recommendations for reporting soft tissue sarcomas. *Am J Clin Pathol.* 1999;111:594-598.
8. Dickman, PS. Ewing's sarcoma/primitive neuroectodermal tumor: case review. *Pathol Case Rev.* 2000;5:60-70.
9. Grier HE, Krailo MD, Tarbell NJ, et al. Addition of ifosfamide and etoposide to standard chemotherapy for Ewing's sarcoma and primitive neuroectodermal tumor of bone. *N Engl J Med.* 2003;348:694-701.
10. Ambros IM, Ambros PF, Strehl S, Kovar H, Gadner H, Salzer-Kuntschik M. MIC2 is a specific marker for Ewing's sarcoma and peripheral primitive neuroectodermal tumor: evidence for a common histogenesis of Ewing's sarcoma and peripheral neuroectodermal tumors from MIC2 expression and specific chromosome aberration. *Cancer.* 1992;67:1886-1893.
11. Collini P, Sampietro G, Bertulli R, et al. Cytokeratin immunoreactivity in 41 cases of Ewing sarcoma/primitive neuroectodermal tumor confirmed by molecular diagnostic studies. *Am J Surg Pathol.* 2001;25:273-274.
12. Folpe AL, Goldblum JR, Rubin BP, Shehata BM, Liu W, Dei Tos AP, Weiss SW. Morphologic and immunophenotypic diversity in Ewing family tumors: a study of 66 genetically confirmed cases. *Am J Surg Pathol.* 2005;29:1025-1033.
13. Tsokos M, Allagio RD, Dehner LP, et al. Ewing sarcoma/peripheral neuroectodermal tumor and related tumors. *Pediatr Dev Pathol.* 2012;15(1 suppl):108-126.
14. Antonescu C. Round cell sarcomas beyond Ewing: emerging entities. *Histopathology* 2014;64:26-37.
15. Van Doorninck JA, Ji L, Schaub B, et al. Current treatment protocols have eliminated the prognostic advantage of Type 1 fusions in Ewing sarcoma: a report from the Children's Oncology Group. *J Clin Oncol.* 2010;28:1989-1994.
16. Extraskelatal Ewing's sarcoma/primitive neuroectodermal tumor family. In: Weiss SW, Goldblum JR, eds. *Enzinger and Weiss's Soft Tissue Tumors.* 5th ed. St. Louis, MO: Mosby; 2008:963-979.
17. Edge SB, Byrd DR, Carducci MA, Compton CC, eds. *AJCC Cancer Staging Manual.* 7th ed. New York, NY: Springer; 2009.
18. Sobin LH, Gospodarowicz M, Wittekind Ch, eds. *UICC TNM Classification of Malignant Tumours.* 7th ed. New York, NY: Wiley-Liss; 2009.