

Protocol for the Examination of Specimens From Patients With Carcinoma and Carcinosarcoma of the Endometrium

Version: Endometrium 4.1.0.1

Protocol Posting Date: August 2019

CAP Laboratory Accreditation Program Protocol Required Use Date: May 2020

Includes pTNM requirements from the 8th Edition, AJCC Staging Manual and 2018 FIGO Cancer Report

For accreditation purposes, this protocol should be used for the following procedures AND tumor types:

Procedure	Description
Hysterectomy	
Tumor Type	Description
Carcinoma	Includes carcinomas, carcinosarcomas (malignant mixed Müllerian tumor) and neuroendocrine carcinomas arising in the endometrium

This protocol is NOT required for accreditation purposes for the following:

Procedure
Endometrial biopsy
Endometrial curettage
Primary resection specimen with no residual cancer (eg, following previous biopsy or curettage)
Cytologic specimens

The following tumor types should NOT be reported using this protocol

Tumor Type
Carcinomas arising in the uterine cervix (consider the Uterine Cervix protocol)
Uterine sarcoma, including adenosarcoma (consider the Uterine Sarcoma protocol)
Lymphoma (consider the Hodgkin or non-Hodgkin Lymphoma protocols)

Authors

Uma Krishnamurti, MD, PhD*; Saeid Movahedi-Lankarani, MD*; George G. Birdsong, MD; Christopher N. Chapman Jr, MD; Bojana Djordjevic, MD; Veronica Klepeis, MD, PhD; Teri A. Longacre, MD; Marisa R. Nucci, MD; Christopher N. Otis, MD

With guidance from the CAP Cancer and CAP Pathology Electronic Reporting Committees.

* Denotes primary author. All other contributing authors are listed alphabetically.

Accreditation Requirements

This protocol can be utilized for a variety of procedures and tumor types for clinical care purposes. For accreditation purposes, only the definitive primary cancer resection specimen is required to have the core and conditional data elements reported in a synoptic format.

- Core data elements are required in reports to adequately describe appropriate malignancies. For accreditation purposes, essential data elements must be reported in all instances, even if the response is “not applicable” or “cannot be determined.”
- Conditional data elements are only required to be reported if applicable as delineated in the protocol. For instance, the total number of lymph nodes examined must be reported, but only if nodes are present in the specimen.
- Optional data elements are identified with “+” and although not required for CAP accreditation purposes, may be considered for reporting as determined by local practice standards.

The use of this protocol is not required for recurrent tumors or for metastatic tumors that are resected at a different time than the primary tumor. Use of this protocol is also not required for pathology reviews performed at a second institution (ie, secondary consultation, second opinion, or review of outside case at second institution).

Synoptic Reporting

All core and conditionally required data elements outlined on the surgical case summary from this cancer protocol must be displayed in synoptic report format. Synoptic format is defined as:

- Data element: followed by its answer (response), outline format without the paired "Data element: Response" format is NOT considered synoptic.
- The data element should be represented in the report as it is listed in the case summary. The response for any data element may be modified from those listed in the case summary, including “Cannot be determined” if appropriate.
- Each diagnostic parameter pair (Data element: Response) is listed on a separate line or in a tabular format to achieve visual separation. The following exceptions are allowed to be listed on one line:
 - Anatomic site or specimen, laterality, and procedure
 - Pathologic Stage Classification (pTNM) elements
 - Negative margins, as long as all negative margins are specifically enumerated where applicable
- The synoptic portion of the report can appear in the diagnosis section of the pathology report, at the end of the report or in a separate section, but all Data element: Responses must be listed together in one location

Organizations and pathologists may choose to list the required elements in any order, use additional methods in order to enhance or achieve visual separation, or add optional items within the synoptic report. The report may have required elements in a summary format elsewhere in the report IN ADDITION TO but not as replacement for the synoptic report ie, all required elements must be in the synoptic portion of the report in the format defined above.

CAP Endometrium Protocol Summary of Changes

Version 4.1.0.1

The following data elements were modified:

Myometrial Invasion

Lower Uterine Segment Involvement

Background Documentation Note J. Pathologic Stage Classification

Surgical Pathology Cancer Case Summary

Protocol posting date: August 2019

ENDOMETRIUM:

Select a single response unless otherwise indicated.

Procedure (select all that apply) (Note A)

- Total hysterectomy and bilateral salpingo-oophorectomy
- Radical hysterectomy
- Simple hysterectomy
- Supracervical hysterectomy
- Bilateral salpingo-oophorectomy
- Right salpingo-oophorectomy
- Left salpingo-oophorectomy
- Salpingo-oophorectomy, side not specified
- Right oophorectomy
- Left oophorectomy
- Oophorectomy, side not specified
- Bilateral salpingectomy
- Right salpingectomy
- Left salpingectomy
- Salpingectomy, side not specified
- Vaginal cuff resection
- Omentectomy
- Peritoneal biopsies
- Peritoneal washing
- Other (specify): _____

Note: For information about lymph node sampling, please refer to the Regional Lymph Node section.

+ Hysterectomy Type

- + Abdominal
- + Vaginal
- + Vaginal, laparoscopic-assisted
- + Laparoscopic
- + Laparoscopic, robotic-assisted
- + Other (specify): _____
- + Not specified

+Specimen Integrity (Note A)

- + Intact
- + Opened
- + Morcellated
- + Other (specify): _____

+ Tumor Site (select all that apply)

- + Endometrium
- + Lower uterine segment
- + Endometrial polyp
- + Other (specify): _____
- + Cannot be determined

+ Data elements preceded by this symbol are not required for accreditation purposes. These optional elements may be clinically important but are not yet validated or regularly used in patient management.

+ Tumor Size

- + Greatest dimension: ___ cm
- + Additional dimensions: ___ x ___ cm
- + ___ Cannot be determined (explain): _____

Histologic Type (Note B)

- ___ Endometrioid carcinoma, NOS
- ___ Endometrioid carcinoma with squamous differentiation
- ___ Endometrioid carcinoma, villoglandular variant
- ___ Endometrioid carcinoma with secretory differentiation
- ___ Endometrioid carcinoma, other variant (specify): _____
- ___ Serous endometrial intraepithelial carcinoma
- ___ Serous carcinoma
- ___ Carcinosarcoma (malignant mixed Müllerian tumor)
- ___ Mucinous carcinoma
- ___ Clear cell carcinoma
- ___ Small cell neuroendocrine carcinoma
- ___ Large cell neuroendocrine carcinoma
- ___ Mixed cell carcinoma (specify types and percentages): _____
- ___ Undifferentiated carcinoma
- ___ Dedifferentiated carcinoma
- ___ Other histologic type not listed (specify): _____

Histologic Grade (required only if applicable) (Note C)#

- ___ FIGO grade 1
- ___ FIGO grade 2
- ___ FIGO grade 3
- ___ Other (specify): _____
- ___ Cannot be assessed (explain): _____

International Federation of Gynecology and Obstetrics (FIGO) Grading System applies to endometrioid and mucinous carcinomas only. Serous, clear cell, transitional, small cell and large cell neuroendocrine carcinomas, undifferentiated/dedifferentiated carcinomas, and carcinosarcomas are generally considered to be high grade and it is not recommended to assign a histologic grade to these tumor types.

Myometrial Invasion (Note D)

- ___ Not identified
- ___ Present
 - Depth of Myometrial Invasion (millimeters): ___ mm
 - Myometrial Thickness (millimeters): ___ mm
 - Percentage of Myometrial Invasion: ___%
- OR, if exact percentage of invasion cannot be determined, state:
 - ___ Depth of myometrial invasion cannot be determined (explain): _____
 - ___ Myometrial thickness cannot be determined (explain): _____
- Estimated Percentage of Myometrial Invasion
 - ___ Less than 50%
 - ___ 50% or greater
- ___ Cannot be determined (explain): _____

+ Adenomyosis

- + ___ Not identified
- + ___ Present, uninvolved by carcinoma
- + ___ Present, involved by carcinoma
- + ___ Cannot be determined

+ Data elements preceded by this symbol are not required for accreditation purposes. These optional elements may be clinically important but are not yet validated or regularly used in patient management.

Uterine Serosa Involvement

- Not identified
- Present
- Cannot be determined (explain): _____

+ Lower Uterine Segment Involvement (Note E)

- + Not identified
- + Present, superficial (non-myoinvasive)
- + Present, myoinvasive
- + Present _____
- + Cannot be determined (explain): _____

Cervical Stromal Involvement (Note F)

- Not identified
- Present
- Cannot be determined (explain): _____

Other Tissue/Organ Involvement (select all that apply)

Note: Any organ not selected is either not involved or was not submitted.

- Not applicable
- Not identified
- Right ovary
- Left ovary
- Ovary (side not specified)
- Right fallopian tube
- Left fallopian tube
- Fallopian tube (side not specified)
- Vagina
- Right parametrium
- Left parametrium
- Parametrium (side not specified)
- Pelvic wall
- Bladder wall
- Bladder mucosa
- Rectal wall
- Bowel mucosa
- Omentum Other organs/tissue (specify): _____
- Cannot be determined (explain): _____

+ Peritoneal/ Ascitic Fluid (Note G)

- + Not submitted/unknown
- + Negative for malignancy (normal/benign)
- + Atypical and/or suspicious (explain): _____
- + Malignant (positive for malignancy)
- + Unsatisfactory/nondiagnostic (explain): _____
- + Results pending

Margins (required only if cervix and/or parametrium/paracervix is involved by carcinoma) (Note H)

Ectocervical/Vaginal Cuff Margin

- Cannot be assessed (explain): _____
- Involved by carcinoma
- Uninvolved by carcinoma
 - + Distance of invasive carcinoma from margin (millimeters): ____ mm

Parametrial/Paracervical Margin

+ Data elements preceded by this symbol are not required for accreditation purposes. These optional elements may be clinically important but are not yet validated or regularly used in patient management.

- Cannot be assessed (explain): _____
- Involved by carcinoma
- Uninvolved by carcinoma
 - + Distance of invasive carcinoma from margin (millimeters): ____ mm

Lymphovascular Invasion (Note I)

- Not identified
- Present
- Cannot be determined

Regional Lymph Nodes

Note: Lymph nodes designated as pelvic (parametrial, obturator, internal iliac (hypogastric), external iliac, common iliac, sacral, presacral) and para-aortic are considered regional lymph nodes. Any other involved nodes should be categorized as metastases (pM1) and commented on in the distant metastasis section. Presence of isolated tumor cells no greater than 0.2 mm in regional lymph node(s) is considered NO (i+).

- No lymph nodes submitted or found

Lymph Node Examination (required only if lymph nodes are present in the specimen)

- All lymph nodes negative for tumor cells
- Positive for tumor cells (select all that apply)
 - Number of Pelvic Nodes with Macrometastases:** ____
 - Number of Pelvic Nodes with Micrometastases:** ____
 - Number of Pelvic Nodes with Isolated Tumor Cells (if applicable):** ____

and/or

- Number of Para-aortic Nodes with Macrometastases:** ____
- Number of Para-aortic Nodes with Micrometastases:** ____
- Number of Para-aortic Nodes with Isolated Tumor Cells (if applicable):** ____

Number cannot be determined (explain): _____

Note: Macrometastases (>2 mm), Micrometastases (>0.2 mm to 2 mm and/or >200 cells), Isolated Tumor Cells (≤0.2 mm and ≤200 cells). Reporting the number of nodes with or without macrometastases and micrometastases is required if pelvic and/or para-aortic lymph nodes are submitted and either are positive for tumor cell. Reporting isolated tumor cells is required only in the absence of macrometastasis or micrometastasis

Laterality of Nodes with Tumor Cells (select all that apply)

- Right pelvic
- Left pelvic
- Right para-aortic
- Left para-aortic
- Cannot be determined (explain): _____

Number of Lymph Nodes Examined (select all that apply)

- Total Number of Pelvic Nodes Examined:** ____
- Number of Pelvic Sentinel Nodes Examined:** ____
- Total Number of Para-aortic Nodes Examined:** ____
- Number of Para-aortic Sentinel Nodes Examined:** ____

Pathologic Stage Classification (pTNM, AJCC 8th Edition) (Note J)

Note: Reporting of pT, pN, and (when applicable) pM categories is based on information available to the pathologist at the time the report is issued. Only the applicable T, N, or M category is required for reporting; their definitions need not be included in the report. The categories (with modifiers when applicable) can be listed on 1 line or more than 1 line.

+ Data elements preceded by this symbol are not required for accreditation purposes. These optional elements may be clinically important but are not yet validated or regularly used in patient management.

TNM Descriptors (required only if applicable) (select all that apply)

- ___ r (recurrent)
 ___ y (posttreatment)

Primary Tumor (pT)

- ___ pTX: Primary tumor cannot be assessed
 ___ pT0: No evidence of primary tumor
 ___ pT1: Tumor confined to the corpus uteri, including endocervical glandular involvement
 ___ pT1a: Tumor limited to endometrium or invading less than half of the myometrium
 ___ pT1b: Tumor invading one-half or more of the myometrium
 ___ pT2: Tumor invading the stromal connective tissue of the cervix but not extending beyond the uterus. This does NOT include endocervical glandular involvement
 ___ pT3: Tumor involving serosa, adnexa, vagina, or parametrium
 ___ pT3a: Tumor involves serosa and/or adnexa (direct extension or metastasis)
 ___ pT3b: Vaginal involvement (direct extension or metastasis) or parametrial involvement
 ___ pT4: Tumor invading the bladder mucosa and/or bowel mucosa (bullous edema is not sufficient to classify a tumor as T4)

Regional Lymph Nodes Modifier (required only if applicable)

- ___ (sn)[#]

Note: Suffix (sn) is required if applicable and added to the N category when only sentinel lymph node biopsy is performed. If after a sentinel node biopsy, the patient then undergoes a complete lymph node dissection, the (sn) suffix is not used.

Regional Lymph Nodes (pN)

- ___ pNX: Regional lymph nodes cannot be assessed
 ___ pN0: No regional lymph node metastasis
 ___ pN0(i+): Isolated tumor cells in regional lymph node(s) no greater than 0.2 mm
 ___ pN1: Regional lymph node metastasis to pelvic lymph nodes
 ___ pN1mi: Regional lymph node metastasis (greater than 0.2 mm but not greater than 2 mm in diameter) to pelvic lymph nodes[#]
 ___ pN1a: Regional lymph node metastasis (greater than 2 mm in diameter) to pelvic lymph nodes
 ___ pN2: Regional lymph node metastasis to para-aortic lymph nodes, with or without positive pelvic lymph nodes
 ___ pN2mi: Regional lymph node metastasis (greater than 0.2 mm but not greater than 2 mm in diameter) to para-aortic lymph nodes, with or without positive pelvic lymph nodes[#]
 ___ pN2a: Regional lymph node metastasis (greater than 2 mm in diameter) to para-aortic lymph nodes, with or without positive pelvic lymph nodes

Note: Even one metastasis >2.0 mm would qualify the classification as pN1a and pN2a.

Distant Metastasis (pM) (required only if confirmed pathologically in this case)

- ___ pM1: Distant metastasis (includes metastasis to inguinal lymph nodes, intraperitoneal disease, lung, liver, or bone. It excludes metastasis to pelvic or para-aortic lymph nodes, vagina, uterine serosa, or adnexa)
 Specify Site(s), if known: _____

+ FIGO Stage (2018 FIGO Cancer Report)

- + ___ I: Tumor confined to the corpus uteri
 + ___ IA: No or less than half myometrial invasion
 + ___ IB: Invasion equal to or more than half of the myometrium
 + ___ II: Tumor invades cervical stroma, but does not extend beyond the uterus
 + ___ III: Local and/or regional spread of the tumor
 + ___ IIIA: Tumor invades the serosa of the corpus uteri and/or adnexae
 + ___ IIIB: Vaginal involvement and/ or parametrial involvement
 + ___ IIIC: Metastases to pelvic and/or para-aortic lymph nodes

+ Data elements preceded by this symbol are not required for accreditation purposes. These optional elements may be clinically important but are not yet validated or regularly used in patient management.

- + ___ IIIC1: Positive pelvic nodes
- + ___ IIIC2: Positive para-aortic nodes with or without positive pelvic lymph nodes
- + ___ IV: Tumor invades bladder and/or bowel mucosa, and/or distant metastases
- + ___ IVA: Tumor invasion of bladder and/or bowel mucosa
- + ___ IVB: Distant metastasis, including intraabdominal metastases and/or inguinal nodes

+ Additional Pathologic Findings (select all that apply) (Note K)

- + ___ None identified
- + ___ Atypical hyperplasia/endometrial intraepithelial neoplasia (EIN)
- + ___ Other (specify): _____

+ Ancillary Studies

Note: For reporting molecular testing, immunohistochemistry, and other cancer biomarker testing results, the CAP endometrium biomarker template should be used. Pending biomarker studies should be listed in the Comments section of this report.

+ Clinical History (select all that apply) (Note L)

- + ___ Lynch syndrome
- + ___ Other (specify): _____

+ Comment(s)

Explanatory Notes

A. Specimen Type

In rare occasions when an endometrial carcinoma is not suspected, the pathologist may receive a supracervical hysterectomy specimen removed by laparoscopy. It has been reported that hysterectomies performed using certain laparoscopic techniques result in the finding of venous tumor emboli that are likely to be iatrogenic.¹ The FDA discourages morcellation for removal of uterus in women with suspected or known uterine cancer because there is risk of spreading tumor cells to the pelvis and peritoneal cavity. Therefore, if applicable reporting of such a procedure is recommended (and listed under Specimen Integrity in the case summary).

References

1. Logani S, Herdman AV, Little JV, Moller KA. Vascular "pseudo invasion" in laparoscopic hysterectomy specimens: a diagnostic pitfall. *Am J Surg Pathol.* 2008;32:560-565.

B. Histologic Type

For consistency in reporting, the histologic classification of endometrial carcinoma and hyperplasia proposed by the World Health Organization (WHO), shown below, is recommended.¹

Endometrioid carcinoma
 Endometrioid carcinoma with squamous differentiation
 Endometrioid carcinoma, villoglandular variant
 Endometrioid carcinoma, with secretory differentiation
 Mucinous carcinoma
 Serous endometrial intraepithelial carcinoma
 Serous carcinoma
 Clear cell carcinoma
 Small cell neuroendocrine carcinoma
 Large cell neuroendocrine carcinoma
 Mixed cell carcinoma
 Undifferentiated carcinoma
 Dedifferentiated carcinoma
 Carcinosarcoma (malignant Müllerian mixed tumor)

Mucinous carcinomas defined as an endometrial carcinoma in which > 50% of the neoplasm is mucinous are very rare. Most tumors that are mucinous are endometrioid adenocarcinoma with mucinous differentiation. The term *mixed carcinoma* should only be used when two or more distinctive subtypes of endometrial carcinoma are identified, each representing at least 5% of the tumor. Optimally, the diagnosis is made on examination of a hysterectomy specimen, but if only a smaller specimen is available, any amount of a second tumor category suffices for the diagnosis. When a carcinoma is classified as "mixed," the major and minor types and their relative proportions should be specified. High-grade tumors with ambiguous features should be classified as "carcinoma, subtype cannot be determined"; however, this is a very infrequent situation and every effort should be made to subclassify such tumors. It should be noted that for mixed endometrioid and serous carcinomas, studies have found variable results regarding tumor behavior based on percentage of the serous component. Some studies have found that tumors with >25% serous component behave like pure serous carcinomas, whereas other studies have shown that tumors with <10% serous component also behave like pure serous carcinomas.^{2,3} It is important to be aware that some serous carcinomas may display a glandular architecture.⁴ Thus, when a gland-forming endometrial carcinoma shows high-grade nuclear features, the diagnosis of serous carcinoma should be considered. Finally, the term *endometrial intraepithelial carcinoma* is discouraged because it is not uncommon for these lesions to be associated with extrauterine spread.⁵⁻⁷ Instead, the term *serous endometrial intraepithelial carcinoma* should be used.

In addition, carcinosarcoma (also referred to as malignant Müllerian mixed tumor [MMMT]) has been added to the above list of tumors in the case summary. Carcinosarcoma is a high-grade endometrial neoplasm that is staged like endometrial carcinomas because it is thought to represent a high-grade metaplastic carcinoma. The diagnosis

of carcinosarcoma requires presence of both a high grade malignant epithelial component and a high grade malignant mesenchymal (sarcomatous) component in the neoplasm, which should not merge.

Proposed Criteria Distinguishing Well-Differentiated Endometrioid Endometrial Adenocarcinoma From EIN or Atypical Endometrial Hyperplasia

- (1) Irregular infiltration of myometrium associated with an altered fibroblastic stroma (desmoplastic response), **or**
- (2) Confluent glandular pattern (cribriform growth, or complex folded maze-like epithelium), **or**
- (3) Solid nonsquamous epithelial growth

Some investigators have offered specific measurements to assess confluent glandular growth more objectively. Kurman and Norris proposed 1.9 mm as a cutoff,⁸ whereas Longacre and colleagues proposed 30% of total architecturally atypical proliferation as a cutoff.⁹ However, it is important to note that different investigators did not find these parameters to have the same predictive value.

References

1. Kurman RJ, Carcangiu ML, Harrington CS, Young RH, eds. *WHO Classification of Tumors of the Female Reproductive Organs*. Geneva, Switzerland: WHO Press; 2014. *World Health Organization Classification of Tumors*. 4th ed.
2. Williams KE, Waters ED, Woolas RP, Hammond IG, McCartney AJ. Mixed serous-endometrioid carcinoma of the uterus: pathologic and cytopathologic analysis of a high-risk endometrial carcinoma. *Int J Gynecol Cancer*. 1994;4:7-18.
3. Lim P, Al Kushi A, Gilks B, Wong F, Aquino-Parsons C. Early stage papillary serous carcinoma of the endometrium: effect of adjuvant whole abdominal radiotherapy and pathologic parameters on outcome. *Cancer*. 2001;91:752-757.
4. Darvishian F, Hummer A, Thaler H, et al. Serous endometrial cancers that mimic endometrioid adenocarcinomas: a clinicopathologic and immunohistochemical study of a group of problematic cases. *Am J Surg Pathol*. 2004;28:1568-1578.
5. Soslow RA, Pirog E, Isacson C. Endometrial intraepithelial carcinoma with peritoneal dissemination. *Am J Surg Pathol*. 2000;24:726-732.
6. Ambros RA, Sherman ME, Zahn CM, Bitterman P, Kurman RJ. Endometrial intraepithelial carcinoma: a distinctive lesion specifically associated with tumors displaying serous differentiation. *Hum Pathol*. 1995;26:1260-1267.
7. Hui P, Kelly M, O'Malley DM, Tavassoli F, Schwartz PE. Minimal uterine serous carcinoma: a clinicopathological study of 40 cases. *Mod Pathol*. 2005;18:75-82.
8. Kurman RJ, Norris HJ. Evaluation of criteria for distinguishing atypical endometrial hyperplasia from well-differentiated carcinoma. *Cancer*. 1982;2547-2559.
9. Longacre TA, Chumg MH, Jensen DN, Hendrickson MR. Proposed criteria for the diagnosis of well-differentiated endometrial carcinoma: a diagnostic test for myoinvasion. *Am J Surg Pathol*. 1995;19:371-406.

C. Histologic Grading

The International Federation of Gynecology and Obstetrics (FIGO) grading system for carcinomas of the uterine corpus is only officially designated for endometrioid carcinomas and is based on architectural features as follows:¹

Grade 1	5% or less nonsquamous solid growth pattern
Grade 2	6% to 50% nonsquamous solid growth pattern
Grade 3	>50% nonsquamous solid growth pattern

Notable nuclear atypia, which exceeds that which is routinely expected for the architectural grade, increases the tumor grade by 1.

In addition, the following guidelines should be used in grading:

- (1) The squamous component of endometrioid adenocarcinoma should not be graded because the degree of differentiation typically parallels that of the glandular component.²
- (2) Because mucinous carcinomas are closely related to endometrioid carcinomas, they can be graded by the same criteria.

- (3) Serous, clear cell, transitional, small cell and large cell neuroendocrine carcinomas, undifferentiated/dedifferentiated carcinomas, and carcinosarcomas are generally considered to be high grade and it is not recommended to assign a FIGO grade to these tumor types.^{1,3} When the case summary is being completed, these should be designated as “not applicable” for histologic grade.
- (4) In mixed carcinomas, the highest grade should be assigned.

References

1. Creasman W, Odicino F, Maisonneuve P, et al. Carcinoma of the corpus uteri: FIGO Annual Report. *J Epidemiol Biostat.* 2001;6:45-86.
2. Zaino RJ, Kurman RJ. Squamous differentiation in carcinoma of the endometrium: a critical appraisal of adenoacanthoma and adenosquamous carcinoma. *Sem Diagn Pathol.* 1988;5:154-171.
3. Kurman RJ, Carcangiu ML, Harrington CS, Young RH, eds. *WHO Classification of Tumors of the Female Reproductive Organs.* Geneva, Switzerland: WHO Press; 2014. *World Health Organization Classification of Tumors.* 4th ed.

D. Myometrial Invasion

Assessing myometrial invasion may be difficult. Depth of invasion should be measured from the endomyometrial junction to the deepest point of invasion, which may not be easy because the endomyometrial junction in normal conditions is often irregular. In these cases, it is always helpful to look for compressed, non-neoplastic endometrial glands at the nearby endomyometrial junction or even at the base of the tumor. Carcinoma involving adenomyotic foci should not be interpreted as invasive carcinoma. However, the distinction between invasive carcinoma and carcinoma involving adenomyosis may be difficult, because in some cases invasive carcinoma may not elicit stromal response. In the absence of adenomyosis uninvolved by tumor in other sections of the specimen, a diagnosis of adenomyosis involved by adenocarcinoma should be made with caution. CD10 staining is not helpful in this differential diagnosis because stromal cells surrounding foci of invasive carcinoma are also frequently CD10 positive. There are no rules for determining how to measure the depth of invasion in the rare cases where myoinvasive carcinoma is only encountered in foci of adenomyosis involved by carcinoma. In such cases, it is advised that the distance from the adenomyotic focus to the deepest area of invasion be measured (Figure 1).¹ Therefore, if there is a tumor with a 2-mm focus of myoinvasion from a focus of adenomyosis in the deep myometrium, it is still considered as having <50% myometrial invasion (FIGO stage IA).

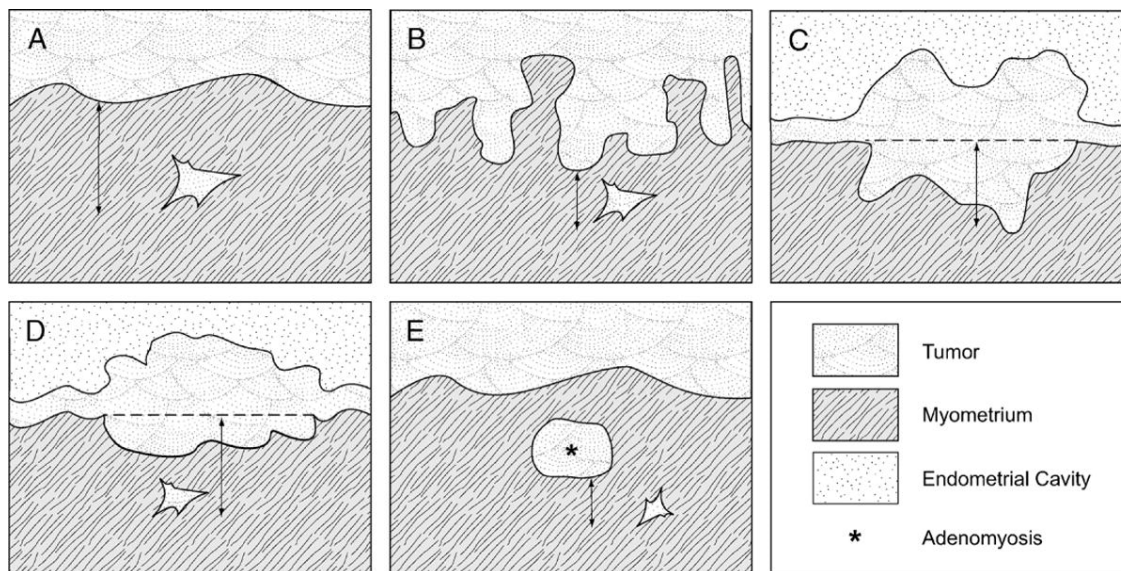


Figure 1. Schematic of measurement of depth of invasion in (A) tumor with a regular interface; (B) tumor with an irregular endomyometrial interface; (C) and (D) tumor with an exophytic growth; (E) tumor arising from adenomyosis. From Ali A, Black D, Soslow RA. Difficulties in assessing the depth of myometrial invasion in endometrial carcinoma. *Int J Gynecol Pathol.* 2007;26:115-123. Copyright © 2007, Wolters Kluwer Health. Reproduced with permission.

References

1. Ali A, Black D, Soslow RA. Difficulties in assessing the depth of myometrial invasion in endometrial carcinoma. *Int J Gynecol Pathol.* 2007;26:115-123.

E. Lower Uterine Segment Involvement

The prevalence of Lynch syndrome in patients with LUS endometrial carcinoma (29%) has been reported to be much greater than that of the general endometrial cancer patient population (1.8%) or in endometrial cancer patients younger than age 50 years (8% to 9%).¹

References

1. Westin SN, Lacour RA, Urbauer DL, et al. Carcinoma of the lower uterine segment: a newly described association with Lynch syndrome. *J Clin Oncol.* 2008;26:5965-5971

F. Cervical Involvement

The American Joint Committee on Cancer (AJCC)/FIGO staging system considers stage II disease only when cervical stromal involvement is seen. Involvement of the surface endocervical epithelium and/or endocervical glands (either by direct extension or drop metastases) does not have any prognostic significance and is not T2/Stage II.

G. Peritoneal Washings or Ascites Fluid

The prognostic significance of presence of tumor cells in peritoneal washings or ascites fluid is controversial. There are studies that indicate either a worse prognosis or no alteration of prognosis on the basis of positive cytology. Consequently, staging systems no longer utilize positive cytology to alter stage. When collected, however, cytology results should be recorded.

H. Margins

The parametrial/paracervical soft tissue and the vaginal cuff are the only true margins in total hysterectomy specimens. These margins should be reported if the cervix and/or parametrium/paracervix is involved by carcinoma. If not, reporting the status of the vaginal and parametrial margins in a hysterectomy specimen is optional.

I. Lymphovascular Invasion

Lymphovascular invasion (LVI) indicates whether microscopic lymphovascular invasion is identified. LVI includes lymphatic invasion, vascular invasion, or lymphovascular invasion. According to AJCC/International Union Against Cancer (UICC) convention, LVI does not affect the T category indicating local extent of tumor unless specifically included in the definition of a T category.

J. Pathologic Stage Classification

The TNM staging system for endometrial cancer endorsed by the AJCC and the UICC,^{1,2} and the parallel system formulated by FIGO³ are recommended.

According to AJCC/UICC convention, the designation “T” refers to a primary tumor that has not been previously treated. The symbol “p” refers to the pathologic classification of the TNM, as opposed to the clinical classification, and is based on gross and microscopic examination. pT entails a resection of the primary tumor or biopsy adequate to evaluate the highest pT category, pN entails removal of nodes adequate to validate lymph node metastasis, and pM implies microscopic examination of distant lesions. Clinical classification (cTNM) is usually carried out by the referring physician before treatment during initial evaluation of the patient or when pathologic classification is not possible.

Pathologic staging is usually performed after surgical resection of the primary tumor. Pathologic staging depends on pathologic documentation of the anatomic extent of disease, whether or not the primary tumor has been completely removed. If a biopsied tumor is not resected for any reason (eg, when technically infeasible) and if the highest T and N categories or the M1 category of the tumor can be confirmed microscopically, the criteria for pathologic classification and staging have been satisfied without total removal of the primary cancer.

TNM Descriptors

For identification of special cases of TNM or pTNM classifications, the “m” suffix and “y,” “r,” and “a” prefixes are used. Although they do not affect the stage grouping, they indicate cases needing separate analysis.

The “y” prefix indicates those cases in which classification is performed during or after initial multimodality therapy (ie, neoadjuvant chemotherapy, radiation therapy, or both chemotherapy and radiation therapy). The cTNM or pTNM category is identified by a “y” prefix. The ycTNM or ypTNM categorizes the extent of tumor actually present at the time of that examination. The “y” categorization is not an estimate of tumor before multimodality therapy (ie, before initiation of neoadjuvant therapy).

The “r” prefix indicates a recurrent tumor when staged after a documented disease-free interval and is identified by the “r” prefix: rTNM.

The “a” prefix designates the stage determined at autopsy: aTNM.

T Category Considerations

It is important to note that in endometrial cancer, as in cancer of other organs, the validity of T stage depends upon the adequacy and completeness of the surgical staging.

N Category Considerations

Isolated tumor cells (ITCs) are single cells or small clusters of cells not more than 0.2 mm in greatest dimension. Lymph nodes or distant sites with ITCs found by either histologic examination (eg, immunohistochemical evaluation for cytokeratin) or nonmorphological techniques (eg, flow cytometry, DNA analysis, polymerase chain reaction [PCR] amplification of a specific tumor marker) should be so identified. There is currently no guidance in the literature as to how these patients should be coded; until more data are available, they should be coded as “NO(i+)” with a comment noting how the cells were identified.

Sentinel nodes should be sliced at 2.0 mm intervals. The sentinel nodes should undergo ultrastaging. Currently, there is no universal ultrastaging protocol. However, all institutions undertaking sentinel lymph node examination should have a standard procedure in place for sentinel lymph nodes. Protocols used at the 2 largest cancer centers in the United States are as follows:

- 1) Memorial Sloan Kettering Cancer Center Protocol:⁴ If the initial H&E-stained slide is negative for carcinoma and the endometrial cancer is myo-invasive or associated with vascular/lymphatic invasion, 2 additional levels at 50 µm apart are examined, at each level 2 slides are obtained, one for H&E and the second for keratin cocktail IHC if the H&E-stained slide is negative.
- 2) The University of Texas M.D. Anderson Cancer Center Protocol:⁵ If the H&E-stained slide is negative for tumor, 3 consecutive sections at 250 µm into the paraffin block are obtained (one for H&E and one of the remaining 2 is to be used for keratin cocktail IHC if the additional H&E-stained slide is negative.

There is little data to assign risk for nonsentinel lymph node metastasis based on the size of the metastasis in the sentinel lymph node. However, the size criteria for micrometastasis and macrometastasis is adopted from the experience in breast carcinoma. Micrometastasis is defined as a metastasis measuring greater than 0.2 mm but less than 2 mm.

Primary Tumor (T)

T Category	FIGO Stage	Definition
T1	I	Tumor confined to corpus uteri
T1a	IA	Tumor limited to endometrium or invades less than one-half of the myometrium
T1b	IB	Tumor invades one-half or more of the myometrium
T2	II	Tumor invades stromal connective tissue of the cervix
T3	III	Tumor involving serosa, adnexa, vagina, or parametrium, ie, local and/or regional spread as specified in T3a and T3b, and in FIGO IIIA and IIIB

T3a	IIIA	Tumor involving the serosa and/or adnexa (direct extension or metastasis)
T3b	IIIB	Vaginal involvement (direct extension or metastasis) or parametrial involvement
T4 [#]	IVA	Tumor invading bladder mucosa [#] and/or bowel mucosa [#]

[#] Presence of bullous edema is not sufficient evidence to classify a tumor as T4.

Regional Lymph Nodes (N):[#] TNM Staging System

N Category	FIGO Stage	Definition
NX		Regional lymph nodes cannot be assessed
N0		No regional lymph node metastasis
N0(i+)		Isolated tumor cells in regional lymph node(s) no greater than 0.2 mm
N1	IIIC1	Regional lymph node metastasis to pelvic lymph nodes
N1mi [#]	IIIC1	Regional lymph node metastasis (greater than 0.2 mm but not greater than 2 mm in diameter) to pelvic lymph nodes
N1a	IIIC1	Regional lymph node metastasis (greater than 2 mm in diameter) to pelvic lymph nodes
N2	IIIC2	Regional lymph node metastasis to para-aortic lymph nodes with or without positive pelvic lymph nodes
N2mi [#]	IIIC2	Regional lymph node metastasis (greater than 0.2 mm but not greater than 2 mm in diameter) to para-aortic lymph nodes, with or without positive pelvic lymph nodes
N2a	IIIC2	Regional lymph node metastasis (greater than 2 mm in diameter) to para-aortic lymph nodes, with or without positive pelvic lymph nodes

[#] Regional lymph nodes include the pelvic, obturator, internal iliac (hypogastric), external iliac, common iliac, para-aortic, presacral, and parametrial lymph nodes. Even one metastasis >2.0 mm would qualify the classification as pN1a and pN2a.

Distant Metastasis (M): TNM Staging System

M Category	FIGO Stage	Definition
M0		No distant metastasis
M1	IVB	Distant metastasis (includes metastasis to abdominal lymph nodes [other than para-aortic], and/or inguinal lymph nodes, intraperitoneal disease, lung, liver, or bone; excludes metastasis to vagina, pelvic serosa, or adnexa)

References

1. Amin MB, Edge SB, Greene FL, et al, eds. *AJCC Cancer Staging Manual*. 8th ed. New York, NY: Springer; 2017.
2. Brierley JD, Gospodarowicz MK, Wittekind C, et al, eds. *TNM Classification of Malignant Tumours*. 8th ed. Oxford, UK: Wiley; 2016.
3. FIGO Cancer Report. Cancer of the corpus uteri. *Int J Gynecol Obstet*. 2018; 143 (Suppl 2);37-50 .
4. Abu-Rustum NR. Sentinel lymph node mapping for endometrial cancer: a modern approach to surgical staging. *J Natl Compr Canc Netw* 2014;12:288–97.
5. Euscher E, Sui D, Soliman P, et al. Ultrastaging of sentinel lymph nodes in endometrial carcinoma according to use of 2 different methods. *Int J Gynecol Pathol* 2018;37:242–251. 97.

K. Additional Findings

Atypical Hyperplasia/Endometrioid Intraepithelial Neoplasia

This is composed of crowded aggregates of cytologically altered tubular or branching glands. The volume of crowded glands exceeds that of the stroma. In addition, there is nuclear atypia in the form of nuclear enlargement, pleomorphism, rounding, loss of polarity, and nucleoli.¹ The diagnosis of atypia is aided by the comparison with adjacent normal glands when present.

References

1. Kurman RJ, Carcangiu ML, Harrington CS, Young RH, eds. *WHO Classification of Tumors of the Female Reproductive Organs*. Geneva, Switzerland: WHO Press; 2014. *World Health Organization Classification of Tumors*. 4th ed.

L. Clinical History

Colon carcinoma is the most common malignancy in hereditary nonpolyposis colon cancer (HNPCC; Lynch syndrome (LS)). However, endometrial carcinoma develops before colon carcinoma in >50% of women with HNPCC.¹⁻⁴ Still, the reported series of HNPCC/LS-related endometrial carcinomas are much smaller in number than those reported for HNPCC/LS colonic carcinoma. Histopathologic features suggestive of HNPCC/LS-related carcinoma are well characterized in the colon, but not as well in the uterus. While lower uterine segment tumors and high grade tumors in the endometrium seem to have a higher rate of being LS-associated tumors, tumor morphology and anatomic location of tumor cannot be used to select patients for screening for LS. Many LS-associated endometrial carcinomas are seen in probands that do not meet Bethesda or Amsterdam personal/family history criteria for Lynch Syndrome. However, when examining an endometrial carcinoma in a patient under 50 years of age or with a personal or family history of colon carcinoma, it is important to consider the possibility of an HNPCC/LS-related endometrial carcinoma. According to the Society of Gynecology Oncology clinical practice statement all women diagnosed with endometrial cancer should undergo systematic clinical screening for Lynch syndrome and/or molecular screening. Molecular tumor testing on cancers diagnosed at age less than 60 regardless of personal or family cancer history is recommended. If resources are available universal molecular screening for LS is the preferred strategy. In these cases, testing for defective DNA mismatch repair proteins by immunohistochemistry is the most cost-effective method (MLH1, MSH2, MSH6, and PMS2 antibodies are commercially available).⁵ Loss of MSH2 or MSH6 expression essentially always indicates Lynch syndrome. HNPCC/LS-related endometrial carcinoma is predominantly associated with MSH2 mutations, and MSH6 mutations.¹⁻⁴ PMS2 loss is often associated with loss of MLH1 and is only independently meaningful if MLH1 is intact. MLH1 hypermethylation analysis should be completed on tumors that show loss of MLH1 on IHC to help triage appropriate cases for germline testing. In addition, PCR assays can be used to detect high levels of microsatellite alterations (MSI), a condition that is definitional for defective DNA mismatch repair. This testing is performed on paraffin-embedded tissue and compares the results of tumor DNA to those of non-neoplastic tissues from the same patient. Please refer to the CAP endometrial cancer biomarker reporting template on www.cap.org/cancerprotocols for further details.

References

1. Aarnio M, Sankila R, Pukkala E, Salovaara R, Aaltonen LA, de la Chapelle A, Peltomäki P, Mecklin JP, Järvinen HJ. Cancer risk in mutation carriers of DNA-mismatch-repair genes. *Int J Cancer*. 1999;81:214-218.
2. Watson P, Vasen HF, Mecklin JP, Järvinen H, Lynch HT. The risk of endometrial cancer in hereditary nonpolyposis colorectal cancer. *Am J Med*. 1994;96:516-520.
3. Wijnen J, de Leeuw W, Vasen H, et al. Familial endometrial cancer in female carriers of MSH6 germline mutations. *Nat Genet*. 1999;23:142-144.
4. Charames GS, Millar AL, Pal T, Narod S, Bapat B. Do MSH6 mutations contribute to double primary cancers of the colorectum and endometrium? *Hum Genet*. 2000;107:623-629.
5. Mills AM, Liou S, Ford JM, Berek JS, Pai RK, Longacre TA. Lynch syndrome screening should be considered for all patients with newly diagnosed endometrial cancer. *Am J Surg Pathol*. 2014;38:1501-1509.