



## Protocol for the Examination of Specimens From Patients With Primary Tumors of the Ovary, Fallopian Tube, or Peritoneum

Version: OvaryFallopian 1.1.0.0

Protocol Posting Date: August 2018

Includes pTNM requirements from the 8<sup>th</sup> Edition, AJCC Staging Manual and 2015 FIGO Cancer Report

**For accreditation purposes, this protocol should be used for the following procedures AND tumor types:**

Procedure	Description
Resection	Includes oophorectomy, salpingo-oophorectomy, salpingectomy, subtotal resection, or removal of tumor in fragments
Tumor Type	Description
Primary malignant tumors of ovary, fallopian tube or peritoneum	Includes all primary epithelial borderline tumors and carcinomas, carcinosarcoma, malignant germ cell tumors, and malignant sex cord-stromal tumors.

**This protocol is NOT required for accreditation purposes for the following:**

Procedure
Biopsy
Primary resection specimen with no residual cancer (eg, following neoadjuvant therapy)
Cytologic specimens

**The following tumor types should NOT be reported using this protocol:**

Tumor Type
Peritoneal mesothelioma
Lymphoma (consider the Hodgkin or non-Hodgkin Lymphoma protocols)
Sarcoma (consider the Soft Tissue protocol)

### Authors

Saeid Movahedi-Lankarani, MD\*; Uma Krishnamurti, MD, PhD\*; Debra A. Bell, MD; George G. Birdsong, MD; Charles V. Biscotti, MD; Christopher N. Chapman Jr, MD; Veronica Klepeis, MD, PhD; Christopher N. Otis, MD

With guidance from the CAP Cancer and CAP Pathology Electronic Reporting Committees.

\* Denotes primary authors. All other contributing authors are listed alphabetically.

### Accreditation Requirements

This protocol can be utilized for a variety of procedures and tumor types for clinical care purposes. For accreditation purposes, only the definitive primary cancer resection specimen is required to have the core and conditional data elements reported in a synoptic format.

- Core data elements are required in reports to adequately describe appropriate malignancies. For accreditation purposes, essential data elements must be reported in all instances, even if the response is “not applicable” or “cannot be determined.”
- Conditional data elements are only required to be reported if applicable as delineated in the protocol. For instance, the total number of lymph nodes examined must be reported, but only if nodes are present in the specimen.
- Optional data elements are identified with “+” and although not required for CAP accreditation purposes, may be considered for reporting as determined by local practice standards.

The use of this protocol is not required for recurrent tumors or for metastatic tumors that are resected at a different time than the primary tumor. Use of this protocol is also not required for pathology reviews performed at a second institution (ie, secondary consultation, second opinion, or review of outside case at second institution).

### Synoptic Reporting

All core and conditionally required data elements outlined on the surgical case summary from this cancer protocol must be displayed in synoptic report format. Synoptic format is defined as:

- Data element: followed by its answer (response), outline format without the paired "Data element: Response" format is NOT considered synoptic.
- The data element should be represented in the report as it is listed in the case summary. The response for any data element may be modified from those listed in the case summary, including “Cannot be determined” if appropriate.
- Each diagnostic parameter pair (Data element: Response) is listed on a separate line or in a tabular format to achieve visual separation. The following exceptions are allowed to be listed on one line:
  - Anatomic site or specimen, laterality, and procedure
  - Pathologic Stage Classification (pTNM) elements
  - Negative margins, as long as all negative margins are specifically enumerated where applicable
- The synoptic portion of the report can appear in the diagnosis section of the pathology report, at the end of the report or in a separate section, but all Data element: Responses must be listed together in one location

Organizations and pathologists may choose to list the required elements in any order, use additional methods in order to enhance or achieve visual separation, or add optional items within the synoptic report. The report may have required elements in a summary format elsewhere in the report IN ADDITION TO but not as replacement for the synoptic report ie, all required elements must be in the synoptic portion of the report in the format defined above.

**CAP Laboratory Accreditation Program Protocol Required Use Date: April 2019**

## CAP Ovary and Fallopian Protocol Summary of Changes

---

### Version 1.1.0.0

**The following data elements were modified:**

**Regional Lymph Nodes** - Revised the format to clarify reporting involved and uninvolved nodes

## Surgical Pathology Cancer Case Summary

---

Protocol posting date: August 2018

### OVARY or FALLOPIAN TUBE or PRIMARY PERITONEUM:

*Note: Applies to primary tumors of ovarian, fallopian tube, or primary peritoneal origin. If bilateral tumors of 2 different histologic types are present, separate case summaries should be used for each tumor.*

**Select a single response unless otherwise indicated.**

#### Procedure (select all that apply) (Note A)

- Total hysterectomy and bilateral salpingo-oophorectomy
- Radical hysterectomy
- Simple hysterectomy
- Supracervical hysterectomy
- Bilateral salpingo-oophorectomy
- Right salpingo-oophorectomy
- Left salpingo-oophorectomy
- Salpingo-oophorectomy, side not specified
- Right oophorectomy
- Left oophorectomy
- Oophorectomy, side not specified
- Bilateral salpingectomy
- Right salpingectomy
- Left salpingectomy
- Salpingectomy, side not specified
- Omentectomy
- Peritoneal biopsies
- Peritoneal tumor debulking
- Peritoneal washing
- Pleurocentesis (pleural fluid)
- Other (specify): \_\_\_\_\_

*Note: For information about lymph node sampling, please refer to the Regional Lymph Node section.*

#### + Hysterectomy Type

- +  Abdominal
- +  Vaginal
- +  Vaginal, laparoscopic-assisted
- +  Laparoscopic
- +  Laparoscopic, robotic-assisted
- +  Other (specify): \_\_\_\_\_
- +  Not specified

#### Specimen Integrity (Note B)

*Note: For primary ovarian tumors, if the ovary containing primary tumor is removed intact into a laparoscopy bag and ruptured in the bag by the surgeon without spillage into the peritoneal cavity (to allow for removal via laparoscopy port site or small incision), the specimen integrity should be listed as "capsule intact" with a comment explaining this in the report.*

#### Specimen Integrity of Right Ovary (if applicable)

- Capsule intact
- Capsule ruptured
- Fragmented
- Other (specify): \_\_\_\_\_

+ Data elements preceded by this symbol are not required for accreditation purposes. These optional elements may be clinically important but are not yet validated or regularly used in patient management.

Specimen Integrity of Left Ovary (if applicable)

- Capsule intact
- Capsule ruptured
- Fragmented
- Other (specify): \_\_\_\_\_

Specimen Integrity of Right Fallopian Tube (if applicable)

- Serosa intact
- Serosa ruptured
- Fragmented
- Other (specify): \_\_\_\_\_

Specimen Integrity of Left Fallopian Tube (if applicable)

- Serosa intact
- Serosa ruptured
- Fragmented
- Other (specify): \_\_\_\_\_

+ Morcellated specimen (specify organ): \_\_\_\_\_

**Tumor Site (Notes C, D, and E)**

*Note: Please select the primary tumor site only. Information about additional organ involvement is provided in another section.*

- Right ovary
- Left ovary
- Bilateral ovaries
- Ovary, laterality cannot be determined (explain): \_\_\_\_\_
- Right fallopian tube
- Left fallopian tube
- Bilateral fallopian tubes
- Fallopian tube, laterality cannot be determined (explain): \_\_\_\_\_
- Right tubo-ovarian
- Left tubo-ovarian
- Bilateral tubo-ovarian
- Tubo-ovarian, laterality cannot be determined (explain): \_\_\_\_\_
- Primary peritoneum
- Other (specify): \_\_\_\_\_

**Ovarian Surface Involvement (required only if applicable)**

- Present
  - Specify laterality (if applicable): \_\_\_\_\_
- Absent
- Cannot be determined (explain): \_\_\_\_\_

**Fallopian Tube Surface Involvement (required only if applicable)**

- Present
  - Specify laterality (if applicable): \_\_\_\_\_
- Absent
- Cannot be determined (explain): \_\_\_\_\_

**Tumor Size**

*Note: For bilateral tumors, please report maximum dimension for each primary tumor, specifying by laterality.*

- Greatest dimension (centimeters): \_\_\_ cm
- + Additional dimensions (centimeters): \_\_\_ x \_\_\_ cm
- Cannot be determined (explain): \_\_\_\_\_

+ Data elements preceded by this symbol are not required for accreditation purposes. These optional elements may be clinically important but are not yet validated or regularly used in patient management.

**Histologic Type (select all that apply) (Notes F and G)**

- Serous tubal intraepithelial carcinoma (STIC)  
 Serous borderline tumor/atypical proliferative serous tumor  
 Serous borderline tumor/atypical proliferative serous tumor with microinvasion  
 Serous borderline tumor-micropapillary variant/noninvasive low-grade serous carcinoma  
 Serous carcinoma  
 Endometrioid borderline tumor/atypical proliferative endometrioid tumor  
 Endometrioid borderline tumor/atypical proliferative endometrioid tumor with microinvasion  
 Endometrioid carcinoma  
 Clear cell borderline tumor/atypical proliferative clear cell tumor  
 Clear cell carcinoma  
 Mucinous borderline tumor/atypical proliferative mucinous tumor  
 Mucinous borderline tumor/atypical proliferative mucinous tumor with intraepithelial carcinoma  
 Mucinous borderline tumor/atypical proliferative mucinous tumor with microinvasion  
 Mucinous carcinoma  
 Mucinous carcinoma with expansile invasive pattern  
 Mucinous carcinoma with infiltrative invasive pattern  
 Seromucinous borderline tumor/atypical proliferative seromucinous tumor  
 Seromucinous borderline tumor/atypical proliferative seromucinous tumor with microinvasion  
 Seromucinous carcinoma  
 Brenner tumor, borderline/atypical proliferative Brenner tumor  
 Brenner tumor, malignant  
 Carcinoma, subtype cannot be determined  
 Mixed epithelial borderline (atypical proliferative) tumor (specify types and percentages): \_\_\_\_\_  
 Mixed epithelial carcinoma (specify types and percentages): \_\_\_\_\_  
 Carcinosarcoma (malignant mixed Müllerian tumor)  
 Small cell carcinoma, pulmonary type  
 Small cell carcinoma, hypercalcemic type  
 Squamous cell carcinoma  
 Transitional cell carcinoma  
 Undifferentiated carcinoma  
 Granulosa cell tumor, adult type  
 Granulosa cell tumor, juvenile type  
 Other sex cord-stromal tumor (specify type): \_\_\_\_\_  
 Dysgerminoma  
 Yolk sac tumor (endodermal sinus tumor)  
 Immature teratoma  
 Carcinoma arising from a teratoma (specify type): \_\_\_\_\_  
 Mixed malignant germ cell tumor (specify types and percentages): \_\_\_\_\_  
 Other histologic type not listed (specify): \_\_\_\_\_

**Histologic Grade (required for serous, endometrioid, mucinous, and seromucinous carcinomas, immature teratomas, and Sertoli-Leydig cell tumors) (Note H)**

*Note: Serous carcinomas are graded via a 2-tier system. Immature teratomas can be graded using a 2-tier or 3-tier system. Endometrioid and mucinous carcinomas are graded via a 3-tier system. Sertoli-Leydig cell tumors are graded via a modified 3-tier grading system with grade 2 tumors being termed "intermediate differentiated." Clear cell carcinomas, borderline epithelial neoplasms, carcinosarcomas, all other malignant sex-cord stromal and germ cell tumors are not graded.*

**WHO Grading System**

- G1: Well differentiated  
 G2: Moderately differentiated  
 G3: Poorly differentiated  
 GX: Cannot be assessed

**Two-Tier Grading System (required for immature teratomas and serous carcinomas only)**

- Low grade

+ Data elements preceded by this symbol are not required for accreditation purposes. These optional elements may be clinically important but are not yet validated or regularly used in patient management.

- High grade
- Other (specify): \_\_\_\_\_
- Not applicable

**Implants (required for advanced stage serous/seromucinous borderline tumors only) (Note I)**

*Note: Serous tumor implants that were formerly classified as “invasive implants” are now classified as low-grade serous carcinoma of the peritoneum.*

- Not sampled
- Not identified
- Present (specify sites): \_\_\_\_\_

**Other Tissue/ Organ Involvement (select all that apply)**

*Note: Any organ not selected is either not involved or was not submitted.*

- Not applicable
- Not identified
- Right ovary
- Left ovary
- Ovary (side not specified)
- Right fallopian tube
- Left fallopian tube
- Fallopian tube (side not specified)
- Uterus
- Cervix
- Pelvic peritoneum
- Abdominal peritoneum
- Omentum
- Other organs/tissue (specify): \_\_\_\_\_
- Cannot be determined (explain): \_\_\_\_\_

**Largest Extrapelvic Peritoneal Focus (required only if applicable)**

- Microscopic
- Macroscopic (2 cm or less)
- Macroscopic (greater than 2 cm)
- Cannot be determined (explain): \_\_\_\_\_

Specify site (if applicable): \_\_\_\_\_

**Peritoneal/Ascitic Fluid**

- Not submitted/unknown
- Negative for malignancy (normal/benign)
- Atypical and/or suspicious (explain): \_\_\_\_\_
- Malignant (positive for malignancy)
- Unsatisfactory/nondiagnostic (explain): \_\_\_\_\_
- Other (specify): \_\_\_\_\_
- Results pending

**+ Pleural Fluid**

- +  Not submitted / unknown
- +  Negative for malignancy (normal/benign)
- +  Atypical and/or suspicious (explain): \_\_\_\_\_
- +  Malignant (positive for malignancy)
- +  Unsatisfactory/nondiagnostic (explain): \_\_\_\_\_
- +  Results pending

+ Data elements preceded by this symbol are not required for accreditation purposes. These optional elements may be clinically important but are not yet validated or regularly used in patient management.

**Treatment Effect (required only for high-grade serous carcinomas) (Note J)**

*Note: Treatment effect is based on assessment of residual tumor in the omentum.*

- No known presurgical therapy
- No definite or minimal response identified (chemotherapy response score 1 [CRS 1])
- Moderate response identified (CRS 2)
- Marked response with no or minimal residual cancer (CRS 3)
- Cannot be determined

**Regional Lymph Nodes**

*Note: For ovarian, fallopian tube, or primary peritoneal tumors, lymph nodes designated as pelvic; (parametrial, obturator, internal iliac (hypogastric), external iliac, common iliac, sacral, presacral), para-aortic, and retroperitoneal are considered regional lymph nodes. Although not specifically named by AJCC or FIGO, intra-omental and peri-intestinal lymph nodes, are also regarded as regional lymph nodes for staging purposes. Any other involved nodes should be categorized as metastases (pM1) and commented on in the distant metastasis section. Presence of isolated tumor cells no greater than 0.2 mm in regional lymph node(s) is considered N0 (i+).*

- No lymph nodes submitted or found

Lymph Node Examination (required only if lymph nodes are present in the specimen)

- All lymph nodes negative for tumor cells
- Positive for tumor cells (select all that apply)
  - Number of Nodes with Metastasis Greater than 10 mm: \_\_\_\_\_
  - Number of Nodes with Metastasis 10 mm or Less (excludes isolated tumor cells): \_\_\_\_\_
  - Number of Nodes with Isolated Tumor Cells (0.2 mm or less) (if applicable): \_\_\_\_\_
  - Number cannot be determined (explain): \_\_\_\_\_

*Note: Reporting the number of lymph nodes with isolated tumor cells is required only in the absence of metastasis greater than 0.2 mm in other lymph nodes.*

+ Nodal Site(s) with Tumor Cells (specify): \_\_\_\_\_

Size of Largest Metastatic Deposit (if applicable) (millimeters): \_\_\_\_\_ mm

Location of Largest Deposit (if applicable) (specify): \_\_\_\_\_

- Number of Lymph Nodes Examined: \_\_\_\_\_
- Number cannot be determined (explain): \_\_\_\_\_
- + Specify Site(s): \_\_\_\_\_

**Pathologic Stage Classification (pTNM, AJCC 8<sup>th</sup> Edition) (Note K)**

*Note: Reporting of pT, pN, and (when applicable) pM categories is based on information available to the pathologist at the time the report is issued. Only the applicable T, N, or M category is required for reporting; their definitions need not be included in the report. The categories (with modifiers when applicable) can be listed on 1 line or more than 1 line.*

TNM Descriptors (required only if applicable) (select all that apply)

- m (multiple primary tumors)
- r (recurrent)
- y (posttreatment)

Primary Tumor (pT)

- pTX: Primary tumor cannot be assessed
- pT0: No evidence of primary tumor
- pT1: Tumor limited to ovaries (one or both) or fallopian tube(s)
- pT1a: Tumor limited to one ovary (capsule intact) or fallopian tube, no tumor on ovarian or fallopian tube surface; no malignant cells in ascites or peritoneal washings #

+ Data elements preceded by this symbol are not required for accreditation purposes. These optional elements may be clinically important but are not yet validated or regularly used in patient management.

- \_\_\_ pT1b: Tumor limited to both ovaries (capsules intact) or fallopian tubes; no tumor on ovarian or fallopian tube surface; no malignant cells in ascites or peritoneal washings
- \_\_\_ pT1c: Tumor limited to one or both ovaries or fallopian tubes with any of the following:
  - \_\_\_ pT1c1: Surgical spill
  - \_\_\_ pT1c2: Capsule ruptured before surgery or tumor on ovarian or fallopian tube surface
  - \_\_\_ pT1c3: Malignant cells in ascites or peritoneal washings
- \_\_\_ pT2: Tumor involves one or both ovaries or fallopian tubes with pelvic extension below pelvic brim or primary peritoneal cancer
  - \_\_\_ pT2a: Extension and/or implants on uterus and/or fallopian tube(s) and/or ovaries.
  - \_\_\_ pT2b: Extension to and/or implants on other pelvic tissues.
- \_\_\_ pT3: Tumor involves one or both ovaries or fallopian tubes, or primary peritoneal cancer with microscopically confirmed peritoneal metastasis outside the pelvis and/or metastasis to retroperitoneal (pelvic and/or para-aortic) lymph nodes
  - \_\_\_ pT3a: Microscopic extra-pelvic (above the pelvic brim) peritoneal involvement with or without positive retroperitoneal lymph nodes
  - \_\_\_ pT3b: Macroscopic peritoneal metastasis beyond pelvis 2 cm or less in greatest dimension with or without metastasis to retroperitoneal lymph nodes
  - \_\_\_ pT3c: Macroscopic peritoneal metastasis beyond pelvis more than 2 cm in greatest dimension with or without metastasis to the retroperitoneal lymph nodes (includes extension of tumor to capsule of liver and spleen without parenchymal involvement of either organ)

# Note: Serous tubal intraepithelial carcinoma (STIC) should be staged as pT1a if it involves one tube only, as pT1b if it involves both tubes, and as pT1c3 if it is accompanied by positive peritoneal washing washings or ascites. Nonmalignant ascites is not classified. The presence of ascites does not affect staging unless malignant cells are present.

#### Regional Lymph Nodes (pN)

- \_\_\_ pNX: Regional lymph nodes cannot be assessed
- \_\_\_ pN0: No regional lymph node metastasis
- \_\_\_ pN0(i+): Isolated tumor cells in regional lymph node(s) no greater than 0.2 mm
- \_\_\_ pN1: Positive retroperitoneal lymph nodes only (histologically confirmed)
  - \_\_\_ pN1a: Metastasis up to and including 10 mm in greatest dimension
  - \_\_\_ pN1b: Metastasis more than 10 mm in greatest dimension

#### Distant Metastasis (pM) (required only if confirmed pathologically in this case)

- \_\_\_ pM1: Distant metastasis, including pleural effusion with positive cytology; liver or splenic parenchymal metastasis; metastasis to extra-abdominal organs (including inguinal lymph nodes and lymph nodes outside the abdominal cavity); and transmural involvement of intestine
  - \_\_\_ pM1a: Pleural effusion with positive cytology
  - \_\_\_ pM1b: Liver or splenic parenchymal metastases; metastases to extra-abdominal organs (including inguinal lymph nodes and lymph nodes outside the abdominal cavity); transmural involvement of intestine

Specify site(s), if known: \_\_\_\_\_

Note: Parenchymal liver or splenic metastasis is classified as stage IV disease, whereas liver or splenic capsule metastasis is classified as stage III disease. Non-regional lymph node metastases (such as inguinal, supraclavicular, and axillary nodes) are considered M1. Involvement of surface of diaphragm is considered pT3; however, involvement of skeletal muscle of diaphragm or abdominal wall tissue beyond the peritoneum is considered distant metastasis (M1).



+ FIGO Stage (2015 FIGO Cancer Report)

- + \_\_\_ I: Tumor confined to ovaries or fallopian tube(s)
- + \_\_\_ IA: Tumor limited to 1 ovary (capsule intact) or fallopian tube; no tumor on ovarian or fallopian tube surface; no malignant cells in the ascites or peritoneal washings
- + \_\_\_ IB: Tumor limited to both ovaries (capsules intact) or fallopian tubes; no tumor on ovarian or fallopian tube surface; no malignant cells in the ascites or peritoneal washings
- + \_\_\_ IC: Tumor limited to 1 or both ovaries or fallopian tubes, with any of the following:
  - + \_\_\_ IC1: Surgical spill intraoperatively
  - + \_\_\_ IC2: Capsule ruptured before surgery or tumor on ovarian or fallopian tube surface
  - + \_\_\_ IC3: Malignant cells present in the ascites or peritoneal washings
- + \_\_\_ II: Tumor involves 1 or both ovaries or fallopian tubes with pelvic extension (below pelvic brim) or peritoneal cancer
  - + \_\_\_ IIA: Extension and/or implants on the uterus and/or fallopian tubes and/or ovaries
  - + \_\_\_ IIB: Extension to other pelvic intraperitoneal tissues
  - + \_\_\_ III: Tumor involves 1 or both ovaries, or fallopian tubes, or primary peritoneal cancer, with cytologically or histologically confirmed spread to the peritoneum outside the pelvis and/or metastasis to the retroperitoneal lymph nodes
    - + \_\_\_ IIIA: Metastasis to the retroperitoneal lymph nodes with or without microscopic peritoneal involvement beyond the pelvis
      - + \_\_\_ IIIA1: Positive retroperitoneal lymph nodes only (cytologically or histologically proven)
      - + \_\_\_ IIIA1(i): Metastasis  $\leq 10$  mm in greatest dimension<sup>#</sup>
      - + \_\_\_ IIIA1(ii): Metastasis  $>10$  mm in greatest dimension<sup>#</sup>
      - + \_\_\_ IIIA2: Microscopic extrapelvic (above the pelvic brim) peritoneal involvement with or without positive retroperitoneal lymph nodes
    - + \_\_\_ IIIB: Macroscopic peritoneal metastases beyond the pelvic brim  $\leq 2$  cm in greatest dimension, with or without metastasis to the retroperitoneal lymph nodes
    - + \_\_\_ IIIC: Macroscopic peritoneal metastases beyond the pelvic brim  $>2$  cm in greatest dimension, with or without metastases to the retroperitoneal nodes<sup>##</sup>
  - + \_\_\_ IV: Distant metastasis excluding peritoneal metastases
    - + \_\_\_ IVA: Pleural effusion with positive cytology
    - + \_\_\_ IVB: Metastases to extra-abdominal organs (including inguinal lymph nodes and lymph nodes outside of abdominal cavity)<sup>###</sup>

<sup>#</sup> This is tumor dimension and not lymph node dimension.

<sup>##</sup> Includes extension of tumor to capsule of liver and spleen without parenchymal involvement of either organ.

<sup>###</sup> Parenchymal metastases are stage IVB. Disease invading through the bowel wall and into the mucosa increases the stage to IVB, and transmural involvement of a visceral structure also represents stage IVB disease.

+ **Additional Pathologic Findings (select all that apply) (Note L)**

- + \_\_\_ None identified
- + \_\_\_ Serous tubal intraepithelial carcinoma (STIC)
- + \_\_\_ Endometriosis
- + \_\_\_ Endosalpingiosis
- + \_\_\_ Other (specify): \_\_\_\_\_

+ **Ancillary Studies (Note M)**

- + *BRCA1* mutation testing (specify result): \_\_\_\_\_
  - + *BRCA2* mutation testing (specify result): \_\_\_\_\_
  - + DNA mismatch repair enzyme studies (specify result)<sup>#</sup>: \_\_\_\_\_
- <sup>#</sup> Note: For clear cell and endometrioid carcinomas only

+ **Clinical History (select all that apply)**

- + \_\_\_ *BRCA1/2* family history
- + \_\_\_ Hereditary breast/ovarian cancer
- + \_\_\_ Lynch syndrome
- + \_\_\_ Other (specify): \_\_\_\_\_

+ Comment(s)

## Explanatory Notes

### A. Suggestions for Sampling for Microscopic Examination

#### Ovarian Surface

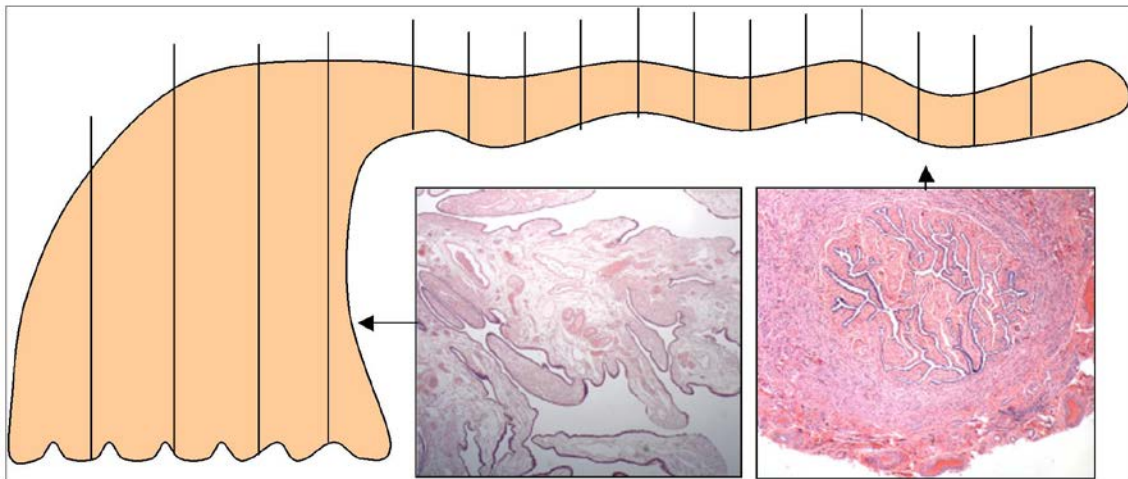
Involvement of the ovarian surface is an important element in staging tumors limited to the ovary, and the presence of surface involvement may influence treatment. Therefore, careful examination of the ovarian surface is crucial. Furthermore, in patients who undergo prophylactic (salpingo-) oophorectomy because of a family history of ovarian and/or breast cancer, very small foci of involvement of the ovarian surface may be present that may be potentially lethal and may be missed if the macroscopic inspection is not optimal.<sup>1-6</sup>

#### Ovarian/Adnexal Tumor

One section for each centimeter of the tumor's largest dimension is generally recommended, with modification based on the degree of heterogeneity of the tumor and the difficulty of diagnosis. Borderline (atypical proliferative) serous tumor, borderline serous tumors with micropapillary features/noninvasive low-grade serous carcinoma, and borderline (atypical proliferative) mucinous tumors require more sections (2 sections for each centimeter of the tumor's largest dimension is recommended in such cases). Some sections should include the ovarian surface where it is most closely approached by tumor on gross examination, with the number of sections depending on the degree of suspicion of surface involvement. Tumor adhesions and sites of rupture should be sampled and labeled specifically for microscopic identification.

#### Risk Reducing Salpingo-Oophorectomy Specimens

The ovary and fallopian tube should be submitted in toto in patients with *BRCA* mutations or suspected to be at increased risk of hereditary breast/ovarian cancer, even when grossly normal. This detailed examination results in an approximately 4-fold increase in detection of precursor lesions or early microscopic carcinoma.<sup>7</sup> Appropriate handling implies that all ovarian and tubal tissue should be serially sectioned and submitted.<sup>8,9</sup> For fallopian tubes, amputate the fimbriated ends and section parallel to the long axis of the fallopian tube to maximize the amount of tubal epithelium available for histological examination (SEE-FIM protocol)<sup>10</sup> (Figure 1). The remainder of the fallopian tube is submitted as serial cross-sections. Fixation for 1 to 2 hours prior to sectioning and/or manipulation may help prevent sloughing of the epithelium.



**Figure 1. Protocol for Sectioning and Extensively Examining the Fimbriated End (SEE-FIM) of the Fallopian Tube.**

This protocol entails amputation and longitudinal sectioning of the infundibulum and fimbrial segment (distal 2 cm) to allow maximal exposure of the tubal plicae. The isthmus and ampulla are cut transversely at 2- to 3-mm intervals. From Crum et al.<sup>10</sup> Copyright © 2007 Lippincott Williams & Wilkins. Reproduced with permission.

#### Sampling Issues

The recommendation for the number of sections to be taken of an ovarian/adnexal tumor is a general guideline, with the pathologist determining how many sections are necessary. If a tumor is obviously malignant and

homogeneous throughout on gross examination, fewer sections may be needed. In contrast, if there is great variability in the gross appearance of the sectioned surfaces or opened cysts, it may be necessary to take more sections to sample the tumor adequately. In addition, as a general recommendation, borderline serous tumors with micropapillary foci or with microinvasion should be extensively sampled to ensure adequate assessment of the extent of invasion, when present. Mucinous tumors (particularly those with solid areas), solid teratomas, and malignant germ cell tumors often require careful gross examination and judicious sampling. Of note, additional sampling of a tumor that poses problems in differential diagnosis may be more informative than special studies.

### **Fallopian Tube(s)**

For patients with high-grade serous carcinoma, if no gross lesion is present in the fimbrial end of each fallopian tube, complete microscopic examination is recommended. If a gross fimbrial lesion is present, representative sections of tumor to determine its distribution and relationship to tubal epithelium are recommended.

For patients with high-grade serous carcinoma, in contrast to other tumor histologic types covered by this protocol, a small, sometimes microscopic focus of tumor may be present in the mucosa of the fallopian tube that is the probable primary site (see Note C). The identification of tubal involvement can usually be accomplished by careful macroscopic examination and, if nothing is identified grossly, by submitting the fimbrial end of the fallopian tubes in toto for microscopic examination using the SEE-FIM protocol.<sup>10</sup>

### **Uterus**

If tumor is grossly present, sections should be taken to determine its extent, including depth of invasion of myometrium if tumor possibly originated in endometrium, and to determine its relation to ovarian tumor (metastatic to, metastatic from, independent primary). If uterine serosa is grossly involved, sections to show this should be taken.

### **Omentum**

If tumor is grossly identifiable, representative sections are enough. It is recommended to take multiple sections when no tumor is detected grossly. Although there is no general consensus regarding the number of sections that should be taken on a grossly normal omentum of a patient with an ovarian serous borderline tumor, serous carcinoma, or immature teratoma, a general recommendation would be to take 5 to 10 sections. Implants in serous borderline tumors and immature teratomas may vary from noninvasive to invasive low-grade serous carcinoma<sup>11</sup> and from mature to immature,<sup>12</sup> respectively. Identification of invasive carcinoma or an immature implant may considerably alter the prognosis and therapy. For borderline tumors or immature teratoma with grossly apparent implants, multiple sections of the implants should be taken.

For patients who have received neoadjuvant chemotherapy for advanced stage tubo-ovarian carcinoma (typically of high-grade serous type), 4 to 6 sections of omentum, to sample the most abnormal areas, are recommended to allow assessment of response to chemotherapy (see Note J).

### **Lymph Nodes**

If the lymph nodes are grossly involved by tumor, representative sections are enough. However, if the lymph nodes appear grossly free of tumor, they should be entirely submitted. In either case, the dimension of the largest metastatic deposit should be documented.

### **Other Staging Biopsy Specimens**

Staging biopsy tissues should be entirely processed unless grossly positive for tumor. If tumor is grossly seen, representative sections are usually sufficient. For borderline tumors or immature teratomas with grossly apparent implants, multiple sections of the implants should be taken (as in omental sampling).

### **Other Organ or Tissue Removed**

Sections should be taken to determine the presence or absence, as well as location and extent, of tumor, if present. Resection margins should be taken, if applicable.

### B. Rupture of Tumor

It is important to know if the tumor is intact or ruptured, because in the latter situation, malignant cells may have spilled into the abdominal cavity. In tumors that have an admixture of benign, borderline, and/or malignant areas, it may also be important to know which area ruptured.<sup>13,14</sup>

### C. Site of Origin

Although determination of primary site for most histologic types of tumor is relatively straightforward, as they present with tumor confined to the ovary, when a tumor involves ovary, fallopian tube, uterus, and multiple intraperitoneal sites, it may be difficult or impossible to determine the primary site of the tumor.

Although historically primary site was assigned based on the dominant mass, this resulted in ovarian metastases from a number of extra-ovarian primary sites (eg, stomach, vermiform appendix, colon, endocervix, endometrium) being mistaken for primary ovarian neoplasms. Increased awareness of the ability of small extra-ovarian primary tumors to metastasize to the ovary and their characteristic morphological features, and the introduction of immunostains that aid in primary site determination, have led to improved recognition of ovarian metastases in practice.

There remain challenges in assignment of primary site in cases of advanced stage high-grade serous carcinoma. Table 1 reflects current recommendations for site assignment in such cases.

**Table 1. Criteria for Assignment of Primary Site in Tubo-Ovarian High-Grade Serous Carcinoma (HGSC)<sup>1,3,5</sup>**

Criteria	Primary Site	Comment
Serous tubal intraepithelial carcinoma (STIC) present	Fallopian tube	Regardless of presence and size of ovarian and peritoneal disease.
Invasive mucosal carcinoma in tube, with or without STIC	Fallopian tube	Regardless of presence and size of ovarian and peritoneal disease.
Fallopian tube partially or entirely incorporated into tubo-ovarian mass	Fallopian tube	Regardless of presence and size of ovarian and peritoneal disease.
No STIC or invasive mucosal carcinoma in either tube in presence of ovarian mass or microscopic ovarian involvement	Ovary	Both tubes should be clearly visible and fully examined by a standardized SEE-FIM protocol. Regardless of presence and size of peritoneal disease.
Both tubes and both ovaries grossly and microscopically normal (when examined entirely) or involved by benign process in presence of peritoneal HGSC	Primary peritoneal HGSC	As recommended in World Health Organization (WHO) 2014 classification. This diagnosis should only be made in specimens removed at primary surgery prior to any chemotherapy; see below for samples following chemotherapy.
HGSC diagnosed on small sample, peritoneal/omental biopsy or cytology	Tubo-ovarian	Note: this should be supported by clinicopathological findings including immunohistochemistry to exclude mimics, principally uterine serous carcinoma
Post-chemotherapy with residual disease	Same criteria as described above	
Post-chemotherapy with no residual disease	Tubo-ovarian	

*Site assignment as “undesignated” should be avoided as far as possible and used only in the rare event that a case does not fit into any of the above categories and/or there remains doubt over whether it is of tubo-ovarian or endometrial origin.*

An adenocarcinoma is primary in the peritoneum when the ovaries and fallopian tubes are not involved or are involved only with minimal surface/serosal implants.

It is important to note that serous carcinomas of endometrium may present with adnexal mass(es). In such cases there is often not the extensive omental involvement characteristic of primary tubo-ovarian high-grade serous carcinoma. Within the endometrium, there may be a co-existent precursor lesion (in situ serous carcinoma, serous endometrial intraepithelial carcinoma), supporting primary endometrial origin of the tumor. WT-1 staining is typically strong and diffuse in tubo-ovarian high-grade serous carcinoma and weak/focal or negative in endometrial serous carcinoma. However, WT-1 is not completely sensitive or specific in determining primary site.<sup>1,3</sup> Further study is needed to improve the ability to distinguish between high-grade serous carcinoma of

endometrial and tubo-ovarian origin; however, it is likely that most instances where high-grade serous carcinoma involves the endometrium, the tumor is primary endometrial serous carcinoma.

#### D. Tumor Location

Distribution of tumor in the ovary may be a clue to its origin. If the tumor is mainly present on the surface of the ovary without forming a discrete lesion, the tumor is more likely to be secondary ovarian involvement. If a tumor is centered or mainly involves the ovarian hilus, it is most likely to be a metastasis. In the case of mucinous neoplasms, if they are bilateral or associated with mucinous ascites or peritoneal/ovarian surface involvement, they are more likely to be metastatic.<sup>15,16</sup>

#### E. Contralateral Ovary

Contralateral ovary refers to the ovary that is non-dominant because it is either (1) involved by a tumor that is similar to but smaller than the dominant ovarian tumor, (2) contains only what appears to be metastatic tumor on gross examination, or (3) is negative for tumor. If the contralateral ovary contains only focal tumor, the gross and microscopic examination should concentrate on determining whether the tumor is an independent primary or it is metastatic from the dominant ovary. Metastatic involvement is supported by the same criteria that are used to distinguish primary and metastatic cancers to the ovary (multiple nodules, surface implants, and hilar vascular space invasion favor metastasis).

#### F. Histologic Type

It is recommended that the World Health Organization (WHO) classification and nomenclature of ovarian tumors be used because of its wide acceptance.<sup>17</sup> An abbreviated form of this classification is shown below.

##### Serous Tumors

- Serous tubal intraepithelial carcinoma (STIC)
- Serous borderline tumor/atypical proliferative serous tumor
- Serous borderline tumor, micropapillary variant/noninvasive low-grade serous carcinoma
- Low-grade serous carcinoma
- High grade serous carcinoma

##### Mucinous Tumors

- Mucinous borderline tumor/atypical proliferative serous tumor
- Mucinous carcinoma

##### Seromucinous Tumors

- Seromucinous borderline tumor/atypical proliferative seromucinous tumor
- Seromucinous carcinoma

##### Endometrioid Tumors

- Endometrioid borderline tumor
- Endometrioid carcinoma

##### Clear Cell Tumors

- Clear cell borderline tumor
- Clear cell carcinoma

##### Brenner Tumors

- Borderline Brenner tumor/atypical proliferative Brenner tumor
- Malignant Brenner tumor

##### Mixed Epithelial Borderline Tumor

##### Mixed Epithelial Carcinoma

##### Carcinoma, Subtype Cannot Be Determined

##### Undifferentiated Carcinoma

##### Carcinosarcoma (malignant mixed Müllerian tumor)

##### Malignant Sex Cord-Stromal Tumors

- Granulosa cell tumor, adult type
- Granulosa cell tumor, juvenile type
- Sertoli-Leydig cell tumor
- Other sex cord-stromal tumor

##### Malignant Germ Cell Tumors

- Dysgerminoma

Yolk sac tumor  
 Embryonal carcinoma  
 Choriocarcinoma, non-gestational  
 Immature teratoma  
 Carcinoma arising in a teratoma  
 Mixed malignant germ cell tumor

Histologic type of ovarian carcinoma can be diagnosed with a high degree of reproducibility in routine practice and does have clinical implications.<sup>17</sup> For example, hereditary breast and ovarian cancer syndrome is associated with high-grade serous carcinoma, while Lynch syndrome is associated with endometrioid and clear cell tumors (both tumors that can be seen in association with endometriosis), so accurate diagnosis is important.

The distinction between high-grade serous carcinoma and low-grade serous carcinoma is not an assignment of grade based on a continuum. They differ with respect to risk factors, precursor lesions, response to chemotherapy, and genetic events during oncogenesis, and merit consideration as distinct histologic types. The criteria for distinguishing between high-grade serous carcinoma and low-grade serous carcinoma are primarily based on nuclear variability (>3-fold nuclear size variation). In cases where the distinction is difficult, p16 and p53 immunostaining and assessment of mitotic activity (>12 mitoses/10 high-power fields) can be used. Such a system has molecular and prognostic validity and excellent inter-observer agreement.<sup>17</sup>

High-grade tumors with ambiguous features, such that 1 of the specific histologic types listed cannot be diagnosed, should be classified as “carcinoma, subtype cannot be determined”; however, this is a very infrequent situation, and every effort should be made to subclassify such tumors.

Serous tubal intraepithelial carcinoma (STIC) is an unusual entity. Although an “in situ” neoplasm, it has malignant potential to spread throughout the peritoneal cavity.<sup>18</sup> Therefore, with cases of only a STIC as a primary site and negative staging and negative peritoneal washing, it is recommended to stage such cases as an AJCC pT1a/FIGO IA tumor.

### G. Mixtures of Histologic Types of Tumors

The term *mixed carcinoma* should only be used when 2 or more distinctive subtypes of surface epithelial carcinomas are identified. When a carcinoma is classified as “mixed,” the major and minor types and their relative proportions should be specified.

The diagnosis of mixed carcinoma was relatively common in the past, but with application of current histopathologic criteria, fewer than 1% of tubo-ovarian carcinomas are mixed, and the most common admixture is of endometrioid and clear cell carcinoma.<sup>17</sup> It is now appreciated that high-grade serous carcinomas show a wide range of histopathologic features, and glandular (pseudoendometrioid) differentiation, solid architecture, transitional growth pattern, or clear cell change are now accepted as being within the spectrum of high-grade serous carcinoma, and the presence of these variants does not warrant diagnosis as mixed carcinoma.<sup>17,19</sup>

Therefore, a mixed carcinoma should only be used when there are 2 or more distinct and separate histologic types in the tumor.

Quantitation of various epithelial cell types within a carcinoma, as well as quantitation of tumor types within primitive germ cell tumors, may be prognostically important.<sup>20</sup>

### H. Histologic Grade

#### Epithelial Carcinomas

Clear cell carcinoma and carcinosarcomas are not graded; at present there is no grading system that has consistently been shown to prognosticate for these histologic types. Serous carcinomas are stratified into low grade and high grade. Endometrioid carcinomas may be graded according to the FIGO system used for endometrioid carcinomas of the endometrium, as shown below.

Grade 1    ≤5% of nonsquamous, solid growth  
 Grade 2    6% to 50% of nonsquamous solid growth

Grade 3 >50% of nonsquamous, solid growth

Notable nuclear atypia, inappropriate for the architectural grade, raises the grade of a grade 1 or grade 2 tumor by 1 grade.

There are no defined grading systems in widespread use for the remaining histologic types of ovarian carcinoma (eg, mucinous), and a gestalt 3-tier grading system can be used, acknowledging that it is not well validated.

Grade X	Cannot be assessed
Grade 1	Well differentiated
Grade 2	Moderately differentiated
Grade 3	Poorly differentiated (tumors with minimal differentiation seen in very small foci)

Seromucinous tumors are tumors with more than one Müllerian epithelial cell type. Although most commonly seen cell types are serous and mucinous, on occasion clear cell, transitional, or squamous epithelium can be seen. Such tumors can be classified as by the 2-tier (almost always low grade) or the 3-tier grading systems listed above.

### Germ Cell Tumors

Immature teratomas are the only malignant germ cell tumors that are graded. They are classically graded on the basis of the quantity of immature/embryonal elements (almost always neuroectodermal tissue) that are present.<sup>21</sup> Even though in the past a 3-tier system was used to classify immature teratomas (G1 = immature neural tissue occupying <1 low-power field [40X] in any slide, and G3 = immature neural tissue occupying ≥4 low-power fields in any slide), a 2-tiered grading system (low versus high grade) has been proposed by some experts.<sup>22</sup> Grade 1 tumors are considered low grade while grade 2 and grade 3 tumors are considered high grade. Also, implants associated with immature teratomas must be assessed for the presence of immature elements, typically glial tissue.

### Sertoli-Leydig Cell Tumors

Sertoli-Leydig cell tumors are graded in a 3-part grading system, as described in the WHO 2014 classification.<sup>17</sup> Briefly, in well-differentiated (grade 1) tumors, the Sertoli cells are present in open or closed tubules; in moderately differentiated (grade 2) tumors, the Sertoli cells are present in lobular aggregates, although there may be some tubular architecture present; and in poorly differentiated (grade 3) tumors, there is sarcomatous sheets of stroma; the lobulated Sertoliform growth typical of (grade 2) tumors, if present, is only focal.

### I. Implants (Serous/Seromucinous Borderline Tumors Only)

In both serous borderline and seromucinous borderline tumors, peritoneal implants must be assessed for invasiveness. Noninvasive implants can be subdivided into epithelial and desmoplastic types and both are typically associated with favorable prognosis. Distinction between subtypes of noninvasive implants is academic and of no clinical significance.

Note that implants with invasive carcinoma (formerly designated as “invasive implants,” as per Bell and Scully criteria) result in a diagnosis of low-grade serous carcinoma or seromucinous carcinoma, based on the WHO 2014 classification,<sup>17</sup> as they are associated with a poor prognosis (identical to that of low-grade serous carcinomas).

### J. Chemotherapy Response Score

A system for histopathologic assessment of response to neoadjuvant chemotherapy (chemotherapy response score or CRS) for high-grade serous carcinoma has been developed and validated, and shown to be highly reproducible.<sup>23</sup> This 3-tiered scoring system is based on assessment of the section of *omentum* that shows the *least* response to chemotherapy. The criteria are shown in Table 2.



**Table 2. Criteria of the Chemotherapy Response Score**

<p><b>CRS 1: No or minimal tumor response</b></p> <p>Mainly viable tumor with no or minimal regression-associated fibro-inflammatory changes,<sup>#</sup> limited to a few foci; cases in which it is difficult to decide between regression and tumor-associated desmoplasia or inflammatory cell infiltration</p>
<p><b>CRS 2: Appreciable tumor response amidst viable tumor, both readily identifiable and tumor regularly distributed</b></p> <p>Ranging from multifocal or diffuse regression associated fibro-inflammatory changes,<sup>#</sup> with viable tumor in sheets, streaks, or nodules, to extensive regression associated fibro-inflammatory changes<sup>#</sup> with multifocal residual tumor which is easily identifiable</p>
<p><b>CRS 3: Complete or near-complete response with no residual tumor OR minimal <i>irregularly scattered</i> tumor foci seen as individual cells, cell groups, or nodules up to 2 mm in maximum size</b></p> <p>Mainly regression-associated fibro-inflammatory changes or, in rare cases, no/very little residual tumor in complete absence of any inflammatory response; advisable to record whether “no residual tumor” or “microscopic residual tumor present”</p>

<sup>#</sup> Regression-associated fibro-inflammatory changes: Fibrosis associated with macrophages, including foam cells, mixed inflammatory cells, and psammoma bodies; to distinguish from tumor-related inflammation or desmoplasia.

### K. Pathologic Stage Classification

In view of the role of the pathologist in the staging of cancers, the staging system for ovarian cancer endorsed by the American Joint Committee on Cancer (AJCC) and the International Union Against Cancer (UICC), as well as the parallel system formulated by the International Federation of Gynecology and Obstetrics (FIGO), are recommended.<sup>24-27</sup>

According to AJCC/UICC convention, the designation “T” refers to a primary tumor that has not been previously treated. The symbol “p” refers to the pathologic classification of the TNM, as opposed to the clinical classification, and is based on gross and microscopic examination. pT entails a resection of the primary tumor or biopsy adequate to evaluate the highest pT category, pN entails removal of nodes adequate to validate lymph node metastasis, and pM implies microscopic examination of distant lesions. Clinical classification (cTNM) is usually carried out by the referring physician before treatment during initial evaluation of the patient or when pathologic classification is not possible.

Pathologic staging is usually performed after surgical resection of the primary tumor. Biopsies of all frequently involved sites, such as the omentum, mesentery, diaphragm, peritoneal surfaces, pelvic nodes, and para-aortic nodes, are required for ideal staging of early disease. For example, a patient can be confidently coded as stage IA (T1 N0 M0), if negative biopsies of all of the aforementioned sites are obtained to exclude microscopic metastases. Pathologic staging depends on pathologic documentation of the anatomic extent of disease, whether or not the primary tumor has been completely removed. If a biopsied tumor is not resected for any reason (eg, when technically infeasible), and if the highest T and N categories or the M1 category of the tumor can be confirmed microscopically, the criteria for pathologic classification and staging have been satisfied without total removal of the primary cancer.

### TNM Descriptors

For identification of special cases of TNM or pTNM classifications, the “m” suffix and “y,” “r,” and “a” prefixes are used. Although they do not affect the stage grouping, they indicate cases needing separate analysis.

The “m” suffix indicates the presence of multiple primary tumors in a single site and is recorded in parentheses: pT(m)NM.

The “y” prefix indicates those cases in which classification is performed during or after initial multimodality therapy (ie, neoadjuvant chemotherapy, radiation therapy, or both chemotherapy and radiation therapy). The cTNM or pTNM category is identified by a “y” prefix. The ycTNM or ypTNM categorizes the extent of tumor actually present at the time of that examination. The “y” categorization is not an estimate of tumor before multimodality therapy (ie, before initiation of neoadjuvant therapy).

The “r” prefix indicates a recurrent tumor when staged after a documented disease-free interval and is identified by the “r” prefix: rTNM.

The “a” prefix designates the stage determined at autopsy: aTNM.

### N Category Considerations

Isolated tumor cells (ITCs) are single cells or small clusters of cells not more than 0.2 mm in greatest dimension. Lymph nodes or distant sites with ITCs found by either histologic examination (eg, immunohistochemical evaluation for cytokeratin) or nonmorphological techniques (eg, flow cytometry, DNA analysis, polymerase chain reaction [PCR] amplification of a specific tumor marker) should be so identified. There is currently no guidance in the literature as to how these patients should be coded; until more data are available, they should be coded as “N0(i+)” with a comment noting how the cells were identified.

### L. Other Lesions

The presence of endometriosis, particularly if it is in continuity with either an endometrioid or clear cell carcinoma, is an important clue as to the primary nature of the ovarian tumor.

### M. Special Studies

Special studies including histochemical, immunohistochemical, and molecular genetic studies may be used in some cases. Evaluation for *BRCA1/BRCA2* testing on patients with high-grade serous carcinoma of tubal/ovarian/peritoneal origin should be performed at the discretion of genetic counselors with assessment of other risk factors. Immunohistochemical stains for DNA mismatch repair enzymes MLH1, MS2, MSH6, and PMS2 for Lynch syndrome screening is recommended on all endometrioid and clear cell carcinomas of the ovary.<sup>28-29</sup>

### References

1. Singh N, Gilks CB, Wilkinson N, et al. Assessment of a new system for primary site assignment in high-grade serous carcinoma of the fallopian tube, ovary, and peritoneum. *Histopathology*. 2015;67(3):331-337.
2. Gilks CB, Irving J, Kobel M, et al. Incidental nonuterine high-grade serous carcinomas arise in the fallopian tube in most cases: further evidence for the tubal origin of high-grade serous carcinomas. *Am J Surg Pathol*. 2015;39:357-364.
3. McCluggage WG, Judge MJ, Clarke BA, et al. Data set for reporting of ovary, fallopian tube and primary peritoneal carcinoma: recommendations from the International Collaboration on Cancer Reporting (ICCR). *Mod Pathol*. 2015;28(8):1101-1122.
4. Morrison JC, Blanco LZ Jr, Vang R, Ronnett BM. Incidental serous tubal intraepithelial carcinoma and early invasive serous carcinoma in the nonprophylactic setting: analysis of a case series. *Am J Surg Pathol*. 2015;39(4):442-53.
5. Singh N, Gilks CB, Hirschowitz L, et al. Adopting a uniform approach to site assignment in tubo-ovarian high grade serous carcinoma – the time has come. *Int J Gynecol Pathol*. In press.
6. Bell DA, Scully RE. Early de novo ovarian carcinoma: a study of fourteen cases. *Cancer*. 1994;73(7):1859-1864.
7. Lamb JD, Garcia RL, Goff BA, Paley PJ, Swisher EM. Predictors of occult neoplasia in women undergoing risk-reducing salpingo-oophorectomy. *Am J Obstet Gynecol*. 2006;194(6):1702-1709.
8. Kindelberger DW, Lee Y, Miron A, et al. Intraepithelial carcinoma of the fimbria and pelvic serous carcinoma: evidence for a causal relationship. *Am J Surg Pathol*. 2007;31(2):161-169.
9. Medeiros F, Muto MG, Lee Y, et al. The tubal fimbria is a preferred site for early adenocarcinoma in women with familial ovarian cancer syndrome. *Am J Surg Pathol*. 2006;30(2):230-236.

10. Crum CP, Drapkin R, Miron A, et al. The distal fallopian tube: a new model for pelvic serous carcinogenesis. *Curr Opin Obstet Gynecol*. 2007;19(1):3-9.
11. Bell DA, Weinstock MA, Scully RE. Peritoneal implants of ovarian serous borderline tumors: histologic features and prognosis. *Cancer*. 1988;62(10):2212-2222.
12. Robboy SJ, Scully RE. Ovarian teratoma with glial implants on peritoneum: an analysis of 12 cases. *Hum Pathol*. 1970;1(4):643-653.
13. Vergote I, De Brabanter J, Fyles A, et al. Prognostic importance of degree of differentiation and cyst rupture in stage I invasive epithelial ovarian carcinoma. *Lancet*. 2001;357(9251):176-182.
14. Trimble EL. Prospects for improving staging of ovarian cancers. *Lancet*. 2001;357(9251):159-160.
15. Lee KR, Young RH. The distinction between primary and metastatic mucinous carcinomas of the ovary: gross and histologic findings in 50 cases. *Am J Surg Pathol*. 2003;27(3):281-292.
16. Yemelyanova AV, Vang R, Judson K, et al. Distinction of primary and metastatic mucinous tumors involving the ovary: analysis of size and laterality data by primary site with reevaluation of an algorithm for tumor classification. *Am J Surg Pathol*. 2008;32(1):128-38.
17. Kurman RJ, Carcangiu ML, Harrington CS, Young RH, eds. *WHO Classification of Tumors of the Female Reproductive Organs*. Geneva, Switzerland: WHO Press; 2014. *World Health Organization Classification of Tumors*. 4<sup>th</sup> edition.
18. Schneider S, Heikaus S, Harter P, et al. Serous tubal intraepithelial carcinoma associated with extraovarian metastases. *Int J Gynecol Cancer*. 2017;27(3):444-451.
19. MacKenzie R, Talhouk A, Eshragh S, et al. Morphologic and molecular characteristics of ovarian mixed epithelial cancers. *Am J Surg Pathol*. 2015;39:1548-1557.
20. Kurman RJ, Norris HJ. Malignant mixed germ-cell tumors of the ovary: a clinical and pathologic analysis of 30 cases. *Obstet Gynecol*. 1976;48(5):579-589.
21. Norris HJ, Zirkin HJ, Benson WL. Immature (malignant) teratoma of the ovary: a clinical and pathologic study of 58 cases. *Cancer*. 1976;37(5):2359-2372.
22. O'Connor DM, Norris HJ. The influence of grade on the outcome of stage I ovarian immature (malignant) teratomas and the reproducibility of grading. *Int J Gynecol Pathol*. 1994;13(4):283-289.
23. Bohm S, Faruqi A, Said I, et al. Chemotherapy response score: development and validation of a system to quantify histopathologic response to neoadjuvant chemotherapy in tubo-ovarian high-grade serous carcinoma. *J Clin Oncol*. 2015;33(22):2457-2463.
24. Amin MB, Edge SB, Greene FL, et al, eds.. *AJCC Cancer Staging Manual*. 8th ed. New York, NY: Springer; 2017.
25. Brierley JD, Gospodarowicz M, Wittekind Ch, eds. *TNM Classification of Malignant Tumors*. 8th ed. Oxford, UK: Wiley; 2016.
26. Wittekind CH, Henson DE, Hutter RVP, Sobin LH. *TNM Supplement: A Commentary on Uniform Use*. 2<sup>nd</sup> ed. New York, NY: Wiley-Liss; 2001.
27. FIGO Cancer Report Update on the diagnosis and management of gestational trophoblastic disease. *Int J Gynecol Obstet*. 2015;131(Suppl 2):S123-S126.
28. Lu FI, Gilks CB, Mulligan AM, et al. Prevalence of loss of expression of DNA mismatch repair proteins in primary epithelial ovarian tumors. *Int J Gynecol Pathol*. 2012;31(6):524-31.
29. Bennett JA, Morales-Oyarvide V, Campbell S, et al. Mismatch repair protein expression in clear cell carcinoma of the ovary: incidence and morphologic associations in 109 cases. *Am J Surg Pathol*. 2016;40(5):656-663.