



Protocol for the Examination of Specimens From Patients With Carcinoma of the Gallbladder

Version: Gallbladder 4.0.0.0

Protocol Posting Date: June 2017

Includes pTNM requirements from the 8th Edition, AJCC Staging Manual

For accreditation purposes, this protocol should be used for the following procedures AND tumor types:

Procedure	Description
Resection	Includes specimens designated cholecystectomy
Tumor Type	Description
Carcinoma	Includes all invasive carcinomas of the gallbladder and cystic duct, including small cell and large cell (poorly differentiated) neuroendocrine carcinomas

This protocol is NOT required for accreditation purposes for the following:

Procedure
Primary resection specimen with no residual cancer (eg, following neoadjuvant therapy)
Cytologic specimens

The following tumor types should NOT be reported using this protocol:

Tumor Type
Well-differentiated neuroendocrine tumors
Lymphoma (consider the Hodgkin or non-Hodgkin Lymphoma protocols)
Sarcoma (consider the Soft Tissue protocol)

Authors

Sanjay Kakar, MD*; Chanjuan Shi, MD, PhD*; N. Volkan Adsay, MD; Patrick L. Fitzgibbons, MD; Wendy L. Frankel, MD; Alyssa M. Krasinskas, MD; Timothy Pawlik, MD, PhD; Jean-Nicolas Vauthey, MD; Mary K. Washington, MD, PhD

With guidance from the CAP Cancer and CAP Pathology Electronic Reporting Committees.

* Denotes primary author. All other contributing authors are listed alphabetically.

Accreditation Requirements

This protocol can be utilized for a variety of procedures and tumor types for clinical care purposes. For accreditation purposes, only the definitive primary cancer resection specimen is required to have the core and conditional data elements reported in a synoptic format.

- Core data elements are required in reports to adequately describe appropriate malignancies. For accreditation purposes, essential data elements must be reported in all instances, even if the response is “not applicable” or “cannot be determined.”
- Conditional data elements are only required to be reported if applicable as delineated in the protocol. For instance, the total number of lymph nodes examined must be reported, but only if nodes are present in the specimen.
- Optional data elements are identified with “+” and although not required for CAP accreditation purposes, may be considered for reporting as determined by local practice standards.

The use of this protocol is not required for recurrent tumors or for metastatic tumors that are resected at a different time than the primary tumor. Use of this protocol is also not required for pathology reviews performed at a second institution (ie, secondary consultation, second opinion, or review of outside case at second institution).

Synoptic Reporting

All core and conditionally required data elements outlined on the surgical case summary from this cancer protocol must be displayed in synoptic report format. Synoptic format is defined as:

- Data element: followed by its answer (response), outline format without the paired "Data element: Response" format is NOT considered synoptic.
- The data element must be represented in the report as it is listed in the case summary. The response for any data element may be modified from those listed in the case summary, including “Cannot be determined” if appropriate.
- Each diagnostic parameter pair (Data element: Response) is listed on a separate line or in a tabular format to achieve visual separation. The following exceptions are allowed to be listed on one line:
 - Anatomic site or specimen, laterality, and procedure
 - Pathologic Stage Classification (pTNM) elements
 - Negative margins, as long as all negative margins are specifically enumerated where applicable
- The synoptic portion of the report can appear in the diagnosis section of the pathology report, at the end of the report or in a separate section, but all Data element: Responses must be listed together in one location

Organizations and pathologists may choose to list the required elements in any order, use additional methods in order to enhance or achieve visual separation, or add optional items within the synoptic report. The report may have required elements in a summary format elsewhere in the report IN ADDITION TO but not as replacement for the synoptic report i.e. all required elements must be in the synoptic portion of the report in the format defined above.

CAP Laboratory Accreditation Program Protocol Required Use Date: March 2018*

* Beginning January 1, 2018, the 8th edition AJCC Staging Manual should be used for reporting pTNM.

CAP Gallbladder Protocol Summary of Changes

The following data elements were modified:

Microscopic Tumor Extension
Margins
Pathologic Stage Classification (pTNM, AJCC 8th Edition)
Additional Pathologic Findings

The following data element was deleted:

Clinical History

Surgical Pathology Cancer Case Summary

Protocol posting date: June 2017

GALLBLADDER:**Select a single response unless otherwise indicated.****Procedure (Note A)**

- Simple cholecystectomy (laparoscopic or open)
 Radical cholecystectomy (with liver resection and lymphadenectomy)
 Other (specify): _____
 Not specified

Tumor Site (select all that apply)

- Fundus
 Body
 Neck
 Cystic duct
 Cannot be determined
 Other (specify): _____
 Not specified

Tumor Size

- Greatest dimension (centimeters): ___ cm
 + Additional dimensions (centimeters): ___ x ___ cm
 Cannot be determined (explain): _____

Histologic Type (Note B)

- Adenocarcinoma
 Adenocarcinoma, intestinal type
 Adenocarcinoma, biliary type
 Adenocarcinoma, gastric foveolar type
 Mucinous adenocarcinoma
 Signet-ring cell carcinoma
 Clear cell carcinoma
 Intracystic papillary neoplasm with an associated invasive carcinoma
 Mucinous cystic neoplasm with an associated invasive carcinoma
 Large cell neuroendocrine carcinoma
 Small cell neuroendocrine carcinoma
 Neuroendocrine carcinoma (poorly differentiated)[#]
 Adenosquamous carcinoma
 Squamous cell carcinoma
 Undifferentiated carcinoma
 Goblet cell carcinoid
 Mixed adenoneuroendocrine carcinoma
 Other histologic type not listed (specify): _____
 Carcinoma, not otherwise specified

[#] Note: Select this option only if large cell or small cell cannot be determined.**Histologic Grade (Note C)**

- G1: Well differentiated
 G2: Moderately differentiated
 G3: Poorly differentiated
 Other (specify): _____

+ Data elements preceded by this symbol are not required for accreditation purposes. These optional elements may be clinically important but are not yet validated or regularly used in patient management.

- GX: Cannot be assessed
- Not applicable

Tumor Extension

- No evidence of primary tumor
- Tumor invades lamina propria
- Tumor invades muscular layer
- Tumor invades perimuscular connective tissue on the peritoneal side without serosal involvement
- Tumor invades perimuscular connective tissue on the hepatic side without liver involvement
- Tumor perforates serosa (visceral peritoneum)
- Tumor directly invades the liver
- Tumor directly invades other adjacent organs or structures[#] (specify): _____
- Cannot be assessed

[#] Sites may include stomach, duodenum, colon, pancreas, extrahepatic bile ducts, omentum, main portal vein, and hepatic artery.

Margins (Note D)

Cystic Duct Margin

- Cannot be assessed
- Uninvolved by invasive carcinoma and high-grade intraepithelial neoplasia
 Distance of invasive carcinoma from margin (millimeters or centimeters): ___ mm or ___ cm
- Uninvolved by invasive carcinoma
 Distance of invasive carcinoma from margin (millimeters or centimeters): ___ mm or ___ cm
- Involved by invasive carcinoma
- Involved by high-grade biliary intraepithelial neoplasia

Liver Parenchymal Margin (required only if applicable)

- Cannot be assessed
- Uninvolved by invasive carcinoma
 + Distance of invasive carcinoma from margin (millimeters or centimeters): ___ mm or ___ cm
- Involved by invasive carcinoma

Other Margin(s) (required only if applicable)

- Specify margin(s): _____
- Cannot be assessed
 - Uninvolved by invasive carcinoma
 - Involved by invasive carcinoma

+ Lymphovascular Invasion (Note E)

- + Not identified
- + Present
- + Cannot be determined

+ Perineural Invasion (Note F)

- + Not identified
- + Present
- + Cannot be determined

Regional Lymph Nodes

- No lymph nodes submitted or found

Lymph Node Examination (required only if lymph nodes are present in the specimen)

Number of Lymph Nodes Involved: _____

+ Data elements preceded by this symbol are not required for accreditation purposes. These optional elements may be clinically important but are not yet validated or regularly used in patient management.

___ Number cannot be determined (explain): _____

Number of Lymph Nodes Examined: _____

___ Number cannot be determined (explain): _____

Pathologic Stage Classification (pTNM, AJCC 8th Edition) (Note G)

Note: Reporting of pT, pN, and (when applicable) pM categories is based on information available to the pathologist at the time the report is issued. Only the applicable T, N, or M category is required for reporting; their definitions need not be included in the report. The categories (with modifiers when applicable) can be listed on 1 line or more than 1 line.

TNM Descriptors (required only if applicable) (select all that apply)

___ m (multiple primary tumors)

___ r (recurrent)

___ y (posttreatment)

Primary Tumor (pT)

___ pTX: Primary tumor cannot be assessed

___ pT0: No evidence of primary tumor

___ pTis: Carcinoma in situ

___ pT1: Tumor invades the lamina propria or muscular layer

___ pT1a: Tumor invades the lamina propria

___ pT1b: Tumor invades the muscular layer

___ pT2: Tumor invades perimuscular connective tissue on the peritoneal side, without involvement of the serosa (visceral peritoneum) or tumor invades the perimuscular connective tissue on the hepatic side, with no extension into the liver

___ pT2a: Tumor invades perimuscular connective tissue on the peritoneal side, without involvement of the serosa (visceral peritoneum)

___ pT2b: Tumor invades the perimuscular connective tissue on the hepatic side, with no extension into the liver

___ pT3: Tumor perforates the serosa (visceral peritoneum) and/or directly invades the liver and/or one other adjacent organ or structure, such as the stomach, duodenum, colon, pancreas, omentum, or extrahepatic bile ducts

___ pT4: Tumor invades main portal vein or hepatic artery or invades two or more extrahepatic organs or structures

Regional Lymph Nodes (pN)

___ pNX: Regional lymph nodes cannot be assessed

___ pN0: No regional lymph node metastasis

___ pN1: Metastases to one to three regional lymph nodes

___ pN2: Metastases to four or more regional lymph nodes

___ No nodes submitted or found

Distant Metastasis (pM) (required only if confirmed pathologically in this case)

___ pM1: Distant metastasis

Specify site(s), if known: _____

+ Additional Pathologic Findings (select all that apply) (Note H)

+ ___ None identified

+ ___ Dysplasia/adenoma

+ ___ Cholelithiasis

+ ___ Chronic cholecystitis

+ ___ Acute cholecystitis

+ ___ Intestinal metaplasia

+ ___ Diffuse calcification (porcelain gallbladder)

+ ___ Primary sclerosing cholangitis

+ ___ Other (specify): _____

+ Data elements preceded by this symbol are not required for accreditation purposes. These optional elements may be clinically important but are not yet validated or regularly used in patient management.

+ Ancillary Studies

+ Specify: _____

+ ____ Not performed

+ Comment(s)

Explanatory Notes

A. Occult Carcinomas in Cholecystectomy Specimens

Occasionally carcinoma is found in gallbladders removed by laparoscopic surgery. Not recognized clinically or by imaging techniques, tumor is discovered during pathologic evaluation of the resected specimen. In this setting, tumor spillage with seeding along the laparoscopic tract or intra-abdominal dissemination may be a major complication of the procedure, with port site recurrences reported in up to 17% of such cases.¹⁻³ If dysplasia is found in such specimens, multiple sections should be examined to exclude invasive cancer.

B. Histologic Type

For consistency in reporting, the histologic classification proposed by the World Health Organization (WHO), shown below, is recommended.⁴ However, this protocol does not preclude use of other systems of classification or histologic types.

WHO Classification of Gallbladder Carcinomas

Adenocarcinoma
 Adenocarcinoma, intestinal type
 Adenocarcinoma, biliary type
 Adenocarcinoma, gastric foveolar type
 Mucinous adenocarcinoma
 Clear cell adenocarcinoma
 Signet-ring cell carcinoma
 Intracystic papillary neoplasm with an associated invasive carcinoma
 Mucinous cystic neoplasm with an associated invasive carcinoma
 Adenosquamous carcinoma
 Squamous cell carcinoma
 Large cell neuroendocrine carcinoma
 Small cell neuroendocrine carcinoma
 Neuroendocrine carcinoma (poorly differentiated)
 Goblet cell carcinoid
 Mixed adenoneuroendocrine carcinoma
 Undifferentiated carcinoma Tumors with no squamous, glandular or neuroendocrine differentiation have been labeled as undifferentiated carcinomas in the WHO 2010 scheme.⁴ Cribriform adenocarcinoma and hepatoid adenocarcinoma are also included in the WHO 2010 classification.

A mucocele may be mistaken for a mucinous carcinoma. Mucoceles often contain macrophages that have engulfed mucin (muciphages). Consequently, these macrophages may resemble signet-ring cells. Neoplastic signet-ring cells are cytokeratin positive, whereas muciphages are cytokeratin negative.

C. Histologic Grade

The following grading system, based on the extent of glandular formation in the tumor, is suggested:

Grade X	Grade cannot be assessed
Grade 1	Well differentiated (greater than 95% of tumor composed of glands)
Grade 2	Moderately differentiated (50% to 95% of tumor composed of glands)
Grade 3	Poorly differentiated (49% or less of tumor composed of glands)

Tumors with no squamous or glandular differentiation (undifferentiated carcinomas by WHO classification) are categorized as grade 4 (G4) in the WHO 2010 classification, but G4 is not included in the AJCC 8th edition.⁴ By convention, signet-ring cell carcinomas are assigned grade 3. The above grading scheme is not applicable to histologic subtypes of adenocarcinoma and poorly differentiated neuroendocrine carcinoma.

Although tumor stage is probably the most important prognostic factor for patient outcome, histologic grade, especially poor differentiation, also has an impact on survival.^{5,6}

D. Margins

Complete surgical resection with negative margins remains the most effective therapy for gallbladder cancer, with 5-year survival advantages of 30% for patients with negative margins (R0) compared with those with microscopic (R1) or macroscopic (R2) residual disease.⁷

E. Venous/Lymphatic Vessel Invasion

Blood vessel and/or lymphatic invasion has been reported to be an adverse prognostic feature in some but not all studies.⁸⁻¹⁰

F. Perineural Invasion

Perineural invasion by neoplastic cells is very common in gallbladder carcinoma and has been identified as an adverse prognostic factor in some but not all studies.^{8,11,12} Perineural invasion has been associated with spread of carcinoma beyond the gallbladder to involve the biliary tree.¹³ A diagnostic pitfall may occur in cases of adenomyomatous hyperplasia, because the ductal structures of adenomyomatous hyperplasia may involve perineural spaces.¹⁴

G. Pathologic Stage Classification

Surgical resection is the most effective therapy for gallbladder carcinomas, and the best estimation of prognosis is related to the anatomic extent (stage) of disease at the time of resection. In particular, lymph node metastases are predictors of poorer outcome.^{15,16}

The TNM staging system for carcinomas of the gallbladder of the American Joint Committee on Cancer (AJCC) and the International Union Against Cancer (UICC) is recommended by the protocol and shown below.¹⁷ The TNM system does not apply to carcinoid tumors or to sarcomas. Carcinomas of the gallbladder are staged according to their depth of penetration into the wall and extension to adjacent organs, and the extent of invasion correlates inversely with survival.¹⁸

According to AJCC/UICC convention, the designation “T” refers to a primary tumor that has not been previously treated. The symbol “p” refers to the pathologic classification of the TNM, as opposed to the clinical classification, and is based on gross and microscopic examination. pT entails a resection of the primary tumor or biopsy adequate to evaluate the highest pT category, pN entails removal of nodes adequate to validate lymph node metastasis, and pM implies microscopic examination of distant lesions. Clinical classification (cTNM) is usually carried out by the referring physician before treatment during initial evaluation of the patient or when pathologic classification is not possible.

Pathologic staging is usually performed after surgical resection of the primary tumor. Pathologic staging depends on pathologic documentation of the anatomic extent of disease, whether or not the primary tumor has been completely removed. If a biopsied tumor is not resected for any reason (eg, when technically infeasible) and if the highest T and N categories or the M1 category of the tumor can be confirmed microscopically, the criteria for pathologic classification and staging have been satisfied without total removal of the primary cancer.

TNM Descriptors

For identification of special cases of TNM or pTNM classifications, the “m” suffix and “y,” “r,” and “a” prefixes are used. Although they do not affect the stage grouping, they indicate cases needing separate analysis.

The “m” suffix indicates the presence of multiple primary tumors in a single site and is recorded in parentheses: pT(m)NM.

The “y” prefix indicates those cases in which classification is performed during or after initial multimodality therapy (ie, neoadjuvant chemotherapy, radiation therapy, or both chemotherapy and radiation therapy). The cTNM or pTNM category is identified by a “y” prefix. The ycTNM or ypTNM categorizes the extent of tumor actually present at the time of that examination. The “y” categorization is not an estimate of tumor before multimodality therapy (ie, before initiation of neoadjuvant therapy).

The “r” prefix indicates a recurrent tumor when staged after a documented disease-free interval and is identified by the “r” prefix: rTNM.

The “a” prefix designates the stage determined at autopsy: aTNM.

T Category Considerations

T categories are illustrated in Figures 1-4.

For gallbladder carcinomas, carcinoma in situ (pTis) as a staging term includes neoplastic cells cytologically indistinguishable from invasive carcinoma but confined within the glandular basement membrane.³ These lesions are usually referred to as high-grade dysplasia rather than carcinoma in situ and the latter term is retained for tumor registry reporting purposes as specified by law in many states. Noninvasive gallbladder tumors with a papillary growth pattern (intracystic papillary neoplasms) are classified as pTis.

Multiple sections should be examined in these cases to exclude invasive cancer.^{2,3} Dysplasia of the gallbladder mucosa is often confused with the reactive change due to inflammation or repair.

Involvement of Rokitansky-Aschoff (RA) sinuses. Distinguishing extension of dysplastic epithelium into RA sinuses from invasive carcinoma may be difficult. Connection of epithelial invaginations to the luminal surface, normal biliary epithelium admixed with neoplastic epithelium, inspissated bile in long dilated spaces, and lack of invasion of smooth muscle bundles favors noninvasive carcinoma involving RA sinuses.¹⁹ RA sinus involvement has been reported as being an independent adverse prognostic factor.²⁰

Tumors extending beyond the muscularis propria are subdivided based on involvement of the perimuscular tissue on the peritoneal side (T2a) or the hepatic side (T2b), with the latter associated with a worse outcome.²¹ If both sides are involved, the tumor should be categorized as T2b. Direct invasion into the liver or adjacent organs is not considered distant metastasis, and is categorized as T3 or T4 depending on the tumor extent.¹⁷

N Category Considerations

The regional lymph nodes of the gallbladder include nodes along the common bile duct, hepatic artery, portal vein, and cystic duct. Celiac and superior mesenteric and peripancreatic lymph node involvement is considered metastatic (M1) disease.

Although it has been suggested that micrometastases detected by immunohistochemical studies for cytokeratin are associated with poor outcome in gallbladder carcinomas,¹¹ such studies are few in number and remain unvalidated by larger series. Routine assessment of regional lymph nodes is limited to conventional pathologic techniques (gross assessment and histologic examination), and data are currently insufficient to recommend special measures to detect micrometastasis or isolated tumor cells. Thus, neither multiple levels of paraffin blocks nor the use of special/ancillary techniques, such as immunohistochemistry, are recommended for routine examination of regional lymph nodes.¹⁵ Evaluation of at least 6 lymph nodes has been recommended.^{6,22}

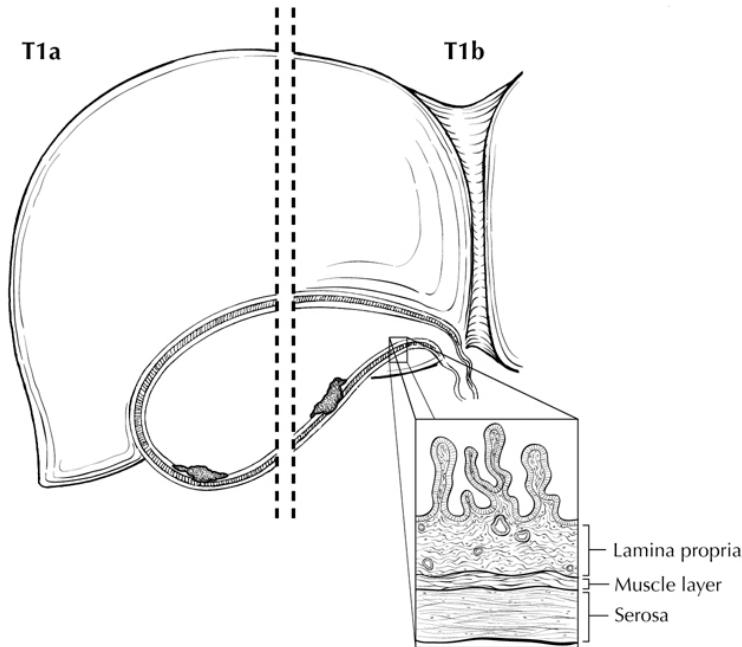


Figure 1. T1a is defined as tumor invading lamina propria; T1b is defined as tumor invading muscle layer. From Greene et al.²⁶ Used with permission of the American Joint Committee on Cancer (AJCC), Chicago, Illinois. The original source for this material is the *AJCC Cancer Staging Atlas* (2006) published by Springer Science and Business Media LLC, www.springerlink.com.

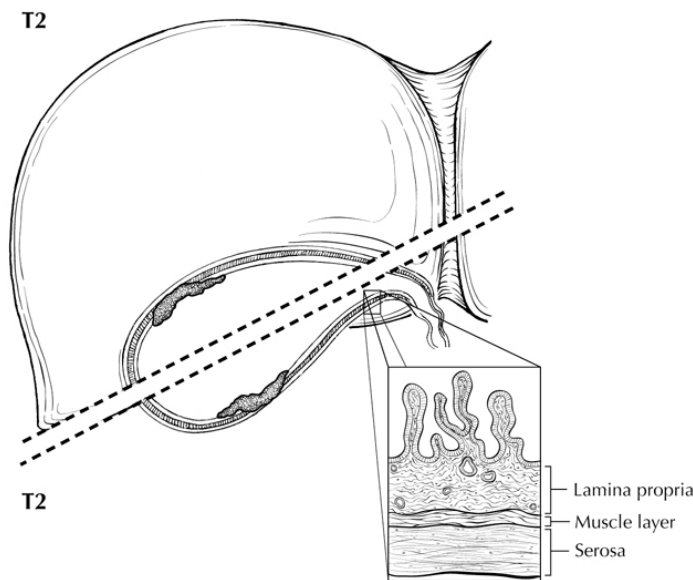


Figure 2. Two views of T2: Tumor invading perimuscular connective tissue (below dotted line) on the peritoneal side without serosal involvement (T2a) and tumor invading the perimuscular connective tissue (above dotted line) on the hepatic side without liver involvement. From Greene et al.²⁶ Used with permission of the American Joint Committee on Cancer (AJCC), Chicago, Illinois. The original source for this material is the *AJCC Cancer Staging Atlas* (2006) published by Springer Science and Business Media LLC, www.springerlink.com.

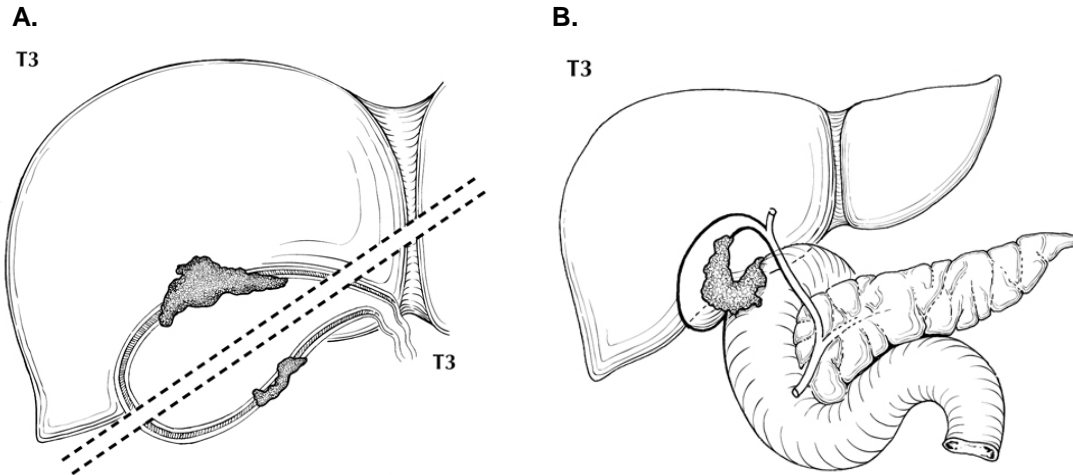


Figure 3. Two views of T3. A. Tumor perforating the serosa (visceral peritoneum) (below dotted line) and/or directly invading the liver (above dotted line). B. T3 may also be defined as tumor invading one other adjacent organ or structure, such as the duodenum (illustrated). From Greene et al.²⁶ Used with permission of the American Joint Committee on Cancer (AJCC), Chicago, Illinois. The original source for this material is the *AJCC Cancer Staging Atlas* (2006) published by Springer Science and Business Media LLC, www.springerlink.com.

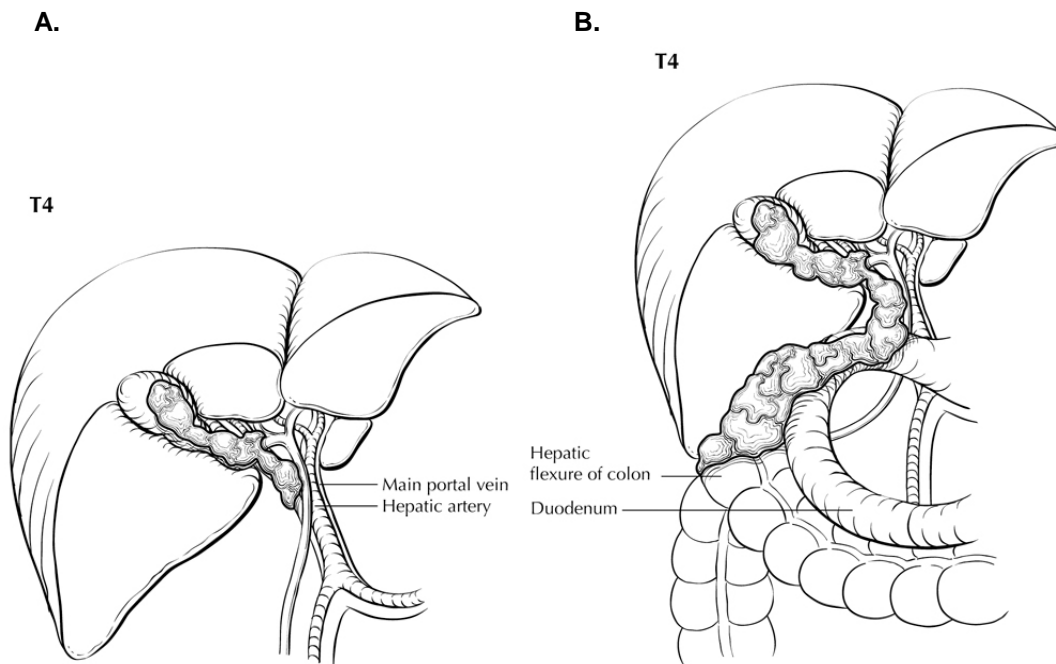


Figure 4. A. T4 is defined as tumor invading the main portal vein or hepatic artery (illustrated) or invading two or more extrahepatic organs or structures. B. T4 invading two or more extrahepatic organs or structures (here, invading colon and duodenum). From Greene et al.²⁶ Used with permission of the American Joint Committee on Cancer (AJCC), Chicago, Illinois. The original source for this material is the *AJCC Cancer Staging Atlas* (2006) published by Springer Science and Business Media LLC, www.springerlink.com.

Stage Groupings

Stage 0	Tis	N0	M0
Stage I	T1	N0	M0
Stage IIA	T2a	N0	M0
Stage IIB	T2b	N0	M0
Stage IIIA	T3	N0	M0
Stage IIIB	T1, T2, or T3	N1	M0

Stage IVA	T4	N0-1	M0
Stage IVB	Any T	N2	M0
	Any T	Any N	M1

Vessel Invasion

According to AJCC/UICC convention, vessel invasion (lymphatic or venous) does not affect the T category indicating local extent of tumor unless specifically included in the definition of a T category.

H. Additional Pathologic Findings

Other common lesions include chronic cholecystitis and various types of metaplasia, such as squamous, pyloric gland, and intestinal metaplasia. Occasionally changes consistent with inflammatory bowel disease are found in the gallbladder. Diffuse calcification of the gallbladder (porcelain gallbladder) has historically been associated with gallbladder carcinoma, although this relationship has been questioned.^{23,24} Recent publications indicate that selective mucosal calcification, rather than diffuse intramural calcification, may be more closely associated with gallbladder cancer.²³

The presence or absence of stones should be reported. Gallbladder cancer occurring in the absence of stones may result from an anomalous choledocho-pancreatic junction or from an association with chronic inflammatory bowel disease. Gallbladders from patients with primary sclerosing cholangitis (PSC) should be carefully examined for dysplasias, reported in 37% of cases, and adenocarcinoma, reported in 14% of cases in a recent study examining gallbladders from patients with PSC undergoing orthotopic liver transplantation.²⁵

I. Clinical History

In addition to longstanding cholelithiasis and chronic cholecystitis, other conditions causing chronic inflammation may predispose to gallbladder carcinoma.

References

1. Giuliante F, Ardito F, Vellone M, Clemente G, Nuzzo G. Port-site excisions for gallbladder cancer incidentally found after laparoscopic cholecystectomy. *Am J Surg.* 2006;191(1):114-116.
2. Adsay V, Saka B, Basturk O, Roa JC. Criteria for pathologic sampling of gallbladder specimens. *Am J Clin Pathol.* 2013;140(2):278-280.
3. Aloia TA, Járufe N, Javle M, et al. Gallbladder cancer: expert consensus statement. HPB (Oxford). 2015;17(8):681-690.
4. Bosman FT, Carneiro F, Hruban RH, Theise ND, eds. *WHO Classification of Tumours of the Digestive System.* Geneva, Switzerland: WHO Press; 2010.
5. Park JS, Yoon DS, Kim KS, et al. Actual recurrence patterns and risk factors influencing recurrence after curative resection with stage II gallbladder carcinoma. *J Gastrointest Surg.* 2007;11(5):631-637.
6. Ito H, Ito K, D'Angelica M, et al. Accurate staging for gallbladder cancer: implications for surgical therapy and pathological assessment. *Ann Surg.* 2011;254(2):320-325.
7. Balachandran P, Agarwal S, Krishnani N, et al. Predictors of long-term survival in patients with gallbladder cancer. *J Gastrointest Surg.* 2006;10(6):848-854.
8. Aramaki M, Matsumoto T, Shibata K, et al. Factors influencing recurrence after surgical treatment for T2 gallbladder carcinoma. *Hepatogastroenterology.* 2004;51(60):1609-1611.
9. Chijiwa K, Yamaguchi K, Tanaka M. Clinicopathologic differences between long-term and short-term postoperative survivors with advanced gallbladder carcinoma. *World J Surg.* 1997;21(1):98-102.
10. Yamaguchi K, Chijiwa K, Saiki S, et al. Retrospective analysis of 70 operations for gallbladder carcinoma. *Br J Surg.* 1997;84(2):200-204.
11. Sasaki E, Nagino M, Ebata T, et al. Immunohistochemically demonstrated lymph node micrometastasis and prognosis in patients with gallbladder carcinoma. *Ann Surg.* 2006;244(1):99-105.
12. Yamaguchi R, Nagino M, Oda K, Kamiya J, Uesaka K, Nimura Y. Perineural invasion has a negative impact on survival of patients with gallbladder carcinoma. *Br J Surg.* 2002;89(9):1130-1136.
13. Yamaguchi K, Chijiwa K, Saiki S, Shimizu S, Takashima M, Tanaka M. Carcinoma of the extrahepatic bile duct: mode of spread and its prognostic implications. *Hepatogastroenterology.* 1997;44(17):1256-1261.
14. Albores-Saavedra J, Henson DE. Adenomyomatous hyperplasia of the gallbladder with perineural invasion. *Arch Pathol Lab Med.* 1995;119:1173-1176.

15. de Aretxabala X, Roa I, Burgos L, et al. Gallbladder cancer: an analysis of a series of 139 patients with invasion restricted to the subserosal layer. *J Gastrointest Surg.* 2006;10(2):186-192.
16. Endo I, Shimada H, Tanabe M, et al. Prognostic significance of the number of positive lymph nodes in gallbladder cancer. *J Gastrointest Surg.* 2006;10(7):999-1007.
17. Amin MB, Edge SB, Greene FL, et al, eds. *AJCC Cancer Staging Manual.* 8th ed. New York, NY: Springer; 2017.
18. Sasaki R, Uesugi N, Itabashi H, et al. Clinicopathological study of depth of subserosal invasion in patients with pT2 gallbladder carcinoma. *J Surg Oncol.* 2005;92(2):83-88.
19. Albores-Saavedra J, Shukla D, Carrick K, Henson DE. In situ and invasive adenocarcinomas of the gallbladder extending into or arising from Rokitansky-Aschoff sinuses: a clinicopathologic study of 49 cases. *Am J Surg Pathol.* 2004;28(5):621-628.
20. Roa JC, Tapia O, Manterola C, et al. Early gallbladder carcinoma has a favorable outcome but Rokitansky-Aschoff sinus involvement is an adverse prognostic factor. *Virchow Arch.* 2013;463(5):651-61.
21. Shindoh J, de Aretxabala X, Aloia TA, et al. Tumor location is a strong predictor of tumor progression and survival in t2 gallbladder cancer: an international multicenter study. *Ann Surg.* 2015;261(4):733-739.
22. Liu GJ, Li XH, Chen YX, Sun HD, Zhao GM, Hu SY. Radical lymph node dissection and assessment: Impact on gallbladder cancer prognosis. *WJG.* 2013;19(31):5150-5158.
23. Stephen AE, Berger DL. Carcinoma in the porcelain gallbladder: a relationship revisited. *Surgery.* 2001;129(6):699-703.
24. Towfigh S, McFadden DW, Cortina GR, et al. Porcelain gallbladder is not associated with gallbladder carcinoma. *Am Surg.* 2001;67(1):7-10.
25. Lewis JT, Talwalkar JA, Rosen CB, Smyrk TC, Abraham SC. Prevalence and risk factors for gallbladder neoplasia in patients with primary sclerosing cholangitis: evidence for a metaplasia-dysplasia-carcinoma sequence. *Am J Surg Pathol.* 2007;31(6):907-913.
26. Greene FL, Compton, CC, Fritz AG, et al, eds. *AJCC Cancer Staging Atlas.* New York: Springer; 2006.