



Protocol for the Examination of Specimens From Patients With Hepatoblastoma

Version: Hepatoblastoma 3.2.0.2

Protocol Posting Date: August 2016

Includes the Children's Oncology Group staging system

This protocol is NOT required for accreditation purposes.

The following should NOT be reported using this protocol:

Tumor Type
Other primary malignant hepatic tumors

Authors

Erin Rudzinski, MD*; Sarangarajan Ranganathan, MD*; John Hicks, MD; Grace Kim, MD

With guidance from the CAP Cancer and CAP Pathology Electronic Reporting Committees.

* Denotes primary author. All other contributing authors are listed alphabetically.

Accreditation Requirements

The use of this protocol is recommended for clinical care purposes, but is not required for accreditation purposes.

CAP Laboratory Accreditation Program Protocol Required Use Date: Not applicable

Important Note

First priority should be given to formalin-fixed tissues for morphologic evaluation. The second priority for tissue processing is snap-freezing up to 1 g (minimum of 100 mg) of tumor from grossly different regions for molecular studies, as well as viable sterile tumor for cytogenetic studies (see Explanatory Note A). Samples from the same foci should be collected for histology, with appropriate identification. Samples of nontumoral liver should be collected for snap-freezing as well.

For more information, contact: The Children's Oncology Group Biopathology Center;
Phone: (614) 722-2890 or (800) 347-2486.

Summary of Changes

v3.2.0.2 - Regional lymph node order modified to report number involved before number examined

Surgical Pathology Cancer Case Summary

Protocol posting date: August 2016

HEPATOBLASTOMA (PEDIATRIC LIVER): Biopsy, Resection

Note: This case summary is recommended for reporting Hepatoblastoma, but is not required for accreditation purposes.

Select a single response unless otherwise indicated.

Procedure (Note A)

Biopsy

- Core biopsy
- Incisional biopsy

Resection

- Right lobectomy
- Extended right lobectomy
- Medial segmentectomy
- Left lateral segmentectomy
- Total left lobectomy
- Explanted liver

- Other (specify): _____
- Not specified

Tumor Site

- Right lobe
- Left lobe
- Right and left lobes
- Other (specify): _____
- Not specified

Tumor Size (specify for each nodule)

- Greatest dimension: ___ cm
- + Additional dimensions: ___ x ___ cm
- Cannot be determined (explain): _____

+ Tumor Focality (within liver)

- + Unifocal
- + Multifocal
- + Cannot be determined (explain): _____

+ Macroscopic Extent of Tumor (select all that apply)

- + Tumor confined to liver
- + Tumor extends into adjacent organ(s) (specify): _____
- + Tumor extends into adjacent soft tissue
 - + Diaphragm
 - + Abdominal wall
 - + Other (specify): _____
- + Intraoperative tumor spill
- + Gross tumor rupture, preoperative
- + Cannot be determined

Preoperative Treatment

- No known preoperative therapy
- Preoperative therapy given
- Not specified

Histologic Type (select all that apply) (Note B)

- Hepatoblastoma, epithelial type, fetal pattern (mitotically inactive)
- Hepatoblastoma, epithelial type, fetal pattern (mitotically active)
- Hepatoblastoma, epithelial type, embryonal
- Hepatoblastoma, epithelial type, pleomorphic (poorly differentiated)
- Hepatoblastoma, epithelial type, macrotrabecular pattern
- Hepatoblastoma, epithelial type, small cell undifferentiated pattern
 - + Percentage of tumor with this histologic feature (if possible): _____%
- Hepatoblastoma, mesenchymal type without teratoid features
- Hepatoblastoma, mesenchymal type with teratoid features
- Hepatoblastoma, other (specify subtypes if not included): _____

Note: Ancillary studies (immunohistochemistry) may be performed to clarify histologic type.

+ Treatment Effect (Note B)

- + No known preoperative therapy (not applicable)
- + Not identified
- + Present
 - + Percent tumor necrosis: _____%
- + Cannot be determined

Margins (applicable to resection specimens only) (select all that apply) (Note C)

Resection Margin

- Cannot be assessed
- Uninvolved by tumor
 - Distance of tumor from closest margin(s): _____ cm
 - Specify margin(s): _____
- Involved by tumor
 - Specify margin(s) _____

Capsular Surface

- Cannot be assessed
- Uninvolved by tumor
 - Distance of tumor from closest surface: _____ cm
- Involved by tumor

+ Lymphovascular Invasion, Macroscopic (select all that apply) (Note D)

- + Not identified
- + Portal vein invasion present
- + Hepatic vein invasion present
- + Cannot be determined

+ Lymphovascular Invasion, Microscopic (Note D)

- + Absent
- + Present
- + Cannot be determined

Regional Lymph Nodes (Note E) No nodes submitted or foundLymph Node Examination (required only if lymph nodes are present in the specimen)

Number of Lymph Nodes Involved

Specify: _____

Specify site(s), if known: _____

+ Histologic type present (specify): _____

 Number cannot be determined (explain): _____

Number of Lymph Nodes Examined

Specify: _____

 Number cannot be determined (explain): _____**Distant Metastases (required only if confirmed pathologically in this case) (Note E)** Present (includes metastasis to lymph nodes in the following locations: inferior phrenic, distal to hilum, hepatoduodenal ligament, or caval region)

+ Specify site(s), if known: _____

+ Histologic type present (specify): _____

+ Staging (Children's Oncology Group) (select all that apply) (Note F)*Note: Staging is based solely on pretreatment tumor characteristics. Clinical information required to definitively assign stage (eg, intraoperative tumor spill or presence of metastatic disease) may not be available to the pathologist. If applicable, the appropriate stage group may be assigned by the pathologist.*+ Stage I+ Stage II+ Microscopic residual tumor present at hepatic resection margin+ Microscopic residual tumor present at extrahepatic resection margin+ Intraoperative tumor spill+ Stage III+ Macroscopic tumor visible at resection margin(s)+ Lymph node metastasis present+ Stage IV+ Complete resection of primary tumor+ Incomplete resection of primary tumor**+ Additional Pathologic Findings (select all that apply) (Note G)**+ No background liver available for evaluation (explain): _____+ None identified+ Cirrhosis/fibrosis+ Iron overload+ Hepatitis (specify type): _____+ Other (specify): _____**Serum Alpha Fetoprotein (α FP) Level (Note H) _____** <100 ng/mL \geq 100 ng/mL Not known**+ Ancillary Studies (select all that apply) (Note I)**+ INI1 immunohistochemistry performed+ INI1 expression retained+ INI1 expression lost+ Glypican 3 immunohistochemistry performed+ Positive

- + Negative
- + Beta-catenin immunohistochemistry performed
 - + Positive (nuclear)
 - + Negative (nuclear)
- + Other (specify): _____

+ Comment(s)

Explanatory Notes

A. Procedures

Fine-Needle Aspiration

Primary diagnosis by cytology (fine-needle aspiration) is not recommended as it may be misleading because of difficulties in distinguishing well-differentiated hepatocellular malignancy from regenerative changes and benign proliferations, and because of the variability of histologic features in hepatoblastoma. Hence, all attempts for fine-needle aspiration should be discouraged in favor of biopsy or resection.

Biopsy

The current recommendation for diagnosis of hepatoblastoma is a biopsy if upfront resection is not an option. This is the recommendation made in a recent consensus classification paper and will be followed in all future Children's Oncology Group (COG) and other international protocols for uniformity.¹ Hepatoblastomas are usually solitary lesions that occupy 1 or the other lobes of the liver, or may transgress more than 1 liver segment (the basis for pretreatment extent of disease [PRETEXT] staging). Multifocal lesions also occur, and multifocal tumors are the most likely cases to be diagnosed by biopsy. However, any tumor that is radiologically PRETEXT I or II or does not fit into stage I or II by the traditional COG staging system may be biopsied upfront, as primary resection may not be an option. Even with lower stage disease, large vessel invasion will be a contraindication to primary resection and will warrant preoperative chemotherapy.

The type of biopsy performed is entirely up to the discretion of the treating physicians and surgeons. Biopsy types include image guided needle biopsy (the more common scenario in the US) or open biopsy for cases that are difficult to access or in which there is potential for surgical resection. While it is much easier to get adequate tissue for studies with open biopsies, a needle biopsy done in interventional radiology is adequate as long as multiple (5-10) needle cores are obtained.¹ It is also recommended that the radiologist obtain needle cores from different portions of the tumor to maximize sampling of all areas of interest in the tumor. Calcified, bony, or hard tissue need not be sampled, however, and focus should be placed on obtaining adequate representation of the viable epithelial component. The region from which the biopsy is obtained should be noted if possible. If tumor involves more than 1 lobe, more than 1 lesion or area of the tumor should be sampled. These sites should be labeled separately, as different nodules in the same patient may have different histologies and biology. As most needle biopsy procedures are ultrasound guided, it may be easy to differentiate between tumor and uninvolved liver, and an attempt should be made to acquire adjacent nontumor liver tissue to understand underlying disease processes.

Upfront biopsy necessitates proper triage of the specimen for all pathologic and biologic studies, as required for COG trials of most pediatric tumors. The goal of the biopsy is tissue diagnosis to separate hepatoblastomas (the most common pediatric tumors) from other benign (especially mesenchymal hamartoma, adenomas, and focal nodular hyperplasia) or malignant (pediatric hepatocellular carcinoma and embryonal sarcoma) liver tumors, therapy for which are different. Regardless of the procedure type, every attempt should be made intraoperatively to assess if tissue obtained is viable and can be triaged for other studies. Imprint cytology may be used to assess tumor viability. No tissue diagnosis is needed at the time of frozen section, for that is the purpose of doing the biopsy, and the surgeon should be so educated. Tissue should instead be set aside for snap freezing (tumor and normal) as well as for cytogenetics (tumor only). While tissue may be set aside for electron microscopy, it is left to individual Institutions to make that decision. For further details, pathologists are referred to the consensus classification of hepatoblastoma published by Lopez-Terrada et al.²

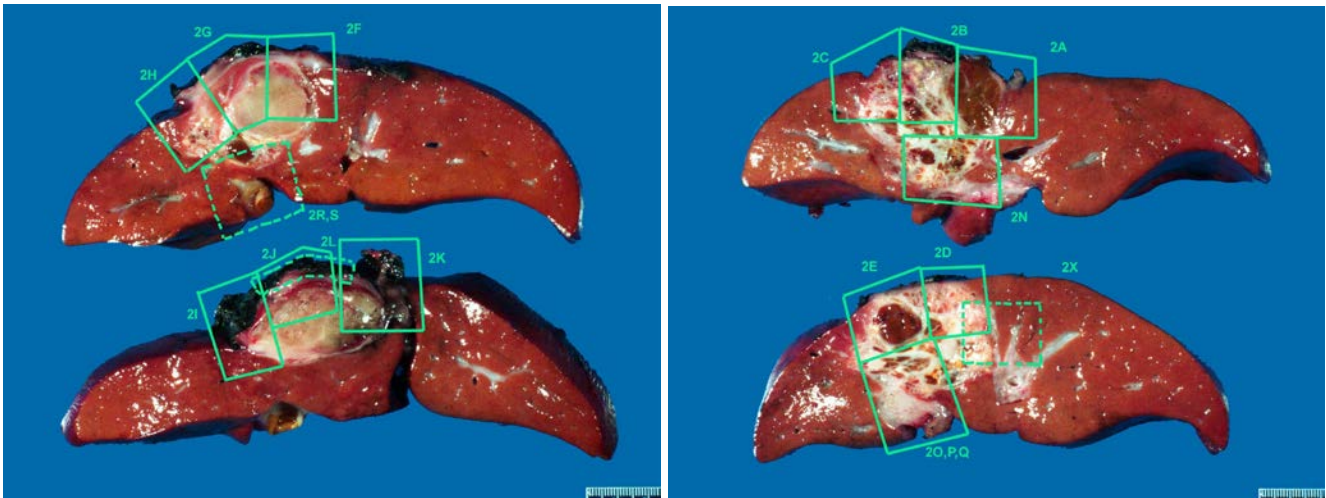
Resection

The various surgical procedures listed include those that attempt primary resection or resection post chemotherapy and the judicious use of transplant where necessary due to overall improved outcome following transplant for nonresectable cases.

Use of intraoperative frozen sections should be avoided unless the operative procedure will be altered by the result. For resection specimens, sections should be prepared from each major tumor nodule, with representative sampling of smaller nodules if macroscopically different in appearance. At least 1 section per centimeter of

greatest diameter should be taken to assure detection of areas with unfavorable (eg, small cell undifferentiated) histopathologic features. Sections from inked margins of resection as well as portal vein or hepatic vein/inferior vena cava involvement should also be submitted if this feature is seen grossly.

A photographic map of the sections taken may help the pathologist target areas of interest, especially in postchemotherapy specimens, where most of the tumor may be necrotic. This map also ensures adequate sampling of margins (lobectomy specimen) and hilar and vena caval margins in explants (see Figure). Every attempt should be made, via photographic map or detailed gross description, to document the site of biopsy or specific regions of tumor sampling, including sections from various nodules, because of the possibility of differential histology in the different tumor nodules. While the overall prognosis is determined by several factors, adequate sampling may identify small cell undifferentiated or pleomorphic epithelial components, which may suggest more therapy-resistant clones of tumor.



The second priority for tissue processing includes snap-freezing up to 1 g (minimum of 100 mg) of tumor from regions of different appearance for future molecular studies in resection specimen; viable sterile tumor should be submitted for cytogenetic studies whenever possible. Samples of nontumoral liver should be collected for snap-freezing as well.

B. Histologic Type

Primary malignant tumors of the liver account for approximately 1% of all childhood cancer. The most common type is hepatoblastoma, which has an annual incidence of 0.9 per 1 million children.¹ Not only are hepatoblastomas rare, but their diversity significantly limits the experience of any single center or pathologist. A classification scheme for hepatoblastoma that divides the more frequently or prognostically influential features from infrequent or inconsequential (minor) components is presented in Table 1.² The significance of a biopsy classification is that it reflects the true components of the tumor and is not limited by chemotherapy effects that alter the morphology of these tumors. It should, however, be noted that not all components may necessarily be sampled in a biopsy, and radiologic features, especially the presence of bone, need to be considered for subtyping.

Table 1. Pediatric Liver Tumors Consensus Classification

Epithelial Tumors - Hepatocellular
Benign and tumor-like conditions
Hepatocellular adenoma (adenomatosis)
Focal nodular hyperplasia
Macroregenerative Nodule
Premalignant lesions
Dysplastic nodules
Malignant
Hepatoblastoma
Epithelial variants
Pure fetal with low mitotic activity
Fetal, mitotically active
Pleomorphic, poorly differentiated
Embryonal
Small-cell undifferentiated
INI1-negative
INI1-positive
Epithelial mixed (any/all above)
Cholangioblastic
Epithelial macrotrabecular pattern
Mixed epithelial and mesenchymal
Without teratoid features
With teratoid features
Hepatocellular carcinoma (HCC)
Classic HCC
Fibrolamellar HCC
Hepatocellular neoplasm, not otherwise specified (NOS)

Modified from Lopez-Terrada et al.²

There is no relationship between the age of the child and the predominant cell type in hepatoblastoma.^{1,3} Of all cases at all ages, 85% to 90% contain both fetal and embryonal derivatives in variable proportions; 20% have stromal derivatives. Because these histologic types tend to be randomly intermingled, both fine-needle aspiration and biopsies may capture a nonrepresentative sample of tumor.

The most significant component to identify in a biopsy of a low-stage tumor is well-differentiated fetal histology characterized by uniform-appearing round to polygonal cells with small central nuclei and clear or pale eosinophilic cytoplasm that may give the tumor a light-cell dark-cell pattern.^{1,2} Nucleoli are usually inconspicuous and the mitotic rate is low (<2 mitoses per 10 high-power fields), the main criteria for this subtype. If the entire biopsy is composed only of this pattern, the possibility of primary resection should be advocated so as to minimize the need for chemotherapy if indeed the resected tumor appears histologically uniform. Again, this is only the case with low stage disease; higher stage diseases are likely to have other histologic components that are unsampled. It is important to realize that diagnosis of pure, well-differentiated fetal histology is to be made only on a completely resected tumor where adequate sampling excludes other areas and chemotherapy does not influence the morphology. The current Children's Oncology Group (COG) study is treating stage I well-differentiated fetal hepatoblastoma (with low mitotic rate) with surgery alone.²⁻⁵

Distinguishing well-differentiated (mitotically inactive) fetal hepatoblastoma tumor cells from normal liver in an infant can be difficult. The fetal tumor cells are larger than normal fetal hepatocytes and have a higher nuclear-to-cytoplasmic ratio. The nuclei are regular and round with little discernible mitotic activity (<2 mitoses per 10 high-power [X40 objective] fields) in the well-differentiated variety.^{2,5} Fetal tumor cells grow in cords, as in normal liver, or in nests or nodules. Clusters of normoblasts (extramedullary hematopoiesis) are seen, as in fetal liver. The cytoplasm of the fetal tumor cells varies from eosinophilic to clear, depending on the amount of glycogen content. Fetal tumor cells may also contain abundant lipid, producing vacuolization. In well-differentiated fetal tumors, bile secretion may be observed.

Histologically, the mitotically active fetal pattern shows ≥ 2 mitoses per 10 high-power fields. Cells are arranged in trabeculae with abundant eosinophilic granular cytoplasm and round centrally placed nuclei with indistinct to occasional conspicuous nucleoli. Extramedullary hematopoiesis is frequently encountered in these areas. The embryonal pattern is composed of cells with high nuclear-to-cytoplasmic ratio with oval to angulated nuclei that are hyperchromatic with prominent single nucleoli and scant cytoplasm. Rosettes and tubular structures may be seen in this component. Purely embryonal tumors are almost never encountered and invariably show some fetal areas.

When tumor cells of either fetal or embryonal type show prominent nucleoli and more atypical morphology resembling hepatocellular carcinoma, the term *pleomorphic epithelial* is used. Most instances of these pleomorphic (also previously called *anaplastic fetal*) epithelial components are seen post resection, but one should be aware of this possibility in a biopsy. Arrangement of cells with fetal or embryonal morphology in areas in a trabecular arrangement where trabeculae are greater than 5 cells thick would warrant a description of macrotrabecular arrangement. This modification of cell thickness for plates was introduced in the new consensus classification, as the original 20-cell-thick plates were unusual and may represent hepatocellular carcinomas in a proportion of cases.

The other significant epithelial component that needs to be looked for is the small cell undifferentiated (SCU) pattern.^{6,7} This is especially true if the entire biopsy or a significant portion of the biopsy shows this morphology. The more common scenario, however, is an epithelial hepatoblastoma with fetal and embryonal areas showing focal aggregates of small cells. These cells have uniform pale nuclei as compared to surrounding darker staining embryonal cells and are arranged in indistinct nests, which can be easily missed on histology. Immunohistochemistry may aid in this diagnosis, and care should be taken to differentiate a predominant SCU pattern from malignant rhabdoid tumor (MRT). Rhabdoid tumor cells have the characteristic, eccentric, pink cytoplasmic inclusions (periodic acid-Schiff/diastase positive, vimentin or cytokeratin positive) with vesicular nuclei and fibrillar inclusion bodies by electron microscopy. They may be associated with the small cell component in otherwise typical hepatoblastomas or as the exclusive cell type, in which case they occur in infancy and are associated with a poor prognosis. The classic rhabdoid tumors show loss of INI1 staining due to *INI1* gene mutation and are treated on the MRT protocol (see Note I).

When first distinguished from embryonal epithelium, small undifferentiated cells in hepatoblastoma were noted to resemble neuroblastoma, to have a low mitotic rate, and were called *anaplastic*, consistent with the dictionary definition, characterized by imperfect development. Because anaplastic was redefined by Faria et al⁸ for Wilms tumor as nuclear enlargement to 3 times that of typical tumor cells, hyperchromasia, and atypical mitoses, the small cell undifferentiated component is no longer designated as anaplastic. Beckwith-type anaplasia does occur rarely in hepatoblastoma, and its significance is unknown. The small cells have been considered putative hepatic progenitor cells on the basis of immunohistochemical and electron microscopic studies. When present in a significant fraction of the hepatoblastoma (75%) or as the sole cell type, the small cell type is typically found in infants younger than 1 year; they have a poor prognosis, with poor response to current therapy. The prognostic significance of smaller proportions of the small cell undifferentiated type is still undetermined.

The majority of tumors will show a mixed pattern of components, either epithelial alone or epithelial admixed with mesenchymal and even teratoid components. Even if mesenchymal components are not visualized histologically in a biopsy, radiologic documentation of bone or calcification may reflect a mixed epithelial-mesenchymal hepatoblastoma and help in the differential from other tumors. In some instances, biopsies may reveal primitive spindled cells at the edges of nodules of hepatoblastoma, mimicking small cells, but outside of nodules. These areas represent primitive mesenchyme, sometimes called “blastema” due to their ability to differentiate into epithelial or mesenchymal elements.

Often, mixed hepatoblastomas contain epithelial membrane antigen (EMA)-positive nests of squamous epithelium. The osteoid component of mixed hepatoblastomas is found to be a matrix of collagen surrounding cells expressing EMA and having ultrastructural features of epithelium, rather than osteoblasts. Hepatoblastomas may contain other stromal derivatives, including cartilage and rhabdomyoblasts. There is no prognostic significance to the presence of mixed histologic features.

Other unusual components that may be seen on a biopsy include the cholangioblastic pattern, neuroepithelium, glandular component (intestinal type), and even squamous elements.^{9,10} Retinal pigment or immature

neuroepithelial rosettes warrant a diagnosis of teratoid hepatoblastoma. These are usually intermingled with more classic morphology of hepatoblastomas. Teratoid hepatoblastoma was initially depicted as having intestinal, neural, and melanocytic elements. These are distinguished from true teratomas, which can also occur in the livers of children, on the basis of organoid differentiation and even greater diversity of tissue elements in the teratomas. Multinucleated tumor giant cells are found in rare hepatoblastomas, sometimes associated with human chorionic gonadotropin (HCG) production and clinical virilization.

Postchemotherapy resection specimens often show eradication of the embryonal cells and more prevalent osteoid-like foci. Heifetz et al¹¹ reported that vascular invasion, amount of mesenchyme, persistence of embryonal epithelium, extent of tumor necrosis, and mitotic activity of the epithelial component have predictive value in this type of specimen. This has yet to be confirmed, but the items should be documented, as should the presence of any small undifferentiated cells, which are known to negatively affect prognosis but may have been missed in the initial biopsies of stage III and IV lesions. Histologic type should therefore be assigned based on the features seen in the current specimen regardless of original diagnosis. With current treatment protocols, postchemotherapy changes may result in complete necrosis, replacement by fibrosis and macrophages, differentiation/maturation of tumor nests to resemble mature hepatocytes within the tumor nodules, and persistence of conventional hepatoblastoma components that can still be recognized, as in a biopsy. There is usually a prominent biliary proliferation separating the treated tumor nodule from adjacent uninvolved liver.¹² These proliferating ducts need to be distinguished from cholangioblastic areas of hepatoblastoma (usually done with a beta-catenin stain, which shows nuclear staining of tumor versus reactive ducts).¹³ The histologic classification of postchemotherapy resection specimens should reflect, where possible, the degree of chemotherapy response, though the significance of this finding is still unknown.

C. Margins

The evaluation of margins for total or partial hepatectomy specimens depends on the method and extent of resection. It is recommended that the surgeon be consulted to determine the critical foci within the margins that require microscopic evaluation. The transection margin of a partial hepatectomy may be large, rendering it impractical for complete examination. In this setting, grossly positive margins should be microscopically confirmed and documented. If the margins are grossly free of tumor, judicious sampling of the cut surface in the region closest to the nearest identified tumor nodule is indicated. In selected cases, adequate random sampling of the cut surface may be sufficient. If the neoplasm is found near the surgical margin, the distance from the margin should be reported. For multiple tumors, the distance from the margin to the nearest tumor should be reported.

D. Vascular Invasion

In both the biopsy and resection specimen, assessment of microscopic lymphovascular invasion should be restricted to the parenchyma outside of the tumor nodules. Documentation should include gross vascular invasion versus intravascular growth found only microscopically, and whether it is within the tumor mass or outside of it. Evidence of vascular invasion usually has been associated with a worse outcome, and COG study AHEP0731 is the first study to evaluate the significance prospectively. It is generally believed that vascular invasion is more common with embryonal tumors and tumors with more aggressive phenotypes, and may warrant adjuvant therapy to prevent disease spread or recurrence. Large vessel involvement is known to be associated with worse outcome, but microscopic vascular invasion may carry the same significance. Presence or absence of large vessel invasion radiologically is assessed as part of PRETEXT staging of tumors and may preclude the possibility of primary resection of the tumor.

E. Lymph Nodes and Distant Metastases

Histologic examination of a regional lymphadenectomy specimen usually involves examination of 3 or more lymph nodes. The regional lymph nodes of the hepatic region include the hilar, hepatoduodenal ligament, and caval lymph nodes, which are likely to be sampled only at the time of surgical resection or transplant. Nodal involvement of the inferior phrenic lymph nodes or other lymph nodes distal to the hilar, hepatoduodenal ligament, and caval lymph nodes is considered distant metastasis. Presence of distant metastasis is a general contraindication to primary surgery, especially transplantation, and is an indication for biopsy. While the primary tumor is biopsied in most instances, rare cases of biopsy of metastasis may become necessary. The histologic classification will, however, remain the same, though metastatic sites are more likely to show more aggressive histologic patterns, either embryonal, SCU, macrotrabecular, or pleomorphic patterns. An occasional metastases resected postchemotherapy may show effects of therapy.

F. Staging of Hepatoblastoma

Staging in the United States combines imaging with surgical judgment about resectability.^{3,4} Computed tomography and magnetic resonance imaging are used exclusively in the SIOPEL (Société Internationale D'Oncologie Pédiatrique Liver Tumor Study Group) protocol^{3,14} to determine the location and extent of hepatic involvement of hepatoblastoma preoperatively (PRETEXT) based on Couinaud's system of segmentation of the liver. PRETEXT is based on cross-sectional imaging assessment of the extent of tumor involvement of the 4 main sections of the liver: right posterior section (Couinaud 6, 7); right anterior section (Couinaud 5, 8); left medial section (Couinaud 4a, 4b); left lateral section (Couinaud 2, 3). PRETEXT assignment to 1 of 4 PRETEXT groups (PRETEXT I, II, III, or IV) is determined by the number of contiguous uninvolved sections of the liver. Tumors sparing the left medial and right anterior sectors are primarily resected.

PRETEXT is further annotated with a V, P, E, M, or C, depending upon extension of tumor beyond the hepatic parenchyma of the major sections. Caudate involvement is annotated as 'C'. Tumor extension outside the liver to a contiguous intraabdominal organ (eg, stomach and diaphragm) is annotated as 'E'. Distant metastatic disease (usually lungs) is annotated as 'M'. Major vascular involvement is annotated as 'V' (all 3 hepatic veins or the vena cava) or 'P' (portal bifurcation or the main portal vein). This system is now being adopted by all International Liver Tumor Study groups.

Dissemination of hepatic malignancies occurs within portal veins and follows the expected ready access of infiltration into hepatic veins, with frequent lung involvement. Further spread to the brain may occur. Hilar lymph node metastases are relatively infrequent, but capsular rupture of subcapsular masses either before or during surgery can upstage an otherwise resectable malignancy. Performance of a biopsy prior to chemotherapy does not upstage the tumor. In this setting, COG staging should be applied based on radiographic features at the time of presentation (if available).

The Children's Oncology Group staging system is recommended for hepatoblastomas³ (staging is performed at diagnosis, prior to any form of therapy).

Stage I tumors are completely resected, margins grossly and microscopically negative for tumor.

Stage II tumors are grossly resected with evidence of microscopic residual tumor. Such tumors are rare, and patients with this stage have not fared differently from those with stage I tumors in previous protocols. Resected tumors with preoperative (intraoperative) rupture are classified as stage II.

Stage III (unresectable) tumors are those that are considered by the attending surgeon not to be resectable without undue risk to the patient. These include partially resected tumors with measurable tumor left behind. They do not include grossly resected tumors with microscopic disease at the margins or resected tumors with preoperative/intraoperative rupture. Lymph node involvement is considered stage III disease and may require evaluation with second laparotomy after an initial 4 courses of chemotherapy.

Stage IV tumors are those that present with measurable metastatic disease to the lungs or other organ.[#]

[#] Nodal involvement of the inferior phrenic lymph nodes or other lymph nodes distal to the hilar, hepatoduodenal ligament, or caval lymph nodes are considered distant metastases.

Resectability is the key prognostic feature for all liver malignancies, with the possible exception of rhabdomyosarcoma (see separate College of American Pathologists protocol for rhabdomyosarcoma¹⁵). Unfortunately, 67% of hepatoblastomas were not amenable to primary surgery (48% stage III and 19% stage IV) in the 16 years of Pediatric Oncology Group/Children's Oncology Group accessions.²

G. Associated Clinical, Environmental, and Genetic FactorsClinical Features and Differential Diagnosis

The presenting symptom of virtually all liver tumors in children is abdominal swelling secondary to hepatomegaly. When confronted with this symptom, it is useful to consider the age at which liver tumors tend to occur (see Table 2).⁵ Exceptions are frequent, but age can serve as a guide when the presenting symptoms lack specificity. In the

Pediatric Oncology Group series from 1986 to 2002,¹⁶⁻¹⁸ 66% of hepatoblastomas were manifest by the second year, and 11% before 6 months of age. Approximately 50% of those in infants were congenital, given their size when discovered by 2 to 3 months of age; 6% of hepatoblastomas occurred after 5 years of age. Hepatocellular carcinomas have been observed as early as 6 months of age. Seven examples of mixed hepatoblastomas and hepatocellular carcinomas have been observed at a mean age of 8.5 years; perinatally acquired hepatitis B virus was responsible in 3 instances. Yolk sac tumors are more common in early childhood, but they also occur rarely in older adults. Systemic malignancies and metastatic disease must be considered at all ages because hepatomegaly due to megakaryoblastic leukemia, Langerhans cell histiocytosis, and neuroblastoma are important sources of confusion with hepatoblastoma in infancy, as are intraabdominal desmoplastic small round cell tumors later in childhood.¹⁶

Age	Benign	Malignant
Infancy (0-1 y)	Hemangioendothelioma Mesenchymal hamartoma Teratoma	Hepatoblastoma, especially small cell undifferentiated Rhabdoid tumor Yolk sac tumor Langerhans cell histiocytosis Megakaryoblastic leukemia Disseminated neuroblastoma
Early childhood (1-3 y)	Hemangioendothelioma Mesenchymal hamartoma	Hepatoblastoma Rhabdomyosarcoma Inflammatory myofibroblastic (pseudo) tumor
Later childhood (3-10 y)	Perivascular epithelioid cell tumors (PE-Comas), including angiomyolipoma in liver and clear cell tumor of ligamentum teres / falciform ligament	Hepatocellular carcinoma Embryonal (undifferentiated) sarcoma Angiosarcoma Cholangiocarcinoma Endocrine (gastrin) carcinoma
Adolescence (10-16 y)	Adenoma Focal nodular hyperplasia Biliary cystadenoma	Fibrolamellar hepatocellular carcinoma Hodgkin lymphoma Leiomyosarcoma

Environmental Factors

Hepatoblastoma occurs in association with several well-described environmental factors and cancer genetic syndromes (see Table 3); however, not all of these associations are necessarily of statistical significance. Environmental factors and prenatal exposure to different agents have been implicated in hepatoblastoma.¹⁹⁻²¹

An increased incidence of hepatoblastoma—from 0.4 to 1.0 per million between 1971 and 1983—has been observed at a Children’s Tumour Registry in Manchester, United Kingdom.¹⁶ Data from the US National Cancer Institute Surveillance, Epidemiology, and End Result (SEER) program revealed an average annual increase of 5.2% in the incidence of hepatoblastoma from 1973 to 1992.¹⁷ This change might be explained by hepatoblastoma occurring in surviving premature infants. Hepatoblastomas in Japan accounted for 58% of all malignancies in children who weighed less than 1000 g at birth.¹⁹ Further analysis of the Japanese Children’s Cancer Registry data revealed that 15 of 303 (5%) hepatoblastomas between 1985 to 1995 occurred in infants with a history of prematurity and weight less than 1500 g at birth.²⁰ This rate was greater than 10 times that for all live births. The histologic features of hepatoblastoma after prematurity are indistinguishable from those of other hepatoblastomas.

The Children’s Cancer Group has evaluated environmental or drug exposure. Seventy-five sets of parents of children with hepatoblastoma were compared with the parents of age-matched controls. In the group of children with hepatoblastoma, there was a significant excess of maternal exposure, before and during pregnancy, to metals used in welding and soldering, lubricating oils, and protective greases.²² Paternal exposure to metals was

also greater. At 23 weeks, a congenital hepatoblastoma was found in a stillborn fetus whose mother was an artist exposed to volatile hydrocarbons.²³

Table 3. Clinical Syndromes, Congenital Malformations, and Other Conditions Associated With Hepatoblastoma

<p>Congenital Malformations</p> <ul style="list-style-type: none"> Absence of left adrenal gland Bilateral talipes Duplicated ureters Dysplasia of ear lobes Cleft palate Fetal hydrops Hemihypertrophy Heterotopic lung tissue Horseshoe kidney Inguinal hernia Intrathoracic kidney Macroglossia Meckel diverticulum Persistent ductus arteriosus Renal dysplasia Right-sided diaphragmatic hernia Single coronary artery Umbilical hernia
<p>Syndromes</p> <ul style="list-style-type: none"> Beckwith-Wiedemann syndrome Beckwith-Wiedemann syndrome with opsoclonus, myoclonus Budd-Chiari syndrome Familial adenomatous polyposis syndrome Li-Fraumeni cancer syndrome Polyposis coli families Schinzell-Geidion syndrome Simpson-Golabi-Behmel syndrome Trisomy 18
<p>Metabolic / Pathophysiologic Abnormalities</p> <ul style="list-style-type: none"> Cystathioninuria Glycogen storage disease types Ia, III, and IV Hypoglycemia Heterozygous α1-antitrypsin deficiency Isosexual precocity Prematurity Total parenteral nutrition Very low birth weight

Table 3. Clinical Syndromes, Congenital Malformations, and Other Conditions Associated With Hepatoblastoma**Environmental / Other**

Alcohol embryopathy
 Human immunodeficiency virus or hepatitis B virus infection
 Maternal clomiphene citrate or Pergonal
 Oral contraceptive, mother
 Oral contraceptive, patient
 Osteoporosis
 Synchronous Wilms tumor

Genetic Factors

Karyotyping of hepatoblastomas has revealed a recurrent pattern of chromosomal abnormalities.^{23,24} The most common karyotypic changes are extra copies of entire chromosomes (trisomies), sometimes in conjunction with other complex structural changes and often in association with double-minute chromosomes. Trisomies of chromosomes 2 and 20 have each been reported most commonly,^{16,25} and each of these trisomies has been reported as a sole karyotypic event, suggesting that they may represent an early stage of tumor evolution. Trisomy of chromosome 20 and duplication of the long arm of chromosome 20 have also been observed in rhabdomyosarcoma, suggesting a link between these 2 embryonal tumors, both of which are also associated with losses at the Beckwith-Wiedemann syndrome locus.²⁶ Trisomy of chromosome 8 is also common; other trisomies are seen with lesser frequency. Occasional losses of entire chromosomes are seen, and these, too, are not random. The clinical significance of trisomies is unknown at present, although a recent study using comparative genomic hybridization has suggested that chromosomal gains at chromosomes 8 and 20 may be associated with an adverse prognosis.²⁷ A unique translocation has been reported in undifferentiated small cell hepatoblastoma,²⁸ a variant associated with a poor prognosis, although this cytogenetic variant has not been reported in other cases.

Numerous recent studies have documented molecular genetic abnormalities in hepatoblastomas (see Table 4) and other hepatic tumors. Several genetic changes are shared with other embryonal tumors, such as loss of heterozygosity at chromosome 11p15, also described in rhabdomyosarcomas and Wilms tumors. Acquired mutations of the *APC* gene and the *beta-catenin* gene, both members of the Wnt signaling pathway, have also been reported in hepatoblastoma.²³⁻³² The high frequency of *beta-catenin* mutations in hepatoblastomas and the increased incidence of hepatoblastomas in familial adenomatous polyposis families suggest the important role of an overactivation of wingless/Wnt pathway in the pathogenesis of hepatoblastoma. Collection of fresh or frozen hepatoblastoma tumor material as well as nontumoral liver tissue from these patients will be of great importance to the further investigation of the clinical relevance of these and other molecular genetic abnormalities in predicting the prognosis and clinical behavior of these tumors.

Disease	Tumor Type	Chromosomal Locus	Gene
Familial adenomatous polyposis	Hepatoblastoma, hepatocellular carcinoma or adenoma, biliary adenoma	5q21.22	<i>APC</i>
Beckwith-Wiedemann syndrome	Hepatoblastoma, hemangioendothelioma	11p15.5	<i>p57KIP2</i> , others
Li-Fraumeni syndrome	Hepatoblastoma, undifferentiated sarcoma	17p13	<i>TP53</i>
Trisomy 18	Hepatoblastoma	18	—
Glycogen storage disease types Ia, III, IV	Hepatocellular adenoma or carcinoma, hepatoblastoma	17	Glucose-6-phosphatase; debrancher and brancher enzymes

H. Tumor Markers

Serum α -fetoprotein (α FP) is the most useful indicator of hepatocellular neoplasia. Levels of serum α FP are markedly elevated in 80% to 90% of hepatoblastomas and in 60% to 70% of hepatocellular carcinomas.^{1,3} Lesser degrees of elevation in infants can be due to variations in the rate of decline after birth or to secretion from regenerating hepatocytes adjacent to hemangioendotheliomas or mesenchymal hamartomas. Therefore, it is unacceptable practice to institute chemotherapy for mass lesions of the liver based solely on imaging studies and serum α FP levels. α FP also can be elevated in yolk sac tumors, which may occur as primary tumors in the liver or together with hepatoblastoma. On the contrary, α FP levels will not be increased when hepatoblastomas are primarily composed of the small cell undifferentiated type or in most fibrolamellar carcinomas, but even some typical fetal hepatoblastomas have failed to produce detectable increases in serum α FP levels. Low α FP levels below 100 ng/dL are therefore considered to be a poor prognostic indication based on a large retrospective review of Children's Hepatic tumor International Collaboration (CHIC) database.^{2-4, 33} Following the α FP level in patients with unresectable hepatoblastoma after chemotherapy had prognostic value in a retrospective analysis of 31 patients in a Children's Cancer Group series from 1986 to 1989.³⁴

There are many other proposed blood assays for the detection of hepatic malignancies. Other than α FP and HCG, none are used widely thus far because of relatively low specificity and predictive value. Occasionally, hypercholesterolemia is found in patients with hepatoblastoma, especially in infants with fetal histology, and all those with high levels died.^{35,36} Precocious puberty secondary to HCG or testosterone secretion has been observed in 6% of males with hepatoblastoma. Thrombocytosis has been present in 25% to 65% of patients with hepatoblastoma.³⁷

I. Ancillary Studies

Immunohistochemistry may help differentiate hepatoblastoma from normal liver or other hepatocellular tumors, or aid in accurate diagnosis of the various hepatoblastoma subtypes. Staining with glypican 3 has a distinctive pattern with a fine pericanalicular staining seen in cells of the well-differentiated fetal hepatoblastoma, while the mitotically active fetal subtype and embryonal areas show similar patterns of coarse granular cytoplasmic staining. Small cell undifferentiated, cholangioblastic, and mesenchymal components are negative for glypican 3. Most teratoid components are also negative, except for an occasional glandular/yolk sac-like component that may show positive staining.

Beta-catenin staining is more variable. Rare pediatric hepatocellular carcinomas can show strong positive staining, as can nested epithelial-stromal tumors. The tumor currently considered under the rubric of hepatocellular neoplasms, NOS in the consensus classification also show nuclear beta-catenin staining despite morphologic overlap with features of hepatocellular carcinomas. At present, there is no immunostain to differentiate hepatocellular carcinoma from hepatoblastoma with confidence, though in general most pediatric hepatocellular carcinomas do not show the same intense nuclear staining as hepatoblastomas. Beta-catenin staining is usually associated with strong glutamine synthetase and cyclin D1 staining in hepatoblastomas. Possible genetic markers (trisomies for chromosomes 2, 20, and 8; abnormalities of chromosome 1p) are being investigated and may help differentiate these 2 entities, but only approximately 35% to 40% of hepatoblastomas carry the abnormalities.²

Immunohistochemistry with glypican-3, beta-catenin, and glutamine synthetase (GS) aids in distinguishing hepatoblastoma from normal liver. Normal fetal liver is negative for glypican and shows only pericentral hepatocyte staining while staining diffusely in the tumor cells. Nuclear beta-catenin is only seen in tumor. Immunohistochemistry may be useful for identifying the small cell component of hepatoblastoma, as well. The small cells usually stain strongly and uniformly with beta-catenin in a nuclear pattern and are negative for glypican 3. This is in contrast to embryonal and fetal cells, which are cytoplasmic glypican 3 positive in most instances and show variable nuclear beta-catenin. The SCU component may also stain for vimentin and cytokeratin.

Evaluation of the SCU component with an INI1 stain is critical, particularly if the SCU component forms a significant portion of the biopsy. Any loss of INI1 in the SCU component may warrant reclassification on review as a malignant rhabdoid tumor with a different Children's Oncology Group treatment protocol. While this loss of INI1 is unusual in the usual SCU components that form small foci in between other epithelial components, it is prudent to do the stain and report the findings. Interestingly, stain for INI1 may be stronger in the nuclei of SCU component than surrounding cells; the significance of this is still to be determined.

It is also important to realize that fetal pattern hepatoblastoma may resemble the fetal hepatocytes trapped in benign liver tumors, such as mesenchymal hamartoma (MH) and infantile hemangioma (IH), and this needs to be recognized in a biopsy. Use of immunohistochemistry may be helpful in some instances but usually needs more than 1 stain for confirmation. The fetal liver trapped in an MH or IH may show fine glypican 3 staining but will usually lack beta-catenin nuclear staining. Also, the lesional cells of IH will stain with CD31 and Glut1, while MH may show epithelial lined cysts or myxoid matrix with a prominent biliary component. The biliary elements in hepatoblastoma (Cholangioblastic pattern) usually show nuclear beta-catenin staining.

References

1. Finegold MJ. Hepatic Tumors in Childhood. In: Russo P RE, Piccoli D, eds. *Pathology of Pediatric Gastrointestinal and Liver Disease*. New York, NY: Springer-Verlag; 2004:300-346.
2. Lopez-Terrada D, Alaggio R, de Davila MT, et al. Towards an international pediatric liver tumor consensus classification: proceedings of the Los Angeles COG liver tumors symposium. *Mod Pathol*. 2014;27(3):472-491.
3. Czauderna P, Lopez-Terrada D, Hiyama E, Häberle B, Malogolowkin MH, Meyers RL. Hepatoblastoma state of the art: pathology, genetics, risk stratification, and chemotherapy. *Curr Opin Pediatr*. 2014;26(1):19-28.
4. Meyers RL, Tiao G, de Ville de Goyet J, Superina R, Aronson DC. Hepatoblastoma state of the art: pre-treatment extent of disease, surgical resection guidelines and the role of liver transplantation. *Curr Opin Pediatr*. 2014;26(1):29-36.
5. Malogolowkin MH, Katzenstein HM, Meyers RL, et al. Complete surgical resection is curative for children with hepatoblastoma with pure fetal histology: a report from the Children's Oncology Group. *J Clin Oncol*. 2011;29(24):3301-3306.
6. Trobaugh-Lotrario AD, Tomlinson GE, Finegold MJ, Gore L, Feusner JH. Small cell undifferentiated variant of hepatoblastoma: adverse clinical and molecular features similar to rhabdoid tumors. *Pediatr Blood Cancer*. 2009;52(3):328-334.
7. Haas JE, Feusner JH, Finegold MJ. Small cell undifferentiated histology in hepatoblastoma may be unfavorable. *Cancer*. 2001;92(12):3130-3134.
8. Faria P, Beckwith JB, Mishra K, et al. Focal versus diffuse anaplasia in Wilms tumor--new definitions with prognostic significance: a report from the National Wilms Tumor Study Group. *Am J Surg Pathol*. 1996;20(8):909-920. Review.

9. Zimmermann A. Hepatoblastoma with cholangioblastic features ('cholangioblastic hepatoblastoma') and other liver tumors with bimodal differentiation in young patients. *Med Pediatr Oncol.* 2002;39(5):487-491. Review.
10. Zhou S, Ranganathan S, Venkatramani R, Gomulia E, Wang L. Teratoid hepatoblastoma with abundant cholangioblastic component in a child with full trisomy 13. *Pediatr Dev Pathol.* 2013;16(6):438-441.
11. Heifetz SA, French M, Correa M, Grosfeld JL. Hepatoblastoma: the Indiana experience with preoperative chemotherapy for inoperable tumors; clinicopathological considerations. *Pediatr Pathol Lab Med.* 1997;17(6):857-874.
12. Wang LL, Filippi RZ, Zurakowski D, et al. Effects of neoadjuvant chemotherapy on hepatoblastoma: a morphologic and immunohistochemical study. *Am J Surg Pathol.* 2010;34(3):287-299.
13. Ranganathan S, Tan X, Monga SP. Beta-catenin and met deregulation in childhood hepatoblastomas. *Pediatr Dev Pathol.* 2005;8(4):435-447.
14. Aronson DC, Schnater JM, Staalman CR, et al. Predictive value of the pretreatment extent of disease system in hepatoblastoma: results from the International Society of Pediatric Oncology Liver Tumor Study Group SIOPEL-1 study. *J Clin Oncol.* 2005;23(6):1245-1252.
15. Rudzinski ER, Bahrami A, Parham DM, Sebire N. Protocol for the Examination of Specimens from Pediatric Patients with Rhabdomyosarcoma.
<http://www.cap.org/ShowProperty?nodePath=/UCMCon/Contribution%20Folders/WebContent/pdf/rhabdomyosarcoma-11protocol.pdf>. Published 2015. Accessed December 9, 2015.
16. Mann JR, Kasthuri N, Raafat F, et al. Malignant hepatic tumours in children: incidence, clinical features and aetiology. *Paediatr Perinat Epidemiol.* 1990;4(3):276-289.
17. Ross JA, Gurney JG. Hepatoblastoma incidence in the United States from 1973 to 1992. *Med Pediatr Oncol.* 1998;30(3):141-142.
18. Ortega JA, Douglass EC, Feusner JH, et al. Randomized comparison of cisplatin/vincristine/fluorouracil and cisplatin/continuous infusion doxorubicin for treatment of pediatric hepatoblastoma: a report from the Children's Cancer Group and the Pediatric Oncology Group. *J Clin Oncol.* 2000;18(14):2665-2675.
19. Ikeda H, Matsuyama S, Tanimura M. Association between hepatoblastoma and very low birth weight: a trend or a chance? *J Pediatr.* 1997;130(4):557-560.
20. Ikeda H, Hachitanda Y, Tanimura M, Maruyama K, Koizumi T, Tsuchida Y. Development of unfavorable hepatoblastoma in children of very low birth weight: results of a surgical and pathologic review. *Cancer.* 1998;82(9):1789-1796.
21. Spector LG, Birch J. The epidemiology of hepatoblastoma. *Pediatr Blood Cancer.* 2012;59(5):776-779.
22. Buckley JD, Sather H, Ruccione K, et al. A case-control study of risk factors for hepatoblastoma: a report from the Children's Cancer Study Group. *Cancer.* 1989;64:1169-1176.
23. Robinson HB Jr, Bolande RP. Case 3: fetal hepatoblastoma with placental metastases. *Pediatr Pathol.* 1985;4:163-167.
24. Fletcher JA, Kozakewich HP, Pavelka K, et al. Consistent cytogenetic aberrations in hepatoblastoma: a common pathway of genetic alterations in embryonal liver and skeletal muscle malignancies? *Genes Chromosomes Cancer.* 1991;3(1):37-43.
25. Tomlinson GE, Finegold MJ. Tumors of the liver. In: Pizzo PA, Poplack DG, eds. *Principles and Practice of Pediatric Oncology.* 4th ed. Philadelphia, PA: Lippincott, Williams & Wilkins; 2002:847-865.
26. Steenman M, Tomlinson G, Westerveld A, Mannens M. Comparative genomic hybridization analysis of hepatoblastomas: additional evidence for a genetic link with Wilms tumor and rhabdomyosarcoma. *Cytogenet Cell Genet.* 1999;86:157-161.
27. Weber RG, Pietsch T, von Schweinitz D, Lichter P. Characterization of genomic alterations in hepatoblastomas: a role for gains on chromosomes 8q and 20 as predictors of poor outcome. *Am J Pathol.* 2000;157:571-578.
28. Hansen K, Bagtas J, Mark HF, Homans A, Singer DB. Undifferentiated small cell hepatoblastoma with a unique chromosomal translocation: a case report. *Pediatr Pathol.* 1992;12:457-462.
29. Trobaugh-Lotrario AD, Venkatramani R, Feusner JH. Hepatoblastoma in children with Beckwith-Wiedemann syndrome: does it warrant different treatment? *J Pediatr Hematol Oncol.* 2014;36(5):369-373.
30. Jeng YM, Wu MZ, Mao TL, Chang MH, Hsu HC. Somatic mutations of beta-catenin play a crucial role in the tumorigenesis of sporadic hepatoblastoma. *Cancer Lett.* 2000;152(1):45-51.
31. Koch A, Denkhau D, Albrecht S, Leuschner I, von Schweinitz D, Pietsch T. Childhood hepatoblastomas frequently carry a mutated degradation targeting box of the beta-catenin gene. *Cancer Res.* 1999;59(2):269-273.

32. Cairo S, Armengol C, De Reyniès A, et al. Hepatic stem-like phenotype and interplay of Wnt/beta-catenin and Myc signaling in aggressive childhood liver cancer. *Cancer Cell*. 2008;14(6):471-484.
33. Meyers RL, Rowland JR, Krailo M, Chen Z, Katzenstein HM, Malogolowkin MH. Predictive power of pretreatment prognostic factors in children with hepatoblastoma: a report from the Children's Oncology Group. *Pediatr Blood Cancer*. 2009;53(6):1016-1022.
34. Ortega JA, Krailo MD, Haas JE et al. Effective treatment of unresectable or metastatic hepatoblastoma with cisplatin and continuous infusion doxorubicin chemotherapy: a report from the Children's Cancer Study Group. *J Clin Oncol*. 1991;9:2167-2176.
35. Hanawa Y, Ise T, Hasegawa H, et al. Serum cholesterol in children with hepatoma. *Jpn J Clin Oncol*. 1971;12:129-136.
36. Muraji T, Woolley MM, Sinatra F, Siegel SM, Isaacs H. The prognostic implication of hypercholesterolemia in infants and children with hepatoblastoma. *J Pediatr Surg*. Jun 1985;20(3):228-230.
37. Patterson K. Liver tumors and tumor like masses. In: Parham DM, ed. *Pediatric Neoplasia, Morphology & Biology*. Philadelphia, PA: Lippincott-Raven; 1996:331-361.