

Protocol for the Examination of Specimens From Patients With Neuroendocrine Tumors (Carcinoid Tumors) of the Jejunum and Ileum

Version: Jejunum/IleumNET 1.0.0.0

Protocol Posting Date: June 2017

Includes pTNM requirements from the 8th Edition, AJCC Staging Manual

For accreditation purposes, this protocol should be used for the following procedures AND tumor types:

Procedure	Description
Resection	Includes specimens designated segmental resection – small intestine and ileocelectomy
Tumor Type	Description
Well-differentiated tumor of the jejunum and ileum	

This protocol is NOT required for accreditation purposes for the following:

Procedure
Biopsy
Primary resection specimen with no residual cancer (eg, following neoadjuvant therapy)
Recurrent tumor
Cytologic specimens

The following tumor types should NOT be reported using this protocol:

Tumor Type
Well-differentiated tumor of the duodenum and ampulla (consider the Duodenum and Ampulla Carcinoma protocol)
Poorly differentiated neuroendocrine carcinoma including small cell and large cell neuroendocrine carcinoma (consider the Small Intestine protocol)
Other epithelial tumors including mixed adenoneuroendocrine carcinoma (consider the Small Intestine protocol)
Lymphoma (consider the Hodgkin or non-Hodgkin Lymphoma protocols)
Gastrointestinal stromal tumor (GIST) (consider the GIST protocol)
Non-GIST sarcoma (consider the Soft Tissue protocol)

Authors

Chanjuan Shi, MD, PhD*; Volkan Adsay, MD; Emily K. Bergsland, MD; Jordan Berlin, MD; Philip A. Branton, MD; Patrick L. Fitzgibbons, MD; Wendy L. Frankel, MD; Sanjay Kakar, MD; Veronica Klepeis, MD, PhD; David S. Klimstra, MD; Joseph T. Lewis, MD; Laura H. Tang, MD; Eugene Woltering, MD; Mary K. Washington, MD, PhD

With guidance from the CAP Cancer and CAP Pathology Electronic Reporting Committees.

* Denotes primary author. All other contributing authors are listed alphabetically.

Accreditation Requirements

This protocol can be utilized for a variety of procedures and tumor types for clinical care purposes. For accreditation purposes, only the definitive primary cancer resection specimen is required to have the core and conditional data elements reported in a synoptic format.

- Core data elements are required in reports to adequately describe appropriate malignancies. For accreditation purposes, essential data elements must be reported in all instances, even if the response is “not applicable” or “cannot be determined.”
- Conditional data elements are only required to be reported if applicable as delineated in the protocol. For instance, the total number of lymph nodes examined must be reported, but only if nodes are present in the specimen.
- Optional data elements are identified with “+” and although not required for CAP accreditation purposes, may be considered for reporting as determined by local practice standards.

The use of this protocol is not required for recurrent tumors or for metastatic tumors that are resected at a different time than the primary tumor. Use of this protocol is also not required for pathology reviews performed at a second institution (ie, secondary consultation, second opinion, or review of outside case at second institution).

Synoptic Reporting

All core and conditionally required data elements outlined on the surgical case summary from this cancer protocol must be displayed in synoptic report format. Synoptic format is defined as:

- Data element: followed by its answer (response), outline format without the paired "Data element: Response" format is NOT considered synoptic.
- The data element must be represented in the report as it is listed in the case summary. The response for any data element may be modified from those listed in the case summary, including “Cannot be determined” if appropriate.
- Each diagnostic parameter pair (Data element: Response) is listed on a separate line or in a tabular format to achieve visual separation. The following exceptions are allowed to be listed on one line:
 - Anatomic site or specimen, laterality, and procedure
 - Pathologic Stage Classification (pTNM) elements
 - Negative margins, as long as all negative margins are specifically enumerated where applicable
- The synoptic portion of the report can appear in the diagnosis section of the pathology report, at the end of the report or in a separate section, but all Data element: Responses must be listed together in one location

Organizations and pathologists may choose to list the required elements in any order, use additional methods in order to enhance or achieve visual separation, or add optional items within the synoptic report. The report may have required elements in a summary format elsewhere in the report IN ADDITION TO but not as replacement for the synoptic report i.e. all required elements must be in the synoptic portion of the report in the format defined above.

CAP Laboratory Accreditation Program Protocol Required Use Date: March 2018*

* Beginning January 1, 2018, the 8th edition AJCC Staging Manual should be used for reporting pTNM.

CAP Jejunum/Ileum NET Protocol Summary of Changes

This is a new protocol. The Small Intestine NET protocol was divided into 2 separate new protocols: Duodenum/Ampulla NET and Jejunum/Ileum NET protocols.

Surgical Pathology Cancer Case Summary

Protocol posting date: June 2017

JEJUNUM AND ILEUM NEUROENDOCRINE TUMOR**Select a single response unless otherwise indicated.****Procedure**

- Segmental resection, small intestine
 Ileocolic resection
 Other (specify): _____
 Not specified

Tumor Site (Notes A and B)

- Jejunum
 Ileum
 Small intestine, not otherwise specified
 Other (specify): _____

Tumor Size (Note C)

- Greatest dimension (centimeters): ___ cm (specify size of largest tumor if multiple tumors are present)
 + Additional dimensions (centimeters): ___ x ___ cm
 Cannot be determined (explain): _____

Tumor Focality

- Unifocal
 Multifocal (specify number of tumors): _____
 Cannot be determined

Histologic Type and Grade (Notes D and E)[#]

- G1: Well-differentiated neuroendocrine tumor
 G2: Well-differentiated neuroendocrine tumor
 G3: Well-differentiated neuroendocrine tumor
 Other (specify): _____
 GX: Well-differentiated neuroendocrine tumor, grade cannot be assessed
 Not applicable

Note: For poorly differentiated (high-grade) neuroendocrine carcinomas arising in the jejunum or ileum, the College of American Pathologists (CAP) protocol for carcinoma of the small intestine should be used.¹

Mitotic rate and/or Ki-67 labeling index is required to determine histologic grade

Mitotic Rate (Note E)[#]

- <2 mitoses/2 mm²
 2-20 mitoses/2 mm²
 + Specify mitoses per 2 mm²: _____
 >20 mitoses per 2 mm²
 + Specify mitoses per 2 mm²: _____
 Cannot be determined (explain): _____
 Not applicable

[#] Mitotic rate should be reported as number of mitoses per 2 mm², by evaluating at least 10 mm² in the most mitotically active part of the tumor (eg, if using a microscope with a field diameter of 0.55 mm, count 42 high-power fields [10 mm²] and divide the resulting number of mitoses by 5 to determine the number of mitoses per 2 mm² needed to assign tumor grade).

+ Data elements preceded by this symbol are not required for accreditation purposes. These optional elements may be clinically important but are not yet validated or regularly used in patient management.

Ki-67 Labeling Index (Note E)

- <3%
 3% to 20%
 + Specify Ki-67 percentage: ____%
 >20%
 + Specify Ki-67 percentage: ____%
 Cannot be determined (explain): _____
 Not applicable

Tumor Extension

- No evidence of primary tumor
 Tumor invades the lamina propria
 Tumor invades the submucosa
 Tumor invades the muscularis propria
 Tumor invades through the muscularis propria into subserosal tissue without penetration of overlying serosa
 Tumor invades visceral peritoneum (serosa)
 Tumor invades other organs or adjacent structures (specify): _____
 Cannot be assessed

Margins

Note: Use this section only if all margins are uninvolved and all margins can be assessed.

- All margins are uninvolved by tumor
 Margins examined: _____
 Note: Margins may include proximal, distal, radial or mesenteric, and others.
 + Distance of tumor from closest margin (millimeters or centimeters): ____ mm or ____ cm
 + Specify closest margin: _____

Individual margin reporting required if any margins are involved or margin involvement cannot be assessed

Proximal Margin

- Cannot be assessed
 Uninvolved by tumor
 Involved by tumor

Distal Margin

- Cannot be assessed
 Uninvolved by tumor
 Involved by tumor

Radial or Mesenteric Margin (Note F)

- Cannot be assessed
 Uninvolved by tumor
 Involved by tumor

Other Margin(s) (required only if applicable)

- Specify margin(s): _____
 Cannot be assessed
 Uninvolved by tumor
 Involved by tumor

Lymphovascular Invasion

- Not identified
 Present
 Cannot be determined

+ Perineural Invasion

- + ___ Not identified
 + ___ Present
 + ___ Cannot be determined

Large Mesenteric Masses (>2 cm) (Note G)

- ___ Not identified
 ___ Present
 + Specify number: _____
 ___ Cannot be determined

Regional Lymph Nodes

___ No lymph nodes submitted or found

Lymph Node Examination (required only if lymph nodes are present in the specimen)

Number of Lymph Nodes Involved: _____
 ___ Number cannot be determined (explain): _____

Number of Lymph Nodes Examined: _____
 ___ Number cannot be determined (explain): _____

Pathologic Stage Classification (pTNM, AJCC 8th Edition) (Note G)

Note: Reporting of pT, pN, and (when applicable) pM categories is based on information available to the pathologist at the time the report is issued. Only the applicable T, N, or M category is required for reporting; their definitions need not be included in the report. The categories (with modifiers when applicable) can be listed on 1 line or more than 1 line.

TNM Descriptors (required only if applicable) (select all that apply)

- ___ m (multiple primary tumors)
 ___ r (recurrent)
 ___ y (posttreatment)

Primary Tumor (pT)

- ___ pTX: Primary tumor cannot be assessed
 ___ pT0: No evidence of primary tumor
 ___ pT1[#]: Invades the lamina propria or submucosa and less than or equal to 1 cm in size
 ___ pT2[#]: Invades the muscularis propria or greater than 1 cm in size
 ___ pT3[#]: Invades through the muscularis propria into subserosal tissue without penetration of overlying serosa
 ___ pT4[#]: Invades visceral peritoneum (serosal) or other organs or adjacent structures

[#] *Note:* For any T, add (m) for multiple tumors [TX(#) or TX(m), where X = 1–4, and # = number of primary tumors identified^{##}]; for multiple tumors with different T, use the highest.

^{##} *Example:* If there are 2 primary tumors, only 1 of which invades through the muscularis propria into subserosal tissue without penetration of overlying serosa (jejunal or ileal), we define the primary tumor as either T3(2) or T3(m).

Regional Lymph Nodes (pN)

- ___ pNX: Regional lymph nodes cannot be assessed
 ___ pN0: No regional lymph node metastasis has occurred
 ___ pN1: Regional lymph node metastasis less than 12 nodes
 ___ pN2: Large mesenteric masses (>2 cm) and/or extensive nodal deposits (12 or greater), especially those that encase the superior mesenteric vessels

Distant Metastasis (pM) (required only if confirmed pathologically in this case)

pM1: Distant metastasis

pM1a: Metastasis confined to liver

pM1b: Metastasis in at least one extrahepatic site (eg, lung, ovary, nonregional lymph node, peritoneum, bone)

Specify site(s), if known: _____

pM1c: Both hepatic and extrahepatic metastases

Specify site(s), if known: _____

+ Additional Pathologic Findings (select all that apply) (Note H)

+ None identified

+ Tumor necrosis

+ Mesenteric tumor deposit(s) ≤ 2 cm

+ Mesenteric vascular elastosis

+ Other (specify): _____

+ Comment(s)

Explanatory Notes

A. Application and Tumor Location

This protocol applies to well-differentiated neuroendocrine tumors (carcinoid tumors) of the jejunum and ileum. Poorly differentiated neuroendocrine carcinomas (small cell carcinomas and large cell neuroendocrine carcinomas) and tumors with mixed glandular/neuroendocrine differentiation are not included.¹ Neuroendocrine tumors of the duodenum and ampulla of Vater use a separate CAP cancer protocol.²

Because of site-specific similarities in histology, immunohistochemistry, and histochemistry, neuroendocrine tumors of the digestive tract have traditionally been subdivided into those of foregut, midgut, and hindgut origin (Table 1). In general, the distribution pattern along the gastrointestinal (GI) tract parallels that of the progenitor cell type, and the anatomic site of origin of GI neuroendocrine tumors is an important predictor of clinical behavior.³

Table 1. Site of Origin of Gastrointestinal Neuroendocrine Tumors

	Foregut Tumors	Midgut Tumors	Hindgut Tumors
<i>Site</i>	<i>Stomach, Proximal Duodenum</i>	<i>Jejunum, Ileum, Appendix, Proximal Colon</i>	<i>Distal Colon, Rectum</i>
Immunohistochemistry Chromogranin A Synaptophysin Serotonin	86%-100% + 50% + 33% + ¹⁹	82%-92% + 95%-100% + 86% + ¹⁷	40%-58% + 94%-100% + 45%-83% + ^{4,5,19}
Other Immunohistochemical Markers	Rarely, + for pancreatic polypeptide, histamine, gastrin, vasoactive intestinal peptide (VIP), or adrenocorticotrophic hormone (ACTH)	Prostatic acid phosphatase + in 20%-40% ¹⁹	Prostatic acid phosphatase + in 20%-82% ^{4,5,19}
Carcinoid Syndrome	Rare	5%-39% ⁶	Rare

B. Site-Specific Features

The small intestine is the most common primary site for neuroendocrine tumors.⁴⁻⁶ Most small intestine neuroendocrine tumors occur in the distal ileum. Multiple tumors are found in 25% to 40% of cases and may be associated with a worse outcome.⁷ Primary jejunal and ileal tumors are often small and asymptomatic. However, extensive fibrosis can form when they invade deep soft tissue (eg, mesenteric soft tissue), causing small bowel obstruction and small bowel ischemia due to encasement of the superior mesenteric vessels. In addition, about 50% of patients with jejunoileal neuroendocrine tumor have liver metastasis as the initial presentation, and patients with liver metastasis can have carcinoid syndrome (eg, flushing, diarrhea, and wheezing). Metastatic risk is increased by tumor size >2 cm, involvement of the muscularis propria, and mitotic activity.³

C. Tumor Size

For neuroendocrine tumors in any part of the gastrointestinal tract, size greater than 2.0 cm is associated with a higher risk of lymph node metastasis. For jejunoileal tumors, nodal metastases occur in about 12% of patients with tumors smaller than 1.0 cm and in most patients with tumors larger than 1.0 cm.³ Thus, treatment for small intestine neuroendocrine tumor includes complete resection with regional lymphadenectomy.

D. Histologic Type

The World Health Organization (WHO) classifies neuroendocrine neoplasms as well-differentiated neuroendocrine tumors (either the primary tumor or metastasis) and poorly differentiated neuroendocrine carcinomas.⁸ Historically, well-differentiated neuroendocrine tumors have been referred to as “carcinoid tumors,” a term which may cause confusion because clinically a carcinoid tumor is a serotonin-producing tumor associated with functional manifestations of carcinoid syndrome. The use of the term “carcinoid” for neuroendocrine tumor reporting is therefore discouraged for these reasons.

Classification of neuroendocrine tumors is based upon size, functionality, site, and invasion. Functioning tumors are those associated with clinical manifestations of hormone production or secretion of measurable amounts of active hormone; immunohistochemical demonstration of hormone production is not equivalent to clinically apparent functionality.

Immunohistochemistry and other ancillary techniques are generally not required to diagnose well-differentiated neuroendocrine tumors. Specific markers that may be used to establish neuroendocrine differentiation include chromogranin A, synaptophysin, and CD56.⁶ Because of their relative sensitivity and specificity, chromogranin A and synaptophysin are recommended.

E. Histologic Grade

Cytologic atypia in well-differentiated neuroendocrine tumors has no impact on clinical behavior of these tumors. The WHO classification⁸ and others⁹ use mitotic rate and/or Ki-67 index as one of the criteria for potential for aggressive behavior. Mitotic rate should be reported as number of mitoses per 2 mm², by evaluating at least 10 mm² in the most mitotically active part of the tumor. Only clearly identifiable mitotic figures should be counted; hyperchromatic, karyorrhectic, or apoptotic nuclei are excluded. Because of variations in field size, the number of high-power field (HPF) (at 40X magnification) for 10 mm² (thereby 2 mm²) must be determined for each microscope (Table 2). For example, if using a microscope with a field diameter of 0.55 mm, count 42 HPF and divide the resulting number of mitoses by 5 to determine the number of mitoses per 2 mm² needed to assign tumor grade.

Table 2. Number of HPF Required for 10 mm² Using Microscopes With Different Field Diameter

Field Diameter (mm)	Area (mm ²)	Number of HPF for 10 mm ²
0.40	0.125	80
0.41	0.132	75
0.42	0.139	70
0.43	0.145	69
0.44	0.152	65
0.45	0.159	63
0.46	0.166	60
0.47	0.173	58
0.48	0.181	55
0.49	0.189	53
0.50	0.196	50
0.51	0.204	49
0.52	0.212	47
0.53	0.221	45
0.54	0.229	44
0.55	0.238	42
0.56	0.246	41
0.57	0.255	39
0.58	0.264	38
0.59	0.273	37
0.60	0.283	35

0.61	0.292	34
0.62	0.302	33
0.63	0.312	32
0.64	0.322	31
0.65	0.332	30
0.66	0.342	29
0.67	0.353	28
0.68	0.363	28
0.69	0.374	28

Ki-67 index is reported as percent positive tumor cells in area of highest nuclear labeling (“hot spot”), although the precise method of assessment has not been standardized. A number of methods have used to assess Ki-67 index, including automatic counting and “eyeballing.”^{10,11} Automated counting is not widely available and requires careful modification of the software to circumvent the inaccuracies.¹⁰ Eye-balling can be used for most tumors; however, for tumors with Ki-67 index close to grade cut-offs, it is recommended to perform the manual count on the print of camera-captured image of the hot spot. It has been recommended that a minimum of 500 tumor cells be counted to determine the Ki-67 index, and a notation is made if less cells are available. Grade assigned based on Ki-67 index is typically higher than that based on mitotic count, and the case is assigned to the higher of the 2 if both methods are performed.⁸

It is important to note that there are a small group of well-differentiated neuroendocrine tumors with a Ki-67 index >20% and a mitotic rate usually <20 per 10 HPF. In WHO-2010, these tumors were considered as G3 poorly differentiated neuroendocrine carcinomas. However, they have typical morphology of well-differentiated tumors. Previous studies (most on pancreatic neuroendocrine tumors) have demonstrated that these tumors have a worse prognosis than grade 2 (Ki-67=3-20% and mitosis <20/10 HPF) neuroendocrine tumors, but they are not as aggressive as poorly differentiated neuroendocrine carcinomas.¹² In addition, these tumors do not have the genetic abnormalities seen in poorly differentiated neuroendocrine carcinomas.¹³ Furthermore, unlike poorly differentiated neuroendocrine carcinomas, they are less responsive to platinum-based chemotherapy.¹⁴ In the WHO-2017 blue book of endocrine tumors and AJCC 8th edition, those with typical morphology of well-differentiated tumors are classified as “well differentiated neuroendocrine tumor” but as grade 3. Here, the updated classification for “endocrine” tumors is adapted, and following grading scheme is recommended to grade well-differentiated gastroenteropancreatic neuroendocrine tumors (Table 3).

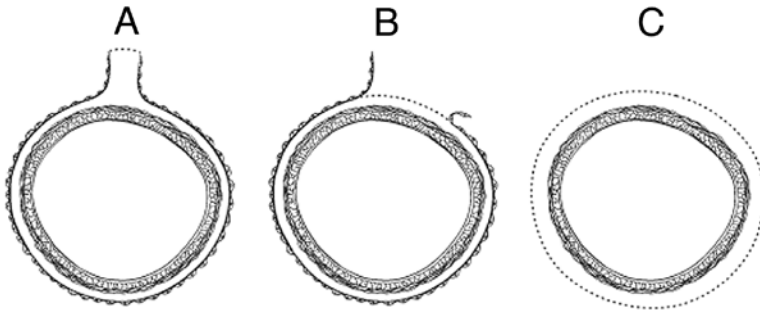
Table 3. Recommended Grading System for Well-Differentiated Gastroenteropancreatic Neuroendocrine Tumors

Grade	Mitotic Rate (per 10 HPF)	Ki-67 Index (%)
Well-differentiated neuroendocrine tumor, G1	<2	<3
Well-differentiated neuroendocrine tumor, G2	2 to 20	3 to 20
Well-differentiated neuroendocrine tumor, G3	>20	>20

F. Circumferential (Radial or Mesenteric) Margin

In addition to addressing the proximal and distal margins, assessment of the circumferential (radial) margin is necessary for any segment of gastrointestinal tract either unencased (Figure, C) or incompletely encased by peritoneum (Figure, B). The circumferential margin represents the adventitial soft tissue margin closest to the deepest penetration of tumor and is created surgically by blunt or sharp dissection of the retroperitoneal or subperitoneal aspect, respectively. The distance between the tumor and circumferential (radial) margin should be reported, if applicable. The circumferential (radial) margin is considered positive if the tumor is present at the inked nonperitonealized surface. This assessment includes tumor within a lymph node as well as direct tumor extension, but if circumferential (radial) margin positivity is based solely on intranodal tumor, this should be so stated.

The mesenteric resection margin is the only relevant circumferential margin in segments completely encased by peritoneum (eg, jejunum and ileum) (Figure, A). Involvement of this margin should be reported even if tumor does not penetrate the serosal surface.



A, Mesenteric margin in viscus completely encased by peritoneum (dotted line). B, Circumferential (radial) margin (dotted line) in viscus incompletely encased by peritoneum. C, Circumferential (radial) margin (dotted line) in viscus completely unencased by peritoneum.

G. Pathologic Stage Classification

The TNM staging system for neuroendocrine tumors of the jejunum and ileum of the American Joint Committee on Cancer (AJCC) and the International Union Against Cancer (UICC) is recommended.¹⁵

By AJCC/UICC convention, the designation “T” refers to a primary tumor that has not been previously treated. The symbol “p” refers to the pathologic classification of the TNM, as opposed to the clinical classification, and is based on gross and microscopic examination. pT entails a resection of the primary tumor or biopsy adequate to evaluate the highest pT category, pN entails removal of nodes adequate to validate lymph node metastasis, and pM implies microscopic examination of distant lesions. Clinical classification (cTNM) is usually carried out by the referring physician before treatment during initial evaluation of the patient or when pathologic classification is not possible.

Pathologic staging is usually performed after surgical resection of the primary tumor. Pathologic staging depends on pathologic documentation of the anatomic extent of disease, whether or not the primary tumor has been completely removed. If a biopsied tumor is not resected for any reason (eg, when technically unfeasible) and if the highest T and N categories or the M1 category of the tumor can be confirmed microscopically, the criteria for pathologic classification and staging have been satisfied without total removal of the primary cancer.

TNM Descriptors

For identification of special cases of TNM or pTNM classifications, the “m” suffix and “y,” “r,” and “a” prefixes are used. Although they do not affect the stage grouping, they indicate cases needing separate analysis.

The “m” suffix indicates the presence of multiple primary tumors in a single site and is recorded in parentheses: pT(m)NM.

The “y” prefix indicates those cases in which classification is performed during or following initial multimodality therapy (ie, neoadjuvant chemotherapy, radiation therapy, or both chemotherapy and radiation therapy). The cTNM or pTNM category is identified by a “y” prefix. The ycTNM or ypTNM categorizes the extent of tumor actually present at the time of that examination. The “y” categorization is not an estimate of tumor prior to multimodality therapy (ie, before initiation of neoadjuvant therapy).

The “r” prefix indicates a recurrent tumor when staged after a documented disease-free interval, and is identified by the “r” prefix: rTNM.

The “a” prefix designates the stage determined at autopsy: aTNM.

N Category Considerations

For ileal and jejunal tumors, the regional lymph nodes are the cecal (for tumors arising in the terminal ileum), superior mesenteric, and mesenteric nodes. Metastases to celiac nodes are considered distant metastases.

Mesenteric masses are defined as discrete but irregular mesenteric tumor nodules frequently located adjacent to neurovascular bundles and discontinuous from the primary neoplasm.¹⁶ Mesenteric masses are often associated with dense fibrosis, causing encasement of large mesenteric vessels. The presence of mesenteric masses has also been associated with frequent liver metastasis and a poor prognosis.^{16,17}

M Category Considerations

The liver is the most common metastatic site. Metastases to extrahepatic sites, such as lung, ovary, peritoneum, and bone, are rare. Involvement of the celiac, para-aortic, and other nonregional lymph nodes is also considered M1 disease. In the AJCC 8th edition, M is subcategorized into M1a (hepatic only), M1b (extrahepatic only), and M1c (both hepatic and extrahepatic).

TNM Anatomic Stage/Prognostic Groupings

Stage I	T1	N0	M0 [#]
Stage II	T2,T3	N0	M0
Stage III	T4	N0	M0
	Any T	N1,N2	M0
Stage IV	Any T	Any N	M1

[#] M0 is defined as no distant metastasis.

H. Additional Pathologic Findings

Mesenteric vascular changes (elastic vascular sclerosis) associated with midgut carcinoids may produce arterial luminal narrowing due to concentric accumulation of elastic tissue in the adventitia. These vascular changes may lead to intestinal ischemia and frank necrosis.¹⁸

References

1. Shi C, Belin J, Branton P, et al. Protocol for the Examination of Specimens From Patients With Carcinoma of the Small Intestine. 2017. Available at www.cap.org/cancerportocols.
2. Shi C, Adsay V, Bergsland EK, et al. Protocol for the Examination of Specimens From Patients With Neuroendocrine Tumors (Carcinoid Tumors) of the Duodenum and Ampulla. 2017. Available at www.cap.org/cancerportocols.
3. Rorstad O. Prognostic indicators for carcinoid neuroendocrine tumors of the gastrointestinal tract. *J Surg Oncol*. 2005;89(3):151-160.
4. Modlin IM, Lye KD, Kidd M. A 5-decade analysis of 13,715 carcinoid tumors. *Cancer*. 2003;97(4):934-959.
5. Graeme-Cook F. Neuroendocrine tumors of the GI tract and appendix. In: Odze RD, Goldblum JR, Crawford JM, eds. *Surgical Pathology of the GI Tract, Liver, Biliary Tract, and Pancreas*. Philadelphia, PA: Saunders; 2004: 483-504.
6. Williams GT. Endocrine tumours of the gastrointestinal tract: selected topics. *Histopathology*. 2007;50(1):30-41.
7. Yantiss RK, Odze RD, Farraye FA, Rosenberg AE. Solitary versus multiple carcinoid tumors of the ileum: a clinical and pathologic review of 69 cases. *Am J Surg Pathol*. 2003;27(6):811-817.
8. Bosman FT, Carneiro F, Hruban RH, Theise ND, eds. *WHO Classification of Tumours of the Digestive System*. Geneva, Switzerland: WHO Press; 2010.
9. Rindi G, Kloppel G, Alhman H, et al; and all other Frascati Consensus Conference participants; European Neuroendocrine Tumor Society (ENETS). TNM staging of foregut (neuro)endocrine tumors: a consensus proposal including a grading system. *Virchows Arch*. 2006;449(4):395-401.
10. Tang LH, Gonen M, Hedvat C, Modlin I, Klimstra DS. Objective quantification of the Ki-67 proliferative index in neuroendocrine tumors of gastroenteropancreatic system: a comparison of digital image analysis with manual methods. *Am J Surg Pathol*. 2012;36(12):1761-1770.
11. Reid MD, Bagci P, Ohike N, et al. Calculation of the Ki67 index in pancreatic neuroendocrine tumors: a comparative analysis of four counting methodologies. *Mod Pathol*. 2016;29(1):93.
12. Shi C, Klimstra DS. Pancreatic neuroendocrine tumors: pathologic and molecular characteristics. *Semin Diagn Pathol*. 2014;31(6):498-511.

13. Yachida S, Vakiani E, White CM, et al. Small cell and large cell neuroendocrine carcinomas of the pancreas are genetically similar and distinct from well-differentiated pancreatic neuroendocrine tumors. *Am J Surg Pathol*. 2012;36(2):173-184.
14. Sorbye H, Strosberg J, Baudin E, Klimstra DS, Yao JC. Gastroenteropancreatic high-grade neuroendocrine carcinoma. *Cancer*. 2014;120(18):2814-2823.
15. Amin MB, Edge SB, Greene FL, et al, eds. *AJCC Cancer Staging Manual*. 8th ed. New York, NY: Springer; 2017.
16. Gonzalez RS, Liu EH, Alvarez JR, Ayers GD, Washington MK, Shi C. Should mesenteric tumor deposits be included in staging of well-differentiated small intestine neuroendocrine tumors? *Mod Pathol*. 2014;27(9):1288-1295.
17. Fata CR, Gonzalez RS, Liu E, et al. Mesenteric tumor deposits in midgut small intestinal neuroendocrine tumors are a stronger indicator than lymph node metastasis for liver metastasis and poor prognosis. *Am J Surg Pathol*. 2017;41(1):128-133.
18. Eckhauser FE, Argenta LC, Strodel WE, et al. Mesenteric angiopathy, intestinal gangrene, and midgut carcinoids. *Surgery*. 1981;90(4):720-728.
19. Nash SV, Said JW. Gastroenteropancreatic neuroendocrine tumors: a histochemical and immunohistochemical study of epithelial (keratin proteins, carcinoembryonic antigen) and neuroendocrine (neuron-specific enolase, bombesin and chromogranin) markers in foregut, midgut, and hindgut tumors. *Am J Clin Pathol*. 1986;86(2):415-422.