



Protocol for the Examination of Specimens From Patients With Primary Non-Small Cell Carcinoma, Small Cell Carcinoma, or Carcinoid Tumor of the Lung

Version: Lung 4.0.0.2

Protocol Posting Date: June 2017

Includes pTNM requirements from the 8th Edition, AJCC Staging Manual

For accreditation purposes, this protocol should be used for the following procedures AND tumor types:

Procedure	Description
Resection	Includes pneumonectomy, lobectomy, segmentectomy, and wedge resection
Tumor Type	Description
Carcinoma	Includes non-small cell carcinoma, small cell carcinoma, or carcinoid tumor of the lung

This protocol is NOT required for accreditation purposes for the following:

Procedure
Biopsy
Primary resection specimen with no residual cancer (e.g. following neoadjuvant therapy)
Cytologic specimens

The following tumor types should NOT be reported using this protocol:

Tumor Type
Mesothelioma (consider the Pleural Mesothelioma protocol)
Lymphoma (consider the Hodgkin or non-Hodgkin Lymphoma protocol)
Sarcoma (consider the Soft Tissue protocol)

Authors

Kelly J. Butnor, MD*; Mary Beth Beasley, MD*; Sanja Dacic, MD, PhD*; Michael Berman, MD; Douglas Flieder, MD; Kirk Jones, MD; Nader T. Okby, MD; Victor L. Roggli, MD; Saul Suster, MD; Henry D. Tazelaar, MD; William D. Travis, MD

With guidance from the CAP Cancer and CAP Pathology Electronic Reporting Committees.

* Denotes primary authors. All other contributing authors are listed alphabetically.

Accreditation Requirements

This protocol can be utilized for a variety of procedures and tumor types for clinical care purposes. For accreditation purposes, only the definitive primary cancer resection specimen is required to have the core and conditional data elements reported in a synoptic format.

- Core data elements are required in reports to adequately describe appropriate malignancies. For accreditation purposes, essential data elements must be reported in all instances, even if the response is “not applicable” or “cannot be determined.”
- Conditional data elements are only required to be reported if applicable as delineated in the protocol. For instance, the total number of lymph nodes examined must be reported, but only if nodes are present in the specimen.
- Optional data elements are identified with “+” and although not required for CAP accreditation purposes, may be considered for reporting as determined by local practice standards.

The use of this protocol is not required for recurrent tumors or for metastatic tumors that are resected at a different time than the primary tumor. Use of this protocol is also not required for pathology reviews performed at a second institution (ie, secondary consultation, second opinion, or review of outside case at second institution).

Synoptic Reporting

All core and conditionally required data elements outlined on the surgical case summary from this cancer protocol must be displayed in synoptic report format. Synoptic format is defined as:

- Data element: followed by its answer (response), outline format without the paired "Data element: Response" format is NOT considered synoptic.
- The data element should be represented in the report as it is listed in the case summary. The response for any data element may be modified from those listed in the case summary, including “Cannot be determined” if appropriate.
- Each diagnostic parameter pair (Data element: Response) is listed on a separate line or in a tabular format to achieve visual separation. The following exceptions are allowed to be listed on one line:
 - Anatomic site or specimen, laterality, and procedure
 - Pathologic Stage Classification (pTNM) elements
 - Negative margins, as long as all negative margins are specifically enumerated where applicable
- The synoptic portion of the report can appear in the diagnosis section of the pathology report, at the end of the report or in a separate section, but all Data element: Responses must be listed together in one location

Organizations and pathologists may choose to list the required elements in any order, use additional methods in order to enhance or achieve visual separation, or add optional items within the synoptic report. The report may have required elements in a summary format elsewhere in the report IN ADDITION TO but not as replacement for the synoptic report i.e. all required elements must be in the synoptic portion of the report in the format defined above.

CAP Laboratory Accreditation Program Protocol Required Use Date: March 2018*

* Beginning January 1, 2018, the 8th edition AJCC Staging Manual should be used for reporting pTNM.

CAP Lung Protocol Summary of Changes

Version 4.0.0.2

Added response to Histologic Type

Version 4.0.0.1

Histologic Type

ADDED (Select all that apply)

Version 4.0.0.0:

The following data elements were modified:

Pathologic Stage Classification (pTNM, AJCC 8th Edition)

Tumor Size

Tumor Focality

Histologic Type

Tumor Extension

Margins

Treatment Effect

The following data elements have been added:

Total Tumor Size

Invasive Tumor Size

Spread Through Air Spaces (STAS)

The following data element was removed:

Tumor Associated Atelectasis or Obstructive Pneumonitis

Surgical Pathology Cancer Case Summary

Protocol posting date: June 2017

LUNG:**Select a single response unless otherwise indicated.****Procedure (select all that apply)**

- Wedge resection
 Segmentectomy
 Lobectomy
 Completion lobectomy
 Sleeve lobectomy
 Bilobectomy
 Pneumonectomy
 Major airway resection (specify): _____
 Other (specify): _____
 Not specified

Specimen Laterality

- Right
 Left
 Not specified

Tumor Site (select all that apply)

- Upper lobe
 Middle lobe
 Lower lobe
 Bronchus, main
 Bronchus intermedius
 Bronchus, lobar (specify): _____
 Other (specify): _____
 Not specified

Tumor Size (applies to histologic types other than invasive nonmucinous adenocarcinoma with a lepidic component) (Note A)

- Greatest dimension (centimeters): ___ cm
 + Additional dimensions (centimeters): ___ x ___ cm
 Cannot be determined

Total Tumor Size Inclusive of Invasive and Lepidic Components (applies only to invasive nonmucinous adenocarcinoma with a lepidic component) (Note A)

- Greatest dimension (centimeters): ___ cm
 + Additional dimensions (centimeters): ___ x ___ cm
 Cannot be determined

Invasive Tumor Size (applies only to invasive nonmucinous adenocarcinoma with a lepidic component) (Note A)

- Greatest dimension (centimeters): ___ cm
 + Additional dimensions (centimeters): ___ x ___ cm
 Cannot be determined

Tumor Focality (Note B)

- Single tumor
- Separate tumor nodules of same histopathologic type (intrapulmonary metastases) in same lobe[#]
- Separate tumor nodules of same histopathologic type (intrapulmonary metastases) in different lobes[#]
- Synchronous primary tumors in same lobe[#]
- Synchronous primary tumors in different lobes[#]
- Multifocal lung adenocarcinoma with lepidic features[#]
- Diffuse pneumonic-type adenocarcinoma
- Cannot be determined

[#] Note: Required elements that differ among the tumor nodules (eg, tumor size, histologic type) should be reported for each tumor nodule.

Histologic Type (select all that apply) (Note C)

- Adenocarcinoma in situ (AIS), nonmucinous
- Adenocarcinoma in situ (AIS), mucinous
- Minimally invasive adenocarcinoma, nonmucinous
- Minimally invasive adenocarcinoma, mucinous
- Invasive adenocarcinoma, lepidic predominant
 - +Other subtypes present (specify subtype(s), may also include percentages): _____
- Invasive adenocarcinoma, acinar predominant
 - +Other subtypes present (specify subtype(s), may also include percentages): _____
- Invasive adenocarcinoma, papillary predominant
 - +Other subtypes present (specify subtype(s), may also include percentages): _____
- Invasive adenocarcinoma, micropapillary predominant
 - +Other subtypes present (specify subtype(s), may also include percentages): _____
- Invasive adenocarcinoma, solid predominant
 - +Other subtypes present (specify subtype(s), may also include percentages): _____
- Invasive adenocarcinoma, predominant subtype cannot be determined (explain): _____
 - +Subtypes present (specify subtype(s), may also include percentages): _____
- Invasive mucinous adenocarcinoma
- Mixed invasive mucinous and nonmucinous adenocarcinoma
- Colloid adenocarcinoma
- Fetal adenocarcinoma
- Enteric adenocarcinoma
- Squamous cell carcinoma in situ (SCIS)
- Invasive squamous cell carcinoma, keratinizing
- Invasive squamous cell carcinoma, non-keratinizing
- Invasive squamous cell carcinoma, basaloid
- Small cell carcinoma
- Combined small cell carcinoma (small cell carcinoma and non-small cell component)
 - (specify type of non-small cell carcinoma component): _____
- Large cell neuroendocrine carcinoma
- Combined large cell neuroendocrine carcinoma (LCNEC and other non-small cell component)
 - (specify type of other non-small cell carcinoma component): _____
- Typical carcinoid tumor
- Atypical carcinoid tumor
- Large cell carcinoma
- Adenosquamous carcinoma
- Pleomorphic carcinoma
- Spindle cell carcinoma
- Giant cell carcinoma
- Carcinosarcoma
- Pulmonary blastoma
- Lymphoepithelioma-like carcinoma
- NUT carcinoma
- Mucoepidermoid carcinoma

+ Data elements preceded by this symbol are not required for accreditation purposes. These optional elements may be clinically important but are not yet validated or regularly used in patient management.

- Adenoid cystic carcinoma
- Epithelial-myoepithelial carcinoma
- Carcinoma, type cannot be determined
- Non-small cell carcinoma, subtype cannot be determined
- Other histologic type not listed (specify): _____

+ Histologic Grade (Note D)

- + G1: Well differentiated
- + G2: Moderately differentiated
- + G3: Poorly differentiated
- + G4: Undifferentiated
- + Other (specify): _____
- + GX: Cannot be assessed
- + Not applicable

+ Spread Through Air Spaces (STAS) (Note C)

- + Not identified
- + Present

Visceral Pleura Invasion (Note E)

- Not identified
- Present
- Cannot be determined

Lymphovascular Invasion (select all that apply) (Note F)

- Not identified
- Present
 - + Lymphatic
 - + Arterial
 - + Venous
- Cannot be determined

Direct Invasion of Adjacent Structures (select all that apply) (Note G)

- No adjacent structures present
- Adjacent structures present but not involved
- Adjacent structures present and involved
 - Main bronchus
 - Hilar soft tissues
 - Carina
 - Parietal pleura
 - Chest wall
 - + Specify involved structure(s): _____
 - Phrenic nerve
 - Parietal pericardium
 - Diaphragm
 - Mediastinum
 - + Specify involved structure(s): _____
 - Heart
 - Great vessels
 - Trachea
 - Recurrent laryngeal nerve
 - Esophagus
 - Vertebral body
 - Other (specify): _____
- Cannot be assessed (explain): _____

+ Data elements preceded by this symbol are not required for accreditation purposes. These optional elements may be clinically important but are not yet validated or regularly used in patient management.

Margins (select all that apply) (Note H)

Note: Use this section only if all margins are uninvolved and all margins can be assessed.

All margins are uninvolved by carcinoma

Margins examined (specify): _____

Note: Margins may include bronchial, vascular, parenchymal, and others.

Distance of invasive carcinoma from closest margin (centimeters): ___ cm

Specify closest margin: _____

Distance of carcinoma in situ from closest margin (if applicable) (centimeters): ___ cm

Specify closest margin (if applicable): _____

Individual margin reporting required if any margins are involved or margin involvement cannot be assessed

Bronchial Margin (select all that apply)

Not applicable

Cannot be assessed

Uninvolved by invasive carcinoma

Uninvolved by carcinoma in situ

Involved by invasive carcinoma

Involved by carcinoma in situ

Vascular Margin

Not applicable

Cannot be assessed

Uninvolved by carcinoma

Involved by carcinoma

Parenchymal Margin (select all that apply)

Not applicable

Cannot be assessed

Uninvolved by invasive carcinoma

Uninvolved by lepidic component of invasive adenocarcinoma

Uninvolved by adenocarcinoma in situ

Involved by invasive carcinoma

Involved by lepidic component of invasive adenocarcinoma

Involved by adenocarcinoma in situ

Other Attached Tissue Margin (required only if applicable)

Specify margin: _____

Cannot be assessed

Uninvolved by invasive carcinoma

Involved by invasive carcinoma

Treatment Effect (Note I)

No known presurgical therapy

Greater than 10% residual viable tumor

Less than or equal to 10% residual viable tumor

Cannot be determined

Regional Lymph Nodes

No lymph nodes submitted or found

Lymph Node Examination (required only if lymph nodes present in the specimen)

Number of Lymph Nodes Involved: _____

+ Data elements preceded by this symbol are not required for accreditation purposes. These optional elements may be clinically important but are not yet validated or regularly used in patient management.

___ Number cannot be determined (explain): _____
Specify nodal station(s) involved (applicable only if node(s) involved): _____

Number of Lymph Nodes Examined: ___
___ Number cannot be determined (explain): _____
Specify nodal station(s) examined: _____

+ Extranodal Extension (Note J)

- + ___ Not identified
+ ___ Present
+ ___ Cannot be determined

Pathologic Stage Classification (pTNM, AJCC 8th Edition) (Note J)

Note: Reporting of pT, pN, and (when applicable) pM categories is based on information available to the pathologist at the time the report is issued. Only the applicable T, N, or M category is required for reporting; their definitions need not be included in the report. The categories (with modifiers when applicable) can be listed on 1 line or more than 1 line.

TNM Descriptors (required only if applicable) (select all that apply)

- ___ m (multiple primary tumors)
___ r (recurrent)
___ y (posttreatment)

Primary Tumor (pT)

- ___ pTX: Primary tumor cannot be assessed, or tumor proven by presence of malignant cells in sputum or bronchial washings but not visualized by imaging or bronchoscopy
- ___ pT0: No evidence of primary tumor
- ___ pTis (SCIS): Squamous cell carcinoma in situ (SCIS)
- ___ pTis (AIS): Adenocarcinoma in situ (AIS): adenocarcinoma with pure lepidic pattern, ≤3 cm in greatest dimension
- pT1: Tumor ≤3 cm in greatest dimension, surrounded by lung or visceral pleura, without bronchoscopic evidence of invasion more proximal than the lobar bronchus (ie, not in the main bronchus)*
- ___ pT1mi: Minimally invasive adenocarcinoma: adenocarcinoma (≤3 cm in greatest dimension) with a predominantly lepidic pattern and ≤5 mm invasion in greatest dimension (See note C)
- ___ pT1a: Tumor ≤1 cm or less in greatest dimension; A superficial spreading tumor of any size with its invasive component limited to the bronchial wall and may extend proximal to the main bronchus also is classified as T1a, but these tumors are uncommon
- ___ pT1b: Tumor >1 cm, but ≤2 cm in greatest dimension
- ___ pT1c: Tumor >2 cm but ≤3 cm in greatest dimension
- pT2: Tumor >3 cm but ≤5 cm or having any of the following features:#*
- *Involves the main bronchus regardless of distance to the carina, but without involvement of the carina;*
 - *Invades visceral pleura (PL1 or PL2);*
 - *Associated with atelectasis or obstructive pneumonitis that extends to the hilar region, involving part or all of the lung.*
- ___ pT2a: Tumor >3 cm, but ≤4 cm in greatest dimension
- ___ pT2b: Tumor >4 cm, but ≤5 cm in greatest dimension
- ___ pT3: Tumor >5 cm but ≤7 cm in greatest dimension; or directly invading any of the following: parietal pleura (PL3), chest wall (including superior sulcus tumors), phrenic nerve, parietal pericardium; or separate tumor nodule(s) in the same lobe as the primary
- ___ pT4: Tumor >7 cm in greatest dimension; or tumor of any size invading one or more of the following: diaphragm, mediastinum, heart, great vessels, trachea, recurrent laryngeal nerve, esophagus, vertebral body or carina; or separate tumor nodule(s) in an ipsilateral lobe different from that of the primary

+ Data elements preceded by this symbol are not required for accreditation purposes. These optional elements may be clinically important but are not yet validated or regularly used in patient management.

#Note: Tumors with these features are classified as T2a if ≤4 cm or if the size cannot be determined and T2b if >4 cm but ≤5 cm.

Regional Lymph Nodes (pN)

- pNX: Regional lymph nodes cannot be assessed
- pN0: No regional lymph node metastasis
- pN1: Metastasis in ipsilateral peribronchial and/or ipsilateral hilar lymph nodes, and intrapulmonary nodes, including involvement by direct extension
- pN2: Metastasis in ipsilateral mediastinal and/or subcarinal lymph node(s)
- pN3: Metastasis in contralateral mediastinal, contralateral hilar, ipsilateral or contralateral scalene, or supraclavicular lymph node(s)

Distant Metastasis (pM) (required only if confirmed pathologically in this case)

pM1: Distant metastasis

- pM1a: Separate tumor nodule(s) in contralateral lobe; tumor with pleural or pericardial nodules or malignant pleural (or pericardial) effusion[#]
- pM1b: Single extrathoracic metastasis in a single organ (including involvement of a single nonregional lymph node)
- pM1c: Multiple extrathoracic metastases in single organ or in multiple organs

Specify site(s) (if applicable): _____

Note: Most pleural (pericardial) effusions with lung cancer are a result of the tumor. In a few patients, however, multiple microscopic examinations of pleural (pericardial) fluid are negative for tumor, and the fluid is nonbloody and not an exudate. If these elements and clinical judgment dictate that the effusion is not related to the tumor, the effusion should be excluded as a staging descriptor.

+ Additional Pathologic Findings (select all that apply)

- + None identified
- + Atypical adenomatous hyperplasia
- + Squamous dysplasia
- + Metaplasia (specify type): _____
- + Diffuse neuroendocrine hyperplasia
- + Inflammation (specify type): _____
- + Emphysema
- + Other (specify): _____

+ Ancillary Studies

Note: For reporting cancer biomarker testing results, the CAP Lung Biomarker Template should be used. Pending biomarker studies should be listed in the Comments section of this report.

+ Comment(s)

Explanatory Notes

A. Tumor Size

Based on data showing prognosis correlates with invasive size in nonmucinous adenocarcinomas with lepidic and invasive components, the American Joint Committee on Cancer (AJCC) has adopted a rule that for nonmucinous adenocarcinomas with a lepidic component, only the size of the invasive component is used to assign T category.¹⁻⁴ This rule aligns with the recommendation previously set forth by the Union for International Cancer Control (UICC) of using invasive size for T descriptor size.⁵ This rule does not apply to other histologic types of lung cancer, including invasive mucinous lung adenocarcinoma.

The invasive component to be measured in nonmucinous adenocarcinomas with a lepidic component includes any histologic subtype other than a lepidic pattern (ie, acinar, papillary, micropapillary, and/or solid) and/or tumor cells infiltrating myofibroblastic stroma.⁶ In tumors where the invasive component is not a single discrete measurable focus, estimating the percentage of the total tumor that is invasive and then multiplying by the total tumor size to estimate invasive tumor size is recommended.¹

B. Tumor Focality

When more than 1 tumor nodule is identified in resection specimens, it is important to attempt distinction of synchronous primary tumors from a tumor with intrapulmonary metastasis. These scenarios have different prognoses and are staged differently. Multiple tumor nodules of different histologic types (eg, 1 squamous cell carcinoma, 1 adenocarcinoma) are considered synchronous primaries and should be recorded as such in the pathology report with an individual TNM assigned to each tumor.⁷ In such cases, required reporting elements that differ among the tumors should be recorded for each primary tumor. For multiple tumor nodules of the same histopathologic type, comprehensive histologic assessment has been proposed for the distinction of synchronous primaries from separate tumor nodules (intrapulmonary metastasis).⁸ Other pathologic criteria for distinguishing synchronous primary tumors from separate tumor nodules (intrapulmonary metastasis) that are not based strictly on histologic assessment (eg, assessing similarity of breakpoints using comparative genomic hybridization) are detailed in the 8th edition of the AJCC staging manual.¹

In cases with multiple tumors deemed not to represent synchronous primaries (ie, intrapulmonary metastases), required elements that differ among the intrapulmonary metastases (eg, tumor size) should be reported for each tumor nodule.

Multifocal lung adenocarcinoma with lepidic features is the designation applied to multiple discrete foci of lepidic-predominant adenocarcinoma (LPA), minimally invasive adenocarcinoma (MIA), or adenocarcinoma in situ (AIS) with or without other subtypes of adenocarcinoma as lesser components that manifest on computed tomography (CT) as multiple subsolid (either pure ground glass or part solid) nodules.⁹ This designation applies whether a detailed histologic assessment shows a matching or different appearance among the tumor foci. Data suggest that in most cases, the multiple lesions represent synchronous primary tumors.¹⁰ Assignment of T category in these cases is based on the highest T lesion, followed by the suffix “m”, indicating multiplicity, or the number of tumors in parentheses (eg, T1b(m) or T1b(2)) (Table 1).¹ It should be noted that foci of atypical adenomatous hyperplasia (AAH) are not counted for the purpose of TNM classification.

In some patients, adenocarcinoma manifests radiographically as diffuse consolidation, which has been designated as “pneumonic-type” lung adenocarcinoma. Such imaging findings typically correspond pathologically to invasive mucinous adenocarcinoma, but mixed mucinous and nonmucinous patterns may also be seen.¹⁰ Invasive mucinous adenocarcinoma often exhibits lepidic-predominant growth, but robust sampling usually discloses invasive foci. Occasionally, invasive mucinous adenocarcinoma shows a heterogeneous mixture of other growth patterns. To qualify as pneumonic-type adenocarcinoma, tumor should be diffusely distributed throughout a region(s) of lung, as opposed to forming discrete single or multiple well-demarcated nodules or masses.¹⁰

The size of diffuse pneumonic-type adenocarcinomas, as well as miliary forms of adenocarcinoma, is often difficult to measure. When a single tumor area is present, it is categorized according to standard TNM criteria. Multiple tumor areas are categorized according to the extent of lobar involvement: T3 when limited to a single

lobe, T4 when there is involvement of other ipsilateral lobe, and M1a is used to indicate the presence of contralateral lung involvement.¹

Table 1. Schematic Summary of Disease Patterns and TNM Classification of Patients With Lung Cancer With Multiple Pulmonary Sites of Involvement

	Second Primary Lung Cancer	Multifocal GG/L Nodules	Pneumonic-type Adenocarcinoma	Separate Tumor Nodule
Imaging features	Two or more distinct masses with imaging characteristic of lung cancer (eg, spiculated)	Multiple ground-glass or part-solid nodules	Patchy areas of ground glass and consolidation	Typical lung cancer (eg, solid, spiculated) with separate solid nodule
Pathological features	Different histotype or different morphology based on comprehensive histologic assessment	Adenocarcinomas with prominent lepidic component (typically varying degrees of AIS, MIA, LPA)	Same histology throughout (most often invasive mucinous adenocarcinoma)	Distinct masses with the same morphologic features based on comprehensive histologic assessment
TNM classification	Separate cTNM and pTNM for each cancer	T based on highest T lesion, with (#/m) indicating multiplicity; single N and M	T based on size or T3 if in single lobe, T4 or M1a if in different ipsilateral or contralateral lobes; single N and M	Location of separate nodule relative to primary site determines whether T3, T4, or M1a; single N and M
Conceptual view	Unrelated tumors	Separate tumors, albeit with similarities	Single tumor, diffuse pulmonary involvement	Single tumor with intrapulmonary metastasis

AIS, adenocarcinoma in situ; GG/L, ground-glass/lepidic; LPA, lepidic-predominant adenocarcinoma; MIA, minimally invasive adenocarcinoma. From AJCC Cancer Staging Manual, 8th edition. Used with permission.

C. Histologic Type

For consistency in reporting, the histologic classification published by the World Health Organization (WHO) for tumors of the lung, including carcinoids, is recommended.⁸ Although acceptable in small biopsies, a designation of non-small cell lung carcinoma, not otherwise specified (NSCLC, NOS), is not acceptable in resection specimens.

Lung carcinomas should be adequately sampled in order to ensure defining features are satisfactorily represented in the sections examined histologically and the presence or absence of invasion can be thoroughly assessed. The WHO defines invasion in adenocarcinoma as: (1) any histologic subtype other than a lepidic pattern (ie, acinar, papillary, micropapillary, and/or solid), (2) tumor cells infiltrating myofibroblastic stroma, (3) vascular or pleural invasion, or (4) spread through air spaces (STAS).⁸

STAS is a recently described concept which is defined as micropapillary clusters, solid nests or single cells of tumor extending beyond the edge of the tumor into the air spaces of the surrounding lung parenchyma. Initial studies have shown that the presence of STAS is associated with an increased incidence of recurrence in tumors that have undergone limited resection (eg, segmentectomy, wedge resection).⁸ At the present time, STAS should not be incorporated into the measurement of tumor size (see Note A).¹

For cases in which a diagnosis of AIS or MIA is being considered, the lesion must be entirely submitted for histopathologic examination. A diagnosis of MIA is applied to a lepidic-predominant tumor ≤ 3 cm in size with an invasive component measuring ≤ 0.5 cm provided it does not exhibit any of the following: (1) tumor invades lymphatics, blood vessels or pleura, (2) tumor necrosis is present, (3) STAS is present.⁸ Tumors ≤ 3 cm with ≤ 0.5 cm of invasion exhibiting 1 or more of these exclusionary features are classified as lepidic-predominant adenocarcinoma. A diagnosis of AIS or MIA should only be made on solitary lesions ≤ 3 cm in diameter. Specimens showing only AIS are categorized as Tis (AIS). MIA is classified as T1mi.¹

For the uncommon occurrence of a lepidic-predominant tumor >3.0 cm with either no invasion or ≤ 0.5 cm of invasion, it is recommended that such tumors be classified as lepidic-predominant adenocarcinoma and staged as pT1a, as there is insufficient data to conclude they have the same prognostic features as ≤ 3.0 cm tumors meeting criteria for AIS or MIA.⁶

Classification of adenocarcinomas by predominant histologic pattern can be useful for assessing pathologic grade. The WHO recommends classifying invasive nonmucinous adenocarcinomas according to the predominant subtype and specifying non-predominant subtypes semi-quantitatively in 5% increments.⁸ In poorly differentiated cases, immunohistochemistry can greatly aid in classification. This is particularly useful in making a diagnosis of solid-type adenocarcinoma or nonkeratinizing squamous cell carcinoma.

D. Histopathologic Grade (G)

A tiered grading scheme for lung cancer (shown below) has been put forth by the AJCC.¹ However, its reproducibility and prognostic significance have not been rigorously tested, and therefore histopathologic grade is designated as an optional reporting element.

AJCC Histopathologic Grading Scheme¹:

Grade X (GX): Cannot be assessed
 Grade 1 (G1): Well differentiated
 Grade 2 (G2): Moderately differentiated
 Grade 3 (G3): Poorly differentiated
 Grade 4 (G4): Undifferentiated

E. Visceral Pleural Invasion

The presence of visceral pleural invasion by tumors ≤ 3 cm changes the T category from pT1 to pT2a and increases the stage from IA (IA1, IA2, or IA3 depending on tumor size) to IB in patients with N0, M0 disease.¹ Studies have shown that tumors ≤ 3 cm that penetrate beyond the elastic layer of the visceral pleura behave similarly to similar-size tumors that extend to the visceral pleural surface.^{11,12} Visceral pleural invasion should therefore be considered present not only in tumors that extend to the visceral pleural surface, but also in tumors that penetrate beyond the elastic layer of the visceral pleura (Figure 1).⁴⁻⁶ Elastic stains may aid in the assessment of visceral pleural invasion.^{11,12,13}

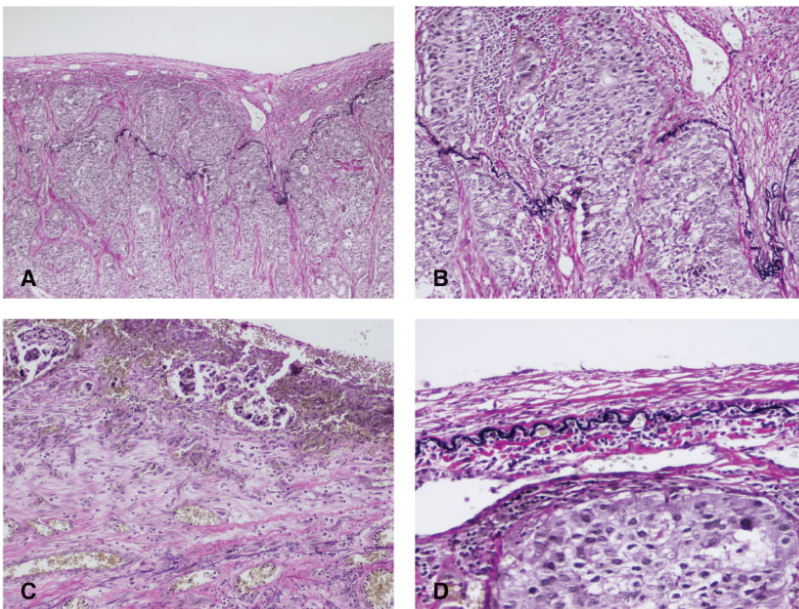


Figure 1. Types of visceral pleural invasion. Staining for elastin (eg, elastic-Van Gieson [EVG] stain) can aid in detection of visceral pleural invasion where it is indeterminate by hematoxylin-eosin (H&E) stain. A and B. Visceral pleural invasion is present when a tumor penetrates beyond the elastic layer of the visceral pleura (type PL1 pleural invasion) C. Tumor extension to the visceral pleural surface is also categorized as visceral pleural invasion (type PL2). Both types of visceral pleural invasion raise the T category of otherwise T1 tumors to T2a. D. Visceral pleural invasion is categorized as absent in tumors that do not penetrate the visceral pleural elastic layer (type PL0). (Original magnifications x200 [A], x400 [B and C], x600 [D]).

Based on available data, a tumor with direct invasion across a fissure or directly if the fissure is incomplete into an adjacent ipsilateral lobe should be classified as T2a unless the size of the tumor or other criteria that would dictate a higher T category are met.¹³

Pleural tumor nodules, including same lobe visceral pleural nodules, separate from the primary tumor (non-contiguous) should be categorized as M1a.¹

F. Vascular/Lymphatic Invasion

There are data showing lymphatic invasion by tumor represents an unfavorable prognostic finding, but studies on the role of large vessel invasion have produced somewhat conflicting results.¹⁵⁻¹⁶ The presence of lymphovascular invasion is exclusionary of adenocarcinoma in situ (AIS) and minimally invasive adenocarcinoma (MIA).⁸ Angiolymphatic invasion does not alter the pT and pN classifications or the TNM stage grouping.

G. Direct Invasion of Adjacent Structures

In pneumonectomy specimens, centrally located tumors sometimes exhibit direct invasion of the hilar fat and/or other hilar soft tissues. Direct hilar fat/soft tissue invasion without evidence of direct extension into other structures that would meet a higher T designation is categorized as T2a.¹

Occasionally, lung cancer specimens consist of en bloc resections that incorporate extrapulmonary structures directly invaded by tumor. Accurate assessment of such specimens requires communication with the surgeon regarding the nature and location of any attached extrapulmonary structures. According to the AJCC, direct invasion of the parietal pleura is categorized as T3, as is direct invasion of the chest wall (including the superior sulcus).¹ Although not required, specifying the chest wall structures directly invaded by tumor (eg, intercostal muscle[s], rib[s], pectoralis muscle, latissimus muscle, serratus muscle) may facilitate patient management. Direct phrenic nerve and parietal pericardial invasion are also categorized as T3. Tumor extension into the visceral pericardium is categorized as T4.

Direct invasion of central thoracic structures, including the heart, great vessels, mediastinum, trachea, recurrent laryngeal nerve, esophagus, vertebral body, and carina is considered T4. Direct invasion of the diaphragm is also categorized as T4.

H. Margins

Surgical margins represent sites that have either been cut or bluntly dissected by the surgeon to resect the specimen. The presence of tumor at a surgical margin is an important finding, because there is the potential for residual tumor remaining in the patient in the area surrounding a positive margin. Peripheral wedge resections contain a parenchymal margin, which is represented by the tissue at the staple line(s). Lobectomy and pneumonectomy specimens contain bronchial and vascular margins and, depending on the completeness of the interlobar fissures and other anatomic factors, may also contain parenchymal margins in the form of staple lines. En bloc resections that contain extrapulmonary structures as part of the specimen have additional margins (eg, parietal pleura, chest wall), which should be designated by the surgeon for appropriate handling. Note that the visceral pleura is not a surgical margin.

I. Treatment Effect

For patients who have received neoadjuvant chemotherapy and/or radiation therapy before surgical resection, quantifying the extent of therapy-induced tumor regression provides prognostically relevant information.¹⁴ Measuring residual tumor size in patients with a partial response can be challenging, as there are often discontinuous clusters of viable tumor at the peripheral edges of an irregular area of treatment-related necrosis. The AJCC suggests multiplying the percentage of the mass that is composed of viable tumor by the size of the total mass to estimate postneoadjuvant tumor size.^{1,6} A “y” prefix is applied to the TNM classification in resections following multimodality therapy (see Note I). If no viable tumor is identified on resection, ypT0 is the appropriate designation.

J. TNM and Stage Grouping

The TNM staging system of the AJCC and the UICC is recommended for both non-small cell lung cancer and small cell lung cancer.^{1,17} Typical carcinoid and atypical carcinoid tumors should also be classified according to the TNM staging system.

By AJCC/UICC convention, the designation “T” refers to a primary tumor that has not been previously treated. The symbol “p” refers to the pathologic classification of the TNM, as opposed to the clinical classification, and is based on gross and microscopic examination. pT entails a resection of the primary tumor or biopsy adequate to evaluate the highest pT category, pN entails removal of nodes adequate to validate lymph node metastasis, and pM implies microscopic examination of distant lesions.

TNM Descriptors

For identification of special cases of TNM or pTNM classifications, the “m” suffix and “y,” and “r” prefixes are used. Although they do not affect the stage grouping, they indicate cases needing separate analysis.

The “m” suffix indicates the presence of multiple primary tumors in a single site and is recorded in parentheses: pT(m)NM (see Note B).

The “y” prefix indicates those cases in which classification is performed during or following initial multimodality therapy (ie, neoadjuvant chemotherapy, radiation therapy, or both chemotherapy and radiation therapy). The cTNM or pTNM category is identified by a “y” prefix. The ycTNM or ypTNM categorizes the extent of tumor actually present at the time of that examination. The “y” categorization is not an estimate of tumor prior to multimodality therapy (ie, before initiation of neoadjuvant therapy) (see Note I).

The “r” prefix indicates a recurrent tumor when staged after a documented disease-free interval, and is identified by the “r” prefix: rTNM.

T Category Considerations

The uncommon superficial spreading tumor of any size with its invasive component limited to the bronchial wall, which may extend proximal to the main bronchus, is classified as T1.¹

Although obstructive pneumonitis associated with tumor is sometimes seen histologically, accurate assessment of tumor-associated obstructive pneumonitis as well as atelectasis requires integration of clinical and radiographic information. Atelectasis and obstructive pneumonitis recognized by pathology only should not be used for TNM staging.

N Category Considerations

Lymph node metastases are an adverse prognostic factor, the extent of which is dependent on the location of the involved lymph nodes. The involved lymph node stations should be recorded according to the International Association for the Study of Lung Cancer (IASLC) lymph node map. Given the nature of the procedure, lymph nodes obtained by mediastinoscopy are often received fragmented, and it may not be possible to distinguish a single fragmented lymph node from fragments of multiple lymph nodes. For this reason, only if the actual number of nodes is known or provided should it be quantified. Otherwise, it is permissible to report the sites of nodal metastases without specifying the number involved.

Although extranodal extension of a positive mediastinal lymph node may represent an unfavorable prognostic finding, it does not change the pN classification or the TNM stage grouping. Extranodal extension refers to the extension of metastatic intranodal tumor beyond the lymph node capsule into the surrounding tissue. Direct extension of a primary tumor into a nearby lymph node does not qualify as extranodal extension.

The anatomic classification of regional lymph nodes proposed by the IASLC is shown below. A complete description of the anatomic limits of each nodal station can be found in the AJCC Staging Manual.¹

N2 Nodes

Station 1	Lower cervical, supraclavicular, and sternal notch nodes
Station 2	Upper paratracheal nodes

Station 3	Prevascular and retrotracheal nodes
Station 4	Lower paratracheal nodes:
Station 5	Subaortic nodes (aorto-pulmonary window)
Station 6	Paraaortic nodes (ascending aorta or phrenic)
Station 7	Subcarinal nodes
Station 8	Paraesophageal nodes (below carina)
Station 9	Pulmonary ligament nodes

N1 Nodes

Station 10	Hilar nodes
Station 11	Interlobar nodes
Station 12	Lobar nodes
Station 13	Segmental nodes
Station 14	Subsegmental nodes

Metastasis to nonregional lymph nodes (ie, lymph nodes that are not included in the IASLC map) are assigned to the M1b or M1c category depending on whether single or multiple metastases are present.

M Category Considerations

With respect to this protocol, reporting a pM designation (ie, pM1a, pM1b, or pM1c) is required only if metastasis is pathologically confirmed in the specimen(s) being examined. The designation pMX should not be used.

In addition to malignant pleural effusion, malignant pericardial effusion, as well as separate tumor nodule(s) in a contralateral lobe are categorized as M1a.¹ Visceral or parietal ipsilateral pleural tumor nodules and pericardial tumor nodules that are not in direct continuity with the primary lung tumor are also categorized as M1a. Discontinuous tumor nodules in the chest wall or diaphragm are categorized as M1b or M1c depending on whether there are single or multiple nodules.

References

1. Amin MB, Edge SB, Greene FL, et al, eds. *AJCC Cancer Staging Manual*. 8th ed. New York, NY: Springer; 2017.
2. Tsutani Y, Miyata Y, Nakayama H, et al. Prognostic significance of using solid versus whole tumor size on high-resolution computed tomography for predicting pathologic malignant grade tumors in clinical stage IA lung adenocarcinoma: a multicenter study. *J Thorac Cardiovasc Surg*. 2012;143(3):607-612.
3. Yoshizawa A, Motoi N, Riely GJ, et al. Impact of proposed IASLC/ATS/ERS classification of lung adenocarcinoma: prognostic subgroups and implications for further revision of staging based on analysis of 514 stage I cases. *Mod Pathol*. 2011;24(5):653-664.
4. Maeyashiki T, Suzuki K, Hattori A, et al. The size of consolidation on thin-section computed tomography is a better predictor of survival than the maximum tumour dimension in resectable lung cancer. *Eur J Cardiothorac Surg*. 2013;43(5):915-918.
5. Wittekind C, Greene FL, Henson DE, Hutter RVP, Sobin LH, eds. *TNM Supplement: A Commentary on Uniform Use*. 3rd ed. New York, NY: Wiley-Liss; 2001.
6. Travis WD, Asamura H, Bankier AA, et al. The IASLC lung cancer staging project: proposals for coding T categories for subsolid nodules and assessment of tumor size in part-solid tumors in the forthcoming eighth edition of the TNM classification of lung cancer. *J Thorac Onc*. 2016;11(8):1204-1223.
7. Detterbeck FC, Franklin WA, Nicholson AG, et al. The IASLC lung cancer staging project: background data and proposed criteria to distinguish separate primary lung cancers from metastatic foci in patients with two lung tumors in the forthcoming eighth edition of the TNM classification of lung cancer. *J Thorac Onc*. 2016;11(5):651-665.
8. Travis WD, Brambilla E, Burke AP, Marx A, Nicholson AG, eds. *WHO Classification of Tumours of the Lung, Pleura, Thymus and Heart*. Geneva, Switzerland: WHO Press; 2015.
9. Detterbeck FC, Nicholson AG, Franklin WA, et al. The IASLC lung cancer staging project: summary of proposals for revisions of the classification of lung cancers with multiple pulmonary sites of involvement in the forthcoming eighth edition of the TNM classification of lung cancer. *J Thorac Onc*. 2016;11(5):639-650.
10. Detterbeck FC, Marom EM, Arenberg DA, et al. The IASLC lung cancer staging project: background data and proposals for the application of TNM staging rules to lung cancer presenting as multiple nodules with

ground glass or lepidic features or a pneumonic type of involvement in the forthcoming eighth edition of the TNM classification of lung cancer. *J Thorac Onc.* 2016;11(5):666-680.

11. Bunker ML, Raab SS, Landreneau RJ, et al. The diagnosis and significance of visceral pleura invasion in lung carcinoma: histologic predictors and the role of elastic stains. *Am J Clin Pathol.* 1999;112(6):777-783.
12. Shimizu K, Yoshida J, Nagai K, et al. Visceral pleural invasion classification in non-small cell lung cancer: a proposal on the basis of outcome assessment. *J Thorac Cardiovasc Surg.* 2004;127(6):1574-1578.
13. Travis WD, Brambilla E, Rami-Porta R, et al. Visceral pleural invasion: pathologic criteria and use of elastic stains: proposal for the 7th edition of the TNM classification for lung cancer. *J Thorac Oncol.* 2008;3(12):1384-1390.
14. Junker K, Langer K, Klinker F, Bosse U, Thomas M. Grading of tumor regression in non-small cell lung cancer: morphology and prognosis. *Chest.* 2001;120(5):1584-1591.
15. Wang J, Wang B, Zhao W, et al. Clinical significance and role of lymphatic vessel invasion as a major prognostic implication in non-small cell lung cancer: a meta-analysis. *PLoS One.* 2012;7(12):e52704.
16. Wang J, Chen J, Chen X, Wang B, Li K, Bi J. Blood vessel invasion as a strong independent prognostic indicator in non-small cell lung cancer: a systematic review and meta-analysis. *PLoS One.* 2011;6(12):e28844.
17. Brierley JD, Gospodarowicz MK, Wittekind CH, et al, eds. *TNM Classification of Malignant Tumours.* 8th ed. Oxford, UK: Wiley; 2016.