

# Protocol for the Examination of TURP and Enucleation Specimens From Patients With Carcinoma of the Prostate Gland

Version: Prostate TURP 4.0.5.0

Protocol Posting Date: February 2020

## Accreditation Requirements

The use of this protocol is recommended for clinical care purposes but is not required for accreditation purposes.

## This protocol may be used for the following procedures AND tumor types:

Procedure	Description
TURP and enucleation specimens	Includes specimens designated transurethral resection of the prostate (TURP), and enucleation specimens (simple or subtotal prostatectomy)
Tumor Type	Description
Carcinoma	Includes all adenocarcinomas and histologic variants, neuroendocrine carcinomas, and others

## The following should NOT be reported using this protocol:

Procedure
Biopsy (consider Prostate Biopsy protocol)
Radical Prostatectomy (consider Prostate Radical Prostatectomy protocol)
Tumor Type
Lymphoma (consider the Hodgkin or non-Hodgkin Lymphoma protocols)
Sarcoma (consider the Soft Tissue protocol)

## Authors

Gladell P. Paner, MD\*; John R. Srigley, MD\*; Ming Zhou, MD, PhD\*; Robert Allan, MD; Mahul B. Amin, MD; Sam S. Chang, MD; Brett Delahunt, MD; Lars Egevad, MD; Jonathan I. Epstein, MD; Andrew J. Evans, MD; David J. Grignon, MD; Peter A. Humphrey, MD, PhD; James M. McKiernan, MD; Rodolfo Montironi, MD; Jason Pettus, MD; Victor E. Reuter, MD; Thomas M. Wheeler, MD

With guidance from the CAP Cancer and CAP Pathology Electronic Reporting Committees.

\* Denotes primary author. All other contributing authors are listed alphabetically.

## Summary of Changes

### Version 4.0.5.0

Removed Urothelial tumor, including variants (consider the Urethra (prostatic urethra) protocol) from list of Tumor Types that should NOT be reported using this protocol

Added to Histologic Grade:

For urothelial carcinoma, other variants, or divergent differentiation, if applicable

For squamous cell carcinoma or urinary tract adenocarcinoma, if applicable

## Surgical Pathology Cancer Case Summary

---

Protocol posting date: February 2020

### **PROSTATE GLAND: Transurethral Prostatic Resection (TURP), Enucleation Specimen (Simple or Subtotal Prostatectomy)**

**Note: This case summary is recommended for reporting TURP specimens but is not required for accreditation purposes. Core data elements are bolded to help identify routinely reported elements.**

**Select a single response unless otherwise indicated.**

#### **Procedure (Note A)**

- Transurethral resection of the prostate (TURP)
- Enucleation (simple or subtotal prostatectomy)
- Other (specify): \_\_\_\_\_
- Not specified

#### **Histologic Type (select all that apply) (Note B)**

- Acinar adenocarcinoma
- Ductal adenocarcinoma
- Small-cell neuroendocrine carcinoma
- Isolated intraductal carcinoma
- Other histologic type not listed (specify): \_\_\_\_\_

#### **Histologic Grade (Note C)**

##### **Grade Group and Gleason Score**

- Not applicable
- Cannot be assessed
- Grade group 1 (Gleason Score 3+3=6)
- Grade group 2 (Gleason Score 3+4=7)
- Grade group 3 (Gleason Score 4+3=7)
- Grade group 4 (Gleason Score 4+4=8)
- Grade group 4 (Gleason Score 3+5=8)
- Grade group 4 (Gleason Score 5+3=8)
- Grade group 5 (Gleason Score 4+5=9)
- Grade group 5 (Gleason Score 5+4=9)
- Grade group 5 (Gleason Score 5+5=10)

**Percentage of Pattern 4 in Gleason Score 7(3+4, 4+3) Cancer (report if applicable) \_\_\_\_\_%**

Percentage Gleason Patterns 4 and 5 (applicable to Gleason score greater than 7)

Percentage pattern 4: \_\_\_\_\_%

Percentage pattern 5: \_\_\_\_\_%

For urothelial carcinoma, other variants, or divergent differentiation, if applicable

- Low-grade
- High-grade
- Other (specify): \_\_\_\_\_

For squamous cell carcinoma or urinary tract adenocarcinoma, if applicable

- G1: Well-differentiated
- G2: Moderately differentiated
- G3: Poorly differentiated
- GX: Cannot be assessed

**Intraductal Carcinoma (IDC) (Note D)**

- Not identified
- Present
- Cannot be determined

**Tumor Quantitation (Note E)**

**Estimated percentage of prostatic tissue involved by tumor: \_\_\_\_%**

*For TURP Specimens*

- Number of positive chips: \_\_\_\_
- Total number of chips: \_\_\_\_
- Cannot be determined

*For Enucleation and Other Specimens*

- Tumor size (dominant nodule, if present):
  - Greatest dimension (millimeters): \_\_\_\_ mm
  - Additional dimensions (millimeters): \_\_\_\_ x \_\_\_\_ mm

**Periprostatic Fat Invasion (report if identified in specimen)**

- Not identified
- Present

**Seminal Vesicle Invasion (report if identified in specimen)**

- Not identified
- Present

**Lymphovascular Invasion**

- Not identified
- Present
- Cannot be determined

**Perineural Invasion (Note F)**

- Not identified
- Present

**Additional Pathologic Findings (select all that apply)**

- None identified
- High-grade prostatic intraepithelial neoplasia (PIN) (Note G)
- Atypical adenomatous hyperplasia (adenosis)
- Nodular prostatic hyperplasia
- Inflammation (specify type): \_\_\_\_\_
- Other (specify): \_\_\_\_\_

**Treatment Effect (select all that apply)**

- No known presurgical therapy
- Not identified
- Radiation therapy effect present
- Hormonal therapy effect present
- Other therapy effect(s) present (specify): \_\_\_\_\_
- Cannot be determined

Comment(s)

## Explanatory Notes

---

### A. Submission of Tissue for Microscopic Evaluation in Transurethral Resection

Transurethral resection specimens that weigh 12 grams or less should be submitted in their entirety, usually in 6 to 8 cassettes.<sup>1</sup> For specimens that weigh more than 12 g, the initial 12 g are submitted (6-8 cassettes), and 1 cassette may be submitted for every additional 5 g of remaining tissue.<sup>2</sup>

In general, random chips are submitted; however, if some chips are firmer or have a yellow or orange-yellow appearance, they should be submitted preferentially.

If an unsuspected carcinoma is found in tissue submitted, and it involves 5% or less of the tissue examined, the remaining tissue may be submitted for microscopic examination, especially in younger patients.

#### References:

1. Humphrey PA, Walther PJ. Adenocarcinoma of the prostate, I: sampling considerations. *Am J Clin Pathol.* 1993;99:746-759.
2. Trpkov K, Thompson J, Kulaga A, Yilmaz A. How much tissue sampling is required when minimal prostate carcinoma is identified on transurethral resection? *Arch Path Lab Med.* 2008;132(8):1313-1316.
3. Paner GP, Magi-Galluzzi C, Amin MB, Srigley JR: Adenocarcinoma of the prostate. In: Amin MB, Grignon DJ, Srigley JR, Eble JN, eds. *Urological Pathology.* Philadelphia, PA: Lippincott William & Wilkins; 2014:559-673.
4. Srigley JR. Key issues in handling and reporting radical prostatectomy specimens. *Arch Pathol Lab Med.* 2006;30:303-317.
5. Sehdev AE, Pan CC, Epstein JI. Comparative analysis of sampling methods for grossing radical prostatectomy specimens performed for nonpalpable (stage T1c) prostatic adenocarcinoma. *Hum Pathol.* 2001;32:494-499.
6. Samarantunga H, Montironi R, True L, et al; The ISUP prostate consensus group. International Society of Urological Pathology (ISUP) Consensus Conference on Handling and Staging of Radical Prostatectomy Specimens: Working group 1: handling of the specimen. *Mod Pathol.* 2011;24:6-15.

### B. Histologic Type

This protocol applies only to invasive adenocarcinomas of the prostate gland, as shown below. Carcinomas other than adenocarcinoma are exceptionally uncommon, accounting for less than 0.5% of prostatic tumors. The protocol does not apply to pure squamous cell carcinoma, basal cell carcinoma, urothelial carcinoma, small cell neuroendocrine carcinoma, and large cell neuroendocrine carcinoma. If these rare subtypes of carcinoma, however, are mixed with acinar type adenocarcinoma, the protocol may be used.

#### Classification of Invasive Adenocarcinoma of Prostate (2016 WHO classification<sup>1</sup>)

##### Acinar adenocarcinoma

- Atrophic
- Pseudohyperplastic
- Microcystic
- Foamy gland
- Mucinous (colloid)
- Signet ring-like cell
- Pleomorphic giant cell
- Sarcomatoid

##### Ductal adenocarcinoma

- Cribriform
- Papillary
- Solid

##### Neuroendocrine tumors

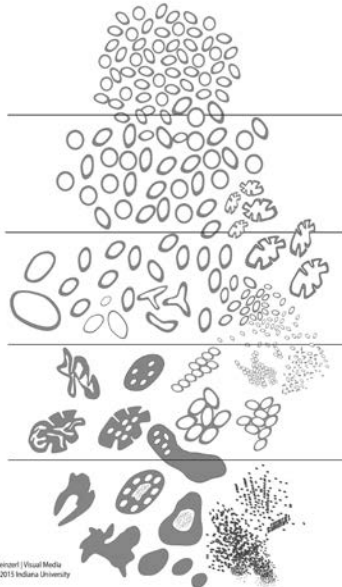
- Adenocarcinoma with neuroendocrine differentiation
- Well-differentiated neuroendocrine tumor
- Small-cell neuroendocrine carcinoma
- Large cell neuroendocrine carcinoma

## References:

1. Humphrey P, Amin MB, Berney D, Billis A, et al. Acinar adenocarcinoma. In: Moch H, Humphrey PA, Ulbright T, Reuter VE, eds. *Pathology and Genetics: Tumors of the Urinary System and Male Genital Organs*. 4th edition. WHO Classification of Tumors. Zurich, Switzerland: WHO Press; 2015:3-28.

**C. Histologic Grade**Gleason Score

The Gleason grading system is recommended for use in all prostatic specimens containing adenocarcinoma, with the exception of those showing treatment effects, usually in the setting of androgen withdrawal and radiation therapy.<sup>1,2</sup> The Gleason score is an important parameter used in nomograms, such as the Kattan nomograms,<sup>3,4</sup> and the Partin tables,<sup>5</sup> which guide individual treatment decisions. Readers are referred to the recommendations of 2 ISUP consensus conferences dealing with the contemporary usage of the Gleason system (also see Figure 1).<sup>6,7</sup> The Gleason score is the sum of the primary (most predominant in terms of surface area of involvement) Gleason grade and the secondary (second most predominant) Gleason grade. Where no secondary Gleason grade exists, the primary Gleason grade is doubled to arrive at a Gleason score. The primary and secondary grades should be reported in addition to the Gleason score, that is, Gleason score 7(3+4) or 7(3+4). In needle biopsy specimens, Gleason score is the sum of the primary (most predominant) Gleason grade and highest Gleason grade.



**Figure 1.** 2015 modified ISUP Gleason schematic diagram.<sup>7</sup>

In TURP specimens, where there is a minor secondary component (less than 5% of tumor) and where the secondary component is of higher grade, the latter should be reported. For instance, a case showing more than 95% Gleason pattern 3 and less than 5% Gleason pattern 4 should be reported as Gleason score 7(3+4). Conversely, if a minor secondary pattern is of lower grade, it need not be reported. For instance, where there is greater than 95% Gleason pattern 4 and less than 5% Gleason pattern 3, the score should be reported as Gleason score 8(4+4).

In TURP specimens where more than 2 patterns are present, and the worst grade is neither the predominant nor the secondary grade, the predominant and highest grade should be chosen to arrive at a score (eg, 75% pattern 3, 20-25% pattern 4, less than 5% pattern 5 is scored as 3+5=8). This approach has been validated in a large clinical series.<sup>9</sup> The above rules apply to both specimen-level and case-level reporting.

Grade Group

The 9 Gleason scores (2-10) have been variably lumped into different groups for prognosis and patient management purposes. Epstein and associates proposed grouping scores into 5 prognostic categories, grade groups 1-5.<sup>10</sup> This grade grouping, shown below in the table, strongly correlate with biochemical recurrence and have been incorporated into the new Partin tables.<sup>10-12</sup> At the 2014 ISUP Consensus Conference, details of this prognostic system were clarified and it was recommended for usage together with the Gleason system.<sup>7</sup> This grade grouping has also been subsequently validated by other independent studies in surgical and radiation cohorts show significant correlation with survival.<sup>13-15</sup> The new grade grouping has been endorsed in the 2016 WHO classification.<sup>1</sup>

The grade grouping has also been endorsed by ISUP and is referred to as ISUP grade in some publications. Like Gleason scoring in needle biopsies, the grade group can be applied at core, specimen, or case levels.

**Table: Grade Groups**

Grade Group	Gleason Score	Definition
1	Less than or equal to 6	Only individual discrete well-formed glands
2	3+4=7	Predominantly well-formed glands with lesser component of poorly formed/fused/cribriform glands
3	4+3=7	Predominantly poorly formed/fused/cribriform glands with lesser component (#) of well-formed glands
4	4+4=8	Only poorly formed/fused/cribriform glands
	3+5=8	Predominantly well-formed glands and lesser component (##) lacking glands (or with necrosis)
	5+3=8	Predominantly lacking glands (or with necrosis) and lesser component (##) of well-formed glands
5	9-10	Lack gland formation (or with necrosis) with or without poorly formed/fused/cribriform glands (#)

# For cases with greater than 95% poorly formed/fused/cribriform glands on a core or at radical prostatectomy, the component of less than 5% well-formed glands is not factored into the grade; should therefore be graded as grade group 4.

## Poorly formed/fused/cribriform glands can be a more minor component.

Percentage Gleason patterns 4 and 5 (Applicable to Gleason Scores ≥7)

Another recommendation from the 2014 ISUP consensus conference endorsed in the 2016 WHO classification is that the percentage of pattern 4 should be recorded in all Gleason score 7(3+4, 4+3) cases.<sup>1</sup> This measurement further stratifies Gleason score 7 and allows identification of cases with limited pattern 4 (eg, less than 10%) or extensive pattern 4 (eg, greater than 75%).<sup>16,17</sup> This has practical importance since selected patients with Gleason score 7(3+4) but small amounts of pattern 4 (less than or equal to 10%) may be eligible for active surveillance.<sup>18-19</sup>

In tumors with Gleason scores greater than 7, the percentage of patterns 4 and 5 has been shown to be of prognostic significance<sup>16</sup> and may be included in the report. Currently there is no consensus on how the percentage of pattern 4+5 should be recorded although it may be captured in 10% intervals or other stratifications such as less than 5%, 5%-10%, 10%-25%, 25%-50%, 50%-75%, greater than 75%.

## References:

1. Humphrey P, Amin MB, Berney D, Billis A, et al. Acinar adenocarcinoma. In: Moch H, Humphrey PA, Ulbright T, Reuter VE, eds. *Pathology and Genetics: Tumors of the Urinary System and Male Genital Organs*. 4th edition. WHO Classification of Tumors. Zurich, Switzerland: WHO Press; 2015:3-28.
2. Gleason DR, Mellinger GT, the Veterans Administration Cooperative Urological Research Group. Prediction of prognosis for prostate adenocarcinoma by combined histological grading and clinical staging. *J Urol*. 1974;111:58-64.
3. Stephenson AJ, Scardino PT, Eastham JA, et al. Preoperative nomogram predicting the 10-year probability of prostate cancer recurrence after radical prostatectomy. *J Natl Cancer Inst*. 2006;98:715-717.
4. Stephenson AJ, Scardino PT, Eastham JA, et al. Postoperative nomogram predicting the 10-year probability of prostate cancer recurrence after radical prostatectomy. *J Clin Oncol*. 2005;23:7005-7012.
5. Makarov DV, Trock BJ, Humphreys EB, et al. Updated nomogram to predict pathologic stage of prostate cancer given prostate-specific antigen level, clinical stage, and biopsy Gleason score (Partin tables) based on cases from 2000 to 2005. *Urology*. 2007;69:1095-1101.
6. Epstein JI, Allsbrook Jr WC, Amin MB, Egevad L, ISUP Grading Committee. The 2005 International Society of Urological Pathology (ISUP) Consensus Conference on Gleason Grading of Prostatic Carcinoma. *Am J Surg Pathol*. 2005;29:1228-1242.
7. Epstein JI, Egevad L, Amin MB, Delahunt B, Srigley JR, Humphrey PA; and the Grading Committee The 2014 International Society of Urological Pathology (ISUP) Consensus Conference on Gleason Grading of Prostatic Carcinoma: definition of grading patterns and proposal for a new grading system. *Am J Surg Pathol*. 2016; 40: 244-252.
8. Arias-Stella JA 3rd, Shah AB, Montoya-Cerrillo D, Williamson SR, Gupta NS. Prostate biopsy and radical prostatectomy Gleason score correlation in heterogeneous tumors: proposal for a composite Gleason score. *Am J Surg Pathol*. 2015;39(9):1213-1218
9. Patel AA, Chen M-H, Renshaw AA, D'Amico AV. PSA failure following definitive treatment of prostate cancer having biopsy Gleason score 7 with tertiary grade 5. *JAMA*. 2007;298:1533-1538.
10. Pierorazio PM, Walsh PC, Partin AW, Epstein JI. Prognostic Gleason grade grouping: data based on the modified Gleason scoring system. *BJU Int*. 2013;111:753-760.
11. Eifler JB, Feng Z, Lin BM, Partin MT, Humphreys EB, Han M, et al. An updated prostate cancer staging nomogram (Partin tables) based on cases from 2006 to 2011. *BJU Int*. 2013;111:22-29.
12. Epstein JI, Zelefsky MJ, Sjoberg DD, et al. A contemporary prostate cancer grading system: a validated alternative to the Gleason score. *Eur Urol*. 2016;69:428-435.
13. Delahunt B, Egevad L, Srigley JR, et al. Validation of International Society of Urological Pathology (ISUP) grading for prostatic adenocarcinoma in thin core biopsies using TROG 03.04 'RADAR' trial clinical data. *Pathology*. 2015;47:520-525.
14. Samaratinga H, Delahunt B, Gianduzzo T, et al. The prognostic significance of the 2014 International Society of Urological Pathology (ISUP) grading system for prostate cancer. *Pathology*. 2015;47:515-519.
15. Berney DM, Beltran L, Fisher G, et al. Validation of a contemporary prostate cancer grading system using prostate cancer death as outcome. *Br J Cancer*. 2016;114(10):1078-1083.
16. Sauter G, Steurer S, Clauditz TS, et al. Clinical Utility of Quantitative Gleason Grading in Prostate Biopsies and Prostatectomy Specimens. *Eur Urol*. 2016;69:592-598.
17. Choy B, Pearce SM, Anderson BB, et al. Prognostic significance of percentages and architectural types of contemporary Gleason pattern 4 prostate cancer in radical prostatectomy. *Am J Surg Pathol*. 2016;40:1400-6.
18. Morash C, Tey R, Agbassi C, Klotz L, McGowan T, Srigley A, Evans A. Active surveillance for the management of localized prostate cancer: guideline recommendations. *Can Urol J Assoc*. 2015;9(5-6):171-178.
19. Chen RC, Rumble RB, Loblaw DA, et al. Active surveillance for the management of localized prostate cancer (Cancer Care Ontario Guideline): American Society of Clinical Oncology practice guideline endorsement. *J Clin Oncol*. 2016;34(18):2182-2190.

**D. Intraductal Carcinoma (IDC)**

The presence of intraductal carcinoma (IDC) is important to record since it has independent prognostic significance. Intraductal carcinoma is uncommon in needle biopsies and when present is usually found within invasive tumor.<sup>1-3</sup> It is important to distinguish IDC from high-grade prostatic intraepithelial neoplasia. The differential diagnosis of IDC is beyond the scope of this protocol.

Intraductal carcinoma may also be recorded in TURP specimens. IDC in needle biopsies is strongly associated with high Gleason score and high volume tumor in radical prostatectomies and with metastatic disease.<sup>3-5</sup> At the 2014 ISUP consensus conference, it was agreed that Gleason scores or grade groups (ISUP grades) should not be assigned to IDC.<sup>6</sup>

#### References:

1. Guo CC and Epstein JI. Intraductal carcinoma of the prostate on needle biopsy: Histologic features and clinical significance. *Mod Pathol*. 2006;19(12):1528-1535.
2. Cohen RJ, Wheeler TM, Bonkhoff H and Rubin MA. A proposal on the identification, histologic reporting, and implications of intraductal prostatic carcinoma. *Arch Pathol Lab Med*. 2007;131(7):1103-1109.
3. Zhou M. Intraductal carcinoma of the prostate: the whole story. *Pathology*. 2013;45(6):533-539.
4. Zhao T, Liao B, Yao J, et al. Is there any prognostic impact of intraductal carcinoma of prostate in initial diagnosed aggressively metastatic prostate cancer? *Prostate*. 2015;75(3):225-232.
5. Van der Kwast T, Al Daoud N, Collette L, et al. Biopsy diagnosis of intraductal carcinoma is prognostic in intermediate and high risk prostate cancer patients treated by radiotherapy. *Eur J Cancer*. 2012;48(9):1318-1325.
6. Epstein JI, Egevad L, Amin MB, Delahunt B, Srigley JR, Humphrey PA; and the Grading Committee The 2014 International Society of Urological Pathology (ISUP) Consensus Conference on Gleason Grading of Prostatic Carcinoma: definition of grading patterns and proposal for a new grading system. *Am J Surg Pathol*. 2016; 40: 244-252.

#### E. Quantitation of Tumor

Studies have shown prostate cancer volume is a prognostic factor, although the data are conflicting as to its independent prognostic significance.

The designation of the percentage of cancer tissue in transurethral samples is important. When prostate cancer is discovered incidentally (ie, discovered in specimens submitted for clinically benign disease, usually benign prostatic hyperplasia [BPH]), the percentage involvement is used to determine the clinical T1 substage, with less than or equal to 5% involvement being T1a and greater than 5% being T1b. In subtotal and radical prostatectomy specimens, the percentage of tissue involved by tumor can also be “eyeballed” by simple visual inspection.<sup>8</sup> Additionally, in these latter specimens, it may be possible to measure a dominant tumor nodule in at least 2 dimensions<sup>9</sup> and/or to indicate the number of blocks involved by tumor out of the total number of prostatic blocks submitted.

#### References

1. Bismar TA, Lewis JS, JR, Vollmer RT, Humphrey PA. Multiple measures of carcinoma extent versus perineural invasion in prostate needle biopsy tissue in prediction of pathologic stage in a screening population. *Am J Surg Pathol*. 2003;27:432-440.
2. Amin M, Boccon-Gibod L, Egevad L, et al. Prognostic and predictive factors and reporting of prostate carcinoma in prostate needle biopsy specimens. (2004 WHO-sponsored International Consultation Consensus). *Scand J Urol Nephrol*. 2004;39(216 suppl):20-33.
3. Paner GP, Magi-Galluzzi C, Amin MB, Srigley JR: Adenocarcinoma of the prostate. In: Amin MB, Grignon DJ, Srigley JR, Eble JN, eds. *Urological Pathology*. Philadelphia, PA: Lippincott William & Wilkins; 2014:559-673.
4. Amin MB, Lin DW, Gore JL, et al. The critical role of the pathologist in determining eligibility for active surveillance as a management option in patients with prostate cancer: consensus statement with recommendations supported by The College of American Pathologists, International Society of Urological Pathology, Association of Directors of Anatomical and Surgical Pathology, The New Zealand Society of Pathologists and the Prostate Cancer Foundation. *Arch Pathol Lab Med*. 2014;138:1387-1405.
5. Arias-Stella JA 3rd, Varma KR, Montoya-Cerrillo D, Gupta NS, Williamson SR. Does discontinuous involvement of a prostatic needle biopsy core by adenocarcinoma correlate with a large tumor focus at radical prostatectomy? *Am J Surg Pathol*. 2015;39(2):281-286.
6. Karram S, Trock BJ, Netto GJ, Epstein JI. Should intervening benign tissue be included in the measurement of discontinuous foci of cancer on prostate needle biopsy? Correlation with radical prostatectomy findings. *Am J Surg Pathol*. 2011;35(9):1351-1355.



7. Fontugne J, Davis K, Palanisamy N, et al. Clonal evaluation of prostate cancer foci in biopsies with discontinuous tumor involvement by dual ERG/SPINK1 immunohistochemistry. *Mod Pathol.* 2016;29(2):157-165.
8. van der Kwast T, Amin M, Billis A, Epstein J, et al; The ISUP prostate consensus group. International Society of Urological Pathology (ISUP) Consensus Conference on Handling of Radical Prostatectomy Specimens: working group 2: T2 substaging and prostate cancer volume. *Mod Pathol.* 2011;24:16-25.
9. Renshaw AA, Richie JP, Loughlin KR, Jiroutek M, Chung A, D'Amico AV. Maximum diameter of prostatic carcinoma is a simple, inexpensive, and independent predictor of prostate-specific antigen failure in radical prostatectomy specimens: validation in a cohort of 434 patients. *Am J Clin Pathol.* 1999;111:641-644.

#### F. Perineural Invasion

Perineural invasion in core needle biopsies has been associated with extraprostatic extension in some correlative radical prostatectomy studies, although its exact prognostic significance remains unclear.<sup>1-4</sup> Perineural invasion has been found to be an independent risk factor, in some studies, for predicting an adverse outcome in patients treated with external beam radiation,<sup>36</sup> but not for patients treated with brachytherapy or radical prostatectomy.<sup>5</sup> The value of perineural invasion as an independent prognostic factor has been questioned in a multivariate analysis.<sup>4</sup> Presence of perineural invasion may also be reported in TURP specimens.

#### References:

1. Bismar TA, Lewis JS, JR, Vollmer RT, Humphrey PA. Multiple measures of carcinoma extent versus perineural invasion in prostate needle biopsy tissue in prediction of pathologic stage in a screening population. *Am J Surg Pathol.* 2003;27:432-440.
2. Amin M, Boccon-Gibod L, Egevad L, et al. Prognostic and predictive factors and reporting of prostate carcinoma in prostate needle biopsy specimens. (2004 WHO-sponsored International Consultation Consensus). *Scand J Urol Nephrol.* 2004;39(216 suppl):20-33.
3. Paner GP, Magi-Galluzzi C, Amin MB, Srigley JR: Adenocarcinoma of the prostate. In: Amin MB, Grignon DJ, Srigley JR, Eble JN, eds. *Urological Pathology*. Philadelphia, PA: Lippincott William & Wilkins; 2014:559-673.
4. Harnden P, Shelley MD, Clements H, et al. The prognostic significance of perineural invasion in prostatic carcinoma biopsies: a systematic review. *Cancer.* 2007;109:13-24.
5. O'Malley KJ, Pound CR, Walsh PC, Epstein JI, Partin AW. Influence of biopsy perineural invasion on long-term biochemical disease-free survival after radical prostatectomy. *Urology.* 2002;59:85-90.

#### G. Prostatic Intraepithelial Neoplasia

The diagnostic term *prostatic intraepithelial neoplasia* (PIN), unless qualified, refers to high-grade PIN. Low-grade PIN is not reported. The presence of an isolated PIN (PIN in the absence of carcinoma) should be reported in TURP specimens.<sup>1</sup> High-grade PIN in a biopsy without evidence of carcinoma has in the past been a risk factor for the presence of carcinoma on subsequent biopsies, but the magnitude of the risk has diminished, and, in some studies, high-grade PIN was not a risk factor at all.<sup>2,3</sup> More recent data suggests that if high-grade PIN is present in 2 or more sites, there is an increased risk of detecting carcinoma in subsequent biopsies.<sup>4-5</sup>

#### References:

1. Amin M, Boccon-Gibod L, Egevad L, et al. Prognostic and predictive factors and reporting of prostate carcinoma in prostate needle biopsy specimens. (2004 WHO-sponsored International Consultation Consensus). *Scand J Urol Nephrol.* 2004;39(216 suppl):20-33.
2. Gokden N, Roehl KA, Catalona WJ, Humphrey PA. High-grade prostatic intraepithelial neoplasia in needle biopsy as risk factor for detection of adenocarcinoma: current level of risk in screening population. *Urology.* 2005;65:538-542.
3. Epstein JI, Herawi M. Prostate needle biopsies containing prostatic intraepithelial neoplasia or atypical foci suspicious for carcinoma: implications for patient care. *J Urol.* 2006;175:820-834.
4. Merrimen JL, Jones G, Walker D, Leung CS, Kapusta LR, Srigley JR. Multifocal high grade prostatic intraepithelial neoplasia is a significant risk factor for prostatic adenocarcinoma. *J Urol.* 2009;182:485-490.
5. Merrimen JL, Jones G, Srigley JR. Is high grade prostatic intraepithelial neoplasia still a risk factor for adenocarcinoma in the era of extended biopsy sampling? *Pathology.* 2010;42(4):325-329.