

Protocol for the Examination of Specimens From Patients With Melanoma of the Skin

Protocol applies to melanoma of cutaneous surfaces only.

Based on AJCC/UICC TNM, 7th edition
Protocol web posting date: February 2015

Procedures

- Biopsy
- Excision
- Sentinel node examination
- Regional node examination

Authors

David P. Frishberg, MD, FCAP*
Department of Pathology and Laboratory Medicine, Cedars-Sinai Medical Center, Los Angeles, California

Charles Balch, MD
Departments of Surgery, Oncology, and Dermatology, Johns Hopkins University, Baltimore, Maryland

Bonnie L. Balzer, MD, PhD, FCAP
Department of Pathology and Laboratory Medicine, Cedars-Sinai Medical Center, Los Angeles, California

A. Neil Crowson, MD, FCAP
Regional Medical Laboratory, Departments of Dermatology, Pathology and Surgery, University of Oklahoma, Tulsa, Oklahoma

Mukund Didolkar, MD, FACS
Division of Surgical Oncology, Sinai Hospital of Baltimore, Department of Surgery, Johns Hopkins University, Baltimore, Maryland

Alexander Lazar, MD, PhD, FCAP
Department of Pathology and Dermatology, The University of Texas MD Anderson Cancer Center, Houston, Texas

Jennifer M. McNiff, MD, FASCP
Departments of Dermatology and Pathology, Yale University School of Medicine

Roger R Perry, MD, FACS
Department of Surgery, Eastern Virginia Medical School, Norfolk, Virginia

Victor G. Prieto, MD, PhD, FCAP
Departments of Pathology and Dermatology, The University of Texas MD Anderson Cancer Center, Houston, Texas

Priya Rao, MD, FCAP
Department of Pathology, The University of Texas MD Anderson Cancer Center, Houston, Texas

M. Timothy Smith, MD
Department of Pathology and Laboratory Medicine, Medical University of South Carolina, Charleston, South Carolina

Bruce Robert Smoller, MD, FCAP
Department of Pathology, University of Arkansas for Medical Sciences, Little Rock, Arkansas

Mark R. Wick, MD, FCAP
Department of Pathology, University of Virginia Health System, Charlottesville, Virginia

For the Members of the Cancer Committee, College of American Pathologists

* Denotes primary author. All other contributing authors are listed alphabetically.

Previous lead contributors: Charles Balch, MD; Raymond Barnhill, MD; Carolyn Compton, MD, PhD; Mark Wick, MD

© 2015 College of American Pathologists (CAP). All rights reserved.

The College does not permit reproduction of any substantial portion of these protocols without its written authorization. The College hereby authorizes use of these protocols by physicians and other health care providers in reporting on surgical specimens, in teaching, and in carrying out medical research for nonprofit purposes. This authorization does not extend to reproduction or other use of any substantial portion of these protocols for commercial purposes without the written consent of the College.

The CAP also authorizes physicians and other health care practitioners to make modified versions of the Protocols solely for their individual use in reporting on surgical specimens for individual patients, teaching, and carrying out medical research for non-profit purposes.

The CAP further authorizes the following uses by physicians and other health care practitioners, in reporting on surgical specimens for individual patients, in teaching, and in carrying out medical research for non-profit purposes: (1) **Dictation** from the original or modified protocols for the purposes of creating a text-based patient record on paper, or in a word processing document; (2) **Copying** from the original or modified protocols into a text-based patient record on paper, or in a word processing document; (3) The use of a **computerized system** for items (1) and (2), provided that the protocol data is stored intact as a single text-based document, and is not stored as multiple discrete data fields.

Other than uses (1), (2), and (3) above, the CAP does not authorize any use of the Protocols in electronic medical records systems, pathology informatics systems, cancer registry computer systems, computerized databases, mappings between coding works, or any computerized system without a written license from the CAP.

Any public dissemination of the original or modified protocols is prohibited without a written license from the CAP.

The College of American Pathologists offers these protocols to assist pathologists in providing clinically useful and relevant information when reporting results of surgical specimen examinations of surgical specimens. The College regards the reporting elements in the "Surgical Pathology Cancer Case Summary" portion of the protocols as essential elements of the pathology report. However, the manner in which these elements are reported is at the discretion of each specific pathologist, taking into account clinician preferences, institutional policies, and individual practice.

The College developed these protocols as an educational tool to assist pathologists in the useful reporting of relevant information. It did not issue the protocols for use in litigation, reimbursement, or other contexts. Nevertheless, the College recognizes that the protocols might be used by hospitals, attorneys, payers, and others. Indeed, effective January 1, 2004, the Commission on Cancer of the American College of Surgeons mandated the use of the required data elements of the protocols as part of its Cancer Program Standards for Approved Cancer Programs. Therefore, it becomes even more important for pathologists to familiarize themselves with these documents. At the same time, the College cautions that use of the protocols other than for their intended educational purpose may involve additional considerations that are beyond the scope of this document.

The inclusion of a product name or service in a CAP publication should not be construed as an endorsement of such product or service, nor is failure to include the name of a product or service to be construed as disapproval.

CAP Melanoma Protocol Revision History

Version Code

The definition of the version code can be found at www.cap.org/cancerprotocols.

Version: Melanoma 3.3.0.1

Summary of Changes

The following changes have been made since the October 2013 release.

Biopsy, Excision, Re-excision

The following note was added:

Note: For molecular genetic reporting, the CAP Melanoma Biomarker Template should be used. Pending biomarker studies should be listed in the Comments section of this report.

Surgical Pathology Cancer Case Summary

Protocol web posting date: February 2015

MELANOMA OF THE SKIN: Biopsy, Excision, Re-Excision

Select a single response unless otherwise indicated.

Procedure (select all that apply) (Note A)

- Biopsy, shave
 Biopsy, punch
 Biopsy, incisional
 Excision
 Re-excision
 Lymphadenectomy, sentinel node(s)
 Lymphadenectomy, regional nodes (specify): _____
 Other (specify): _____
 Not specified

Specimen Laterality

- Right
 Left
 Midline
 Not specified

Tumor Site (Note B)

- Specify (if known): _____
 Not specified

Tumor Size (required only if tumor is grossly present)

- Greatest dimension: __ cm
 + Additional dimensions: __ x __ cm
 Indeterminate (see "Comment")

Macroscopic Satellite Nodule(s) (required for excision specimens only)

- Not identified
 Present
 Indeterminate

+ Macroscopic Pigmentation

- + Not identified
 + Present, diffuse
 + Present, patchy/focal
 + Indeterminate

Histologic Type (Note C)

- Malignant melanoma
 Melanoma, not otherwise classified
 Superficial spreading melanoma
 Nodular melanoma
 Lentigo maligna melanoma
 Acral-lentiginous melanoma
 Desmoplastic and/or desmoplastic neurotropic melanoma
 Melanoma arising from blue nevus

+ Data elements preceded by this symbol are not required. However, these elements may be clinically important but are not yet validated or regularly used in patient management.

- Melanoma arising in a giant congenital nevus
 Melanoma of childhood
 Nevoid melanoma
 Persistent melanoma
 Other (specify): _____

Maximum Tumor Thickness (Note D)

- Specify: ___ mm
 At least ___ mm (see "Comment")
 Indeterminate (see "Comment")

+ Anatomic Level (Note D)

- I (Melanoma in situ)
 II (Melanoma present in but does not fill and expand papillary dermis)
 III (Melanoma fills and expands papillary dermis)
 IV (Melanoma invades reticular dermis)
 V (Melanoma invades subcutis)

Ulceration (Note E)

- Present
 Not identified
 Indeterminate

Margins (select all that apply) (Note F)Peripheral Margins

- Cannot be assessed
 Uninvolved by invasive melanoma
 Distance of invasive melanoma from closest peripheral margin: ___ mm (required for excisions only)
 Specify location(s), if possible: _____
 Involved by invasive melanoma
 Specify location(s), if possible: _____
 Uninvolved by melanoma in situ
 Distance of melanoma in situ from closest margin: ___ mm (required for excisions only)
 Specify location(s), if possible: _____
 Involved by melanoma in situ
 Specify location(s), if possible: _____

Deep Margin

- Cannot be assessed
 Uninvolved by invasive melanoma
 Distance of invasive melanoma from margin: ___ mm (required for excisions only)
 Involved by invasive melanoma

Mitotic Rate (Note G)

- None identified
 $\geq 1/\text{mm}^2$ (specify number: _____)

Microsatellitosis (Note H)

- Not identified
 Present
 Indeterminate
 Not applicable

Lymph-Vascular Invasion (Note I)

- Not identified
 Present
 Indeterminate

+ Perineural Invasion (Note J)

- + Not identified
 + Present
 + Indeterminate

+ Tumor-Infiltrating Lymphocytes (Note K)

- + Not identified
 + Present, nonbrisk
 + Present, brisk

+ Tumor Regression (Note L)

- + Not identified
 + Present, involving less than 75% of lesion
 + Present, involving 75% or more of lesion
 + Indeterminate

+ Growth Phase (select all that apply) (Note M)

- + Radial
 + Vertical
 + Indeterminate

Lymph Nodes (required only if lymph nodes are present in the specimen) (select all that apply) (Note N)

- Number of sentinel nodes examined: _____
 Total number of nodes examined (sentinel and nonsentinel): _____
 Number of lymph nodes with metastases: _____
 + Extranodal tumor extension:
 + Present
 + Not identified
 + Indeterminate
 + Size of largest metastatic focus: ____ (mm) (for sentinel node)
 + Location of metastatic tumor (for sentinel node)
 + Subcapsular
 + Intramedullary
 + Subcapsular and intramedullary

Pathologic Staging (pTNM) (Note O and Note P)

TNM Descriptors (required only if applicable) (select all that apply)

- m (multiple)
 r (recurrent)
 y (posttreatment)

Primary Tumor (pT)

- pTX: Primary tumor cannot be assessed (eg, shave biopsy or regressed melanoma) (see "Comment")
 pT0: No evidence of primary tumor
 pTis: Melanoma in situ (ie, not an invasive tumor: anatomic level I)
 pT1: Melanoma 1.0 mm or less in thickness, with or without ulceration (see Note D)
 pT1a: Melanoma 1.0 mm or less in thickness, no ulceration, <1 mitoses/mm²
 pT1b: Melanoma 1.0 mm or less in thickness with ulceration and/or 1 or more mitoses/mm²

- pT2: Melanoma 1.01 to 2 mm in thickness, with or without ulceration
 ___ pT2a: Melanoma 1.01 to 2.0 mm in thickness, no ulceration
 ___ pT2b: Melanoma 1.01 to 2.0 mm in thickness, with ulceration
 pT3: Melanoma 2.01 to 4.0 mm in thickness, with or without ulceration
 ___ pT3a: Melanoma 2.01 to 4.0 mm in thickness, no ulceration
 ___ pT3b: Melanoma 2.01 to 4.0 mm in thickness, with ulceration
 pT4: Melanoma greater than 4.0 mm in thickness, with or without ulceration
 ___ pT4a: Melanoma greater than 4.0 mm in thickness, no ulceration
 ___ pT4b: Melanoma greater than 4.0 mm in thickness, with ulceration

Regional Lymph Nodes (pN)

- ___ pNX: Regional lymph nodes cannot be assessed
 ___ pN0: No regional lymph node metastasis
 pN1: Metastasis in 1 regional lymph node
 ___ pN1a: Clinically occult metastasis (micrometastasis)
 ___ pN1b: Clinically apparent metastasis (macrometastasis)
 pN2: Metastasis in 2 to 3 regional nodes or intralymphatic regional metastasis without nodal metastasis
 ___ pN2a: Clinically occult metastasis (micrometastasis)
 ___ pN2b: Clinically apparent metastasis (macrometastasis)
 ___ pN2c: Satellite or in-transit metastasis without nodal metastasis
 ___ pN3: Metastasis in 4 or more regional lymph nodes, or matted metastatic nodes, or in-transit metastasis or satellites(s) with metastasis in regional node(s)

 ___ No nodes submitted or found

Number of lymph nodes identified: _____

Number containing metastases: _____

Matted nodes:

- ___ Present
 ___ Not identified

Distant Metastasis (pM)

- ___ Not applicable
 ___ pM1: Distant metastasis (documented in this specimen)
 + ___ pM1a: Metastasis in skin, subcutaneous tissues, or distant lymph nodes
 + ___ pM1b: Metastasis to lung
 + ___ pM1c: Metastasis to all other visceral sites or distant metastasis at any site associated with an elevated serum lactic dehydrogenase (LDH)
 + Specify site, if known: _____

+ Additional Pathologic Findings (select all that apply)

- + ___ Nevus remnant
 + ___ Other (specify): _____

+ Comment(s)

Note: For molecular genetic reporting, the CAP Melanoma Biomarker Template should be used. Pending biomarker studies should be listed in the Comments section of this report.

Explanatory Notes

A. Procedure

Optimal evaluation of melanocytic lesions requires complete excision that incorporates the full thickness of the involved lesion removed intact.¹ "Shave" procedures that do not include the intact base of the lesion should be avoided. Similarly, "punch" procedures may not include intact lateral borders for assessment of symmetry and lateral circumscription, which can be essential for distinction of melanoma from melanocytic nevus.^{2,3}

The use of frozen sections in biopsies or excisions of melanocytic lesions is strongly discouraged.⁴ Optimal histologic evaluation of cutaneous melanoma requires well-cut, well-stained hematoxylin-and-eosin (H&E) sections prepared from formalin-fixed paraffin-embedded tissue. Frozen sections of sentinel lymph nodes are similarly discouraged, because the manipulation required for intraoperative handling may decrease the sensitivity of the procedure.⁵

B. Anatomic Site

For cutaneous melanoma, prognosis may be affected by primary anatomic site.^{6,7}

C. Histologic Subtypes

The (modified) World Health Organization (WHO) classification⁷ of variants of malignant melanocytic neoplasms of the skin includes the following:

- Superficial spreading melanoma
- Nodular melanoma
- Lentigo maligna melanoma
- Acral lentiginous melanoma
- Mucosal-lentiginous melanoma
- Desmoplastic/neurotropic melanoma
- Melanoma arising from blue nevus
- Melanoma arising from a giant congenital nevus
- Melanoma in childhood
- Nevoid melanoma
- Persistent melanoma
- Melanoma, not otherwise classified

The WHO list is not exhaustive; this protocol does not preclude use of other diagnostic terms, for example, mucosal lentiginous melanoma, a form commonly observed in the vulva.

There is ongoing research to correlate molecular abnormalities in malignant melanoma, particularly *BRAF* mutations, with histologic parameters. Given the wide variety of reported mutations in melanoma⁸ and the lack of predictably effective targeted molecular therapy,⁹ practical application of such morphologic correlates remains an issue for future protocols.

D. Primary Tumor Thickness (Breslow Thickness) and Anatomic (Clark) Levels⁷

Maximum tumor thickness is measured with a calibrated ocular micrometer at a right angle to the adjacent normal skin. The upper point of reference is the granular layer of the epidermis of the overlying skin or, if the lesion is ulcerated, the base of the ulcer. The lower reference point is the deepest point of tumor invasion (ie, the leading edge of a single mass or an isolated group of cells deep to the main mass).

If the tumor is transected by the deep margin of the specimen, the depth may be indicated as "at least ___ mm" with a comment explaining the limitation of thickness assessment.

Clark levels are defined as follows:

- I Intraepidermal tumor only
- II Tumor present in but does not fill and expand papillary dermis
- III Tumor fills and expands papillary dermis

- IV Tumor invades into reticular dermis
- V Tumor invades subcutis

Clark levels were previously a primary requirement for subclassifying pT1 lesions according to the American Joint Committee on Cancer (AJCC) 6th edition TNM classification system and are commonly reported. Anatomic level has been replaced by mitotic rate in the AJCC 7th edition tables for subclassifying pT1 lesions as T1a or T1b, but in the text and in a table comment of the AJCC chapter,¹⁰ Clark level IV or V is referred to as a tertiary criterion for T1b in cases with no ulceration and “if mitotic rate cannot be determined.” Clark level should therefore be reported whenever it would form the basis for upstaging T1 lesions.

The distinction of T1a versus T1b is of significant clinical importance, as the AJCC recommends that sentinel node examination be considered for melanomas stage T1b and above.

E. Ulceration

Ulceration is a dominant prognostic factor in cutaneous melanoma without metastasis,⁶ and if present, changes the pT stage from T1a to T1b. The presence or absence of ulceration must be confirmed on microscopic examination.¹¹ Melanoma ulceration is defined as the combination of the following features: full-thickness epidermal defect (including absence of stratum corneum and basement membrane); evidence of reactive changes (ie, fibrin deposition, neutrophils); and thinning, effacement, or reactive hyperplasia of the surrounding epidermis in the absence of trauma or a recent surgical procedure. Ulcerated melanomas typically show invasion through the epidermis, whereas nonulcerated melanomas tend to lift the overlying epidermis. Overall, for patients with stage I and II melanomas, the 10-year survival rate is 50% if the tumor is ulcerated and 78% if the tumor is not ulcerated.¹² In Cox regression analyses of prognostic factors in cutaneous melanoma that include ulceration, a significantly worse prognosis and a higher risk of metastatic disease have been demonstrated for ulcerated versus non-ulcerated tumors of equivalent thickness.^{6,11}

There is a positive correlation between ulceration and thickness. For ulcerated tumors, the median thickness has been shown to be about 3 mm; for nonulcerated tumors, it is about 1.3 mm. Nevertheless, the adverse prognostic significance of melanoma ulceration has been shown to be independent of tumor thickness. For thin melanomas (1.0 mm or less in thickness), level of invasion is more predictive of survival outcome than ulceration. For melanomas greater than 1.0 mm, ulceration is more predictive than thickness.⁶ Recent studies suggest that ulceration may lose its independent prognostic significance when mitotic rate is taken into account.¹³

F. Margins

Microscopically measured distances between tumor and labeled lateral or deep margins are appropriately recorded for melanoma excision specimens because these neoplasms may demonstrate clinical “satellitosis.” Nevertheless, a “safe minimum” margin has not been established in the literature. If a lateral margin is involved by tumor, it should be stated whether the tumor is in situ or invasive.

G. Mitotic Rate

A mitotic rate of 1 or more mitotic figure per square millimeter is a powerful adverse prognostic factor for cutaneous melanoma¹³ and will upstage pT1 lesions from pT1a to pT1b in the 7th edition of the AJCC staging manual. The AJCC recommended method¹⁰ is provided below:

“The recommended approach to enumerating mitoses is to first find the areas in the dermis containing the most mitotic figures, the so called hot spot. After counting the mitoses in the hot spot, the count is extended to adjacent fields until an area corresponding to 1 mm² is assessed. If no hot spot can be found and mitoses are sparse and randomly scattered throughout the lesion, then a representative mitosis is chosen and beginning with that field the count is then extended to adjacent fields until an area corresponding to 1 mm² is assessed. The count then is expressed as the number of mitoses/mm² (ie, an area corresponding to approximately four high power fields at 400x in most microscopes). To obtain accurate measurement, calibration of individual microscopes is recommended. For classifying thin (≤ 1 mm) melanomas, the threshold for a nonulcerated melanoma to be defined as T1b is ≥ 1 mitoses/mm².

When the invasive component of tumor is < 1 mm² (in area), the number of mitoses present in 1mm² of dermal tissue that includes the tumor should be enumerated and recorded as a number per millimeter

squared. Alternatively, in tumors where the invasive component is $<1 \text{ mm}^2$ in area, the simple presence or absence of a mitosis can be designated as *at least 1/mm²* (ie, "mitogenic") or *0/mm²* (ie, "nonmitogenic"), respectively. At some institutions when mitotic figures are not found after numerous fields are examined, the mitotic count has been described as " $<1/\text{mm}^2$ ". For most tumor registries the designation " $<1/\text{mm}^2$ " equals 0 as has been customarily used in the past. This practice may be continued for historical data. For the future, we urge pathologists to list 0 or 1 or more, and this practice should also be demanded by clinicians.

It is a common and appropriate practice with small, thin melanomas to have the technician place multiple sections cut from the block on a single slide. As a guide, we suggest that no more than two slides with such multiple sections be evaluated so that exhaustive evaluation of the lesion is not performed."

Several points deserve emphasis:

The enumerated mitoses must be melanocytic and *dermal*.

Implied by the "hot spot" method, as applied in the first paragraph above, is that *the identification of even a single mitosis in the dermal component, regardless of the size of that component, is sufficient to report the mitotic rate as greater than or equal to 1 per square millimeter and upstage a thin melanoma to pT1b*. This concept has been more explicitly elaborated upon in a recent paper.¹⁴

The apparent limit on "exhaustive evaluation" is interpreted as indicating that skin specimens containing melanoma should not be processed in a special manner to increase detection of mitoses, but rather should be processed in the same manner as other specimens in that laboratory.

Although the AJCC recommends reporting "0" rather than "none identified" or "less than 1," for the purposes of cancer registry reporting all of these terms should be considered equivalent and equally acceptable.

H. Microsatellitosis

Microsatellitosis is defined as the presence of tumor nests greater than 0.05 mm in diameter, in the reticular dermis, panniculus, or vessels beneath the principal invasive tumor but separated from it by at least 0.3 mm of normal tissue on the section in which the Breslow measurement was taken.¹⁵

See also Note O.

I. Vascular Invasion

At least one study¹⁶ has suggested that vascular invasion by melanoma correlates independently with worsened overall survival.

J. Perineural Invasion

Perineural invasion may be seen in melanoma, particularly desmoplastic-neuroid subtypes.⁷ This feature may correlate with an increased risk for local recurrence. It is suggested that the presence of perineural infiltration be noted in surgical pathology reports on melanomas.

K. Tumor-Infiltrating Lymphocytes

A paucity of tumor-infiltrating lymphocytes (TILs) is an adverse prognostic factor for cutaneous melanoma.¹⁷ Tumor-infiltrating lymphocytes may be assessed in a semiquantitative way, as defined below. To qualify as TILs, lymphocytes need to surround and disrupt tumor cells of the vertical growth phase.

TILs Not Identified: No lymphocytes present, or lymphocytes present but do not infiltrate tumor at all.

TILs Nonbrisk: Lymphocytes infiltrate melanoma only focally or not along the entire base of the vertical growth phase.

TILs Brisk: Lymphocytes diffusely infiltrate the entire base of the vertical growth phase (Figure 1, A) or the entire invasive component of the melanoma (Figure 1, B).

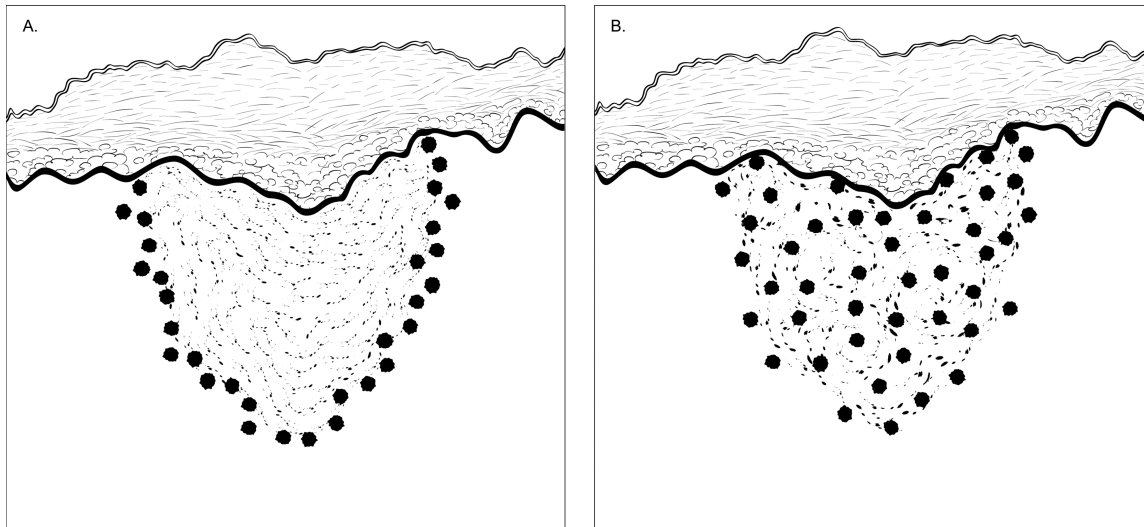


Figure 1. Brisk tumor-infiltrating lymphocytes. A, Lymphocytes diffusely infiltrate the entire base of the vertical growth phase. B, Lymphocytes infiltrate the entire invasive component of the melanoma.

L. Tumor Regression

Characteristic features of regression include replacement of tumor cells by lymphocytic inflammation (definitional), as well as attenuation of the epidermis and nonlaminated dermal fibrosis with inflammatory cells, melanophagocytosis, and telangiectasia.

Complete regression carries adverse prognostic importance in invasive melanomas, as does regression involving more than 75% of the lesion.¹⁷

M. Growth Patterns and Phases

The prognostic significance of histologic type is less significant than the growth patterns and depth of infiltration displayed by those histologic types. For example, superficial spreading melanomas, by definition, demonstrate prominent radial growth and have a better prognosis than nodular melanomas, which predominantly demonstrate vertical growth.¹⁸

Radial Growth Phase: Tumor demonstrates a uniform cytological appearance and is generally wider than it is deep. One commonly applied criterion is presence of melanoma in situ 3 or more rete ridges beyond the invasive component.

Vertical Growth Phase: Vertical growth phase is an adverse prognostic factor for cutaneous melanoma. Nodular melanomas are by definition vertical growth phase tumors. Vertical growth pattern in superficial spreading melanoma is defined as the presence of 1 or more dermal clusters larger than the largest epidermal cluster and/or the presence of any mitotic activity in the dermis.¹⁹

N. Lymph Nodes

Removal of sentinel lymph nodes may be performed for patients with primary localized cutaneous melanomas with a thickness of 1 mm or greater, and recent data indicates that it also may be justified for lesions less than 1 mm thick (incidence of sentinel lymph node metastasis is about 4% to 6% in so-called thin melanomas versus about 15% for melanomas ≥ 1 mm thick).²⁰ Frozen section analysis of sentinel lymph nodes is not advised.⁵ Review of the H&E-stained slides from multiple levels through serially sectioned sentinel lymph nodes increases the sensitivity of detecting microscopic melanoma metastasis; routine analysis (H&E-stained sections of the cut surfaces of a simply bisected lymph node) may lead to a false-negative rate of 10% to 15%. The use of immunohistochemical stains (eg, for HMB-45 or MART-1) further increases the sensitivity of detection of microscopic melanoma metastases and should also be considered in the examination of sentinel lymph nodes. Although immunohistochemical staining should be used in conjunction with and not in place of standard histologic

examination, immunohistochemically identified micrometastases are accepted as representing greater than N0 disease by the 7th edition of the AJCC staging system.¹⁰

For histologic examination, whether for sentinel node analysis or for routine regional lymph node evaluation, the entire node, except tissue collected for consented research protocols, should be submitted. For routine evaluation, large lymph nodes may be bisected or sliced at 2-mm intervals, whereas smaller nodes (<5 mm) may be submitted whole.

A number of studies²¹⁻²³ have suggested the sentinel lymph node tumor burden or the pattern of metastasis in the sentinel node (such as the S Classification)²⁴ may be useful in predicting patients who have additional disease in nonsentinel nodes and thus would help select patients who might benefit from complete lymph node dissection. Investigators have suggested that the amount or pattern of the disease in the sentinel node may also serve as a prognostic factor. If such results are validated and found to be reproducible, then they may be an issue for future protocols.

Although not required for AJCC staging, current National Comprehensive Cancer Network (NCCN) guidelines²⁵ recommend recording the size and location of tumor present in a positive sentinel node. These are included as optional elements in this protocol.

O. TNM and Stage Groupings

The TNM Staging System of the American Joint Committee on Cancer (AJCC) and the International Union Against Cancer (UICC) is recommended by this protocol.^{10,26}

Changes in the 7th edition *AJCC Cancer Staging Manual* of importance to practicing pathologists include:

- Assignment of pT1b status to lesions less than 1mm thick with 1 or more mitoses per mm²
- Relegation of Clark level IV or V to tertiary importance in assignment of pT1b status
- Classification of the presence of any nodal melanoma cells (including isolated tumor cells [ITCs]) as nodal involvement (>pN0)
- Allowing purely immunohistochemical detection of nodal metastasis

Pathologic staging includes microstaging of the primary melanoma and pathologic information about the regional lymph nodes after partial or complete lymphadenectomy.¹⁰

In virtually all studies of cutaneous melanoma, tumor thickness has been shown to be a dominant prognostic factor,^{7,10,16} and it forms the basis for the stratification of pT. Clark levels are also commonly used to indicate depth of invasion of the primary tumor,^{7,10,17,26} but are less predictive of clinical outcome than mitotic activity.²⁰

By AJCC/UICC convention, the designation “T” refers to a primary tumor that has not been previously treated. The symbol “p” refers to the pathologic classification of the TNM, as opposed to the clinical classification, and is based on gross and microscopic examination of surgically removed tissues. pT entails a resection of the primary tumor or biopsy adequate to evaluate the highest pT category, pN entails removal of nodes adequate to validate lymph node metastasis, and pM implies pathologic examination of distant lesions.

T Category Considerations

Pathologic (microscopic) assessment of the primary tumor is required for proper staging. Therefore, excision of the primary tumor, rather than incisional biopsy, is advised. The T classification of melanoma is based on the thickness of the primary tumor, presence or absence of ulceration, mitotic rate, and in some cases its anatomic level of invasion (see also Notes D, E, and G).

N Category Considerations (see also Note N)

The regional lymph nodes are the most common sites of metastasis. The widespread use of cutaneous lymphoscintigraphy, lymphatic mapping, and sentinel lymph node biopsies has greatly enhanced the ability to identify the presence of lymph node metastasis.¹⁰ By convention, the term regional lymph nodal metastasis refers to disease confined to 1 draining nodal basin or 2 contiguous draining nodal basins, as in patients with nodal disease in combinations of femoral/iliac, axillary/supraclavicular, cervical/supraclavicular, axillary/femoral, or bilateral axillary or femoral metastases. Metastasis to nondraining nodal basin(s) is considered M1 disease.

Isolated Tumor Cells, Micrometastasis, and Sentinel Lymph Nodes^{27,28}

The previous edition of this protocol employed the use of ITC terminology analogous to that published for breast cancer. The 7th edition staging system defines nodal involvement by the presence of *any* tumor cells regardless of quantity, size, or mode of detection (ie, >pN0).

Sentinel lymph node identification and evaluation may be included in the surgical approach to cutaneous melanoma. A sentinel lymph node is defined as the first node to receive lymphatic drainage from a primary tumor. There may be more than 1 sentinel node for some tumors. The clinical rationale for sentinel lymph node identification and separate evaluation is based on the assumption that metastatic involvement of a sentinel node increases the likelihood that other, more distant nodes may also contain metastatic disease. Conversely, if sentinel nodes are negative, other regional nodes would be less likely to contain metastasis.

In almost all studies using Cox regression analysis, either the number of regional lymph nodes containing metastases or the percentage of regional nodes containing metastases more strongly predicted outcome than the size of metastasis.^{6,11,29} Patients with 1 involved lymph node have longer survivals compared to patients with any combination of 2 or more involved nodes, regardless of the size of the metastasis. In their review of reported studies, the AJCC Melanoma Staging Committee found no compelling evidence that the gross dimension of lymph nodes metastases was an independent predictor of outcome.³⁰

Micrometastasis versus Macrometastasis¹⁰

The AJCC 7th edition staging system defines *micrometastasis* as nodal metastasis diagnosed after pathologic examination of sentinel lymph node biopsy or completion lymphadenectomy (if performed), in patients without clinical or radiologic evidence of metastasis, ie, “clinically occult.” *Macrometastases* are defined as clinically detectable nodal metastases confirmed by therapeutic lymphadenectomy or when nodal metastasis exhibits gross extracapsular extension. Because complete clinical staging information may not always be available to the pathologist, it may be advisable in cases with bulky nodal disease to add a comment to the report to the effect that if nodal disease was clinically apparent, that upstaging to pN1b or pN2b would be appropriate and that clinical correlation is needed. Centers receiving nodal dissections routinely may wish to make submission of presence or absence of clinical adenopathy part of their standard requisition data.

In-transit metastasis/satellitosis is used in the 7th edition AJCC staging system for definition of N2c disease. Satellitosis by definition occurs within 2 cm of the primary tumor. In-transit metastasis is defined as intralymphatic tumor in skin or subcutaneous tissue more than 2 cm from the primary tumor but not beyond the nearest regional lymph node basin. The presence of in-transit metastasis between the primary tumor and the regional lymph nodes portends a poor prognosis.

The presence of clinical or microscopic satellite lesions around a primary melanoma and in-transit metastases both portend a poor prognosis, and an analysis of the available data by the AJCC Melanoma Staging Committee revealed no significant difference in survival between the two, both of which are associated with a prognosis equivalent to multiple lymph node metastases.¹⁰

M Category Considerations

The category “MX” has been eliminated from the AJCC/UICC TMN system.¹⁰ Unless there is clinical or pathologic evidence of distant metastasis the stage is classified as clinical M0 (ie, no distant metastasis). pM should *only* be reported when metastases have been documented by pathologic examination, that is, pM1 disease. pMX and pM0 should *not* be reported by the pathologist.

Pathologic Stage Groupings

Stage 0	Tis	N0	M0
Stage IA	T1a	N0	M0
Stage IB	T1b	N0	M0
	T2a	N0	M0
Stage IIA	T2b	N0	M0
	T3a	N0	M0

Stage IIB	T3b	N0	M0
	T4a	N0	M0
Stage IIC	T4b	N0	M0
Stage IIIA	T1-4a	N1a	M0
	T1-4a	N2a	M0
Stage IIIB	T1-4b	N1a	M0
	T1-4b	N2a	M0
	T1-4a	N1b	M0
	T1-4a	N2b	M0
	T1-4a	N2c	M0
Stage IIIC	T1-4b	N1b	M0
	T1-4b	N2b	M0
	T1-4b	N2c	M0
Stage IV	Any T	N3	M0
	Any T	Any N	M1

Note that for cutaneous melanoma, clinical and pathologic stage groupings differ for stage III. The complete clinical stage groupings are shown below for comparison.

Clinical Stage Groupings

Stage 0	Tis	N0	M0
Stage IA	T1a	N0	M0
Stage IB	T1b	N0	M0
	T2a	N0	M0
Stage IIA	T2b	N0	M0
	T3a	N0	M0
Stage IIB	T3b	N0	M0
	T4a	N0	M0
Stage IIC	T4b	N0	M0
Stage III	Any T	≥N1	M0
Stage IV	Any T	Any N	M1

TNM Descriptors^{10,26}

For identification of special cases of TNM or pTNM classifications, the “y,” “r,” and “a” prefixes are used. Although they do not affect the stage grouping, they indicate cases needing separate analysis.

Post-therapy stage (yTNM) documents the extent of the disease for patients whose first course of therapy includes systemic or radiation treatment prior to surgical resection or when systemic therapy or radiation is primary treatment with no surgical resection. The extent of disease is classified using the same T, N, and M definitions and identified as post-treatment with a “yc” or “yp” prefix (ycT, ycN, ycTNM; ypT, ypN, ypTNM).

Retreatment classification (rTNM) is used because information gleaned from therapeutic procedures and from extent of disease defined clinically may be prognostic for patients with recurrent cancer after a disease-free interval. It is important to understand that the rTNM classification does not change the original clinical or pathologic staging of the case.

Autopsy classification (aTNM) is used to stage cases of cancer not recognized during life and only recognized postmortem.

Additional Descriptors^{10,26}

Residual Tumor (R)

Tumor remaining in a patient after therapy with curative intent (eg, surgical resection for cure) is categorized by a system known as R classification, as follows.

RX	Presence of residual tumor cannot be assessed
R0	No residual tumor
R1	Microscopic residual tumor
R2	Macroscopic residual tumor

For the surgeon, the R classification may be useful to indicate the known or assumed status of the completeness of a surgical excision. For the pathologist, the R classification is relevant to the status of the margins of a surgical resection specimen. That is, tumor involving the resection margin on pathologic examination may be assumed to correspond to residual tumor in the patient and may be classified as macroscopic or microscopic according to the findings at the specimen margin(s).

Lymph-Vascular Invasion

Lymph-vascular invasion (LVI) indicates whether microscopic lymph-vascular invasion is identified and includes lymphatic invasion, vascular invasion, or lymph-vascular invasion. By AJCC/UICC convention, LVI does not affect the T category indicating local extent of tumor unless specifically included in the definition of a T category.

P. Pretreatment Serum Lactate Dehydrogenase and Serum Albumin

Data from numerous studies have suggested that an elevated serum level of LDH is a stage-independent prognostic factor for decreased survival in melanoma. In these studies, pretreatment LDH elevation has been variably defined as serum levels greater than 200 to 225 U/L or as levels elevated above the reference range of the reference laboratory.^{6,12,31} It is recommended that any elevation above reference range should be checked by repeat LDH testing after at least 24 hours. For stage IV melanoma, a decreased serum albumin level (≤ 3.5 to 4.0 g/dL) has also been shown to be an independent adverse prognostic factor.^{6,12,31}

References

1. Sober AJ, Chuang TY, Duvic M, et al. Guidelines of care for primary cutaneous melanoma. *J Am Acad Dermatol.* 2001;45:579-586.
2. Stell VH, Norton HJ, Smith KS, Salo JC, White RL Jr. Method of biopsy and incidence of positive margins in primary melanoma. *Ann Surg Oncol.* 2007;14:893-898.
3. Sober AJ, Balch CM. Method of biopsy and incidence of positive margins in primary melanoma. *Ann Surg Oncol.* 2007;14:274-275.
4. Smith-Zagone MJ, Schwartz MR. Frozen section of skin specimens. *Arch Pathol Lab Med.* 2005;129:1536-1543.
5. Scolyer RA, Thompson JF, McCarthy SW, Gershenwald JE, Ross MI, Cochran AJ. Intraoperative frozen-section evaluation can reduce accuracy of pathologic assessment of sentinel nodes in melanoma patients. *J Am Coll Surg.* 2005;201:821-823. Author reply: *J Am Coll Surg.* 2005(5);201:823-824.
6. Balch CM, Soong SJ, Gershenwald JE, et al. Prognostic factors analysis of 17,600 melanoma patients: validation of the American Joint Committee on Cancer melanoma staging system. *J Clin Oncol.* 2001;19:3622-3634.
7. LeBoit PE, Weedon D, Sarasin A, eds. *World Health Organization Classification of Tumours: Pathology and Genetics of Skin Tumors.* Lyon, France: IARC Press; 2006.
8. Fecher LA, Cummings SD, Keefe MJ, Alani RM. Toward a molecular classification of melanoma. *J Clin Oncol.* 2007;25:1606-1620.
9. Becker JC, Kirkwood JM, Agarwala SS, Dummer R, Schrama D, Hauschild A. Molecularly targeted therapy for melanoma: current reality and future options. *Cancer.* 2006;107:2317-2327.
10. Edge SB, Byrd DR, Carducci MA, Compton CA, eds. *AJCC Cancer Staging Manual.* 7th ed. New York, NY: Springer; 2009.
11. Balch CM, Buzaid AC, Soong SJ, et al. Final version of the American Joint Committee on Cancer staging system for cutaneous melanoma. *J Clin Oncol.* 2001;19:3635-3648.
12. Balch CM. Cutaneous melanoma: prognosis and treatment results worldwide. *Semin Surg Oncol.* 1992;8:400-414.
13. Barnhill RL, Katzen J, Spatz A, Fine J, Berwick M. The importance of mitotic rate as a prognostic factor for localized cutaneous melanoma. *J Cutan Pathol.* 2005;32:268-273.
14. Piris A, Mihm M, Duncan L. AJCC melanoma staging update: impact on dermatopathology practice and patient management. *J Cutan Pathol.* 2011;38:394-400.

15. Harrist TJ, Rigel DS, Day CL Jr, et al. "Microscopic satellites" are more highly associated with regional lymph node metastases than is primary melanoma thickness. *Cancer*. 1984;53:2183-2187.
16. Straume O, Akslen LA. Independent prognostic importance of vascular invasion in nodular melanomas. *Cancer*. 1996;78:1211-1219.
17. Crowson AN, Magro CM, Mihm MC. Prognosticators of melanoma, the melanoma report, and the sentinel lymph node. *Mod Pathol*. 2006;19(Suppl 2):S71-S87.
18. Balch CM, Murad TM, Soong SJ, Ingalls AL, Halpern NB, Maddox WA. A multifactorial analysis of melanoma: prognostic histopathological features comparing Clark's and Breslow's staging methods. *Ann Surg*. 1978;188:732-742.
19. Lefevre M, Vergier B, Balme B et al. Relevance of vertical growth pattern in thin level II cutaneous superficial spreading melanomas. *Am J Surg Pathol*. 2003;27:717-724.
20. Bedrosian I, Faries MB, Guerry D 4th, et al. Incidence of sentinel node metastasis in patients with thin primary melanoma (≤ 1 mm) with vertical growth phase. *Ann Surg Oncol*. 2000;7:262-267.
21. Gershenwald JE, Andtbacka RH, Prieto VG, et al. Microscopic tumor burden in sentinel lymph nodes predicts synchronous nonsentinel lymph node involvement in patients with melanoma. *J Clin Oncol*. 2008 Sep 10;26(26):4296-4303.
22. van Akkooi AC, Nowecki ZI, Voit C, et al. Sentinel node tumor burden according to the Rotterdam criteria is the most important prognostic factor for survival in melanoma patients: a multicenter study in 388 patients with positive sentinel nodes. *Ann Surg*. 2008;248(6):949-955.
23. Dewar DJ, Newell B, Green MA, Topping AP, Powel B, Cook MG. The microanatomic location of metastatic melanoma in sentinel lymph nodes predicts nonsentinel lymph node involvement. *J Clin Oncol*. 2004 August 15;22:3345-3349.
24. Starz H, Siedlecki K, Balda BR. Sentinel lymphonodectomy and S-Classification: a successful strategy for better prediction and improvement of outcome of melanoma. *Ann Surg Oncol*. 2004;11(3)(suppl):162S-168S.
25. National Comprehensive Cancer Network (NCCN). Melanoma. Available at: http://www.nccn.org/professionals/physician_gls/PDF/melanoma.pdf. Accessed April 3, 2009.
26. Sobin LH, Gospodarowicz M, Wittekind Ch, eds. *UICC TNM Classification of Malignant Tumours*. 7th ed. New York, NY: Wiley-Liss; 2009.
27. Singletary SE, Greene FL, Sobin LH. Classification of isolated tumor cells: clarification of the 6th edition of the American Joint Committee on Cancer Staging Manual. *Cancer*. 2003;98:2740-2741.
28. Scheri RP, Essner R, Turner RR, Ye X, Morton DL. Isolated tumor cells in the sentinel node affect long-term prognosis of patients with melanoma. *Ann Surg Oncol*. 2007;14:2861-2866.
29. Buzaid AC, Tinoco LA, Jendiroba D, et al. Prognostic value of size of lymph node metastases in patients with cutaneous melanoma. *J Clin Oncol*. 1995;13:2361-2368.
30. Schuchter LM. Review of the 2001 AJCC staging system for cutaneous malignant melanoma. *Curr Oncol Rep*. 2001;3:332-337.
31. Eton O, Legha SS, Moon TE, et al. Prognostic factors for survival of patients treated systemically for disseminated melanoma. *J Clin Oncol*. 1998;16:1103-1111.