

Protocol for the Examination of Specimens From Patients With Carcinoma of the Pancreas

Protocol applies to all epithelial tumors of the pancreas, including high-grade neuroendocrine carcinomas. Low-grade neuroendocrine tumors and tumors of the ampulla of Vater are not included.

Based on AJCC/UICC TNM, 7th edition
Protocol web posting date: January 2016

Procedures

- Partial Pancreatectomy
- Pancreaticoduodenectomy (Whipple Resection)
- Total Pancreatectomy

Authors

Kay Washington, MD, PhD *

Department of Pathology, Vanderbilt University Medical Center, Nashville, TN

Jordan Berlin, MD

Department of Medicine, Vanderbilt University Medical Center, Nashville, TN

Philip Branton, MD

Department of Pathology, Inova Fairfax Hospital, Falls Church, VA

Lawrence J. Burgart, MD

Allina Laboratories, Abbott Northwestern Hospital, Minneapolis, MN

David K. Carter, MD

Department of Pathology, St. Mary's/Duluth Clinic Health System, Duluth, MN

Carolyn C. Compton, MD, PhD

Critical Path Institute, Tucson, AZ

Patrick Fitzgibbons, MD

Department of Pathology, St. Jude Medical Center, Fullerton, CA

Wendy L. Frankel, MD

Department of Pathology, Ohio State University Medical Center, Columbus, OH

John Jessup, MD

Division of Cancer Treatment and Diagnosis, National Cancer Institute, Bethesda, MD

Sanjay Kakar, MD

Department of Pathology, University of California San Francisco and the Veterans Affairs Medical Center, San Francisco, CA

Bruce Minsky, MD

Department of Radiation Oncology, University of Chicago, Chicago, IL

Raouf Nakhleh, MD

Department of Pathology, Mayo Clinic, Jacksonville, FL

Laura H. Tang, MD, PhD†

Department of Pathology, Memorial Sloan-Kettering Cancer Center, New York, NY

For the Members of the Cancer Committee, College of American Pathologists

* Denotes primary author. † Denotes senior author. All other contributing authors are listed alphabetically.

Previous contributors: Donald E. Henson, MD; Carlos Fernandez-del Castillo, MD; Andrew L. Warshaw, MD; Christopher Willett, MD

© 2016 College of American Pathologists (CAP). All rights reserved.

The College does not permit reproduction of any substantial portion of these protocols without its written authorization. The College hereby authorizes use of these protocols by physicians and other health care providers in reporting on surgical specimens, in teaching, and in carrying out medical research for nonprofit purposes. This authorization does not extend to reproduction or other use of any substantial portion of these protocols for commercial purposes without the written consent of the College.

The CAP also authorizes physicians and other health care practitioners to make modified versions of the Protocols solely for their individual use in reporting on surgical specimens for individual patients, teaching, and carrying out medical research for non-profit purposes.

The CAP further authorizes the following uses by physicians and other health care practitioners, in reporting on surgical specimens for individual patients, in teaching, and in carrying out medical research for non-profit purposes: (1) **Dictation** from the original or modified protocols for the purposes of creating a text-based patient record on paper, or in a word processing document; (2) **Copying** from the original or modified protocols into a text-based patient record on paper, or in a word processing document; (3) The use of a **computerized system** for items (1) and (2), provided that the protocol data is stored intact as a single text-based document, and is not stored as multiple discrete data fields.

Other than uses (1), (2), and (3) above, the CAP does not authorize any use of the Protocols in electronic medical records systems, pathology informatics systems, cancer registry computer systems, computerized databases, mappings between coding works, or any computerized system without a written license from the CAP.

Any public dissemination of the original or modified protocols is prohibited without a written license from the CAP.

The College of American Pathologists offers these protocols to assist pathologists in providing clinically useful and relevant information when reporting results of surgical specimen examinations of surgical specimens. The College regards the reporting elements in the “Surgical Pathology Cancer Case Summary” portion of the protocols as essential elements of the pathology report. However, the manner in which these elements are reported is at the discretion of each specific pathologist, taking into account clinician preferences, institutional policies, and individual practice.

The College developed these protocols as an educational tool to assist pathologists in the useful reporting of relevant information. It did not issue the protocols for use in litigation, reimbursement, or other contexts. Nevertheless, the College recognizes that the protocols might be used by hospitals, attorneys, payers, and others. Indeed, effective January 1, 2004, the Commission on Cancer of the American College of Surgeons mandated the use of the required data elements of the protocols as part of its Cancer Program Standards for Approved Cancer Programs. Therefore, it becomes even more important for pathologists to familiarize themselves with these documents. At the same time, the College cautions that use of the protocols other than for their intended educational purpose may involve additional considerations that are beyond the scope of this document.

The inclusion of a product name or service in a CAP publication should not be construed as an endorsement of such product or service, nor is failure to include the name of a product or service to be construed as disapproval.

CAP Pancreas (Exocrine) Protocol Revision History

Version Code

The definition of version control and an explanation of version codes can be found at www.cap.org (search: cancer protocol terms).

Version: PancreasExocrine 3.3.0.0

Summary of Changes

The following changes have been made since the October 2013 release.

The following data elements were modified:

- Tumor Size
- Histologic Type
- Microscopic Tumor Extension
- Margins
- Treatment Effect
- Lymph-Vascular Invasion
- Perineural Invasion
- Distant Metastasis (changed to required only if confirmed pathologically)

Surgical Pathology Cancer Case Summary

Protocol web posting date: January 2016

PANCREAS (EXOCRINE): Resection (Note A)

Select a single response unless otherwise indicated.

Specimen (select all that apply)

- Head of pancreas
 Body of pancreas
 Tail of pancreas
 Duodenum
 Stomach
 Common bile duct
 Gallbladder
 Spleen
 Adjacent large vessels
 Portal vein
 Superior mesenteric vein
 Other large vessel (specify): _____
 Other (specify): _____
 Not specified
 Cannot be determined

Procedure

- Pancreaticoduodenectomy (Whipple resection), partial pancreatectomy
 Pancreaticoduodenectomy (Whipple resection), total pancreatectomy
 Partial pancreatectomy, pancreatic body
 Partial pancreatectomy, pancreatic tail
 Other (specify): _____
 Not specified

Tumor Site (select all that apply) (Note B)

- Pancreatic head
 Uncinate process
 Pancreatic body
 Pancreatic tail
 Other (specify): _____
 Cannot be determined
 Not specified

Tumor Size

- Greatest dimension: ___ cm
 + Additional dimensions: ___ x ___ cm
 Cannot be determined (explain): _____

Histologic Type (select all that apply) (Note C)

- Ductal adenocarcinoma
 Colloid carcinoma (mucinous noncystic carcinoma)
 Signet-ring cell carcinoma
 Adenosquamous carcinoma
 Intraductal papillary-mucinous neoplasia with low- or intermediate-grade intraepithelial neoplasia
 Intraductal papillary-mucinous neoplasia with high-grade intraepithelial neoplasia

+ Data elements preceded by this symbol are not required. However, these elements may be clinically important but are not yet validated or regularly used in patient management.

- Intraductal papillary-mucinous neoplasia with an associated invasive carcinoma
- Mucinous cystic neoplasm with low- or intermediate-grade intraepithelial neoplasia
- Mucinous cystic neoplasm with high-grade intraepithelial neoplasia
- Mucinous cystic neoplasm with an associated invasive carcinoma
- High-grade neuroendocrine carcinoma
 - Large cell neuroendocrine carcinoma
 - Small cell neuroendocrine carcinoma
- Undifferentiated (anaplastic) carcinoma
- Undifferentiated carcinoma with osteoclast-like giant cells
- Acinar cell carcinoma
- Acinar cell cystadenocarcinoma
- Serous cystadenocarcinoma
- Mixed acinar-ductal carcinoma
- Mixed ductal-neuroendocrine carcinoma
- Mixed acinar-neuroendocrine carcinoma
- Mixed acinar-neuroendocrine-ductal carcinoma
- Solid-pseudopapillary neoplasm
- Hepatoid carcinoma
- Medullary carcinoma
- Other (specify): _____

Histologic Grade (ductal carcinoma only) (Note D)

- Not applicable
- GX: Cannot be assessed
- G1: Well differentiated
- G2: Moderately differentiated
- G3: Poorly differentiated
- G4: Undifferentiated
- Other (specify): _____

Microscopic Tumor Extension (select all that apply)

- Cannot be assessed
- No evidence of primary tumor
- No invasion (carcinoma in situ/high-grade dysplasia, includes pancreatic high-grade intraepithelial neoplasia)
- Tumor is confined to pancreas
- Tumor invades ampulla of Vater or sphincter of Oddi
- Tumor invades duodenal wall
- Tumor invades peripancreatic soft tissues
 - + Tumor invades retroperitoneal soft tissue
 - + Tumor invades mesenteric adipose tissue
 - + Tumor invades mesocolon
 - + Tumor invades other peripancreatic soft tissue (specify): _____
 - + Tumor invades extrapancreatic common bile duct
- Tumor invades other adjacent organs or structures (specify): _____
- + Tumor involves posterior surface of pancreas
- + Tumor involves anterior surface of pancreas
- + Tumor involves vascular bed/groove (corresponding to superior mesenteric vein/portal vein)

Margins (select all that apply) (Note E)

If all margins uninvolved by invasive carcinoma:

Distance of invasive carcinoma from closest margin: ___ mm or ___ cm

Specify margin: _____

For segmental resection (including distal pancreatectomy) specimens only:

Proximal Pancreatic Parenchymal Margin

- Cannot be assessed
 Uninvolved by pancreatic high-grade intraepithelial neoplasia or invasive carcinoma
 + Distance of invasive carcinoma from margin: ___ mm *or* ___ cm
 Involved by invasive carcinoma
 Involved by pancreatic high-grade intraepithelial neoplasia

Distal Pancreatic Parenchymal Margin (required only if applicable)

- Cannot be assessed
 Uninvolved by invasive carcinoma or high-grade intraepithelial neoplasia
 + Distance of invasive carcinoma from margin: ___ mm *or* ___ cm
 Involved by invasive carcinoma
 Involved by pancreatic high-grade intraepithelial neoplasia

Other Margin(s) (required only if applicable)

- Specify margin(s): _____
 Cannot be assessed
 Uninvolved by invasive carcinoma
 Involved by invasive carcinoma

For pancreaticoduodenal resection specimens only:

Pancreatic Neck/Parenchymal Margin

- Cannot be assessed
 Uninvolved by pancreatic high-grade intraepithelial neoplasia or invasive carcinoma
 + Distance of invasive carcinoma from margin: ___ mm *or* ___ cm
 Involved by invasive carcinoma
 Involved by pancreatic high-grade intraepithelial neoplasia

Uncinate (Retroperitoneal/Superior Mesenteric Artery) Margin

- Cannot be assessed
 Uninvolved by invasive carcinoma
 + Distance of invasive carcinoma from margin: ___ mm *or* ___ cm
 Involved by invasive carcinoma

Bile Duct Margin

- Cannot be assessed
 Uninvolved by high-grade intraepithelial neoplasia or invasive carcinoma
 + Distance of invasive carcinoma from margin: ___ mm *or* ___ cm
 Involved by invasive carcinoma
 Involved by high-grade intraepithelial neoplasia

Proximal Margin (Gastric or Duodenal)

- Cannot be assessed
 Uninvolved by high-grade dysplasia or invasive carcinoma
 Involved by invasive carcinoma

Distal Margin (Distal Duodenal or Jejunal)

- Cannot be assessed
 Uninvolved by high-grade dysplasia or invasive carcinoma
 Involved by invasive carcinoma

Other Margin(s) (required only if applicable)

Specify margin(s): _____

- Cannot be assessed
 Uninvolved by invasive carcinoma
 Involved by invasive carcinoma

Treatment Effect (required only if applicable) (select all that apply) (Note F)

- No prior treatment
 Present
 + No viable cancer cells (complete response, score 0)
 + Single cells or rare small groups of cancer cells (near complete response, score 1)
 + Residual cancer with evident tumor regression, but more than single cells or rare small groups of cancer cells (partial response, score 2)
 Extensive residual cancer with no evident tumor regression (poor or no response, score 3)
 Not known

Lymph-Vascular Invasion (select all that apply) (Note G)

- Not identified
 Present
 + Small vessel lymph-vascular invasion
 + Large vessel (venous) invasion
 Cannot be determined

Perineural Invasion (Note H)

- Not identified
 Present
 Cannot be determined

Pathologic Staging (pTNM) (Note I)TNM Descriptors (required only if applicable) (select all that apply)

- m (multiple primary tumors)
 r (recurrent)
 y (posttreatment)

Primary Tumor (pT)

- pTX: Cannot be assessed
 pT0: No evidence of primary tumor
 pTis: Carcinoma in situ
 pT1: Tumor limited to the pancreas, 2 cm or less in greatest dimension
 pT2: Tumor limited to the pancreas, more than 2 cm in greatest dimension
 pT3: Tumor extends beyond the pancreas but without involvement of the celiac axis or the superior mesenteric artery
 pT4: Tumor involves the celiac axis or the superior mesenteric artery

Regional Lymph Nodes (pN)

- pNX: Cannot be assessed
 pN0: No regional lymph node metastasis
 pN1: Regional lymph node metastasis
 No nodes submitted or found

Number of Lymph Nodes Examined

Specify: _____
 Number cannot be determined (explain): _____

Number of Lymph Nodes Involved

Specify: ____

____ Number cannot be determined (explain): _____

Distant Metastasis (pM) (required only if confirmed pathologically in this case)

____ pM1: Distant metastasis

Specify site(s), if known: _____

+ Additional Pathologic Findings (select all that apply) (Note J)

+ ____ None identified

+ ____ Pancreatic intraepithelial neoplasia (highest grade: PanIN ____)

+ ____ Chronic pancreatitis

+ ____ Acute pancreatitis

+ ____ Other (specify): _____

+ Ancillary Studies (Note K)

+ Specify: _____

+ Clinical History (select all that apply) (Note L)

+ ____ Neoadjuvant therapy

+ ____ Familial pancreatitis

+ ____ Familial pancreatic cancer syndrome

+ ____ Other (specify): _____

+ ____ Not specified

+ Comment(s)

Explanatory Notes

A. Tumors

This protocol applies to epithelial tumors of the exocrine pancreas. It excludes endocrine tumors and tumors of the ampulla of Vater. More than 90% to 95% of malignant tumors of the pancreas are exocrine carcinomas.¹ For these tumors, surgical resection remains the only potentially curative approach, and the prognosis is primarily dependent on the anatomic extent of disease and performance status.²

B. Definition of Location

The anatomic subdivisions defining location of tumors of the pancreas (Figure 1) are as follows³:

- Tumors of the head of the pancreas are those arising to the right of the left border of the superior mesenteric vein. The uncinuate process is part of the head.
- Tumors of the body of the pancreas are those arising between the left border of the superior mesenteric vein and the left border of the aorta.
- Tumors of the tail of the pancreas are those arising between the left border of the aorta and the hilum of the spleen.

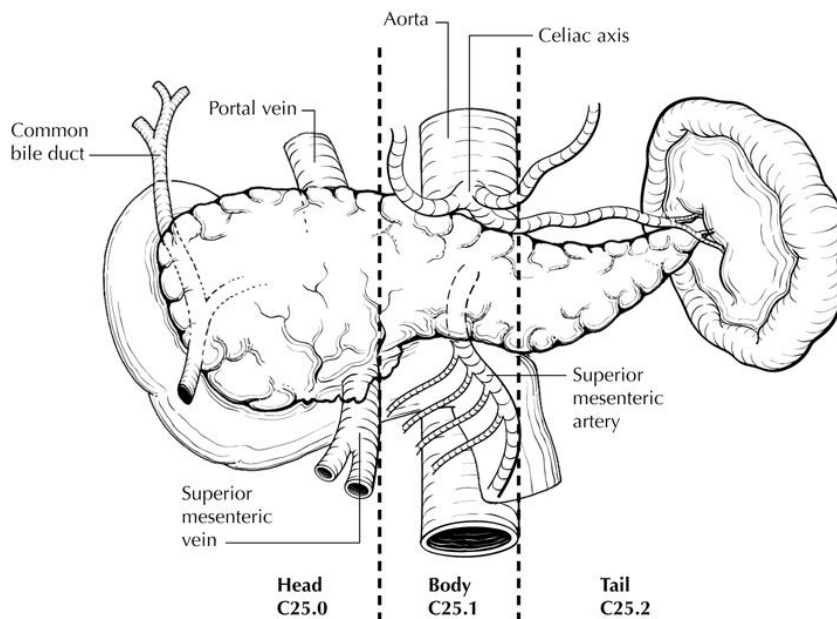


Figure 1. Anatomic subsites of the pancreas. From Greene et al.²¹ Used with permission of the American Joint Committee on Cancer (AJCC), Chicago, Illinois. The original source for this material is the *AJCC Cancer Staging Atlas* (2006) published by Springer Science and Business Media LLC, www.springerlink.com.

C. Histologic Type

A classification of malignant and borderline (uncertain malignant potential) epithelial tumors of the exocrine pancreas recommended by the World Health Organization (WHO) is shown below.⁴ However, this protocol does not preclude the use of other histologic types or systems of classification.

WHO Classification of Epithelial Tumors of the Exocrine Pancreas

Malignant Tumors

Ductal adenocarcinoma

Colloid carcinoma (mucinous noncystic carcinoma)

Signet-ring cell carcinoma[#]

Adenosquamous carcinoma

Mucinous cystic neoplasm with an associated invasive carcinoma
 Mucinous cystic neoplasm with low- or intermediate-grade dysplasia
 Mucinous cystic neoplasm with high-grade dysplasia
 Intraductal papillary-mucinous neoplasia with an associated invasive carcinoma
 Intraductal papillary-mucinous neoplasia with low- or intermediate-grade dysplasia
 Intraductal papillary-mucinous neoplasia with high-grade dysplasia
 Neuroendocrine carcinoma
 Large cell neuroendocrine carcinoma
 Small cell neuroendocrine carcinoma
 Undifferentiated (anaplastic) carcinoma^{##}
 Undifferentiated carcinoma with osteoclast-like giant cells^{##}
 Acinar cell carcinoma^{###}
 Acinar cell cystadenocarcinoma^{###}
 Serous cystadenocarcinoma^{###}
 Mixed acinar-ductal carcinoma
 Mixed ductal-neuroendocrine carcinoma
 Mixed acinar-neuroendocrine carcinoma^{###}
 Mixed acinar-neuroendocrine-ductal carcinoma
 Solid-pseudopapillary neoplasm^{###}
 Hepatoid carcinoma
 Medullary carcinoma

[#] By convention, signet-ring cell carcinomas are assigned grade 3 (see below).

^{##} By definition, undifferentiated carcinomas are grade 4 (see below).

^{###} These histologic types are not usually graded. By definition, neuroendocrine carcinomas are high grade (grade 3) based on WHO M2010 grading scheme for neuroendocrine neoplasms.

D. Histopathologic Grade

For adenocarcinomas, a histologic grade based on the extent of glandular differentiation is suggested, as shown below³:

Grade X	Cannot be assessed
Grade 1	Well differentiated (greater than 95% of tumor composed of glands)
Grade 2	Moderately differentiated (50% to 95% of tumor composed of glands)
Grade 3	Poorly differentiated (49% or less of tumor composed of glands)

Tumors with no differentiation or minimal differentiation that is discernible only in rare, tiny foci (undifferentiated carcinomas by WHO classification) are categorized as grade 4.

For pancreatic ductal carcinoma, histologic grade has been shown to have prognostic significance, with high grade (grades 3 and 4) being an unfavorable prognostic factor.^{5,6} In comparisons between the Klöppel grading system and the TNM grading system, no differences in predictive value have been demonstrated.⁶ Other systems based on patterns of infiltration of predominant and secondary tumor patterns have been proposed⁵ but have not been widely adopted.

E. Margins

The nonperitonealized surface of the uncinate process (uncinate margin) constitutes the inferior-posterior retroperitoneal margin of pancreaticoduodenectomy specimens (Figure 2) and should be inked; sections through the tumor at its closest approach to this margin should be submitted.³ This margin has also been referred to as *retroperitoneal margin* and *superior mesenteric artery margin*.

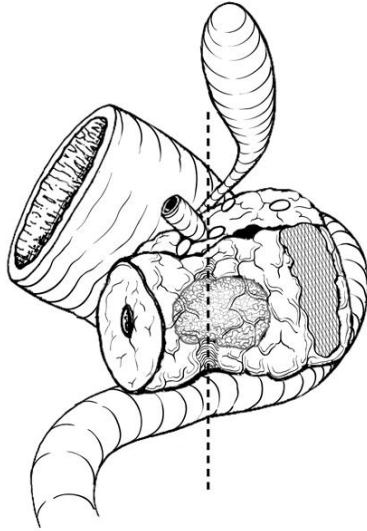


Figure 2. Posterior view of tumor arising in the pancreatic head, with dotted line indicating the location of the confluence of the portal and superior mesenteric veins. The hatched area shows the retroperitoneal (uncinate process) margin. From Greene et al.²¹ Used with permission of the American Joint Committee on Cancer (AJCC), Chicago, Illinois. The original source for this material is the *AJCC Cancer Staging Atlas* (2006) published by Springer Science and Business Media LLC, www.springerlink.com.

Because local recurrences of invasive pancreatic adenocarcinoma arise in the pancreatic bed corresponding to the uncinate margin and vascular groove of portal and superior mesenteric veins, inking of the vascular groove and submission of sections through the tumor at its closest approach to this surface is recommended.

When dealing with an intraductal tumor, the pancreatic (neck/parenchymal) resection margin and the common bile duct margin (Whipple resection) are the most critical. Complete en face sections through the pancreatic resection margin and the common bile duct margin should be taken.

F. Treatment Effect

Response of tumor to previous chemotherapy or radiation therapy should be reported. Several scoring systems have been described, and a modified Ryan scheme⁷ is recommended, as below:

Modified Ryan Scheme for Tumor Regression Score⁷

Description	Tumor Regression Score
No viable cancer cells (complete response)	0
Single cells or rare small groups of cancer cells (near complete response)	1
Residual cancer with evident tumor regression, but more than single cells or rare small groups of cancer cells (partial response)	2
Extensive residual cancer with no evident tumor regression (poor or no response)	3

Sizable pools of acellular mucin may be present after chemoradiation but should not be interpreted as representing residual tumor.

This protocol does not preclude the use of other systems for assessment of tumor response, such as the scheme reported by investigators at MD Anderson Cancer Center.⁸

G. Venous/Lymphatic Vessel Invasion

Venous as well as lymphatic (small vessel) invasion has been shown to be an adverse prognostic factor.⁹

H. Perineural Invasion

Perineural invasion has been shown to be an adverse prognostic factor.⁹

I. TNM and Anatomic Stage/Prognostic Groupings

The TNM staging system for carcinoma of the exocrine pancreas of the American Joint Committee on Cancer (AJCC) and the International Union Against Cancer (UICC) is recommended and shown below.³ The postresection prognosis of a patient with pancreatic carcinoma is primarily determined by the anatomic extent of disease as defined by the TNM stage groupings.^{3,10}

According to AJCC/UICC convention, the designation “T” refers to a primary tumor that has not been previously treated. The symbol “p” refers to the pathologic classification of the TNM, as opposed to the clinical classification, and is based on gross and microscopic examination. pT entails a resection of the primary tumor or biopsy adequate to evaluate the highest pT category, pN entails removal of nodes adequate to validate lymph node metastasis, and pM implies microscopic examination of distant lesions. Clinical classification (cTNM) is usually carried out by the referring physician before treatment during initial evaluation of the patient or when pathologic classification is not possible.

Pathologic staging is usually performed after surgical resection of the primary tumor. Pathologic staging depends on pathologic documentation of the anatomic extent of disease, whether or not the primary tumor has been completely removed. If a biopsied tumor is not resected for any reason (eg, when technically infeasible) and if the highest T and N categories or the M1 category of the tumor can be confirmed microscopically, the criteria for pathologic classification and staging have been satisfied without total removal of the primary cancer.

Primary Tumor[#] (T) (Figures 3 through 5)

TX	Primary tumor cannot be assessed
T0	No evidence of primary tumor
Tis	Carcinoma in situ ^{##}
T1	Tumor limited to the pancreas, 2 cm or less in greatest dimension ^{###}
T2	Tumor limited to the pancreas, more than 2 cm in greatest dimension ^{###}
T3	Tumor extends beyond the pancreas but without involvement of the celiac axis or the superior mesenteric artery [^]
T4	Tumor involves the celiac axis or the superior mesenteric artery (unresectable primary tumor) ^{^^}

[#] If more than 1 tumor is present in the pancreas, the tumor with the highest T category should be classified according to the pT definitions and either the multiplicity (“m”) or the actual number of simultaneous multiple tumors (eg, “3”) should be indicated in parentheses after the T category of the primary tumor (eg, pT3[m] or pT3[2]).

This applies only to grossly recognizable, synchronous primary carcinomas and not to a single, grossly detected tumor with multiple separate microscopic foci.¹¹

Multiple synchronous carcinomas of the exocrine pancreas may be¹¹:

- Multiple noninvasive tumors
- Multiple invasive tumors
- Multiple invasive tumors with associated carcinoma in situ

^{##} PanIN-3 (see Note J) is the equivalent of carcinoma in situ and should be assigned pTis. For invasive carcinoma associated with intraductal papillary mucinous neoplasms and mucinous cystic neoplasms, only the size of the invasive component should be used to determine the T category.

^{###} Tumor size has been shown to have independent prognostic significance.¹²⁻¹⁴

[^] For T3, extension beyond the pancreas may include invasion of soft tissues adjacent to the pancreas, the extrapancreatic biliary system, and/or duodenum (including the ampulla of Vater). Specifically, peripancreatic tissues include the surrounding retroperitoneal fat (retroperitoneal soft tissue), including mesentery (mesenteric fat), mesocolon, greater and lesser omentum, and peritoneum.³

^^ Invasion of the portal vein also has been shown to have independent prognostic significance as an adverse factor.¹⁵

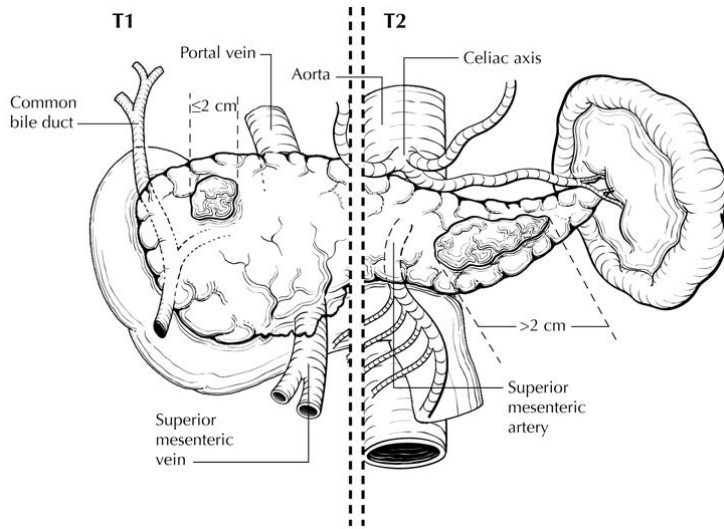
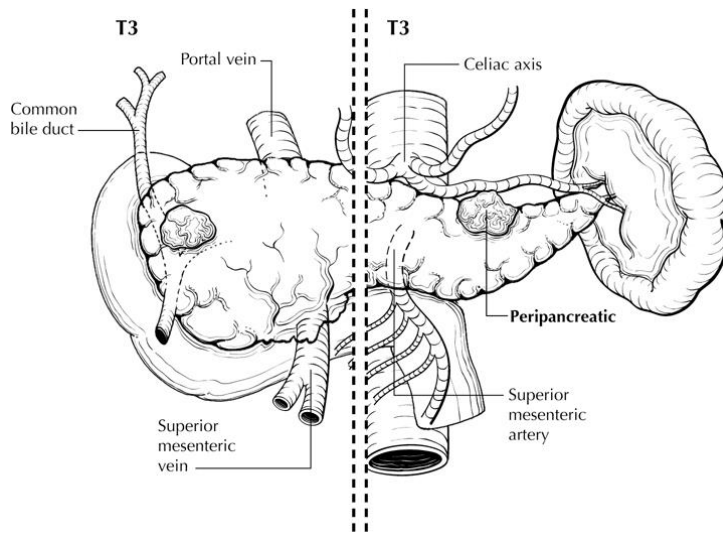
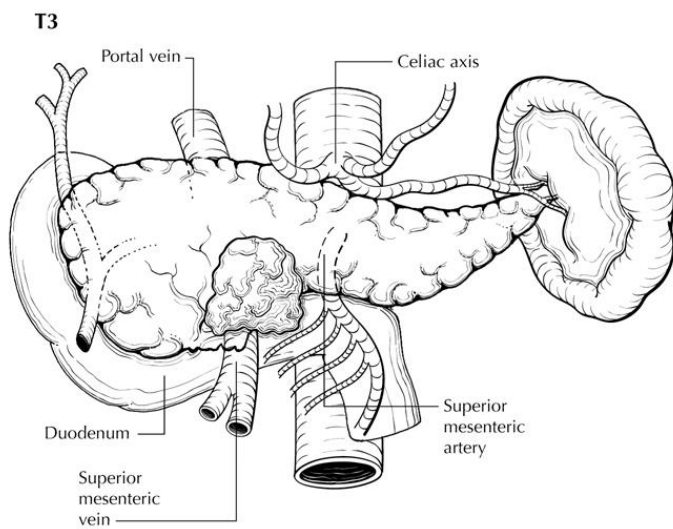


Figure 3. T1 (left of dotted line) is defined as tumor measuring 2 cm or less in greatest dimension and limited to the pancreas. T2 (right of dotted line) is defined as tumor measuring more than 2 cm in greatest dimension and limited to the pancreas. From Greene et al.²¹ Used with permission of the American Joint Committee on Cancer (AJCC), Chicago, Illinois. The original source for this material is the *AJCC Cancer Staging Atlas* (2006) published by Springer Science and Business Media LLC, www.springerlink.com.

A.



B.



C.

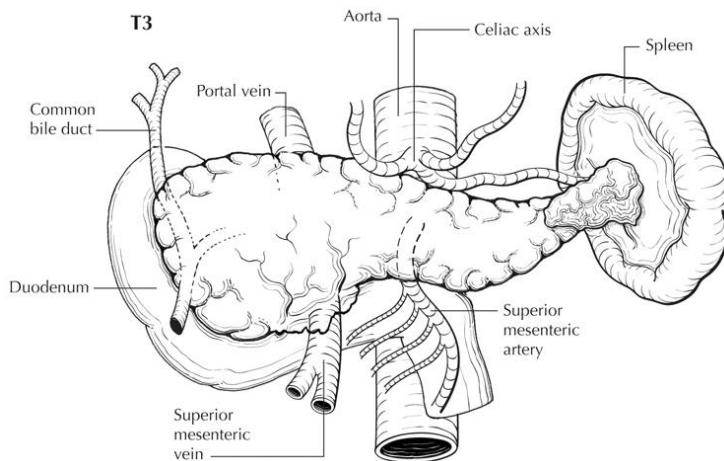


Figure 4. T3 is defined as tumor that extends beyond the pancreas but without involvement of the celiac axis or superior mesenteric artery. A. To the right of the dotted line, tumor invades the peripancreatic tissues without involving the celiac axis. B. Tumor invades duodenum without involvement of superior mesenteric artery. C. Tumor invades spleen without involvement of celiac axis or superior mesenteric artery. From Greene et al.²¹ Used with permission of the American Joint Committee on Cancer (AJCC), Chicago, Illinois. The original source for this material is the *AJCC Cancer Staging Atlas* (2006) published by Springer Science and Business Media LLC, www.springerlink.com.

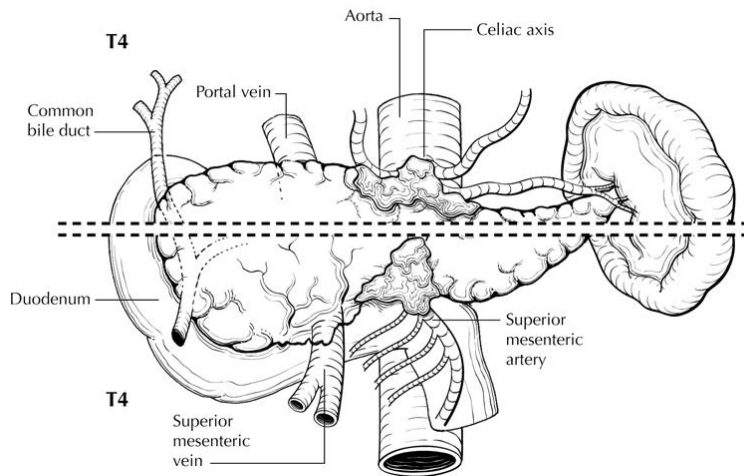


Figure 5. T4 tumor involves the celiac axis (above dotted line) or the superior mesenteric artery (below dotted line). T4 tumors are considered unresectable and are rarely encountered in surgical pathology specimens. From Greene et al.²¹ Used with permission of the American Joint Committee on Cancer (AJCC), Chicago, Illinois. The original source for this material is the *AJCC Cancer Staging Atlas* (2006) published by Springer Science and Business Media LLC, www.springerlink.com.

Regional Lymph Nodes (N)[#]

- NX Regional lymph nodes cannot be assessed
 N0 No regional lymph node metastasis^{##}
 N1 Regional lymph node metastasis^{###}

[#] The regional nodes may be subdivided as follows (Figures 6 and 7):

- Superior Lymph nodes superior to head and body of pancreas
 Inferior Lymph nodes inferior to head and body of pancreas
 Anterior Anterior pancreaticoduodenal, pyloric, and proximal mesenteric lymph nodes
 Posterior Posterior pancreaticoduodenal, common bile duct or pericholedochal, and proximal mesenteric nodes
 Splenic (For tumors in body and tail only) Nodes of the splenic hilum and tail of pancreas

^{##} The following lymph nodes are also considered regional: hepatic artery nodes, infrapyloric nodes (for tumors in head only), subpyloric nodes (for tumors in head only), celiac nodes (for tumors in head only), superior mesenteric nodes, pancreaticolienal nodes (for tumors in body and tail only), splenic nodes (for tumors in body and tail only), retroperitoneal nodes, and lateral aortic nodes. Tumor involvement of other nodal groups is considered distant metastasis.

^{###} The presence of lymph node metastases has been shown to have independent prognostic significance as an adverse factor.^{9,12,14,16-18} A minimum of 15 lymph nodes has been suggested to achieve optimal staging for node-negative pancreatic cancer¹⁹; however, this proposed guideline requires further study before its widespread adoption is recommended.

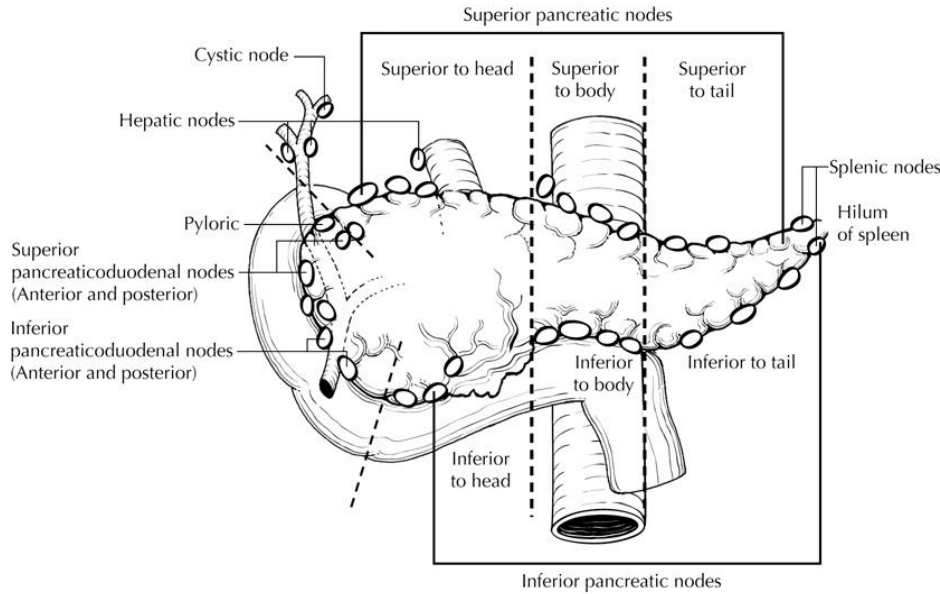


Figure 6. Regional lymph nodes of the pancreas (anterior view). From Greene et al.²¹ Used with permission of the American Joint Committee on Cancer (AJCC), Chicago, Illinois. The original source for this material is the *AJCC Cancer Staging Atlas* (2006) published by Springer Science and Business Media LLC, www.springerlink.com.

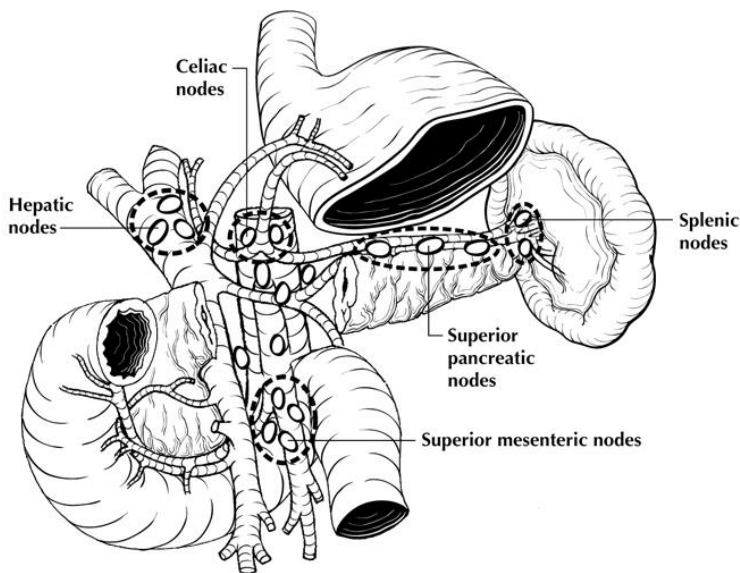


Figure 7. Regional lymph nodes of the pancreas (anterior view with pancreatic body removed to reveal retroperitoneal vessels and lymph nodes). From Greene et al.²¹ Used with permission of the American Joint Committee on Cancer (AJCC), Chicago, Illinois. The original source for this material is the *AJCC Cancer Staging Atlas* (2006) published by Springer Science and Business Media LLC, www.springerlink.com.

Distant Metastasis (M)

- M0 No distant metastasis
- M1 Distant metastasis[#]

[#] Peritoneal seeding or ascitic peritoneal fluid containing cytologic evidence of malignancy is considered M1.¹¹ Positive peritoneal cytology in patients without ascites is also considered M1 because the data suggest that this finding predicts a short survival.³

Stage Groupings

Stage 0	Tis	N0	M0
Stage IA	T1	N0	M0
Stage IB	T2	N0	M0
Stage IIA	T3	N0	M0
Stage IIB	T1	N1	M0
	T2	N1	M0
	T3	N1	M0
Stage III	T4	Any N	M0
Stage IV	Any T	Any N	M1

TNM Descriptors

For identification of special cases of TNM or pTNM classifications, the “m” suffix and “y,” “r,” and “a” prefixes are used. Although they do not affect the stage grouping, they indicate cases needing separate analysis.

The “m” suffix indicates the presence of multiple primary tumors in a single site and is recorded in parentheses: pT(m)NM.

The “y” prefix indicates those cases in which classification is performed during or after initial multimodality therapy (ie, neoadjuvant chemotherapy, radiation therapy, or both chemotherapy and radiation therapy). The cTNM or pTNM category is identified by a “y” prefix. The ycTNM or ypTNM categorizes the extent of tumor actually present at the time of that examination. The “y” categorization is not an estimate of tumor before multimodality therapy (ie, before initiation of neoadjuvant therapy).

The “r” prefix indicates a recurrent tumor when staged after a documented disease-free interval and is identified by the “r” prefix: rTNM.

The “a” prefix designates the stage determined at autopsy: aTNM.

Vessel Invasion

According to AJCC/UICC convention, vessel invasion (lymphatic or venous) does not affect the T category indicating local extent of tumor unless specifically included in the definition of a T category.

J. Additional Pathologic Findings**Pancreatic Intraepithelial Neoplasia (PanIN)**

Noninvasive lesions of the ductal epithelium often are found in the pancreatic parenchyma surrounding ductal adenocarcinoma. These lesions are collectively known as pancreatic intraepithelial neoplasia (PanIN). PanINs have been classified at a National Cancer Institute Think Tank as follows²⁰:

Normal	Nonmucinous flattened or cuboidal epithelium without dysplasia
PanIN-1A	Flat mucinous epithelium without dysplasia
PanIN-1B	Papillary mucinous epithelium without dysplasia
PanIN-2	Flat or papillary mucinous epithelium with mild-to-moderate dysplasia (mild-to-moderate nuclear irregularity, hyperchromasia, and loss of polarity)
PanIN-3	Flat or papillary mucinous epithelium with severe dysplasia (marked nuclear irregularity, hyperchromasia, and loss of polarity), often with cribriforming and intraluminal blebbing (budding off of noncohesive cells)

PanINs are thought to progress from flat to papillary lesions with increasing degrees of dysplasia and increasing numbers of alterations in cancer-associated genes. PanINs are believed to be the precursor lesions of ductal adenocarcinoma of the pancreas. Many of the cytological changes included in the PanIN spectrum are seen in cystic tumors of the pancreas, such as mucinous cystic neoplasms and papillary mucinous neoplasms, but PanINs, by definition, occur in nondilated ducts. A 2-tier system for pancreatic intraepithelial lesion has been proposed, in which low-grade dysplasia would include PanIN-1 and PanIN-2, while high-grade dysplasia would be used for PanIN-3.

PanIN occurring at the resection margins of an otherwise completely resected malignancy should be noted in the pathology report. In this setting, the biologic significance of low-grade PanIN remains unclear, because these ductal changes may be seen in pancreata with benign lesions, but PanIN-3 is the equivalent of carcinoma in situ and should be reported as Tis.

Other Findings

In addition to the examination of other tissues and organs that are part of pancreaticoduodenectomy specimens, pathologic evaluation may also include examination of the gastric antrum for gastritis (eg, *Helicobacter pylori* gastritis or chemical gastritis) and the duodenum for duodenitis, peptic ulcer disease, and ampullitis.

K. Ancillary Studies

No specific molecular or immunohistochemical studies are recommended at this time for pancreatic cancer.

L. Clinical History

Predisposing conditions for pancreatic cancer include familial pancreatic cancer syndromes, which are relatively rare and account for less than 10% of cases.¹ Germline mutations in BRCA2 and p16 have been linked to increased risk, and patients with hereditary pancreatitis have at least a 4-fold higher risk. Preexisting chronic pancreatitis probably accounts for a small minority of cases. Diabetes mellitus and smoking have also been associated with increased risk.

References

1. Hruban RH, Pitman MB, Klimstra DS. *Tumors of the Pancreas*. Fourth Series, Fascicle 6. Washington, DC: Armed Forces Institute of Pathology; 2007.
2. Ghaneh P, Neoptolemos JP. Pancreas cancer. In: Gospodarowicz MK, O'Sullivan B, Sobin LH, eds. *Prognostic Factors in Cancer*. 3rd ed. New York, NY: Wiley-Liss; 2006:153-156.
3. Edge SB, Byrd DR, Carducci MA, Compton CC, eds. *AJCC Cancer Staging Manual*. 7th ed. New York, NY: Springer; 2009.
4. Bosman FT, Carneiro F, Hruban RH, Theise ND, eds. *WHO Classification of Tumours of the Digestive System*. Geneva, Switzerland: WHO Press; 2010.
5. Adsay NV, Basturk O, Bonnett M, et al. A proposal for a new and more practical grading scheme for pancreatic ductal adenocarcinoma. *Am J Surg Pathol*. 2005;29(6):724-733.
6. Giulianotti PC, Boggi U, Fornaciari G, et al. Prognostic value of histological grading in ductal adenocarcinoma of the pancreas: Kloppel vs TNM grading. *Int J Pancreatol*. 1995;17(3):279-289.
7. Ryan R, Gibbons D, Hyland JMP, et al. Pathological response following long-course neoadjuvant chemoradiotherapy for locally advanced rectal cancer. *Histopathology*. 2005;47:141-146.
8. Breslin TM, Hess KR, Harbison DB, et al. Neoadjuvant chemoradiotherapy for adenocarcinoma of the pancreas: treatment variables and survival duration. *Ann Surg Oncol*. 2001;8(2):123-132.
9. Garcea G, Dennison AR, Ong SL, et al. Tumour characteristics predictive of survival following resection for ductal adenocarcinoma of the head of pancreas. *Eur J Surg Onco*. 2007;33(7):892-897.
10. Bilimoria KY, Bentrem DJ, Ko CY, et al. Validation of the 6th edition AJCC Pancreatic Cancer Staging System: report from the National Cancer Database. *Cancer*. 2007;110(4):738-744.
11. Wittekind C, Greene FL, Hutter RVP, Sobin LH, Henson DE, eds. *TNM Supplement: A Commentary on Uniform Use*. 3rd ed. New York, NY: Wiley-Liss; 2003.
12. Lim JE, Chien MW, Earle CC. Prognostic factors following curative resection for pancreatic adenocarcinoma: a population-based, linked database analysis of 396 patients. *Ann Surg*. 2003;237(1):74-85.
13. Matsumoto G, Muta M, Tsuruta K, Horiguchi S, Karasawa K, Okamoto A. Tumor size significantly correlates with postoperative liver metastases and COX-2 expression in patients with resectable pancreatic cancer. *Pancreatol*. 2007;7(2-3):167-173.
14. Moon HJ, An JY, Heo JS, Choi SH, Joh JW, Kim YI. Predicting survival after surgical resection for pancreatic ductal adenocarcinoma. *Pancreas*. 2006;32(1):37-43.
15. Nakagohri T, Kinoshita T, Konishi M, Inoue K, Takahashi S. Survival benefits of portal vein resection for pancreatic cancer. *Am J Surg*. 2003;186(2):149-153.
16. Geer RJ, Brennan MF. Prognostic indicators for survival after resection of pancreatic adenocarcinoma. *Am J Surg*. 1993;165(1):68-73.

17. House MG, Gonen M, Jarnagin WR, et al. Prognostic significance of pathologic nodal status in patients with resected pancreatic cancer. *J Gastrointest Surg.* 2007;11(11):1549-1555.
18. Pawlik TM, Gleisner AL, Cameron JL, et al. Prognostic relevance of lymph node ratio following pancreaticoduodenectomy for pancreatic cancer. *Surgery.* 2007;141(5):610-618.
19. Tomlinson JS, Jain S, Bentrem DJ, et al. Accuracy of staging node-negative pancreas cancer: a potential quality measure. *Arch Surg.* 2007;142(8):767-773; discussion 773-774.
20. Hruban RHMD, Adsay NVMD, Albores-Saavedra JMD, et al. Pancreatic intraepithelial neoplasia: a new nomenclature and classification system for pancreatic duct lesions. *Am J Surg Pathol.* 2001;25:579-586.
21. Greene FL, Compton, CC, Fritz AG, et al, eds. *AJCC Cancer Staging Atlas.* New York, NY: Springer; 2006.