



Protocol for the Examination of Resection Specimens From Patients With Hepatoblastoma

Version: Hepatoblastoma Resection 4.0.0.0 **Protocol Posting Date:** February 2019
Includes the Children’s Oncology Group staging system

Accreditation Requirements

The use of this protocol is recommended for clinical care purposes but is not required for accreditation purposes.

This protocol should be used for the following procedures AND tumor types:

Procedure	Description
Resection	Includes specimens designated lobectomy, segmentectomy, explanted liver, or other
Tumor Type	Description
Hepatoblastoma	Includes pediatric hepatoblastoma

The following should NOT be reported using this protocol:

Procedure
Biopsy (consider Hepatoblastoma Biopsy protocol)
Tumor Type
Other primary malignant hepatic tumors

Authors

Erin Rudzinski, MD*; Sarangarajan Ranganathan, MD*; John Hicks, MD; Grace Kim, MD
With guidance from the CAP Cancer and CAP Pathology Electronic Reporting Committees

* Denotes primary author. All other contributing authors are listed alphabetically.

Important Note

First priority should be given to formalin-fixed tissues for morphologic evaluation. The second priority for tissue processing is snap-freezing up to 1 g (minimum of 100 mg) of tumor from grossly different regions for molecular studies, as well as viable sterile tumor for cytogenetic studies (see Explanatory Note A). Samples from the same foci should be collected for histology, with appropriate identification. Samples of nontumoral liver should be collected for snap-freezing as well.

For more information, contact: The Children’s Oncology Group Biopathology Center; Phone: (614) 722-2890 or (800) 347-2486.

Summary of Changes

v4.0.0.0 - Biopsy and resection procedures separated into individual protocols

Surgical Pathology Cancer Case Summary

Protocol posting date: February 2019

HEPATOBLASTOMA: Resection**Note: This case summary is recommended for reporting Hepatoblastoma but is NOT REQUIRED for accreditation purposes. Core data elements are bolded to help identify routinely reported elements.****Select a single response unless otherwise indicated.****Procedure (Note A)**

- Right lobectomy
 Extended right lobectomy
 Medial segmentectomy
 Left lateral segmentectomy
 Total left lobectomy
 Explanted liver
 Other (specify): _____
 Not specified

Tumor Site

- Right lobe
 Left lobe
 Right and left lobes
 Other (specify): _____
 Not specified

Tumor Size (specify for each nodule)

- Greatest dimension: (centimeters) ___ cm
 Additional dimensions: (centimeters) ___ x ___ cm
 Cannot be determined (explain): _____

Tumor Focality (within liver)

- Unifocal
 Multifocal
 Cannot be determined (explain): _____

Macroscopic Extent of Tumor (select all that apply)

- Tumor confined to liver
 Tumor extends into adjacent organ(s) (specify): _____
 Tumor extends into adjacent soft tissue
 Diaphragm
 Abdominal wall
 Other (specify): _____
 Intraoperative tumor spill
 Gross tumor rupture, preoperative
 Cannot be determined

Histologic Type (select all that apply) (Note B)

- Hepatoblastoma, epithelial type, fetal pattern (mitotically inactive)
 Hepatoblastoma, epithelial type, fetal pattern (mitotically active)
 Hepatoblastoma, epithelial type, embryonal
 Hepatoblastoma, epithelial type, pleomorphic (poorly differentiated)
 Hepatoblastoma, epithelial type, macrotrabecular pattern

- Hepatoblastoma, epithelial type, small cell undifferentiated pattern
Percentage of tumor with small cell undifferentiated pattern (if possible): _____%
- Hepatoblastoma, mesenchymal type without teratoid features
- Hepatoblastoma, mesenchymal type with teratoid features
- Hepatoblastoma, treated
- Hepatoblastoma, other (specify subtypes if not included): _____
- Hepatocellular neoplasm, not otherwise specified

Note: Ancillary studies (immunohistochemistry) may be performed to clarify histologic type.

Preoperative Treatment

- No known preoperative therapy
- Preoperative therapy given
- Not specified

Treatment Effect (Note B)

- Not identified
- Present
Percentage of tumor necrosis: _____%
- Cannot be determined
- Not applicable

Margins (Note C)

Resection Margin

- Cannot be assessed
- Uninvolved by tumor
Distance of tumor from closest margin(s) (centimeters): ____ cm
Specify margin(s): _____
- Involved by tumor
Specify margin(s) _____

Capsular Surface

- Cannot be assessed
- Uninvolved by tumor
Distance of tumor from closest surface centimeters): ____ cm
- Involved by tumor

Lymphovascular Invasion, Macroscopic (select all that apply) (Note D)

- Not identified
- Portal vein invasion present
- Hepatic vein invasion present
- Cannot be determined

Lymphovascular Invasion, Microscopic (Note D)

- Absent
- Present
- Cannot be determined

Regional Lymph Nodes (Note E)

- No nodes submitted or found

Lymph Node Examination (required only if lymph nodes are present in the specimen)

- Number of Lymph Nodes Involved:** _____
- Specify site(s), if known: _____
- Histologic type present (specify): _____

Number of Lymph Nodes Examined: _____

Distant Metastases (if confirmed pathologically in this case) (Note E)

___ Present (includes metastasis to lymph nodes in the following locations: inferior phrenic, distal to hilum, hepatoduodenal ligament, or caval region)

Specify site(s), if known: _____

Histologic type present (specify): _____

Staging (Children's Oncology Group) (select all that apply) (Note F)

Note: Staging is based solely on pretreatment tumor characteristics. Clinical information required to definitively assign stage (eg, intraoperative tumor spill or presence of metastatic disease) may not be available to the pathologist. If applicable, the appropriate stage group may be assigned by the pathologist.

___ Stage I

___ Stage II

+ ___ Microscopic residual tumor present at hepatic resection margin

+ ___ Microscopic residual tumor present at extrahepatic resection margin

+ ___ Intraoperative tumor spill

___ Stage III

+ ___ Macroscopic tumor visible at resection margin(s)

+ ___ Lymph node metastasis present

___ Stage IV

+ ___ Complete resection of primary tumor

+ ___ Incomplete resection of primary tumor

Additional Pathologic Findings (select all that apply) (Note G)

___ No background liver available for evaluation

___ None identified

___ Cirrhosis/fibrosis (specify stage of fibrosis): _____

___ Iron overload

___ Hepatitis (specify type): _____

___ Other (specify): _____

Serum Alpha Fetoprotein (α FP) Level (Note H) _____

Note: Level at time of diagnosis may be prognostically important.

___ less than 100 ng/mL

___ 100 ng/mL – 1.2 million ng/mL

___ greater than 1.2 million ng/ml

___ Not known

Ancillary Studies (select all that apply) (Note I)

___ INI1 immunohistochemistry performed

___ INI1 expression retained

___ INI1 expression lost

___ Glypican-3 immunohistochemistry performed

___ Negative

___ Positive

___ Pattern of staining (specify): _____

___ Beta-catenin immunohistochemistry performed

___ Negative (nuclear)

___ Positive (nuclear)

___ Other (specify): _____

Comment(s)

Explanatory Notes

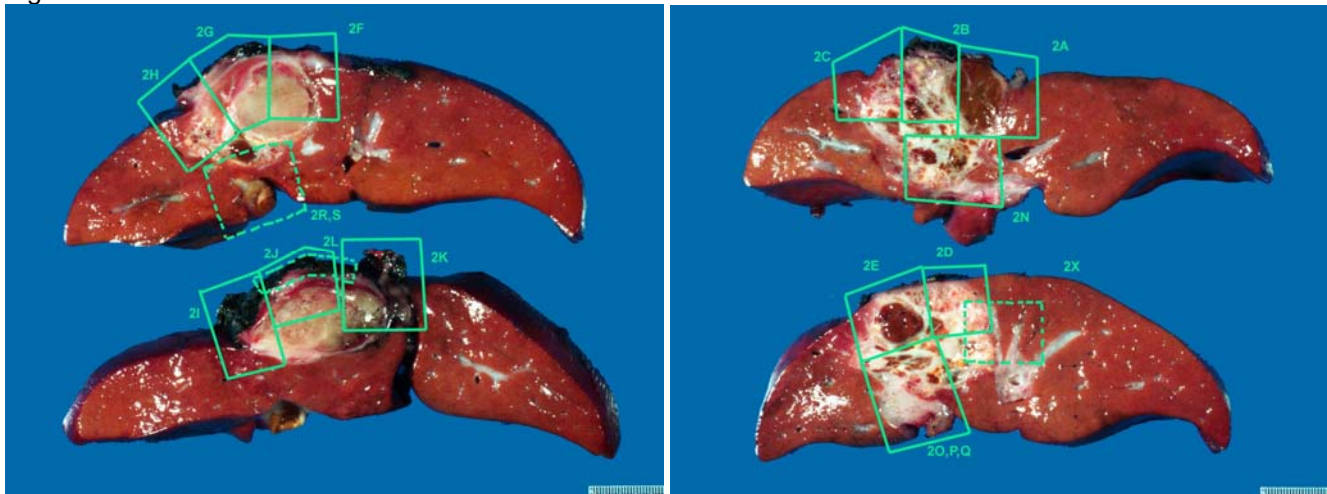
A. Procedures

The various surgical procedures listed include those that attempt primary resection or resection post chemotherapy and the judicious use of transplant where necessary due to overall improved outcome following transplant for nonresectable cases.

Use of intraoperative frozen sections should be avoided unless the operative procedure will be altered by the result. For resection specimens, sections should be prepared from each major tumor nodule, with representative sampling of smaller nodules if macroscopically different in appearance. At least 1 section per centimeter of greatest diameter should be taken to assure detection of areas with unfavorable (eg, small cell undifferentiated) histopathologic features. Sections from the uninvolved background liver, inked margins of resection, as well as portal vein or hepatic vein/inferior vena cava involvement should also be submitted if this feature is seen grossly.

A photographic map of the sections taken is recommended to help the pathologist target areas of interest, especially in postchemotherapy specimens, where most of the tumor may be necrotic. This map also ensures adequate sampling of margins (lobectomy specimen) and hilar and vena caval margins in explants (see Figure 1.). Every attempt should be made, via photographic map or detailed gross description, to document the site of biopsy or specific regions of tumor sampling, including sections from various nodules, because of the possibility of differential histology in the different tumor nodules. While the overall prognosis is determined by several factors, adequate sampling may identify small cell undifferentiated or pleomorphic epithelial components, which may suggest more therapy-resistant clones of tumor.

Figure 1.



Photographic map of liver sections with tumor evident and areas for sectioning marked.

The second priority for tissue processing includes snap-freezing up to 1 gram (minimum of 100 mg) of tumor from regions of different appearance for future molecular studies in resection specimen; viable sterile tumor should be submitted for cytogenetic studies whenever possible. Samples of nontumoral liver should be collected for snap-freezing as well.

B. Histologic Type

Primary malignant tumors of the liver account for approximately 1% of all childhood cancer. The most common type is hepatoblastoma, which has an annual incidence of 0.9 per 1 million children.¹ Not only are hepatoblastomas rare, but their diversity significantly limits the experience of any single center or pathologist. A classification scheme for hepatoblastoma that divides the more frequently or prognostically influential features from infrequent or inconsequential (minor) components is presented in Table 1.² The significance of a biopsy classification is that it reflects the true components of the tumor and is not limited by chemotherapy effects that alter the morphology of these tumors. It should, however, be noted that not all components may necessarily be

sampled in a biopsy, and radiologic features, especially the presence of bone, need to be considered for subtyping.

Table 1. Pediatric Liver Tumors Consensus Classification

Epithelial Tumors - Hepatocellular
Benign and tumor-like conditions
Hepatocellular adenoma (adenomatosis)
Focal nodular hyperplasia
Macroregenerative Nodule
Premalignant lesions
Dysplastic nodules
Malignant
Hepatoblastoma
Epithelial variants
Pure fetal with low mitotic activity
Fetal, mitotically active
Pleomorphic, poorly differentiated
Embryonal
Small-cell undifferentiated
INI1-negative
INI1-positive
Epithelial mixed (any/all above)
Cholangioblastic
Epithelial macrotrabecular pattern
Mixed epithelial and mesenchymal
Without teratoid features
With teratoid features
Hepatocellular carcinoma (HCC)
Classic HCC
Fibrolamellar HCC
Hepatocellular neoplasm, not otherwise specified (NOS)

Modified from Lopez-Terrada et al.²

There is no relationship between the age of the child and the predominant cell type in hepatoblastoma.^{1,3} Of all cases at all ages, 85%-90% contain both fetal and embryonal derivatives in variable proportions; 20% have stromal derivatives. Because these histologic types tend to be randomly intermingled, both fine-needle aspiration and biopsies may capture a nonrepresentative sample of tumor.

The most significant component to identify in a biopsy of a low-stage tumor is well-differentiated fetal histology characterized by uniform-appearing round to polygonal cells with small central nuclei and clear or pale eosinophilic cytoplasm that may give the tumor a light-cell dark-cell pattern.^{1,2} Nucleoli are usually inconspicuous and the mitotic rate is low (less than 2 mitoses per 10 high-power fields), the main criteria for this subtype. If the entire biopsy is composed only of this pattern, the possibility of primary resection should be advocated to minimize the need for chemotherapy if indeed the resected tumor appears histologically uniform. Again, this is only the case with low stage disease; higher stage diseases are likely to have other histologic components that are unsampled. It is important to realize that diagnosis of pure, well-differentiated fetal histology is to be made only on a completely resected tumor where adequate sampling excludes other areas and chemotherapy does not influence the morphology. The current Children's Oncology Group (COG) study is treating stage I well-differentiated fetal hepatoblastoma (with low mitotic rate) with surgery alone.²⁻⁵

Distinguishing well-differentiated (mitotically inactive) fetal hepatoblastoma tumor cells from normal liver in an infant can be difficult. The fetal tumor cells are larger than normal fetal hepatocytes and have a higher nuclear-to-cytoplasmic ratio. The nuclei are regular and round with little discernible mitotic activity (less than 2 mitoses per 10 high-power [X40 objective] fields) in the well-differentiated variety.^{2,5} Fetal tumor cells grow in cords, as in normal liver, or in nests or nodules. Clusters of normoblasts (extramedullary hematopoiesis) are seen, as in fetal liver. The cytoplasm of the fetal tumor cells varies from eosinophilic to clear, depending on the amount of

glycogen content. Fetal tumor cells may also contain abundant lipid, producing vacuolization. In well-differentiated fetal tumors, bile secretion may be observed.

Histologically, the mitotically active fetal pattern shows greater than or equal to 2 mitoses per 10 high-power fields. Cells are arranged in trabeculae with abundant eosinophilic granular cytoplasm and round centrally placed nuclei with indistinct to occasional conspicuous nucleoli. Extramedullary hematopoiesis is frequently encountered in these areas. The embryonal pattern is composed of cells with high nuclear-to-cytoplasmic ratio with oval to angulated nuclei that are hyperchromatic with prominent single nucleoli and scant cytoplasm. Rosettes and tubular structures may be seen in this component. Purely embryonal tumors are almost never encountered and invariably show some fetal areas.

When tumor cells of either fetal or embryonal type show prominent nucleoli and more atypical morphology resembling hepatocellular carcinoma, the term *pleomorphic epithelial* is used. Most instances of these pleomorphic (also previously called *anaplastic fetal*) epithelial components are seen post resection, but one should be aware of this possibility in a biopsy. Arrangement of cells with fetal or embryonal morphology in areas in a trabecular arrangement where trabeculae are greater than 5 cells thick would warrant a description of macrotrabecular arrangement. This modification of cell thickness for plates was introduced in the new consensus classification, as the original 20-cell-thick plates were unusual and may represent hepatocellular carcinomas in a proportion of cases.

The other significant epithelial component that needs to be looked for is the small cell undifferentiated (SCU) pattern.⁶ This is especially true if the entire biopsy or a significant portion of the biopsy shows this morphology. The more common scenario, however, is an epithelial hepatoblastoma with fetal and embryonal areas showing focal aggregates of small cells. These cells have uniform pale nuclei as compared to surrounding darker staining embryonal cells and are arranged in indistinct nests, which can be easily missed on histology. Immunohistochemistry may aid in this diagnosis, and care should be taken to differentiate a predominant SCU pattern from malignant rhabdoid tumor (MRT). Rhabdoid tumor cells have the characteristic, eccentric, pink cytoplasmic inclusions (periodic acid-Schiff/diastase positive, vimentin or cytokeratin positive) with vesicular nuclei and fibrillar inclusion bodies by electron microscopy. They may be associated with the small cell component in otherwise typical hepatoblastomas or as the exclusive cell type, in which case they occur in infancy and are associated with a poor prognosis. The classic rhabdoid tumors show loss of INI1 staining due to *INI1* gene mutation and are treated on the MRT protocol (see Note I).

When first distinguished from embryonal epithelium, small undifferentiated cells in hepatoblastoma were noted to resemble neuroblastoma, to have a low mitotic rate, and were called *anaplastic*, consistent with the dictionary definition, characterized by imperfect development. Because anaplastic was redefined by Faria et al⁷ for Wilms tumor as nuclear enlargement to 3 times that of typical tumor cells, hyperchromasia, and atypical mitoses, the small cell undifferentiated component is no longer designated as anaplastic. Beckwith-type anaplasia does occur rarely in hepatoblastoma, and its significance is unknown. The small cells have been considered putative hepatic progenitor cells on the basis of immunohistochemical and electron microscopic studies. When present in a significant fraction of the hepatoblastoma (75%) or as the sole cell type, the small cell type is typically found in infants younger than 1 year; they have a poor prognosis, with poor response to current therapy. The prognostic significance of smaller proportions of the small cell undifferentiated type is still undetermined. The majority of tumors will show a mixed pattern of components, either epithelial alone or epithelial admixed with mesenchymal and even teratoid components. Even if mesenchymal components are not visualized histologically in a biopsy, radiologic documentation of bone or calcification may reflect a mixed epithelial-mesenchymal hepatoblastoma and help in the differential from other tumors. In some instances, biopsies may reveal primitive spindled cells at the edges of nodules of hepatoblastoma, mimicking small cells, but outside of nodules. These areas represent primitive mesenchyme, sometimes called "blastema" due to their ability to differentiate into epithelial or mesenchymal elements.

Often, mixed hepatoblastomas contain epithelial membrane antigen (EMA)-positive nests of squamous epithelium. The osteoid component of mixed hepatoblastomas is found to be a matrix of collagen surrounding cells expressing EMA and having ultrastructural features of epithelium, rather than osteoblasts. Hepatoblastomas may contain other stromal derivatives, including cartilage and rhabdomyoblasts. There is no prognostic significance to the presence of mixed histologic features.

Other unusual components that may be seen on a biopsy include the cholangioblastic pattern, neuroepithelium, glandular component (intestinal type), and even squamous elements.^{2,8} Retinal pigment or immature neuroepithelial rosettes warrant a diagnosis of teratoid hepatoblastoma. These are usually intermingled with more classic morphology of hepatoblastomas. Teratoid hepatoblastoma was initially depicted as having intestinal, neural, and melanocytic elements. These are distinguished from true teratomas, which can also occur in the livers of children, on the basis of organoid differentiation and even greater diversity of tissue elements in the teratomas. Multinucleated tumor giant cells are found in rare hepatoblastomas, sometimes associated with human chorionic gonadotropin (HCG) production and clinical virilization.

Postchemotherapy resection specimens often show eradication of the embryonal cells and more prevalent osteoid-like foci. Vascular invasion, amount of mesenchyme, persistence of embryonal epithelium, extent of tumor necrosis, and mitotic activity of the epithelial component may have predictive value in this type of specimen. This has yet to be confirmed, but the items should be documented, as should the presence of any small undifferentiated cells, which are known to negatively affect prognosis but may have been missed in the initial biopsies of stage III and IV lesions. Histologic type should therefore be assigned based on the features seen in the current specimen regardless of original diagnosis. With current treatment protocols, postchemotherapy changes may result in complete necrosis, replacement by fibrosis and macrophages, differentiation/maturation of tumor nests to resemble mature hepatocytes within the tumor nodules, and persistence of conventional hepatoblastoma components that can still be recognized, as in a biopsy. There is usually a prominent biliary proliferation separating the treated tumor nodule from adjacent uninvolved liver.⁹ These proliferating ducts need to be distinguished from cholangioblastic areas of hepatoblastoma (usually done with a beta-catenin stain, which shows nuclear staining of tumor versus reactive ducts). The histologic classification of postchemotherapy resection specimens should reflect, where possible, the degree of chemotherapy response, though the significance of this finding is still unknown.

References:

1. Finegold MJ. Hepatic Tumors in Childhood. In: Russo P RE, Piccoli D, eds. *Pathology of Pediatric Gastrointestinal and Liver Disease*. New York, NY: Springer-Verlag; 2004:300-346.
2. Lopez-Terrada D, Alaggio R, de Davila MT, et al. Towards an international pediatric liver tumor consensus classification: proceedings of the Los Angeles COG liver tumors symposium. *Mod Pathol*. 2014;27(3):472-491.
3. Czauderna P, Lopez-Terrada D, Hiyama E, Häberle B, Malogolowkin MH, Meyers RL. Hepatoblastoma state of the art: pathology, genetics, risk stratification, and chemotherapy. *Curr Opin Pediatr*. 2014;26(1):19-28.
4. Meyers RL, Tiao G, de Ville de Goyet J, Superina R, Aronson DC. Hepatoblastoma state of the art: pre-treatment extent of disease, surgical resection guidelines and the role of liver transplantation. *Curr Opin Pediatr*. 2014;26(1):29-36.
5. Malogolowkin MH, Katzenstein HM, Meyers RL, et al. Complete surgical resection is curative for children with hepatoblastoma with pure fetal histology: a report from the Children's Oncology Group. *J Clin Oncol*. 2011;29(24):3301-3306.
6. Trobaugh-Lotrario AD, Tomlinson GE, Finegold MJ, Gore L, Feusner JH. Small cell undifferentiated variant of hepatoblastoma: adverse clinical and molecular features similar to rhabdoid tumors. *Pediatr Blood Cancer*. 2009;52(3):328-334.
7. Faria P, Beckwith JB, Mishra K, et al. Focal versus diffuse anaplasia in Wilms tumor--new definitions with prognostic significance: a report from the National Wilms Tumor Study Group. *Am J Surg Pathol*. 1996;20(8):909-920. Review.
8. Rudzinski ER, Bahrami A, Parham DM, Sebire N. Protocol for the Examination of Specimens from Pediatric Patients with Rhabdomyosarcoma (Version 3.2.0.2) College of American Pathologists, August 2016; (accessed 8/1/2018; available at www.cap.org/cancerprotocols).
9. Wang LL, Filippi RZ, Zurakowski D, et al. Effects of neoadjuvant chemotherapy on hepatoblastoma: a morphologic and immunohistochemical study. *Am J Surg Pathol*. 2010;34(3):287-299.

C. Margins

The evaluation of margins for total or partial hepatectomy specimens depends on the method and extent of resection. It is recommended that the surgeon be consulted to determine the critical foci within the margins that require microscopic evaluation. The transection margin of a partial hepatectomy may be large, rendering it

impractical for complete examination. In this setting, grossly positive margins should be microscopically confirmed and documented. If the margins are grossly free of tumor, judicious sampling of the cut surface in the region closest to the nearest identified tumor nodule is indicated. In selected cases, adequate random sampling of the cut surface may be sufficient. If the neoplasm is found near the surgical margin, the distance from the margin should be reported. For multiple tumors, the distance from the margin to the nearest tumor should be reported.

D. Vascular Invasion

In both the biopsy and resection specimen, assessment of microscopic lymphovascular invasion should be restricted to the parenchyma outside of the tumor nodules. Documentation should include gross vascular invasion versus intravascular growth found only microscopically, and whether it is within the tumor mass or outside of it. Evidence of vascular invasion usually has been associated with a worse outcome, and COG study AHEP0731 is the first study to evaluate the significance prospectively. It is generally believed that vascular invasion is more common with embryonal tumors and tumors with more aggressive phenotypes and may warrant adjuvant therapy to prevent disease spread or recurrence. Large vessel involvement is known to be associated with worse outcome, but microscopic vascular invasion may carry the same significance. Presence or absence of large vessel invasion radiologically is assessed as part of PRETEXT staging of tumors and may preclude the possibility of primary resection of the tumor.

E. Lymph Nodes and Distant Metastases

Histologic examination of a regional lymphadenectomy specimen usually involves examination of 3 or more lymph nodes. The regional lymph nodes of the hepatic region include the hilar, hepatoduodenal ligament, and caval lymph nodes, which are likely to be sampled only at the time of surgical resection or transplant. Nodal involvement of the inferior phrenic lymph nodes or other lymph nodes distal to the hilar, hepatoduodenal ligament, and caval lymph nodes is considered distant metastasis. Presence of distant metastasis is a general contraindication to primary surgery, especially transplantation, and is an indication for biopsy. While the primary tumor is biopsied in most instances, rare cases of biopsy of metastasis may become necessary. The histologic classification will, however, remain the same, though metastatic sites are more likely to show more aggressive histologic patterns, either embryonal, SCU, macrotrabecular, or pleomorphic patterns. An occasional metastasis resected postchemotherapy may show effects of therapy.

F. Staging of Hepatoblastoma

Staging in the United States combines imaging with surgical judgment about resectability.^{1,2} Computed tomography and magnetic resonance imaging are used exclusively in the SIOPEL (Société Internationale D'Oncologie Pédiatrique Liver Tumor Study Group) protocol^{1,3} to determine the location and extent of hepatic involvement of hepatoblastoma preoperatively (PRETEXT) based on Couinaud's system of segmentation of the liver. PRETEXT is based on cross-sectional imaging assessment of the extent of tumor involvement of the 4 main sections of the liver: right posterior section (Couinaud 6, 7); right anterior section (Couinaud 5, 8); left medial section (Couinaud 4a, 4b); left lateral section (Couinaud 2, 3). PRETEXT assignment to 1 of 4 PRETEXT groups (PRETEXT I, II, III, or IV) is determined by the number of contiguous uninvolved sections of the liver. Tumors sparing the left medial and right anterior sectors are primarily resected.

PRETEXT is further annotated with a V, P, E, M, or C, depending upon extension of tumor beyond the hepatic parenchyma of the major sections. Caudate involvement is annotated as 'C'. Tumor extension outside the liver to a contiguous intraabdominal organ (eg, stomach and diaphragm) is annotated as 'E'. Distant metastatic disease (usually lungs) is annotated as 'M'. Major vascular involvement is annotated as 'V' (all 3 hepatic veins or the vena cava) or 'P' (portal bifurcation or the main portal vein). This system is now being adopted by all International Liver Tumor Study groups.

Dissemination of hepatic malignancies occurs within portal veins and follows the expected ready access of infiltration into hepatic veins, with frequent lung involvement. Further spread to the brain may occur. Hilar lymph node metastases are relatively infrequent, but capsular rupture of subcapsular masses either before or during surgery can upstage an otherwise resectable malignancy. Performance of a biopsy prior to chemotherapy does not upstage the tumor. In this setting, COG staging should be applied based on radiographic features at the time of presentation (if available).

The Children's Oncology Group staging system is recommended for hepatoblastomas¹ (staging is performed at

diagnosis, prior to any form of therapy).

- Stage I tumors are completely resected, margins grossly and microscopically negative for tumor.
- Stage II tumors are grossly resected with evidence of microscopic residual tumor. Such tumors are rare, and patients with this stage have not fared differently from those with stage I tumors in previous protocols. Resected tumors with preoperative (intraoperative) rupture are classified as stage II.
- Stage III (unresectable) tumors are those that are considered by the attending surgeon not to be resectable without undue risk to the patient. These include explanted livers as well as partially resected tumors with measurable tumor left behind. They do not include grossly resected tumors with microscopic disease at the margins or resected tumors with preoperative/intraoperative rupture. Lymph node involvement is considered stage III disease and may require evaluation with second laparotomy after an initial 4 courses of chemotherapy.
- Stage IV tumors are those that present with measurable metastatic disease to the lungs or other organ.#

Nodal involvement of the inferior phrenic lymph nodes or other lymph nodes distal to the hilar, hepatoduodenal ligament, or caval lymph nodes are considered distant metastases.

Resectability is the key prognostic feature for all liver malignancies, with the possible exception of rhabdomyosarcoma (see separate College of American Pathologists protocol for rhabdomyosarcoma⁴). Unfortunately, 67% of hepatoblastomas were not amenable to primary surgery (48% stage III and 19% stage IV) in the 16 years of Pediatric Oncology Group/Children's Oncology Group accessions.⁵

References:

1. Czauderna P, Lopez-Terrada D, Hiyama E, Häberle B, Malogolowkin MH, Meyers RL. Hepatoblastoma state of the art: pathology, genetics, risk stratification, and chemotherapy. *Curr Opin Pediatr.* 2014;26(1):19-28.
2. Meyers RL, Tiao G, de Ville de Goyet J, Superina R, Aronson DC. Hepatoblastoma state of the art: pre-treatment extent of disease, surgical resection guidelines and the role of liver transplantation. *Curr Opin Pediatr.* 2014;26(1):29-36.
3. Aronson DC, Schnater JM, Staalman CR, et al. Predictive value of the pretreatment extent of disease system in hepatoblastoma: results from the International Society of Pediatric Oncology Liver Tumor Study Group SIOPEL-1 study. *J Clin Oncol.* 2005;23(6):1245-1252.
4. Rudzinski ER, Bahrami A, Parham DM, Sebire N. Protocol for the Examination of Specimens from Pediatric Patients with Rhabdomyosarcoma (Version 3.2.0.2) College of American Pathologists, August 2016; (accessed 8/1/2018; available at www.cap.org/cancerprotocols).
5. Lopez-Terrada D, Alaggio R, de Davila MT, et al. Towards an international pediatric liver tumor consensus classification: proceedings of the Los Angeles COG liver tumors symposium. *Mod Pathol.* 2014;27(3):472-491.

G. Associated Clinical, Environmental, and Genetic Factors

Clinical Features and Differential Diagnosis

The presenting symptom of virtually all liver tumors in children is abdominal swelling secondary to hepatomegaly. When confronted with this symptom, it is useful to consider the age at which liver tumors tend to occur (see Table 2).¹ Exceptions are frequent, but age can serve as a guide when the presenting symptoms lack specificity. In the Pediatric Oncology Group series from 1986-2002,^{2,3} 66% of hepatoblastomas were manifest by the second year, and 11% before 6 months of age. Approximately 50% of those in infants were congenital, given their size when discovered by 2-3 months of age; 6% of hepatoblastomas occurred after 5 years of age. Hepatocellular carcinomas have been observed as early as 6 months of age. Seven examples of mixed hepatoblastomas and hepatocellular carcinomas have been observed at a mean age of 8.5 years; perinatally acquired hepatitis B virus was responsible in 3 instances. Yolk sac tumors are more common in early childhood, but they also occur rarely in older adults. Systemic malignancies and metastatic disease must be considered at all ages because hepatomegaly due to megakaryoblastic leukemia, Langerhans cell histiocytosis, and neuroblastoma are important sources of confusion with hepatoblastoma in infancy, as are intraabdominal desmoplastic small round cell tumors later in childhood.

Age	Benign	Malignant
Infancy (0-1 y)	Hemangioendothelioma Mesenchymal hamartoma Teratoma	Hepatoblastoma, especially small cell undifferentiated Rhabdoid tumor Yolk sac tumor Langerhans cell histiocytosis Megakaryoblastic leukemia Disseminated neuroblastoma
Early childhood (1-3 y)	Hemangioendothelioma Mesenchymal hamartoma	Hepatoblastoma Rhabdomyosarcoma Inflammatory myofibroblastic (pseudo) tumor
Later childhood (3-10 y)	Perivascular epithelioid cell tumors (PE-Comas), including angiomyolipoma in liver and clear cell tumor of ligamentum teres / falciform ligament	Hepatocellular carcinoma Embryonal (undifferentiated) sarcoma Angiosarcoma Cholangiocarcinoma Endocrine (gastrin) carcinoma
Adolescence (10-16 y)	Adenoma Focal nodular hyperplasia Biliary cystadenoma	Fibrolamellar hepatocellular carcinoma Hodgkin lymphoma Leiomyosarcoma

Environmental Factors

Hepatoblastoma occurs in association with several well-described environmental factors and cancer genetic syndromes (see Table 3); however, not all of these associations are necessarily of statistical significance. Environmental factors and prenatal exposure to different agents have been implicated in hepatoblastoma.^{4,5}

Data from the US National Cancer Institute Surveillance, Epidemiology, and End Result (SEER) program revealed an average annual increase of 5.2% in the incidence of hepatoblastoma from 1973-1992.² This change might be explained by hepatoblastoma occurring in surviving premature infants. Hepatoblastomas in Japan accounted for 58% of all malignancies in children who weighed less than 1000g at birth. Further analysis of the Japanese Children's Cancer Registry data revealed that 15 of 303 (5%) hepatoblastomas between 1985-1995 occurred in infants with a history of prematurity and weight less than 1500g at birth.⁴ This rate was greater than 10 times that for all live births. The histologic features of hepatoblastoma after prematurity are indistinguishable from those of other hepatoblastomas.

The Children's Cancer Group has evaluated environmental or drug exposure. Seventy-five sets of parents of children with hepatoblastoma were compared with the parents of age-matched controls. In the group of children with hepatoblastoma, there was a significant excess of maternal exposure, before and during pregnancy, to metals used in welding and soldering, lubricating oils, and protective greases.⁶ Paternal exposure to metals was also greater.

Table 3. Clinical Syndromes, Congenital Malformations, and Other Conditions Associated With Hepatoblastoma**Congenital Malformations**

Absence of left adrenal gland
 Bilateral talipes
 Duplicated ureters
 Dysplasia of ear lobes
 Cleft palate
 Fetal hydrops
 Hemihypertrophy
 Heterotopic lung tissue
 Horseshoe kidney
 Inguinal hernia
 Intrathoracic kidney
 Macroglossia
 Meckel diverticulum
 Persistent ductus arteriosus
 Renal dysplasia
 Right-sided diaphragmatic hernia
 Single coronary artery
 Umbilical hernia

Syndromes

Beckwith-Wiedemann syndrome
 Beckwith-Wiedemann syndrome with opsoclonus, myoclonus
 Budd-Chiari syndrome
 Familial adenomatous polyposis syndrome
 Li-Fraumeni cancer syndrome
 Polyposis coli families
 Schinzel-Geidion syndrome
 Simpson-Golabi-Behmel syndrome
 Trisomy 18

Metabolic / Pathophysiologic Abnormalities

Cystathioninuria
 Glycogen storage disease types Ia, III, and IV
 Hypoglycemia
 Heterozygous α 1-antitrypsin deficiency
 Isosexual precocity
 Prematurity
 Total parenteral nutrition
 Very low birth weight

Environmental / Other

Alcohol embryopathy
 Human immunodeficiency virus or hepatitis B virus infection
 Maternal clomiphene citrate or Pergonal
 Oral contraceptive, mother
 Oral contraceptive, patient
 Osteoporosis
 Synchronous Wilms tumor

Genetic Factors

Karyotyping of hepatoblastomas has revealed a recurrent pattern of chromosomal abnormalities.⁷ The most common karyotypic changes are extra copies of entire chromosomes (trisomies), sometimes in conjunction with other complex structural changes and often in association with double-minute chromosomes. Trisomies of chromosomes 2 and 20 have each been reported most commonly, and each of these trisomies has been reported as a sole karyotypic event, suggesting that they may represent an early stage of tumor evolution. Trisomy of chromosome 20 and duplication of the long arm of chromosome 20 have also been observed in rhabdomyosarcoma, suggesting a link between these 2 embryonal tumors, both of which are also associated with losses at the Beckwith-Wiedemann syndrome locus.⁸ Trisomy of chromosome 8 is also common; other trisomies are seen with lesser frequency. Occasional losses of entire chromosomes are seen, and these, too, are not random. The clinical significance of trisomies is unknown at present, although a recent study using comparative genomic hybridization has suggested that chromosomal gains at chromosomes 8 and 20 may be associated with an adverse prognosis.⁹

Numerous recent studies have documented molecular genetic abnormalities in hepatoblastomas (see Table 4) and other hepatic tumors. Several genetic changes are shared with other embryonal tumors, such as loss of heterozygosity at chromosome 11p15, also described in rhabdomyosarcomas and Wilms tumors. Acquired mutations of the *APC* gene and the *beta-catenin* gene, both members of the Wnt signaling pathway, have also been reported in hepatoblastoma.⁷⁻¹¹ The high frequency of *beta-catenin* mutations in hepatoblastomas and the increased incidence of hepatoblastomas in familial adenomatous polyposis families suggest the important role of an overactivation of wingless/Wnt pathway in the pathogenesis of hepatoblastoma. Collection of fresh or frozen hepatoblastoma tumor material as well as nontumoral liver tissue from these patients will be of great importance to the further investigation of the clinical relevance of these and other molecular genetic abnormalities in predicting the prognosis and clinical behavior of these tumors.

Disease	Tumor Type	Chromosomal Locus	Gene
Familial adenomatous polyposis	Hepatoblastoma, hepatocellular carcinoma or adenoma, biliary adenoma	5q21.22	<i>APC</i>
Beckwith-Wiedemann syndrome	Hepatoblastoma, hemangioendothelioma	11p15.5	<i>p57KIP2</i> , others
Li-Fraumeni syndrome	Hepatoblastoma, undifferentiated sarcoma	17p13	<i>TP53</i>
Trisomy 18	Hepatoblastoma	18	—
Glycogen storage disease types Ia, III, IV	Hepatocellular adenoma or carcinoma, hepatoblastoma	17	Glucose-6-phosphatase; debrancher and brancher enzymes

References:

1. Malogolowkin MH, Katzenstein HM, Meyers RL, et al. Complete surgical resection is curative for children with hepatoblastoma with pure fetal histology: a report from the Children's Oncology Group. *J Clin Oncol*. 2011;29(24):3301-3306.
2. Ross JA, Gurney JG. Hepatoblastoma incidence in the United States from 1973 to 1992. *Med Pediatr Oncol*. 1998;30(3):141-142.

3. Ortega JA, Douglass EC, Feusner JH, et al. Randomized comparison of cisplatin/vincristine/fluorouracil and cisplatin/continuous infusion doxorubicin for treatment of pediatric hepatoblastoma: a report from the Children's Cancer Group and the Pediatric Oncology Group. *J Clin Oncol*. 2000;18(14):2665-2675.
4. Ikeda H, Hachitanda Y, Tanimura M, Maruyama K, Koizumi T, Tsuchida Y. Development of unfavorable hepatoblastoma in children of very low birth weight: results of a surgical and pathologic review. *Cancer*. 1998;82(9):1789-1796.
5. Spector LG, Birch J. The epidemiology of hepatoblastoma. *Pediatr Blood Cancer*. 2012;59(5):776-779.
6. Buckley JD, Sather H, Ruccione K, et al. A case-control study of risk factors for hepatoblastoma: a report from the Children's Cancer Study Group. *Cancer*. 1989;64:1169-1176.
7. Fletcher JA, Kozakewich HP, Pavelka K, et al. Consistent cytogenetic aberrations in hepatoblastoma: a common pathway of genetic alterations in embryonal liver and skeletal muscle malignancies? *Genes Chromosomes Cancer*. 1991;3(1):37-43.
8. Steenman M, Tomlinson G, Westerveld A, Mannens M. Comparative genomic hybridization analysis of hepatoblastomas: additional evidence for a genetic link with Wilms tumor and rhabdomyosarcoma. *Cytogenet Cell Genet*. 1999;86:157-161.
9. Weber RG, Pietsch T, von Schweinitz D, Lichter P. Characterization of genomic alterations in hepatoblastomas: a role for gains on chromosomes 8q and 20 as predictors of poor outcome. *Am J Pathol*. 2000;157:571-578.
10. Trobaugh-Lotrario AD, Venkatramani R, Feusner JH. Hepatoblastoma in children with Beckwith-Wiedemann syndrome: does it warrant different treatment? *J Pediatr Hematol Oncol*. 2014;36(5):369-373.
11. Jeng YM, Wu MZ, Mao TL, Chang MH, Hsu HC. Somatic mutations of beta-catenin play a crucial role in the tumorigenesis of sporadic hepatoblastoma. *Cancer Lett*. 2000;152(1):45-51.

H. Tumor Markers

Serum α -fetoprotein (α FP) is the most useful indicator of hepatocellular neoplasia. Levels of serum α FP are markedly elevated in 80%-90% of hepatoblastomas and in 60%-70% of hepatocellular carcinomas.^{1,2} Lesser degrees of elevation in infants can be due to variations in the rate of decline after birth or to secretion from regenerating hepatocytes adjacent to hemangioendotheliomas or mesenchymal hamartomas. Therefore, it is unacceptable practice to institute chemotherapy for mass lesions of the liver based solely on imaging studies and serum α FP levels. α FP also can be elevated in yolk sac tumors, which may occur as primary tumors in the liver or together with hepatoblastoma. On the contrary, α FP levels will not be increased when hepatoblastomas are primarily composed of the small cell undifferentiated type or in most fibrolamellar carcinomas, but even some typical fetal hepatoblastomas have failed to produce detectable increases in serum α FP levels. Low α FP levels below 100 ng/dL are therefore considered to be a poor prognostic indication based on a large retrospective review of Children's Hepatic tumor International Collaboration (CHIC) database.²⁻⁵ Following the α FP level in patients with unresectable hepatoblastoma after chemotherapy may have prognostic value.

References:

1. Finegold MJ. Hepatic Tumors in Childhood. In: Russo P RE, Piccoli D, eds. *Pathology of Pediatric Gastrointestinal and Liver Disease*. New York, NY: Springer-Verlag; 2004:300-346.
2. Czauderna P, Lopez-Terrada D, Hiyama E, Häberle B, Malogolowkin MH, Meyers RL. Hepatoblastoma state of the art: pathology, genetics, risk stratification, and chemotherapy. *Curr Opin Pediatr*. 2014;26(1):19-28.
3. Lopez-Terrada D, Alaggio R, de Davila MT, et al. Towards an international pediatric liver tumor consensus classification: proceedings of the Los Angeles COG liver tumors symposium. *Mod Pathol*. 2014;27(3):472-491.
4. Meyers RL, Tiao G, de Ville de Goyet J, Superina R, Aronson DC. Hepatoblastoma state of the art: pre-treatment extent of disease, surgical resection guidelines and the role of liver transplantation. *Curr Opin Pediatr*. 2014;26(1):29-36.
5. Meyers RL, Rowland JR, Krailo M, Chen Z, Katzenstein HM, Malogolowkin MH. Predictive power of pretreatment prognostic factors in children with hepatoblastoma: a report from the Children's Oncology Group. *Pediatr Blood Cancer*. 2009;53(6):1016-1022.

I. Ancillary Studies

Immunohistochemistry may help differentiate hepatoblastoma from normal liver or other hepatocellular tumors, or aid in accurate diagnosis of the various hepatoblastoma subtypes. Staining with glypican-3 has a distinctive pattern with a fine pericanalicular staining seen in cells of the well-differentiated fetal hepatoblastoma, while the

mitotically active fetal subtype and embryonal areas show similar patterns of coarse granular cytoplasmic staining. Small cell undifferentiated, cholangioblastic, and mesenchymal components are negative for glypican-3. Most teratoid components are also negative, except for an occasional glandular/yolk sac-like component that may show positive staining.

Beta-catenin staining is more variable. Rare pediatric hepatocellular carcinomas can show strong positive staining, as can nested epithelial-stromal tumors. The tumor currently considered under the rubric of hepatocellular neoplasms, NOS in the consensus classification also show nuclear beta-catenin staining despite morphologic overlap with features of hepatocellular carcinomas. At present, there is no immunostain to differentiate hepatocellular carcinoma from hepatoblastoma with confidence, though in general most pediatric hepatocellular carcinomas do not show the same intense nuclear staining as hepatoblastomas. Beta-catenin staining is usually associated with strong glutamine synthetase and cyclin D1 staining in hepatoblastomas. Possible genetic markers (trisomies for chromosomes 2, 20, and 8; abnormalities of chromosome 1p) are being investigated and may help differentiate these 2 entities, but only approximately 35%-40% of hepatoblastomas carry the abnormalities.¹

Immunohistochemistry with glypican-3, beta-catenin, and glutamine synthetase (GS) aids in distinguishing hepatoblastoma from normal liver. Normal fetal liver is negative for glypican and shows only pericentral hepatocyte staining while staining diffusely in the tumor cells. Nuclear beta-catenin is only seen in tumor. Immunohistochemistry may be useful for identifying the small cell component of hepatoblastoma, as well. The small cells usually stain strongly and uniformly with beta-catenin in a nuclear pattern and are negative for glypican-3. This is in contrast to embryonal and fetal cells, which are cytoplasmic glypican-3 positive in most instances and show variable nuclear beta-catenin. The SCU component may also stain for vimentin and cytokeratin.

Evaluation of the SCU component with an INI1 stain is critical, particularly if the SCU component forms a significant portion of the biopsy. Any loss of INI1 in the SCU component may warrant reclassification on review as a malignant rhabdoid tumor with a different Children's Oncology Group treatment protocol. While this loss of INI1 is unusual in the usual SCU components that form small foci in between other epithelial components, it is prudent to do the stain and report the findings. Interestingly, stain for INI1 may be stronger in the nuclei of SCU component than surrounding cells; the significance of this is still to be determined.

It is also important to realize that fetal pattern hepatoblastoma may resemble the fetal hepatocytes trapped in benign liver tumors, such as mesenchymal hamartoma (MH) and infantile hemangioma (IH), and this needs to be recognized in a biopsy. Use of immunohistochemistry may be helpful in some instances but usually needs more than 1 stain for confirmation. The fetal liver trapped in an MH or IH may show fine glypican-3 staining but will usually lack beta-catenin nuclear staining. Also, the lesional cells of IH will stain with CD31 and Glut1, while MH may show epithelial lined cysts or myxoid matrix with a prominent biliary component. The biliary elements in hepatoblastoma (Cholangioblastic pattern) usually show nuclear beta-catenin staining.

References:

1. Lopez-Terrada D, Alaggio R, de Davila MT, et al. Towards an international pediatric liver tumor consensus classification: proceedings of the Los Angeles COG liver tumors symposium. *Mod Pathol*. 2014;27(3):472-491.