



cap

## Protocol for the Examination of Specimens From Patients With Carcinoma of the Perihilar Bile Ducts

**Protocol applies to all invasive carcinomas of the perihilar bile ducts. Carcinomas of the distal extrahepatic bile ducts, intrahepatic bile ducts, and well-differentiated neuroendocrine neoplasms (carcinoid tumors) are not included.**

---

**Based on AJCC/UICC TNM, 7th edition**

Protocol web posting date: June 2012

### Procedures

- Local or Segmental Bile Duct Resection
- Hilar Resection with or without Hepatic Resection

### Authors

Kay Washington, MD, PhD, FCAP\*

Department of Pathology, Vanderbilt University Medical Center, Nashville, TN

Jordan Berlin, MD

Department of Medicine, Vanderbilt University Medical Center, Nashville, TN

Philip Branton, MD, FCAP

Department of Pathology, Inova Fairfax Hospital, Falls Church, VA

Lawrence J. Burgart, MD, FCAP

Allina Laboratories, Abbott Northwestern Hospital, Minneapolis, MN

David K. Carter, MD, FCAP

Department of Pathology, St. Mary's/Duluth Clinic Health System, Duluth, MN

Carolyn C. Compton, MD, PhD, FCAP

Critical Path Institute, Tucson, AZ

Patrick Fitzgibbons, MD, FCAP

Department of Pathology, St. Jude Medical Center, Fullerton, CA

Wendy L. Frankel, MD, FCAP

Department of Pathology, Ohio State University Medical Center, Columbus, OH

John Jessup, MD

Division of Cancer Treatment and Diagnosis, National Cancer Institute, Bethesda, MD

Sanjay Kakar, MD, FCAP

Department of Pathology, University of California San Francisco and the Veterans Affairs Medical Center, San Francisco, CA

Bruce Minsky, MD

Department of Radiation Oncology, University of Chicago, Chicago, IL

Raouf Nakhleh, MD, FCAP

Department of Pathology, Mayo Clinic, Jacksonville, FL

Jean-Nicolas Vauthey, MD†

Department of Surgical Oncology, University of Texas MD Anderson Cancer Center, Houston, TX

For the Members of the Cancer Committee, College of American Pathologists

\* Denotes primary author. † Denotes senior author. All other contributing authors are listed alphabetically.

**Previous contributors:** Jorge Albores-Saavedra, MD; Donald E. Henson, MD

© 2012 College of American Pathologists (CAP). All rights reserved.

The College does not permit reproduction of any substantial portion of these protocols without its written authorization. The College hereby authorizes use of these protocols by physicians and other health care providers in reporting on surgical specimens, in teaching, and in carrying out medical research for nonprofit purposes. This authorization does not extend to reproduction or other use of any substantial portion of these protocols for commercial purposes without the written consent of the College.

The CAP also authorizes physicians and other health care practitioners to make modified versions of the Protocols solely for their individual use in reporting on surgical specimens for individual patients, teaching, and carrying out medical research for non-profit purposes.

The CAP further authorizes the following uses by physicians and other health care practitioners, in reporting on surgical specimens for individual patients, in teaching, and in carrying out medical research for non-profit purposes: (1) **Dictation** from the original or modified protocols for the purposes of creating a text-based patient record on paper, or in a word processing document; (2) **Copying** from the original or modified protocols into a text-based patient record on paper, or in a word processing document; (3) The use of a **computerized system** for items (1) and (2), provided that the Protocol data is stored intact as a single text-based document, and is not stored as multiple discrete data fields.

Other than uses (1), (2), and (3) above, the CAP does not authorize any use of the Protocols in electronic medical records systems, pathology informatics systems, cancer registry computer systems, computerized databases, mappings between coding works, or any computerized system without a written license from CAP. Applications for such a license should be addressed to the SNOMED Terminology Solutions division of the CAP.

Any public dissemination of the original or modified Protocols is prohibited without a written license from the CAP.

The College of American Pathologists offers these protocols to assist pathologists in providing clinically useful and relevant information when reporting results of surgical specimen examinations of surgical specimens. The College regards the reporting elements in the "Surgical Pathology Cancer Case Summary" portion of the protocols as essential elements of the pathology report. However, the manner in which these elements are reported is at the discretion of each specific pathologist, taking into account clinician preferences, institutional policies, and individual practice.

The College developed these protocols as an educational tool to assist pathologists in the useful reporting of relevant information. It did not issue the protocols for use in litigation, reimbursement, or other contexts. Nevertheless, the College recognizes that the protocols might be used by hospitals, attorneys, payers, and others. Indeed, effective January 1, 2004, the Commission on Cancer of the American College of Surgeons mandated the use of the required data elements of the protocols as part of its Cancer Program Standards for Approved Cancer Programs. Therefore, it becomes even more important for pathologists to familiarize themselves with these documents. At the same time, the College cautions that use of the protocols other than for their intended educational purpose may involve additional considerations that are beyond the scope of this document.

The inclusion of a product name or service in a CAP publication should not be construed as an endorsement of such product or service, nor is failure to include the name of a product or service to be construed as disapproval.

## **CAP Perihilar Bile Duct Protocol Revision History**

---

### **Version Code**

The definition of the version code can be found at [www.cap.org/cancerprotocols](http://www.cap.org/cancerprotocols).

**Version:** PerihilarBileDuct 3.1.0.1

### **Summary of Changes**

The following changes have been made since the February 2011 release.

### **Local or Segmental Resection, Hilar Resection With or Without Hepatic Resection**

#### **Histologic Type**

“Small cell carcinoma” was replaced with the following:

- \_\_\_ High-grade neuroendocrine carcinoma
  - \_\_\_ Large cell neuroendocrine carcinoma
  - \_\_\_ Small cell neuroendocrine carcinoma

#### **Explanatory Notes**

**Histologic Type:** Histologic types were updated, as detailed above.

**References:** Reference #3 was updated.

## Surgical Pathology Cancer Case Summary

---

Protocol web posting date: June 2012

### PERIHILAR BILE DUCTS: Local or Segmental Resection, Hilar Resection With or Without Hepatic Resection (Note A)

Select a single response unless otherwise indicated.

#### Specimen (select all that apply)

- Common bile duct
- Right hepatic duct
- Left hepatic duct
- Junction of right and left hepatic ducts
- Common hepatic duct
- Cystic duct

#### Other Organs Received

- Liver
- Gallbladder
- Other (specify): \_\_\_\_\_

#### Procedure

- Hilar and hepatic resection
- Segmental resection of bile ducts(s)
- Choledochal cyst resection (Note B)
- Total hepatectomy
- Other (specify): \_\_\_\_\_
- Not specified

#### Tumor Site (select all that apply)

- Right hepatic duct
- Left hepatic duct
- Junction of right and left hepatic ducts
- Cystic duct
- Common hepatic duct
- Common bile duct
- Not specified

#### Tumor Size

- Greatest dimension: \_\_\_ cm  
 + Additional dimensions: \_\_\_ x \_\_\_ cm  
 Cannot be determined (see "Comment")

**Histologic Type (Note C)**

- Adenocarcinoma (not otherwise characterized)
- Papillary adenocarcinoma
- Mucinous adenocarcinoma
- Clear cell adenocarcinoma
- Signet-ring cell carcinoma
- Adenosquamous carcinoma
- Squamous cell carcinoma
- High-grade neuroendocrine carcinoma
  - Large cell neuroendocrine carcinoma
  - Small cell neuroendocrine carcinoma
- Biliary cystadenocarcinoma
- Other (specify): \_\_\_\_\_
- Carcinoma, not otherwise specified

**Histologic Grade (Note D)**

- Not applicable
- GX: Cannot be assessed
- G1: Well differentiated
- G2: Moderately differentiated
- G3: Poorly differentiated
- G4: Undifferentiated

**Microscopic Tumor Extension (select all that apply)**

- Carcinoma in situ
- Tumor confined to the bile duct histologically
- Tumor invades beyond the wall of the bile duct into surrounding connective tissue
- Tumor invades the adjacent liver parenchyma
- Tumor invades the gallbladder
- Tumor invades the unilateral branches of the portal vein (right or left)
- Tumor invades the unilateral branches of the hepatic artery (right or left)
- Tumor invades main portal vein or its branches bilaterally
- Tumor invades common hepatic artery
- Tumor invades second-order biliary radicals
  - Unilateral
  - Bilateral

**Margins (select all that apply) (Note E)**Segmental Resection Specimen

- Cannot be assessed
- Margins uninvolved by invasive carcinoma
  - Distance of invasive carcinoma from closest margin: \_\_\_ mm or \_\_\_ cm
  - Specify margin: \_\_\_\_\_
- Margins involved by invasive carcinoma
  - Proximal bile duct margin
  - Distal bile duct margin
  - Hepatic parenchymal margin
  - Other (specify): \_\_\_\_\_
- Dysplasia/carcinoma in situ not identified at bile duct margin
- Dysplasia/carcinoma in situ present at bile duct margin

+ Data elements preceded by this symbol are not required. However, these elements may be clinically important but are not yet validated or regularly used in patient management.

**Lymph-Vascular Invasion (Note F)**

- Not identified  
 Present  
 Indeterminate

**Perineural Invasion (Note F)**

- Not identified  
 Present  
 Indeterminate

**Pathologic Staging (pTNM) (Note G)**

TNM Descriptors (required only if applicable) (select all that apply)

- m (multiple primary tumors)  
 r (recurrent)  
 y (posttreatment)

Primary Tumor (pT)

- pTX: Cannot be assessed  
 pT0: No evidence of primary tumor  
 pTis: Carcinoma in situ  
 pT1: Tumor confined to the bile duct, with extension up to the muscle layer or fibrous tissue  
 pT2a: Tumor invades beyond the wall of the bile duct to surrounding adipose tissue  
 pT2b: Tumor invades adjacent hepatic parenchyma  
 pT3: Tumor invades unilateral branches of the portal vein or hepatic artery  
 pT4: Tumor invades main portal vein or its branches bilaterally; or the common hepatic artery; or the second-order biliary radicals bilaterally; or unilateral second-order biliary radicals with contralateral portal vein or hepatic artery involvement

Regional Lymph Nodes (pN)

- pNX: Cannot be assessed  
 pN0: No regional lymph node metastasis  
 pN1: Regional lymph node metastasis (including nodes along the cystic duct, common bile duct, hepatic artery, and portal vein)  
 pN2: Metastasis to periaortic, pericaval, superior mesentery artery, and/or celiac artery lymph nodes

No nodes submitted or found

*Number of Lymph Nodes Examined*

Specify: \_\_\_\_\_

Number cannot be determined (explain): \_\_\_\_\_

*Number of Lymph Nodes Involved*

Specify: \_\_\_\_\_

Number cannot be determined (explain): \_\_\_\_\_

Distant Metastasis (pM)

- Cannot be assessed  
 pM1: Distant metastasis  
           + Specify site(s), if known: \_\_\_\_\_

+ Data elements preceded by this symbol are not required. However, these elements may be clinically important but are not yet validated or regularly used in patient management.

**+ Additional Pathologic Findings (select all that apply) (Note H)**

- +  None identified
- +  Choledochal cyst
- +  Dysplasia
- +  Primary sclerosing cholangitis (PSC)
- +  Biliary stones
- +  Other (specify): \_\_\_\_\_

**+ Ancillary Studies**

- + Specify: \_\_\_\_\_

**+ Clinical History (select all that apply)**

- +  PSC
- +  Inflammatory bowel disease
- +  Biliary stones
- +  Other (specify): \_\_\_\_\_
- +  Not known

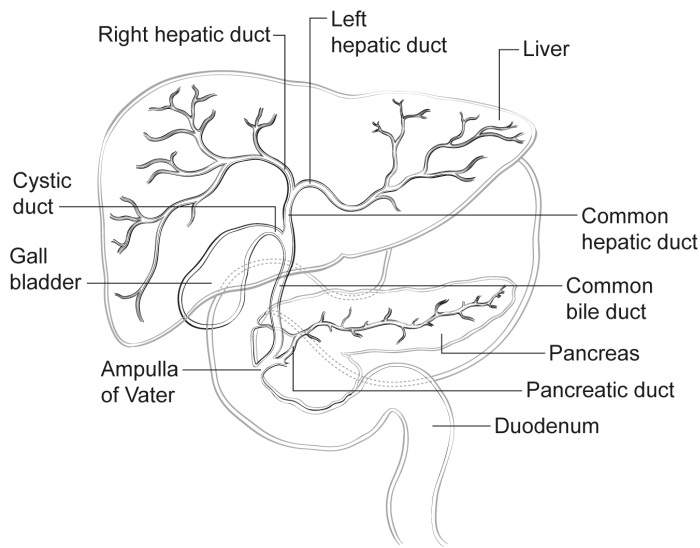
**+ Comment(s)**

## Explanatory Notes

### A. Application

Tumors arising in the biliary tree are classified into three groups: intrahepatic, perihilar, and distal (Figure 1). Perihilar tumors are defined as those involving the hepatic duct bifurcation or extrahepatic biliary tree proximal to the origin of the cystic duct<sup>1</sup>; distal tumors are defined as those arising between the junction of the cystic duct-bile duct and the ampulla of Vater.<sup>2</sup> This protocol applies only to perihilar carcinomas. It does not include tumors of the extrahepatic bile ducts that arise distal to the cystic duct, low-grade neuroendocrine neoplasms (carcinoids), or tumors arising in the ampulla of Vater.

Carcinomas arising in the cystic duct are grouped for staging purposes with carcinomas of the gallbladder (see CAP Protocol for Examination of Specimens with Carcinomas of the Gallbladder). Tumors arising within the intrahepatic bile ducts are classified and staged as carcinomas of the intrahepatic bile ducts (see CAP Protocol for Examination of Specimens with Carcinomas of the Intrahepatic Bile Ducts). Carcinomas arising in the middle portion of the extrahepatic bile duct are classified according to their treatment (combined hepatic and hilar resection for perihilar tumors, pancreaticoduodenectomy for distal bile duct tumors).



**Figure 1.** Anatomy of the biliary system.

### B. Choledochal Cyst

Carcinomas may arise in choledochal cysts (congenital cystic dilatation or duplications) of the bile duct. Histologically, they are classified in the same way as those arising in the gallbladder or bile ducts. Stones may be found in these cysts. If dysplasia or carcinoma in situ is found on initial microscopic sections, then multiple additional sections should be examined to exclude invasive cancer in other areas of the cyst.

### C. Histologic Type

For consistency in reporting, the histologic classification published by the World Health Organization (WHO), shown below, is recommended.<sup>3</sup> However, this protocol does not preclude the use of other systems of classification or histologic types. According to WHO convention, the term "cholangiocarcinoma" is reserved for carcinomas arising in the intrahepatic bile ducts (see CAP Protocol for Examination of Specimens with Carcinomas of the Intrahepatic Bile Ducts).



Some histologic types of bile duct carcinoma are prognostically significant. Papillary carcinomas, which are often polypoid on macroscopic examination, have the best prognosis.<sup>4,5</sup> High-grade tumors, such as signet-ring cell carcinomas, small cell carcinomas, and undifferentiated carcinomas, are associated with a poorer prognosis compared with adenocarcinoma. Many of the special subtypes, such as clear cell adenocarcinoma, are rarely encountered. The following classification is adapted from the WHO classification of carcinoma of the extrahepatic bile ducts:

### Modified WHO Classification of Carcinoma of the Extrahepatic Bile Ducts

Adenocarcinoma  
 Papillary adenocarcinoma#  
 Adenocarcinoma, intestinal type  
 Mucinous adenocarcinoma  
 Clear cell adenocarcinoma#  
 Signet-ring cell carcinoma##  
 Adenosquamous carcinoma  
 Squamous cell carcinoma  
 High-grade neuroendocrine carcinoma  
     Large cell neuroendocrine carcinoma  
     Small cell neuroendocrine carcinoma###  
 Large cell neuroendocrine carcinoma  
 Undifferentiated carcinoma###  
 Biliary cystadenocarcinoma

# These histologic types are not usually graded.

## By convention, signet-ring cell carcinomas are assigned grade 3 (see below).

### Small cell carcinomas and undifferentiated (histologic type) carcinomas are assigned grade 4 (see below).

### D. Histologic Grade

For adenocarcinomas, a quantitative grading system based on the proportion of gland formation within the tumor is suggested<sup>3</sup> and shown below.

Grade X	Grade cannot be assessed
Grade 1	Well differentiated (greater than 95% of tumor composed of glands)
Grade 2	Moderately differentiated (50% to 95% of tumor composed of glands)
Grade 3	Poorly differentiated (less than 50% of tumor composed of glands)

Definitions corresponding to the above histologic grades are as follows:

Grade 1	Composed entirely of glands or has less than 5% solid or cordlike growth patterns
Grade 2	Has more than 5% but less than 50% solid or cordlike growth patterns
Grade 3	Has 50% to 100% solid or cordlike growth patterns

For squamous cell carcinomas, a rare tumor type in the extrahepatic bile ducts, a suggested grading system is shown below. If there are variations in the differentiation within the tumor, the highest (least favorable) grade is recorded.

Grade X	Grade cannot be assessed
Grade 1	Well differentiated
Grade 2	Moderately differentiated

Grade 3 Poorly differentiated

Note: Tumors with no differentiation or minimal differentiation that is discernible only in rare tiny foci (undifferentiated carcinomas by WHO classification) are categorized as grade 4.

### E. Margins

Locoregional recurrence, as opposed to distant metastases, is usually the first site of disease recurrence and occurs in up to 59% of patients with perihilar bile duct carcinomas.<sup>6</sup> Tumor recurrence is often related to residual tumor located in the proximal or distal surgical margins of the bile duct or from tumor located along the dissected soft tissue margin in the portal area. Local recurrence (usually at the surgical margins) can be attributed in many cases to tumor spread longitudinally along the duct wall and to perineural and lymph-vascular invasion.<sup>7</sup>

Complete surgical resection with microscopically negative surgical margins is an important predictor of outcome in multivariate analysis for both perihilar and distal bile duct carcinomas, with overall 5-year survival for perihilar tumor improved from 10% for all patients to 30% for those with negative resection margins.<sup>1</sup>

Malignant tumors of the extrahepatic bile ducts are often multifocal.<sup>8</sup> Therefore, microscopic foci of carcinoma or intraepithelial neoplasia may be found at the margin(s) even though the main tumor mass has been resected. In some cases it may be difficult to evaluate margins on frozen section preparations because of inflammation and reactive change of the surface epithelium or within the intramural mucous glands. If surgical margins are free of carcinoma, the distance between the closest margin and the tumor edge should be measured.

Because 5% of patients with bile duct carcinoma have synchronous carcinomas of the gallbladder, examination of the entire surgical specimen, including the gallbladder, is advised.

### F. Perineural and Vascular/Lymphatic Invasion

Perineural and lymphatic invasion are common in extrahepatic bile duct carcinomas, although they are found less often in early-stage cancers (11%).<sup>9</sup> They should be specifically evaluated because they are associated with adverse outcome on univariate analysis.<sup>10</sup> Although perineural invasion is sometimes useful for distinguishing carcinoma from nonneoplastic glands, caution should be used in interpretation of this finding in ducts affected by primary sclerosing cholangitis, because perineural invasion by benign hyperplastic intramural glands as been reported in this setting<sup>11</sup> and may be seen in adenomatous hyperplasia.

### G. TNM and Anatomic Stage/Prognostic Groupings

Surgical resection is the most effective therapy for extrahepatic biliary tract carcinomas, and the best estimation of prognosis is related to the anatomic extent (stage) of disease at the time of resection. In particular, lymph node metastases are predictors of poorer outcome.<sup>1,12</sup>

For malignant tumors of the perihilar bile ducts, the TNM staging system of the American Joint Committee on Cancer (AJCC) and the International Union Against Cancer (UICC) is recommended.<sup>2</sup> The staging system also applies to tumors arising in choledochal cysts.

According to AJCC/UICC convention, the designation "T" refers to a primary tumor that has not been previously treated. The symbol "p" refers to the pathologic classification of the TNM, as opposed to the clinical classification, and is based on gross and microscopic examination. pT entails a resection of the primary tumor or biopsy adequate to evaluate the highest pT category, pN entails removal of nodes adequate to validate lymph node metastasis, and pM implies microscopic examination of distant

lesions. Clinical classification (cTNM) is usually carried out by the referring physician before treatment during initial evaluation of the patient or when pathologic classification is not possible.

Pathologic staging is usually performed after surgical resection of the primary tumor. Pathologic staging depends on pathologic documentation of the anatomic extent of disease, whether or not the primary tumor has been completely removed. If a biopsied tumor is not resected for any reason (eg, when technically infeasible) and if the highest T and N categories or the M1 category of the tumor can be confirmed microscopically, the criteria for pathologic classification and staging have been satisfied without total removal of the primary cancer.

### TNM Descriptors

For identification of special cases of TNM or pTNM classifications, the “m” suffix and “y,” “r,” and “a” prefixes are used. Although they do not affect the stage grouping, they indicate cases needing separate analysis.

The “m” suffix indicates the presence of multiple primary tumors in a single site and is recorded in parentheses: pT(m)NM.

The “y” prefix indicates those cases in which classification is performed during or after initial multimodality therapy (ie, neoadjuvant chemotherapy, radiation therapy, or both chemotherapy and radiation therapy). The cTNM or pTNM category is identified by a “y” prefix. The ycTNM or ypTNM categorizes the extent of tumor actually present at the time of that examination. The “y” categorization is not an estimate of tumor before multimodality therapy (ie, before initiation of neoadjuvant therapy).

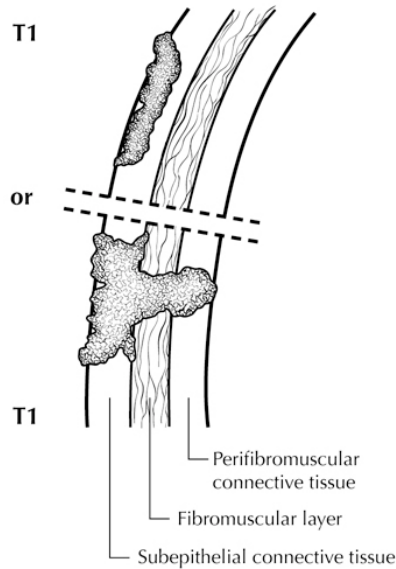
The “r” prefix indicates a recurrent tumor when staged after a documented disease-free interval and is identified by the “r” prefix: rTNM.

The “a” prefix designates the stage determined at autopsy: aTNM.

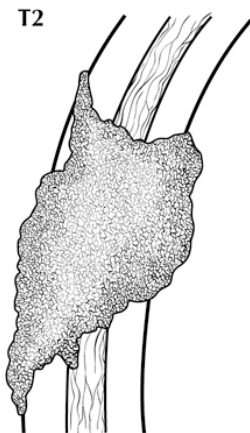
### T Category Considerations (Figures 2 and 3)

pTis. For bile duct carcinomas, “carcinoma in situ” (pTis) as a staging term includes neoplastic cells cytologically indistinguishable from invasive carcinoma but confined within the glandular basement membrane.<sup>8</sup> Separation of high-grade dysplasia from carcinoma in situ is subjective and, because morphologic criteria are ill defined, subject to interobserver variability. The term “carcinoma in situ” is not widely applied to glandular neoplastic lesions in the gastrointestinal tract but is retained for tumor registry reporting purposes as specified by law in many states. Noninvasive bile duct carcinomas with a papillary growth pattern are classified as pTis.

pT2 and pT3. Because the histology of the extrahepatic biliary tree varies along its length, with little smooth muscle in the wall of the proximal ducts compared with the distal bile duct, assessment of depth of tumor invasion may be difficult. In addition to the problem caused by lack of discrete tissue boundaries, inflammatory changes in the bile ducts and desmoplastic stromal response to tumor may cause distortion. To overcome these difficulties, it has been proposed that the pathologist should measure the depth of invasion of tumor from the basal lamina of normal epithelium to the point of deepest tumor invasion.<sup>13</sup> However, this system has not yet been widely adopted for staging purposes.



**Figure 2.** T1 tumors are confined to the bile duct histologically. From Greene et al.<sup>14</sup> Used with permission of the American Joint Committee on Cancer (AJCC), Chicago, Illinois. The original source for this material is the *AJCC Cancer Staging Atlas* (2006) published by Springer Science and Business Media LLC, [www.springerlink.com](http://www.springerlink.com).



**Figure 3.** T2 tumors invade beyond the wall of the bile duct. From Greene et al.<sup>14</sup> Used with permission of the American Joint Committee on Cancer (AJCC), Chicago, Illinois. The original source for this material is the *AJCC Cancer Staging Atlas* (2006) published by Springer Science and Business Media LLC, [www.springerlink.com](http://www.springerlink.com).

### Vessel Invasion

According to AJCC/UICC convention, vessel invasion (lymphatic or venous) does not affect the T category indicating local extent of tumor unless specifically included in the definition of a T category.

### N Category Considerations

The regional nodes for perihilar bile duct carcinomas are hilar nodes along the cystic duct, common bile duct, hepatic artery, and portal vein (N1); and periaortic, pericaval, superior mesentery artery, and/or celiac artery lymph nodes (N2).

Tumor involvement of other nodal groups is considered distant metastasis. Anatomic division of regional lymph nodes is not necessary, but separately submitted lymph nodes should be reported as submitted.

Routine assessment of regional lymph nodes is limited to conventional pathologic techniques (gross assessment and histologic examination), and data are currently insufficient to recommend special measures to detect micrometastasis or isolated tumor cells. Thus, neither multiple levels of paraffin blocks nor the use of special/ancillary techniques, such as immunohistochemistry, are recommended for routine examination of regional lymph nodes.

### Stage Groupings

Stage 0	Tis	N0	M0 <sup>#</sup>
Stage I	T1	N0	M0
Stage II	T2a or T2b	N0	M0
Stage IIIA	T3	N0	M0
Stage IIIB	T1, T2, or T3	N1	M0
Stage IVA	T4	N0 or N1	M0
Stage IVB	Any T	N2	M0 or M1
	Any T	Any N	M1

# M0 is defined as no distant metastasis.

### H. Additional Findings

Chronic inflammatory conditions affecting the bile ducts are associated with higher risk for biliary tract carcinomas. The most common risk factor for cholangiocarcinoma of the extrahepatic bile ducts in Western countries is primary sclerosing cholangitis, characterized by multifocal strictures and inflammation of the extrahepatic and intrahepatic biliary tree. Patients with PSC are at risk for multifocal biliary carcinomas. In Japan and Southeast Asia, hepatolithiasis due to recurrent pyogenic cholangitis with biliary stones is a more common risk factor for biliary malignancy. Biliary parasites such as *Clonorchis sinensis* and *Opisthorchis viverrini*, prevalent in parts of Asia, are also associated with carcinomas of the extrahepatic bile ducts.

### References

1. DeOliveira ML, Cunningham SC, Cameron JL, et al. Cholangiocarcinoma: thirty-one-year experience with 564 patients at a single institution. *Ann Surg*. 2007;245(5):755-762.
2. Edge SB, Byrd DR, Carducci MA, Compton CC, eds. *AJCC Cancer Staging Manual*. 7th ed. New York, NY: Springer; 2009.
3. Bosman FT, Carneiro F, Hruban RH, Theise ND, eds. *WHO Classification of Tumours of the Digestive System*. Geneva, Switzerland: WHO Press; 2010.
4. Albores-Saavedra J, Murakata L, Krueger JE, Henson DE. Noninvasive and minimally invasive papillary carcinomas of the extrahepatic bile ducts. *Cancer*. 2000;89(3):508-515.
5. Jarnagin WR, Bowne W, Klimstra DS, et al. Papillary phenotype confers improved survival after resection of hilar cholangiocarcinoma. *Ann Surg*. 2005;241(5):703-712.
6. Jarnagin WR, Ruo L, Little SA, et al. Patterns of initial disease recurrence after resection of gallbladder carcinoma and hilar cholangiocarcinoma: implications for adjuvant therapeutic strategies. *Cancer*. 2003;98(8):1689-700.
7. Jarnagin WR. Cholangiocarcinoma of the extrahepatic bile ducts. *Semin Surg Oncol*. 2000;19(2):156-176.
8. Albores-Saavedra J, Henson DE, Klimstra DS. *Tumors of the Gallbladder, Extrahepatic Bile Duct, and Ampulla of Vater*. Washington, DC.: Armed Forces Institute of Pathology; 2000. 3rd series, fascicle 27.
9. Cha JM, Kim MH, Lee SK, et al. Clinicopathological review of 61 patients with early bile duct cancer. *Clin Oncol*. 2006;18(9):669-677.

10. Murakami Y, Uemura K, Hayashidani Y, Sudo T, Ohge H, Sueda T. Pancreatoduodenectomy for distal cholangiocarcinoma: prognostic impact of lymph node metastasis. *World J Surg.* 2007;31(2):337-342; discussion 343-344.
11. Katabi N, Albores-Saavedra J. The extrahepatic bile duct lesions in end-stage primary sclerosing cholangitis. *Am J Surg Pathol.* 2003;27(3):349-355.
12. Hong SM, Cho H, Lee OJ, Ro JY. The number of metastatic lymph nodes in extrahepatic bile duct carcinoma as a prognostic factor. *Am J Surg Pathol.* 2005;29(9):1177-1183. [erratum in *Am J Surg Pathol.* 2005;29(11):1548]
13. Hong SM, Cho H, Moskaluk CA, Yu E. Measurement of the invasion depth of extrahepatic bile duct carcinoma: an alternative method overcoming the current T classification problems of the AJCC staging system. *Am J Surg Pathol.* 2007;31(2):199-206.
14. Greene FL, Compton, CC, Fritz AG, et al, eds. *AJCC Cancer Staging Atlas.* New York, NY: Springer; 2006.