

Protocol for the Examination of Specimens From Patients With Carcinoma of the Prostate Gland

Protocol applies to invasive carcinomas of the prostate gland.

Based on AJCC/UICC TNM, 7th edition

Protocol web posting date: June 2012

Procedures

- Needle Biopsy
- Transurethral Prostatic Resection
- Suprapubic or Retropubic Enucleation (Subtotal Prostatectomy)
- Radical Prostatectomy

Authors

John R. Srigley, MD, FCAP*

Department of Laboratory Medicine, Credit Valley Hospital, Mississauga, Ontario, Canada

Peter A. Humphrey, MD, PhD, FCAP*

Department of Pathology, Washington University School of Medicine and Barnes-Jewish Hospital, St. Louis, Missouri

Mahul B. Amin, MD, FCAP*

Department of Pathology and Laboratory Medicine, Cedars-Sinai Medical Center, Los Angeles, California

Sam S. Chang, MD

Department of Urologic Surgery, Vanderbilt-Ingram Cancer Center, Nashville, Tennessee

Lars Egevad, MD

Department of Pathology and Cytology, Karolinska University Hospital, Stockholm, Sweden

Jonathan I. Epstein, MD

Department of Pathology, Johns Hopkins Hospital, Baltimore, Maryland

David J. Grignon, MD

Department of Pathology, Indiana University School of Medicine, Indianapolis, Indiana

James M. McKiernan, MD

Columbia University College of Physicians and Surgeons, New York, New York

Rodolfo Montironi, MD, FRCPath

Institute of Pathological Anatomy and Histopathology, University of Ancona School of Medicine, Ancona, Italy

Andrew A. Renshaw, MD

Department of Pathology, Baptist Hospital of Miami, Miami, Florida

Victor E. Reuter, MD

Pathology Department, Memorial Sloan-Kettering Cancer Center, New York, New York

Thomas M. Wheeler, MD, FCAP

Department of Pathology and Immunology, Baylor College of Medicine, Houston, Texas

Ming Zhou, MD, PhD, FCAP†

Department of Pathology, New York University Langone Medical Center, New York, New York

For the Members of the Cancer Committee, College of American Pathologists

* denotes primary authors. † denotes senior author. All other contributing authors are listed alphabetically.

© 2012 College of American Pathologists (CAP). All rights reserved.

The College does not permit reproduction of any substantial portion of these protocols without its written authorization. The College hereby authorizes use of these protocols by physicians and other health care providers in reporting on surgical specimens, in teaching, and in carrying out medical research for nonprofit purposes. This authorization does not extend to reproduction or other use of any substantial portion of these protocols for commercial purposes without the written consent of the College.

The CAP also authorizes physicians and other health care practitioners to make modified versions of the Protocols solely for their individual use in reporting on surgical specimens for individual patients, teaching, and carrying out medical research for non-profit purposes.

The CAP further authorizes the following uses by physicians and other health care practitioners, in reporting on surgical specimens for individual patients, in teaching, and in carrying out medical research for non-profit purposes: (1) **Dictation** from the original or modified protocols for the purposes of creating a text-based patient record on paper, or in a word processing document; (2) **Copying** from the original or modified protocols into a text-based patient record on paper, or in a word processing document; (3) The use of a **computerized system** for items (1) and (2), provided that the Protocol data is stored intact as a single text-based document, and is not stored as multiple discrete data fields.

Other than uses (1), (2), and (3) above, the CAP does not authorize any use of the Protocols in electronic medical records systems, pathology informatics systems, cancer registry computer systems, computerized databases, mappings between coding works, or any computerized system without a written license from CAP. Applications for such a license should be addressed to the SNOMED Terminology Solutions division of the CAP.

Any public dissemination of the original or modified Protocols is prohibited without a written license from the CAP.

The College of American Pathologists offers these protocols to assist pathologists in providing clinically useful and relevant information when reporting results of surgical specimen examinations of surgical specimens. The College regards the reporting elements in the "Surgical Pathology Cancer Case Summary" portion of the protocols as essential elements of the pathology report. However, the manner in which these elements are reported is at the discretion of each specific pathologist, taking into account clinician preferences, institutional policies, and individual practice.

The College developed these protocols as an educational tool to assist pathologists in the useful reporting of relevant information. It did not issue the protocols for use in litigation, reimbursement, or other contexts. Nevertheless, the College recognizes that the protocols might be used by hospitals, attorneys, payers, and others. Indeed, effective January 1, 2004, the Commission on Cancer of the American College of Surgeons mandated the use of the required data elements of the protocols as part of its Cancer Program Standards for Approved Cancer Programs. Therefore, it becomes even more important for pathologists to familiarize themselves with these documents. At the same time, the College cautions that use of the protocols other than for their intended educational purpose may involve additional considerations that are beyond the scope of this document.

The inclusion of a product name or service in a CAP publication should not be construed as an endorsement of such product or service, nor is failure to include the name of a product or service to be construed as disapproval.

CAP Prostate Protocol Revision History

Version Code

The definition of the version code can be found at www.cap.org/cancerprotocols.

Version: Prostate 3.2.0.0

Summary of Changes

The following changes have been made since the February 2011 release.

Transurethral Prostatic Resection (TUR), Enucleation Specimen

Tumor Quantitation: TUR Specimens

Deleted the following data elements:

Tumor incidental histologic finding in no more than 5% of tissue resected with Gleason score 2 to 6 (cT1a)

Tumor incidental histologic finding in more than 5% of tissue resected or Gleason score 7 to 10 (cT1b)

Radical Prostatectomy

Seminal Vesicle Invasion

Optional elements "Right," "Left," and "Bilateral" were added, as follows:

Seminal Vesicle Invasion (invasion of muscular wall required) (select all that apply)

Not identified

Present

+ Right

+ Left

+ Bilateral

No seminal vesicle present

Explanatory Notes

B. Gleason Score

The phrase "and radiation therapy" was added to the first sentence.

C. Quantitation of Tumor

The fifth sentence was changed, beginning with "The designation of the proportion (percentage)..."

K. TNM and Stage Groupings

Regional and Distant Lymph Nodes

This section was added.

Surgical Pathology Cancer Case Summary

Protocol web posting date: June 2012

PROSTATE GLAND: Needle Biopsy

Select a single response unless otherwise indicated.

The Gleason grade and score and tumor extent measures should be documented for each positive specimen (container). The essential information in each specimen could be conveyed with a simple diagnostic line such as, "Adenocarcinoma, Gleason grade 3 + 4 = score of 7, in 1 of 2 cores, involving 20% of needle core tissue, and measuring 4 mm in length." (See "Explanatory Notes.")

Histologic Type (Note A)

- Adenocarcinoma (acinar, not otherwise specified)
 Other (specify): _____

Histologic Grade (Note B)

Gleason Pattern

(If 3 patterns present, use most predominant pattern and worst pattern of remaining 2)

- Not applicable
 Cannot be determined

Primary (Predominant) Pattern

- Grade 1
 Grade 2
 Grade 3
 Grade 4
 Grade 5

Secondary (Worst Remaining) Pattern

- Grade 1
 Grade 2
 Grade 3
 Grade 4
 Grade 5

Total Gleason Score: ____

Tumor Quantitation (Note C)

Number cores positive: ____

Total number of cores: ____

and

Proportion (percent) of prostatic tissue involved by tumor: ____%

or

+ Data elements preceded by this symbol are not required. However, these elements may be clinically important but are not yet validated or regularly used in patient management.

Number cores positive: ____
Total number of cores: ____
and
Total linear millimeters of carcinoma: ____ mm
Total linear millimeters of needle core tissue: ____ mm

or

Number cores positive: ____
Total number of cores: ____
and
Proportion (percent) of prostatic tissue involved by tumor: ____%
and
Total linear millimeters of carcinoma: ____ mm
Total linear millimeters of needle core tissue: ____mm

+ Proportion (percentage) of prostatic tissue involved by tumor for core with the greatest amount of tumor: ____%

Periprostatic Fat Invasion (document if identified) (Note D)

+ ____ Not identified
____ Present

Seminal Vesicle Invasion (document if identified) (Note D)

+ ____ Not identified
____ Present

+ Lymph-Vascular Invasion

+ ____ Not identified
+ ____ Present
+ ____ Indeterminate

+ Perineural Invasion (Note E)

+ ____ Not identified
+ ____ Present

+ Additional Pathologic Findings (select all that apply)

+ ____ None identified
+ ____ High-grade prostatic intraepithelial neoplasia (PIN) (Note F)
+ ____ Atypical adenomatous hyperplasia (adenosis)
+ ____ Inflammation (specify type): _____
+ ____ Other (specify): _____

+ Comment(s)

+ Data elements preceded by this symbol are not required. However, these elements may be clinically important but are not yet validated or regularly used in patient management.

Surgical Pathology Cancer Case Summary

Protocol web posting date: June 2012

PROSTATE GLAND: Transurethral Prostatic Resection (TUR), Enucleation Specimen (Subtotal Prostatectomy)

Select a single response unless otherwise indicated.

Procedure

- Transurethral prostatic resection (Note G)
 Enucleation
 Other (specify): _____
 Not specified

Specimen Size

Weight: ___ g
 Size (enucleation specimens only): ___ x ___ x ___ cm

Histologic Type (Note A)

- Adenocarcinoma (acinar, not otherwise specified)
 Other (specify): _____

Histologic Grade (Note B)

Gleason Pattern

(If 3 patterns present, use most predominant pattern and worst pattern of remaining 2)

- Not applicable
 Cannot be determined

Primary (Predominant) Pattern

- Grade 1
 Grade 2
 Grade 3
 Grade 4
 Grade 5

Secondary (Worst Remaining) Pattern

- Grade 1
 Grade 2
 Grade 3
 Grade 4
 Grade 5

Total Gleason Score: ____

Tumor Quantitation: TUR Specimens (Note C)

Proportion (percentage) of prostatic tissue involved by tumor: ____%
 + Number of positive chips: ____
 + Total number of chips: ____

+ Data elements preceded by this symbol are not required. However, these elements may be clinically important but are not yet validated or regularly used in patient management.

Tumor Quantitation: Enucleation Specimens (Note C)

Proportion (percent) of prostatic tissue involved by tumor: ____%

+ Tumor size (dominant nodule, if present):

+ Greatest dimension: ____ cm

+ Additional dimensions: ____ x ____ cm

Periprostatic Fat Invasion (document if identified) (Note D)

+ ____ Not identified

____ Present

Seminal Vesicle Invasion (document if identified) (Note D)

+ ____ Not identified

____ Present

+ Lymph-Vascular Invasion

+ ____ Not identified

+ ____ Present

+ ____ Indeterminate

+ Perineural Invasion (Note E)

+ ____ Not identified

+ ____ Present

+ Additional Pathologic Findings (select all that apply)

+ ____ None identified

+ ____ High-grade prostatic intraepithelial neoplasia (PIN) (Note F)

+ ____ Atypical adenomatous hyperplasia (adenosis)

+ ____ Nodular prostatic hyperplasia

+ ____ Inflammation (specify type): _____

+ ____ Other (specify): _____

+ Comment(s)

Surgical Pathology Cancer Case Summary

Protocol web posting date: June 2012

PROSTATE GLAND: Radical Prostatectomy

Select a single response unless otherwise indicated.

Procedure (Note G)

- Radical prostatectomy
 Other (specify): _____
 Not specified

Prostate Size (Note G)

Weight: ___ g
 Size: ___ x ___ x ___ cm

Lymph Node Sampling (Note G)

- No lymph nodes present
 Pelvic lymph node dissection

Histologic Type (Note A)

- Adenocarcinoma (acinar, not otherwise specified)
 Prostatic duct adenocarcinoma
 Mucinous (colloid) adenocarcinoma
 Signet-ring cell carcinoma
 Adenosquamous carcinoma
 Small cell carcinoma
 Sarcomatoid carcinoma
 Undifferentiated carcinoma, not otherwise specified
 Other (specify): _____

Histologic Grade (Note B)

Gleason Pattern

If 3 patterns are present, record the most predominant and second most common patterns; the tertiary pattern should be recorded if higher than the primary and secondary patterns but it is not incorporated into the Gleason score.

- Not applicable
 Cannot be determined

Primary Pattern

- Grade 1
 Grade 2
 Grade 3
 Grade 4
 Grade 5

Secondary Pattern

- Grade 1
 Grade 2
 Grade 3
 Grade 4
 Grade 5

Tertiary Pattern

- Grade 3
 Grade 4
 Grade 5
 Not applicable

Total Gleason Score: ____

Tumor Quantitation (Note C)

Proportion (percentage) of prostate involved by tumor: ____%
and/or

Tumor size (dominant nodule, if present):

- Greatest dimension: ____ mm
 + Additional dimensions: ____ x ____ mm

Extraprostatic Extension (select all that apply) (Note H)

- Not identified
 Present
 - Focal
 - + Specify site(s): _____
 - Nonfocal (established, extensive)
 - + Specify site(s): _____ Indeterminate

Seminal Vesicle Invasion (invasion of muscular wall required) (select all that apply) (Note D)

- Not identified
 Present
 - + Right
 - + Left
 - + Bilateral No seminal vesicle present

Margins (select all that apply) (Note I)

- Cannot be assessed
+ Benign glands at surgical margin
 Margins uninvolved by invasive carcinoma
 Margin(s) involved by invasive carcinoma
+ Unifocal
+ Multifocal
 Apical
 Bladder neck
 Anterior
 Lateral
 Postero-lateral (neurovascular bundle)
 Posterior
 Other(s) (specify): _____

Treatment Effect on Carcinoma (select all that apply)

- Not identified
 Radiation therapy effect present
 Hormonal therapy effect present
 Other therapy effect(s) present (specify): _____

Lymph-Vascular Invasion

- Not identified
 Present
 Indeterminate

+ Perineural Invasion (Note E)

- + Not identified
+ Present

Pathologic Staging (pTNM) (Note K)

TNM Descriptors (required only if applicable) (select all that apply)

- m (multiple)
 r (recurrent)
 y (posttreatment)

Primary Tumor (pT)

- Not identified
 pT2: Organ confined
+ pT2a: Unilateral, involving one-half of 1 side or less
+ pT2b: Unilateral, involving more than one-half of 1 side but not both sides
+ pT2c: Bilateral disease
pT3: Extraprostatic extension
 pT3a: Extraprostatic extension or microscopic invasion of bladder neck
 pT3b: Seminal vesicle invasion
 pT4: Invasion of rectum, levator muscles and/or pelvic wall (Note J)

Note: There is no pathologic T1 classification. Subdivision of pT2 disease is problematic and has not proven to be of prognostic significance.

Regional Lymph Nodes (pN)

- pNX: Cannot be assessed
 pN0: No regional lymph node metastasis
 pN1: Metastasis in regional lymph node or nodes

No nodes submitted or found

Number of Lymph Nodes Examined

Specify: _____

Number cannot be determined (explain): _____

Number of Lymph Nodes Involved

Specify: _____

Number cannot be determined (explain): _____

Diameter of largest lymph node metastasis: _____ (mm)

Distant Metastasis (pM)

- Not applicable
 pM1: Distant metastasis
 pM1a: Nonregional lymph nodes(s)
 pM1b: Bone(s)
 pM1c: Other site(s) with or without bone disease

Note: When more than 1 site of metastasis is present, the most advanced category is used. pM1c is most advanced.

+ Additional Pathologic Findings (select all that apply)

- + None identified
 + High-grade prostatic intraepithelial neoplasia (PIN) (Note F)
 + Inflammation (specify type): _____
 + Atypical adenomatous hyperplasia (adenosis)
 + Nodular prostatic hyperplasia
 + Other (specify): _____

+ Ancillary Studies

- + Specify: _____
 + Not performed

+ Comment(s)

Explanatory Notes

A. Histologic Type

This protocol applies only to carcinomas of the prostate gland. The histologic classification of prostate carcinoma is recommended and shown below.¹ However, this protocol does not preclude the use of other systems of classification or histologic types. Mixtures of different histologic types should be indicated.

Histologic Classification of Carcinoma of the Prostate

Adenocarcinoma (conventional, acinar)

Special variants of adenocarcinoma and other carcinomas

Prostatic duct adenocarcinoma

Mucinous (colloid) adenocarcinoma

Signet-ring cell carcinoma

Adenosquamous carcinoma

Squamous cell carcinoma[#]

Basaloid (basal cell) and adenoid cystic carcinoma [#]

Urothelial (transitional cell) carcinoma[#]

Small cell carcinoma

Sarcomatoid carcinoma

Lymphoepithelioma-like carcinoma[#]

Undifferentiated carcinoma, not otherwise specified

[#] This protocol does not apply to these carcinomas.

B. Gleason Score

The Gleason grading system is recommended for use in all prostatic specimens containing adenocarcinoma, with the exception of those showing treatment effects, usually in the setting of androgen withdrawal and radiation therapy.^{2,3} Gleason score is an important parameter used in nomograms, such as the Kattan nomograms,^{4,5} and the Partin tables,⁶ which guide individual treatment decisions. Readers are referred to the recommendations of a recent consensus conference dealing with the contemporary usage of the Gleason system.⁷ The Gleason score is the sum of the primary (most predominant in terms of surface area of involvement) Gleason grade and the secondary (second most predominant) Gleason grade. Where no secondary Gleason grade exists, the primary Gleason grade is doubled to arrive at a Gleason score. The primary and secondary grades should be reported in addition to the Gleason score, that is, Gleason score 7(3+4) or 7(3+4).

In needle biopsy specimens, it is recommended that Gleason scores be assigned for each specimen (container). Alternatively, a Gleason score may be given for each positive intact core in a container.

In needle biopsy specimens where there is a minor secondary component (<5% of tumor) and where the secondary component is of higher grade, the latter should be reported. For instance, a case showing more than 95% Gleason 3 and less than 5% Gleason 4 should be reported as Gleason score 7(3+4). Conversely, if a minor secondary pattern is of lower grade, it need not be reported. For instance, where there is greater than 95% Gleason score 4 and less than 5% Gleason 3, the score should be reported as Gleason 8(4+4).

In needle biopsy specimens where more than 2 patterns are present, and the worst grade is neither the predominant nor the secondary grade, the predominant and highest grade should be chosen to arrive at a score (eg, 75%, grade 3; 20%–25%, grade 4; <5%, grade 5 is scored as 3+5=8). This approach has been validated in a large clinical series.⁸

Rules of grading similar to the above apply to transurethral resection and enucleation (simple prostatectomy) specimens.

Tertiary Gleason patterns are common in radical prostatectomy specimens. When Gleason pattern 5 is present as a tertiary pattern, its presence should be recognized in the report. For instance, in a situation where the primary Gleason grade is 3, the secondary is 4 and there is less than 5% Gleason 5, the report should indicate a Gleason score of 7(3+4) with tertiary Gleason pattern 5.

For radical prostatectomy specimens, Gleason score should be assigned to the dominant nodule(s), if present. Where more than one separate tumor is clearly identified, the Gleason scores of individual tumors can be recorded separately, or, at the very least, a Gleason score of the dominant or most significant lesion should be recorded. For instance, if there is a large Gleason score 4(2+2) transition zone tumor and a separate smaller Gleason score 8(4+4) peripheral zone cancer, both scores should be reported, or, at the very least, the latter score should be reported rather than these scores being averaged.

C. Quantitation of Tumor

There are many methods of estimating the amount of tumor in prostatic specimens.⁹⁻¹⁷ For needle core biopsy specimens, it is suggested that the number of positive cores out of the total number of cores always be reported, except in situations where fragmentation precludes accurate counting. The estimated proportion (percent) of prostatic tissue involved by tumor and/or the linear millimeters of the tumor should also be reported. Reporting of the positive core with the greatest percentage of tumor is an option. The designation of the proportion (percentage) of prostatic tissue in transurethral samples is important. When prostate cancer is discovered incidentally (ie, discovered in specimens submitted for clinically benign disease, usually BPH), the percentage involvement is used to determine the clinical T1 substage, with $\leq 5\%$ involvement being T1a and $>5\%$ being T1b. The Gleason score may also play a factor in the substage. In subtotal and radical prostatectomy specimens, the percentage of tissue involved by tumor can also be "eyeballed" by simple visual inspection. Additionally, in these latter specimens, it may be possible to measure a dominant tumor nodule in at least 2 dimensions and/or to indicate the number of blocks involved by tumor out of the total number of prostatic blocks submitted.

D. Local Invasion in Needle Biopsies

Occasionally in needle biopsies, periprostatic fat is present and involved by tumor.⁹ This observation should be noted since it indicates that the tumor is at least pT3a in the TNM system. Furthermore, if seminal vesicle tissue is present (either unintentionally or intentionally, as in a directed biopsy) and involved by tumor, this should be reported since it indicates that the tumor is at least pT3b. Seminal vesicle invasion is defined by involvement of the muscular wall.^{9,18} At times, especially in needle biopsy specimens, it is difficult to distinguish between seminal vesicle and ejaculatory duct tissue. It is important not to overinterpret the ejaculatory duct as seminal vesicle since involvement of the former by tumor does not constitute pT3b disease. If there is doubt as to whether the involved tissue represents the seminal vesicle or the ejaculatory duct, then invasion of the seminal vesicle should not be definitively diagnosed.

E. Perineural Invasion

Perineural invasion in core needle biopsies has been associated with extraprostatic extension in some correlative radical prostatectomy studies, although its exact prognostic significance remains to be determined.^{9,14,19-22} Perineural invasion has also been found to be an independent risk factor, in some studies, for predicting an adverse outcome in patients treated with external beam radiation,¹⁹ but not for patients treated with brachytherapy or radical prostatectomy.²⁰ The value of perineural invasion as an independent prognostic factor has been questioned in a multivariate analysis.²²

F. Prostatic Intraepithelial Neoplasia

The diagnostic term prostatic intraepithelial neoplasia (PIN), unless qualified, refers to high-grade PIN. Low-grade PIN is not reported. The presence of an isolated PIN (PIN in the absence of carcinoma) should be reported in all biopsy specimens.⁹ The reporting of PIN in biopsies with carcinoma is considered optional. High-grade PIN in a biopsy without evidence of carcinoma has in the past been a risk factor for the presence of carcinoma on subsequent biopsies, but the magnitude of the risk has diminished, and, in some studies, high-grade PIN was not a risk factor at all, unless multiple cores were positive for PIN.²³⁻²⁶ The reporting of high-grade PIN in prostatectomy specimens is optional.

G. Submission of Tissue for Microscopic Evaluation in Transurethral Resection and Radical Prostatectomy Specimens

Transurethral resection specimens that weigh 12 g or less should be submitted in their entirety, usually in 6 to 8 cassettes.^{26,27} For specimens that weigh more than 12 g, the initial 12 g are submitted (6 to 8 cassettes), and 1 cassette may be submitted for every additional 5 g may be submitted.

In general, random chips are submitted; however, if some chips are firmer or have a yellow or orange-yellow appearance, they should be submitted preferentially.

If an unsuspected carcinoma is found in tissue submitted, and it involves 5% or less of the tissue examined, the remaining tissue may be submitted for microscopic examination, especially in younger patients.

A radical prostatectomy specimen may be submitted in its entirety or partially sampled in a systematic fashion.^{28,29} For partial sampling in the setting of a grossly visible tumor, the tumor and associated periprostatic tissue and margins, along with the entire apical and bladder neck margins and the junction of each seminal vesicle with prostate proper, should be submitted. If there is no grossly visible tumor, a number of systematic sampling strategies may be used. One that yields excellent prognostic information involves submitting the posterior aspect of each transverse slice along with a mid anterior block from each side.²⁹ The anterior sampling detects the T1c cases arising in the transition zone and extending anteriorly. The entire apical and bladder neck margins and the junction of each seminal vesicle with the prostate should also be submitted.

H. Extraprostatic Extension

Extraprostatic extension (EPE) is the preferred term for the presence of tumor beyond the confines of the prostate gland.^{28,30-32} Tumor admixed with fat constitutes extraprostatic extension. Tumor involving loose connective tissue in the plane of fat or beyond, even in the absence of direct contact between the tumor and the adipocytes, indicates EPE. Extraprostatic extension may also be reported when the tumor involves perineural spaces in the neurovascular bundles, even in the absence of periprostatic fat involvement. In certain locations, such as the anterior and apical prostate and bladder neck regions, there is a paucity of fat, and in these locations EPE is determined when the tumor extends beyond the confines of the normal glandular prostate. In the distal apical perpendicular margin section, it is often difficult to identify EPE. Sometimes there is a distinct bulging tumor nodule, which may be associated with a desmoplastic stromal reaction. The specific location(s) and the number of sites (blocks) of EPE are useful to report. Descriptors of EPE (focal versus nonfocal) should be used. Focal EPE equates with only a few neoplastic glands being outside the prostate or a tumor involving less than 1 high-power field in 1 or 2 sections³⁰; nonfocal (established) EPE is more extensively spread beyond the prostatic edge.

I. Margins

The entire surface of the prostate should be inked to evaluate the surgical margins.²⁸⁻³⁶ Usually, surgical margins should be designated as "negative" if tumor is not present at the inked margin and as "positive" if tumor cells touch the ink at the margin. When tumor is located very close to an inked surface but is not actually in contact with the ink, the margin is considered negative. Positive surgical

margins should not be interpreted as extraprostatic extension. Intraprostatic margins are positive in the setting of intraprostatic incision (so-called pT2+ disease; Figure 1).²⁸ If the surgical margin finding is positive, the pathologist should state that explicitly, although this finding is not relied upon for pathologic staging. The specific locations of the positive margins should be reported, and it should be specified whether EPE or intraprostatic incision is present at each site of margin positivity. There should be some indication of the extent of margin positivity. At the 2009 International Society of Urological Pathology Consensus Conference on Handling and Staging of Radical Prostatectomy Specimens, it was recommended that the extent of a positive margin should be reported as millimeters of involvement.

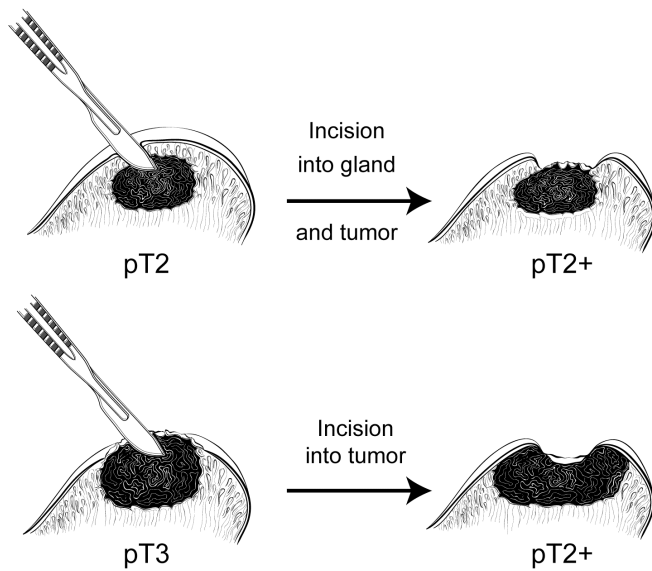


Figure 1. Surgical incision can create stage pT2+ from either pT2 or pT3 disease.

J. Apex and Bladder Neck

The apex should be carefully examined because it is a common site of margin positivity.²⁸⁻³¹ At the apex, tumor admixed with skeletal muscle elements does not constitute extraprostatic extension. The apical and bladder neck surgical margins should be submitted entirely, preferably with a perpendicular sectioning technique. Microscopic involvement of bladder neck muscle fibers in radical prostatectomy specimens indicates pT3a disease.³⁷

K. TNM and Stage Groupings

The protocol recommends the use of the TNM Staging System for carcinoma of the prostate of the American Joint Committee on Cancer (AJCC) and the International Union Against Cancer (UICC).³⁸

By AJCC/UICC convention, the designation "T" refers to a primary tumor that has not been previously treated. The symbol "p" refers to the pathologic classification of the TNM, as opposed to the clinical classification, and is based on gross and microscopic examination. pT entails a resection of the primary tumor or biopsy adequate to evaluate the highest pT category, pN entails removal of nodes adequate to validate lymph node metastasis, and pM implies microscopic examination of distant lesions. Clinical classification (cTNM) is usually carried out by the referring physician before treatment during initial evaluation of the patient or when pathologic classification is not possible.

Pathologic staging is usually performed after surgical resection of the primary tumor. Pathologic staging depends on pathologic documentation of the anatomic extent of disease, whether or not the primary tumor has been completely removed. If a biopsied tumor is not resected for any reason (eg, when technically unfeasible), and if the highest T and N categories or the M1 category of the tumor can be

confirmed microscopically, the criteria for pathologic classification and staging have been satisfied without total removal of the primary cancer. pT2, pT3a, and pT3b are illustrated in Figures 2 through 5.³⁹

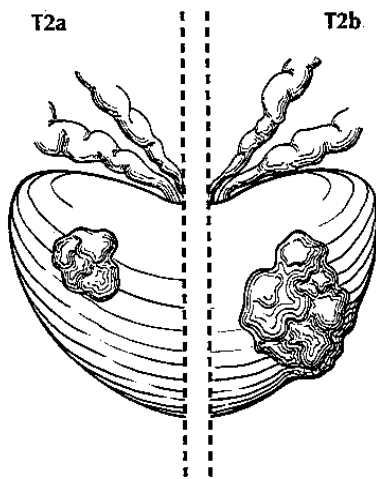


Figure 2. T2a (left) shows tumor involving one-half of one lobe (side) or less whereas T2b (right) shows tumor involving more than one-half of one lobe but not both lobes. Used with permission of the American Joint Committee on Cancer (AJCC), Chicago, Ill. The original source for this material is the *AJCC Cancer Staging Atlas* (2006) edited by Greene et al³⁹ and published by Springer Science and Business Media, LLC, www.springerlink.com.

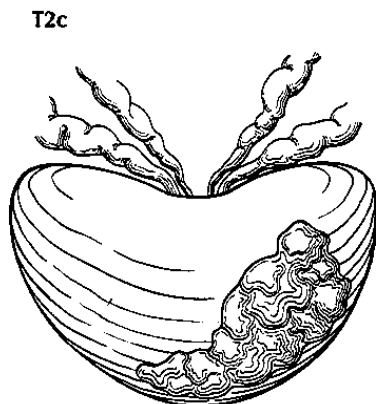


Figure 3. T2c tumor involving both lobes (sides). Used with permission of the American Joint Committee on Cancer (AJCC), Chicago, Ill. The original source for this material is the *AJCC Cancer Staging Atlas* (2006) edited by Greene et al³⁹ and published by Springer Science and Business Media, LLC, www.springerlink.com.

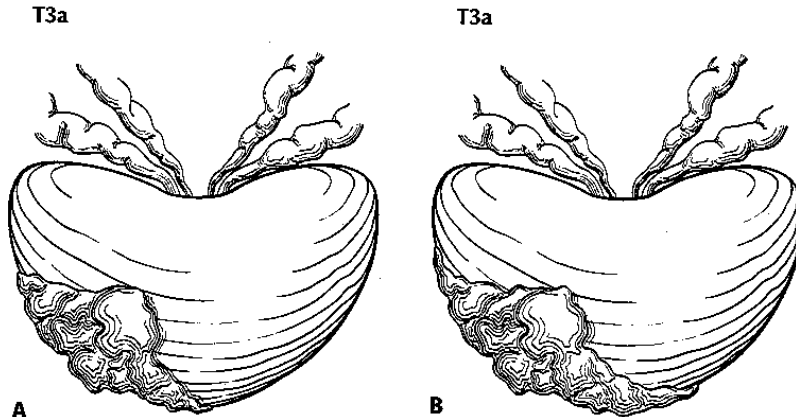


Figure 4. T3a is defined as a tumor with unilateral extraprostatic extension, as shown in A, or with bilateral extension, as shown in B. Microscopic extension into the bladder neck is also pT3a. Used with permission of the American Joint Committee on Cancer (AJCC), Chicago, Ill. The original source for this material is the *AJCC Cancer Staging Atlas* (2006) edited by Greene et al³⁹ and published by Springer Science and Business Media, LLC, www.springerlink.com.

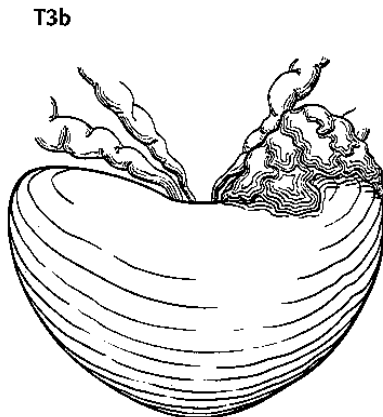


Figure 5. T3b tumor invading the seminal vesicle. Used with permission of the American Joint Committee on Cancer (AJCC), Chicago, Ill. The original source for this material is the *AJCC Cancer Staging Atlas* (2006) edited by Greene et al³⁹ and published by Springer Science and Business Media, LLC, www.springerlink.com.

Regional and Distant Lymph Nodes

Regional Lymph Nodes

The regional lymph nodes are the nodes of the true pelvis, which essentially are the pelvic nodes below the bifurcation of the common iliac arteries. They include the following groups:

- Pelvic, NOS
- Hypogastric
- Obturator
- Iliac (internal, external, or NOS)
- Sacral (lateral, presacral, promontory [Gerota's], or NOS)

Laterality does not affect the N classification.

Distant Lymph Nodes

Distant lymph nodes lie outside the confines of the true pelvis. They can be imaged using ultrasound, computed tomography, magnetic resonance imaging, or lymphangiography. Although enlarged lymph

nodes can occasionally be visualized on radiographic imaging, fewer patients are initially discovered with clinically evident metastatic disease. In lower risk patients, imaging tests have proven unhelpful. In lieu of imaging, risk tables are many times used to determine individual patient risk of nodal involvement prior to therapy. Involvement of distant lymph nodes is classified as M1a. The distant lymph nodes include the following:

- Aortic (para-aortic lumbar)
- Common iliac
- Inguinal, deep
- Superficial inguinal (femoral)
- Supraclavicular
- Cervical
- Scalene
- Retroperitoneal, NOS

Primary Tumor (T): Clinical Classification

TX	Primary tumor cannot be assessed
T0	No evidence of primary tumor
T1	Clinically inapparent tumor neither palpable nor visible by imaging
T1a	Tumor incidental histologic finding in 5% or less of tissue resected
T1b	Tumor incidental histologic finding in more than 5% of tissue resected
T1c	Tumor identified by needle biopsy (eg, because of elevated prostate specific antigen [PSA])
T2	Tumor confined within prostate#
T2a	Tumor involves one-half of one lobe or less
T2b	Tumor involves more than one-half of one lobe but not both lobes
T2c	Tumor involves both lobes
T3	Tumor extends through the prostate capsule##
T3a	Extracapsular extension (unilateral or bilateral) including microscopic bladder neck involvement
T3b	Tumor invades seminal vesicle(s)
T4	Tumor is fixed or invades adjacent structures other than seminal vesicles: bladder neck, external sphincter, rectum, levator muscles, and/or pelvic wall

Tumor found in one or both lobes by needle biopsy, but not palpable or reliably visible by imaging, is classified as T1c.

Invasion into the prostatic apex or into (but not beyond) the prostatic capsule is classified not as T3 but as T2.

The 2009 Anatomic Stage/Prognostic Groups incorporate serum PSA level and Gleason score:

Anatomic Stage / Prognostic Groups

Group	T	N	M	PSA	Gleason
I	T1a – c	N0	M0	PSA <10	Gleason ≤6
	T2a	N0	M0	PSA <10	Gleason ≤6
	T1 – 2a	N0	M0	PSA X	Gleason X
IIA	T1 a – c	N0	M0	PSA <20	Gleason 7
	T1 a – c	N0	M0	PSA ≥10 <20	Gleason ≤6
	T2a	N0	M0	PSA ≥10 <20	Gleason ≤6
	T2a	N0	M0	PSA <20	Gleason 7
	T2b	N0	M0	PSA <20	Gleason ≤7
	T2b	N0	M0	PSA X	Gleason X
IIB	T2c	N0	M0	Any PSA	Any Gleason
	T1 – 2	N0	M0	PSA ≥20	Any Gleason
	T1 – 2	N0	M0	Any PSA	Gleason ≥8
III	T3 a – c	N0	M0	Any PSA	Any Gleason
IV	T4	N0	M0	Any PSA	Any Gleason
	Any T	N1	M0	Any PSA	Any Gleason
	Any T	Any N	M1	Any PSA	Any Gleason

Note: When either prostate specific antigen (PSA) or Gleason is not available, grouping should be determined by T stage and/or whichever of either the PSA or Gleason is available.

TNM Descriptors

For identification of special cases of TNM or pTNM classifications, the “m” suffix and the “y,” “r,” and “a” prefixes are used. Although they do not affect the stage grouping, they indicate cases needing separate analysis.

The “m” suffix indicates the presence of multiple primary tumors in a single site and is recorded in parentheses: pT(m)NM.

The “y” prefix indicates those cases in which classification is performed during or following initial multimodality therapy (ie, neoadjuvant chemotherapy, radiation therapy, or both chemotherapy and radiation therapy). The cTNM or pTNM category is identified by a “y” prefix. The ycTNM or ypTNM categorizes the extent of tumor actually present at the time of that examination. The “y” categorization is not an estimate of tumor prior to multimodality therapy (ie, before initiation of neoadjuvant therapy).

The “r” prefix indicates a recurrent tumor when staged after a documented disease-free interval, and is identified by the “r” prefix: rTNM.

The “a” prefix designates the stage determined at autopsy: aTNM.

Additional DescriptorsResidual Tumor (R)

Tumor remaining in a patient after therapy with curative intent (eg, surgical resection for cure) is categorized by a system known as R classification, shown below.

RX	Presence of residual tumor cannot be assessed
R0	No residual tumor
R1	Microscopic residual tumor
R2	Macroscopic residual tumor

For the surgeon, the R classification may be useful to indicate the known or assumed status of the completeness of a surgical excision. For the pathologist, the R classification is relevant to the status of the margins of a surgical resection specimen. That is, tumor involving the resection margin on pathologic examination may be assumed to correspond to residual tumor in the patient and may be classified as macroscopic or microscopic according to the findings at the specimen margin(s).

Lymph-Vascular Invasion

Lymph-vascular invasion (LVI) indicates whether microscopic lymph-vascular invasion is identified. LVI includes lymphatic invasion, vascular invasion, or lymph-vascular invasion. By AJCC/UICC convention, LVI does not affect the T category indicating local extent of tumor unless specifically included in the definition of a T category.

References

1. Young RH, Srigley JR, Amin MB, Ulbright TM, Cubilla A. Tumors of the Prostate Gland, Seminal Vesicle, Male Urethra and Penis. Washington, DC: Armed Forces Institute of Pathology; 2000. *Atlas of Tumor Pathology*. 3rd series, fascicle 28.
2. Gleason DR, Mellinger GT, the Veterans Administration Cooperative Urological Research Group. Prediction of prognosis for prostate adenocarcinoma by combined histological grading and clinical staging. *J Urol*. 1974;111:58-64.
3. Amin MB, Grignon DJ, Humphrey PA, Srigley JR. *Gleason Grading of Prostate Cancer. A Contemporary Approach*. Philadelphia, PA: Lippincott Williams & Wilkins; 2004.
4. Stephenson AJ, Scardino PT, Eastham JA, et al. Preoperative nomogram predicting the 10-year probability of prostate cancer recurrence after radical prostatectomy. *J Natl Cancer Inst*. 2006;98:715-717.
5. Stephenson AJ, Scardino PT, Eastham JA, et al. Postoperative nomogram predicting the 10-year probability of prostate cancer recurrence after radical prostatectomy. *J Clin Oncol*. 2005;23:7005-7012.
6. Makarov DV, Trock BJ, Humphreys EB, et al. Updated nomogram to predict pathologic stage of prostate cancer given prostate-specific antigen level, clinical stage, and biopsy Gleason score (Partin tables) based on cases from 2000 to 2005. *Urology*. 2007;69:1095-1101.
7. Epstein JI, Allsbrook WC Jr, Amin MB, Egevad LL; ISUP Grading Committee. The 2005 International Society of Urological Pathology (ISUP) Consensus Conference on Gleason Grading of Prostatic Carcinoma. *Am J Surg Pathol*. 2005;29(9):1228-1242.
8. Patel AA, Chen M-H, Renshaw AA, D'Amico AV. PSA failure following definitive treatment of prostate cancer having biopsy Gleason score 7 with tertiary grade 5. *JAMA*. 2007;298:1533-1538.
9. Amin M, Boccon-Gibod L, Egevad L, et al. Prognostic and predictive factors and reporting of prostate carcinoma in prostate needle biopsy specimens. (2004 WHO-sponsored International Consultation Consensus). *Scand J Urol Nephrol*. 2004;39(216 suppl):20-33.
10. Cupp MR, Bostwick DG, Myers RP, Oesterling JE. The volume of prostate cancer in the biopsy specimen cannot reliably predict the quantity of cancer in the radical prostatectomy on an individual basis. *J Urol*. 1995;153:1543-1548.

11. Ravery V, Boccon-Gibod LA, Dauge-Geffroy MC, et al. Systematic biopsies accurately predict extracapsular extension of prostate cancer and persistent/recurrent detectable PSA after radical prostatectomy. *Urology*. 1994;44:371-376.
12. Ravery V, Schmid HP, Toubanc M, Boccon-Gibod L. Is the percentage of cancer in biopsy cores predictive of extracapsular disease in T1-T2 prostate carcinoma? *Cancer*. 1996;78:1079-1084.
13. Freedland SJ, Csathy GS, Dorey F, et al. Percent prostate needle biopsy tissue with cancer is more predictive of biochemical failure or adverse pathology after radical prostatectomy than prostate specific antigen or Gleason score. *J Urol*. 2002;167:516-520.
14. Bismar TA, Lewis JS, JR, Vollmer RT, Humphrey PA. Multiple measures of carcinoma extent versus perineural invasion in prostate needle biopsy tissue in prediction of pathologic stage in a screening population. *Am J Surg Pathol*. 2003;27:432-440.
15. Stamey TA, Freiha FS, McNeal JE, Redwine EA, Whittemore AS, Schmid HP. Localized prostate cancer: relationship of tumor volume to clinical significance for treatment of prostate cancer. *Cancer*. 1993;71(3)(suppl):933-938.
16. Renshaw AA, Richie JP, Loughlin KR, Jiroutek M, Chung A, D'Amico AV. Maximum diameter of prostatic carcinoma is a simple, inexpensive, and independent predictor of prostate-specific antigen failure in radical prostatectomy specimens: validation in a cohort of 434 patients. *Am J Clin Pathol*. 1999;111:641-644.
17. Humphrey PA, Vollmer RT. Percentage carcinoma as a measure of prostatic tumor size in radical prostatectomy tissues. *Mod Pathol*. 1997;10:326-333.
18. Ohori M, Scardino PT, Lapin SL, Seale-Hawkins C, Link J, Wheeler TM. The mechanisms and prognostic significance of seminal vesicle involvement by prostate cancer. *Am J Surg Pathol*. 1993;17:1252-1261.
19. Yu HH, Song DY, Tsai YY, Thompson T, Frassica DA, DeWeese TL. Perineural invasion affects biochemical recurrence-free survival in patients with prostate cancer treated with definitive external beam radiotherapy. *Urology*. 2007;70:111-116.
20. O'Malley KJ, Pound CR, Walsh PC, Epstein JI, Partin AW. Influence of biopsy perineural invasion on long-term biochemical disease-free survival after radical prostatectomy. *Urology*. 2002;59:85-90.
21. Harnden P, Shelley MD, Clements H, et al. The prognostic significance of perineural invasion in prostatic carcinoma biopsies: a systematic review. *Cancer*. 2007;109:13-24.
22. Vargas SO, Jiroutek M, Welch MR, Nucci MR, D'Amico AV, Renshaw AA. Perineural invasion in prostate needle biopsy specimens: correlation with extraprostatic extension at resection. *Am J Clin Pathol*. 1999;111:223-228.
23. Epstein JI, Herawi M. Prostate needle biopsies containing prostatic intraepithelial neoplasia or atypical foci suspicious for carcinoma: implications for patient care. *J Urol*. 2006;175:820-834.
24. Netto GJ, Epstein JI. Widespread high-grade prostatic intraepithelial neoplasia on prostatic needle biopsy: a significant likelihood of subsequently diagnosed adenocarcinoma. *Am J Surg Pathol*. 2006;30:1184-1188.
25. Gokden N, Roehl KA, Catalona WJ, Humphrey PA. High-grade prostatic intraepithelial neoplasia in needle biopsy as risk factor for detection of adenocarcinoma: current level of risk in screening population. *Urology*. 2005;65:538-542.
26. Merrimen JL, Jones G, Walker D, Leung CS, Kapusta LR, Srigley JR. Multifocal high grade prostatic intraepithelial neoplasia is a significant risk factor for prostatic adenocarcinoma. *J Urol*. 2009;182(2):485-490; discussion 490. Epub 2009 Jun 13.
27. Humphrey PA, Walther PJ. Adenocarcinoma of the prostate, I: sampling considerations. *Am J Clin Pathol*. 1993;99:746-759.
28. Srigley JR. Key issues in handling and reporting radical prostatectomy specimens. *Arch Pathol Lab Med*. 2006;30:303-317.
29. Sehdev AE, Pan CC, Epstein JI. Comparative analysis of sampling methods for grossing radical prostatectomy specimens performed for nonpalpable (stage T1c) prostatic adenocarcinoma. *Hum Pathol*. 2001;32:494-499.

30. Wheeler TM, Dillioglulugil O, Kattan MW, et al. Clinical and pathological significance of the level and extent of capsular invasion in clinical stage T1-2 prostate cancer. *Hum Pathol.* 1998;29:856-862.
31. Ohori M, Kattan M, Scardino PT, Wheeler TM. Radical prostatectomy for carcinoma of the prostate. *Mod Pathol.* 2004;17:349-359.
32. Epstein JI, Amin M, Boccon-Gibod L, et al. Prognostic factors and reporting of prostate carcinoma in radical prostatectomy and pelvic lymphadenectomy specimens. *Scand J Urol Nephrol.* 2005;216(suppl):34-63.
33. Epstein JI, Sauvageot J. Do close but negative margins in radical prostatectomy specimens increase the risk of postoperative progression? *J Urol.* 1997;157:241-243.
34. Graefen M, Hammerer P, Michl U, et al. Incidence of positive surgical margins after biopsy-selected nerve-sparing radical prostatectomy. *Urology.* 1998;51:437-442.
35. Ohori M, Wheeler T, Kattan MW, et al. Prognostic significance of positive surgical margins in radical prostatectomy specimens. *J Urol.* 1995;154:1818-1824.
36. Epstein JI, Partin AW, Sauvageot J, Walsh PC. Prediction of progression following radical prostatectomy: a multivariate analysis of 721 men with long-term follow-up. *Am J Surg Pathol.* 1996;20:286-292.
37. Aydin H, Tsuzuki T, Hernandez D, Walsh PC, Partin AW, Epstein JI. Positive proximal (bladder neck) margin at radical prostatectomy confers greater risk of biochemical progression. *Urology.* 2004;64:551-555.
38. Edge SB, Byrd DR, Carducci MA, Compton CC, eds. *AJCC Cancer Staging Manual.* 7th ed. New York, NY: Springer; 2009.
39. Greene FL, Compton CC, Fritz AG, Shah J, Winchester DP, eds. *AJCC Cancer Staging Atlas.* New York, NY: Springer; 2006.