



Protocol for the Examination of Specimens From Patients With Carcinoma of the Prostate Gland

Version: Prostate 4.0.2.0

Protocol Posting Date: June 2017

Includes pTNM requirements from the 8th Edition, AJCC Staging Manual

For accreditation purposes, this protocol should be used for the following procedures AND tumor types:

Procedure	Description
Prostatectomy	Includes specimens designated radical prostatectomy
Tumor Type	Description
Carcinoma	Including all adenocarcinomas and histologic variants, neuroendocrine tumors, and small cell carcinomas.

This protocol is NOT required for accreditation purposes for the following:

Procedure
Needle biopsies, transurethral resection of the prostate gland (TURP) [#] or enucleations
Primary resection specimen with no residual cancer (eg, following neoadjuvant therapy)
Cytologic specimens

[#] *Transurethral resection of the prostate is NOT considered to be the definitive resection specimen, even though the entire cancer may be removed. This protocol is recommended for reporting TURP specimens for clinical care purposes, but it is not required for accreditation purposes.*

The following tumor types should NOT be reported using this protocol:

Tumor Type
Urothelial tumor, including variants (consider the Urethra (prostatic urethra) protocol)
Lymphoma (consider the Hodgkin or non-Hodgkin Lymphoma protocols)
Sarcoma (consider the Soft Tissue protocol)

Authors

John R. Srigley, MD*; Ming Zhou, MD, PhD*; Robert Allan, MD; Mahul B. Amin, MD; Sam S. Chang, MD; Brett Delahunt, MD; Lars Egevad, MD; Jonathan I. Epstein, MD; David J. Grignon, MD; Peter A. Humphrey, MD, PhD; James M. McKiernan, MD; Rodolfo Montironi, MD; Jason Pettus, MD; Victor E. Reuter, MD; Thomas M. Wheeler, MD

With guidance from the CAP Cancer and CAP Pathology Electronic Reporting Committees.

* Denotes primary author. All other contributing authors are listed alphabetically.

Accreditation Requirements

This protocol can be utilized for a variety of procedures and tumor types for clinical care purposes. For accreditation purposes, only the definitive primary cancer resection specimen is required to have the core and conditional data elements reported in a synoptic format.

- Core data elements are required in reports to adequately describe appropriate malignancies. For accreditation purposes, essential data elements must be reported in all instances, even if the response is “not applicable” or “cannot be determined.”
- Conditional data elements are only required to be reported if applicable as delineated in the protocol. For instance, the total number of lymph nodes examined must be reported, but only if nodes are present in the specimen.
- Optional data elements are identified with “+” and although not required for CAP accreditation purposes, may be considered for reporting as determined by local practice standards.

The use of this protocol is not required for recurrent tumors or for metastatic tumors that are resected at a different time than the primary tumor. Use of this protocol is also not required for pathology reviews performed at a second institution (ie, secondary consultation, second opinion, or review of outside case at second institution).

Synoptic Reporting

All core and conditionally required data elements outlined on the surgical case summary from this cancer protocol must be displayed in synoptic report format. Synoptic format is defined as:

- Data element: followed by its answer (response), outline format without the paired "Data element: Response" format is NOT considered synoptic.
- The data element should be represented in the report as it is listed in the case summary. The response for any data element may be modified from those listed in the case summary, including “Cannot be determined” if appropriate.
- Each diagnostic parameter pair (Data element: Response) is listed on a separate line or in a tabular format to achieve visual separation. The following exceptions are allowed to be listed on one line:
 - Anatomic site or specimen, laterality, and procedure
 - Pathologic Stage Classification (pTNM) elements
 - Negative margins, as long as all negative margins are specifically enumerated where applicable
- The synoptic portion of the report can appear in the diagnosis section of the pathology report, at the end of the report or in a separate section, but all Data element: Responses must be listed together in one location

Organizations and pathologists may choose to list the required elements in any order, use additional methods in order to enhance or achieve visual separation, or add optional items within the synoptic report. The report may have required elements in a summary format elsewhere in the report IN ADDITION TO but not as replacement for the synoptic report i.e. all required elements must be in the synoptic portion of the report in the format defined above.

CAP Laboratory Accreditation Program Protocol Required Use Date: March 2018*

* Beginning January 1, 2018, the 8th edition AJCC Staging Manual should be used for reporting pTNM.

CAP Prostate Protocol Summary of Changes

Version 4.0.2.0:

Tumor quantitation in the Radical Prostatectomy checklist

- **MODIFIED** from a core data element to an optional data element
- **MODIFIED** measurement of enucleated specimens from centimeters to millimeters

Version 4.0.1.0 errata:

Size of Largest Metastatic Deposit

- **MODIFIED** Unit of measure from millimeters to centimeters

Version 4.0.0.0:

The following data elements were modified:

Pathologic Stage Classification (pTNM, AJCC 8th Edition)

Surgical Pathology Cancer Case Summary

Protocol posting date: June 2017

PROSTATE GLAND: Needle Biopsy (Specimen-Level Summary) (Note A)

Note: This case summary is recommended for reporting biopsy specimens, but is not required for accreditation purposes.

Select a single response unless otherwise indicated.

Histologic Type (select all that apply) (Note B)

- Acinar adenocarcinoma
 Ductal adenocarcinoma
 Small-cell neuroendocrine carcinoma
 Other histologic type not listed (specify): _____

Histologic Grade (Note C)

Gleason Pattern

- Not applicable
 Cannot be assessed

Gleason Pattern, Score, and Grade Group (only if applicable and if Gleason pattern can be assessed)

Note: Gleason patterns and score may be reported on a single line.

Primary Gleason (Predominant) Pattern

- Pattern 3
 Pattern 4
 Pattern 5

Worst Remaining Gleason Pattern[#]

- Pattern 3
 Pattern 4
 Pattern 5

[#] *Note: If 3 patterns present, use most predominant pattern and worst pattern of remaining 2. . If only 2 patterns are present, Gleason score is the sum of the primary and secondary grades.*

Gleason Score: _____

Grade Group (Note D)

- Grade group 1
 Grade group 2
 Grade group 3
 Grade group 4
 Grade group 5

Percentage of Pattern 4 in Gleason Score 3+4=7 Cancer (only if applicable): _____%

+ Percentage of Gleason Patterns 4 and 5 (applicable to Gleason score ≥ 7) (Note E)

- + Percentage of pattern 4: _____%
 + Percentage of pattern 5: _____%

+ Data elements preceded by this symbol are not required for accreditation purposes. These optional elements may be clinically important but are not yet validated or regularly used in patient management.

+ Intraductal Carcinoma (IDC) (Note F)

- + ___ Not identified
- + ___ Present

Tumor Quantitation (Note G)

Number cores positive: ____
Total number of cores: ____
____ Cannot be determined
and
Percentage of prostatic tissue involved by tumor: ____%

or

Number cores positive: ____
Total number of cores: ____
____ Cannot be determined
and
Total linear millimeters of carcinoma (millimeters): ____ mm
Total linear millimeters of needle core tissue (millimeters): ____ mm

or

Number cores positive: ____
Total number of cores: ____
____ Cannot be determined
and
Percentage of prostatic tissue involved by tumor: ____%
and
Total linear millimeters of carcinoma (millimeters): ____ mm
Total linear millimeters of needle core tissue (millimeters): ____mm

+ Percentage of prostatic tissue involved by tumor for core with the greatest amount of tumor: ____%

Periprostatic Fat Invasion (required only if identified in specimen) (Note H)

- + ___ Not identified
 - ___ Present
- Specify site: _____

Seminal Vesicle/Ejaculatory Duct Invasion (required only if identified in specimen) (Note H)

- + ___ Not identified
- ___ Present

+ Lymphovascular Invasion

- + ___ Not identified
- + ___ Present
- + ___ Cannot be determined

+ Perineural Invasion (Note I)

- + ___ Not identified
- + ___ Present

+ Data elements preceded by this symbol are not required for accreditation purposes. These optional elements may be clinically important but are not yet validated or regularly used in patient management.

+ Additional Pathologic Findings (select all that apply)

- + None identified
- + High-grade prostatic intraepithelial neoplasia (PIN) (Note J)
- + Atypical adenomatous hyperplasia (adenosis)
- + Inflammation (specify type): _____
- + Other (specify): _____

+ Comment(s)

Surgical Pathology Cancer Case Summary

Protocol posting date: June 2017

PROSTATE GLAND: Needle Biopsy (Case-Level Summary) (Note A)

Note: For accreditation purposes the use of case-level summary is not required.

Select a single response unless otherwise indicated.

In situations where a case level summary is used and specimen level summaries are not used, the Gleason patterns, score, grade group and tumor extent should be documented for each positive specimen (container) in the line diagnosis. The essential information could be conveyed with a simple diagnostic line such as, “Adenocarcinoma, Gleason grade 3 + 4 = score of 7 (Grade group 2), in 1 of 2 cores, involving 20% of needle core tissue, and measuring 4 mm in length.” (Note A.)

+ Histologic Type (select all that apply) (Note B)

- + ___ Acinar adenocarcinoma
- + ___ Ductal adenocarcinoma
- + ___ Small-cell neuroendocrine carcinoma
- + ___ Other histologic type not listed (specify): _____

+ Histologic Grade (Note C)

+ Gleason Score in Site (Specimen) With Highest Gleason Score

Note: This applies in cases where there are 2 or more cores involved by cancer with different Gleason scores or 2 or more sites (containers) contain cancer with different Gleason scores.

- + Highest Gleason Score: _____
- + Site(s) with Highest Gleason Score (specify): _____

Gleason Pattern, Score, and Grade Group (only if applicable and if Gleason pattern can be assessed)

Note: Gleason patterns and score may be reported on a single line.

+ Primary Gleason Pattern

- + ___ Pattern 3
- + ___ Pattern 4
- + ___ Pattern 5

+ Worst Remaining Gleason Pattern[#]

- + ___ Pattern 3
- + ___ Pattern 4
- + ___ Pattern 5

[#] *Note: If 3 patterns present, use most predominant pattern and worst pattern of remaining 2. If only 2 patterns are present, Gleason score is the sum of the primary and secondary grades.*

+ Grade Group (based on specimen with highest Gleason Score) (Note D)

- + ___ Grade group 1
- + ___ Grade group 2
- + ___ Grade group 3
- + ___ Grade group 4
- + ___ Grade group 5

+ Data elements preceded by this symbol are not required for accreditation purposes. These optional elements may be clinically important but are not yet validated or regularly used in patient management.

+ Percentage of Pattern 4 in Gleason Score 3+4=7 Cancer
+ Specify: ____%

+ Percentage Gleason Patterns 4 and 5 (applicable to Gleason score ≥ 7) (Note E)
+ Percentage pattern 4: ____%
+ Percentage pattern 5: ____%

+ Composite (Total) Gleason Score

Gleason Pattern, Score, and Grade Group (only if applicable and if Gleason pattern can be assessed)

Note: Gleason patterns and score may be reported on a single line.

+ Primary (Predominant) Gleason Pattern
+ ___ Pattern 3
+ ___ Pattern 4
+ ___ Pattern 5

+ Worst Remaining Gleason Pattern[#]
+ ___ Pattern 3
+ ___ Pattern 4
+ ___ Pattern 5

Note: If 3 patterns present, use most predominant pattern and worst pattern of remaining 2

+ Grade Group (based on composite Gleason Score)
+ ___ Grade group 1
+ ___ Grade group 2
+ ___ Grade group 3
+ ___ Grade group 4
+ ___ Grade group 5

+ Intraductal Carcinoma (IDC) (Note F)

+ ___ Not identified
+ ___ Present

+ Tumor Quantitation (Note G)

+ Number cores positive: ____
+ Total number of cores: ____
+ ___ Cannot be determined

+ Greatest length of core involvement by cancer in any core (millimeters): ____ mm
+ Specify site(s): _____
+ Greatest percentage of core involvement by cancer in any core: ____%
+ Specify site(s) ____

+ Percentage of total prostatic tissue involved by tumor: ____%

and/or

+ Total linear millimeters of carcinoma (millimeters): ____ mm
+ Total linear millimeters of needle core tissue (millimeters): ____ mm

+ Periprostatic Fat Invasion (Note H)

+ ___ Not identified
+ ___ Present

+ Data elements preceded by this symbol are not required for accreditation purposes. These optional elements may be clinically important but are not yet validated or regularly used in patient management.

+ Seminal Vesicle/Ejaculatory Duct Invasion (Note H)

- + ___ Not identified
- + ___ Present

+ Lymphovascular Invasion

- + ___ Not identified
- + ___ Present
- + ___ Cannot be determined

+ Perineural Invasion (Note I)

- + ___ Not identified
- + ___ Present

+ Additional Pathologic Findings (select all that apply)

- + ___ None identified
- + ___ High-grade prostatic intraepithelial neoplasia (PIN) (Note J)
- + ___ Atypical adenomatous hyperplasia (adenosis)
- + ___ Inflammation (specify type): _____
- + ___ Other (specify): _____

+ Comment(s)

Surgical Pathology Cancer Case Summary

Protocol posting date: June 2017

PROSTATE GLAND: Transurethral Prostatic Resection (TURP), Enucleation Specimen (Subtotal Prostatectomy)

Note: This case summary is recommended for reporting TURP specimens, but is not required for accreditation purposes.

Select a single response unless otherwise indicated.

Procedure

- Transurethral prostatic resection (Note K)
 Enucleation
 Other (specify): _____
 Not specified

Histologic Type (select all that apply) (Note B)

- Acinar adenocarcinoma
 Ductal adenocarcinoma
 Small-cell neuroendocrine carcinoma
 Other histologic type not listed (specify): _____

Histologic Grade (Note C)

Gleason Pattern

- Not applicable
 Cannot be assessed

Gleason Pattern, Score, and Grade Group (only if applicable and if Gleason pattern can be assessed)

Note: Gleason patterns and score may be reported on a single line.

Primary (Predominant) Gleason Pattern

- Pattern 1
 Pattern 2
 Pattern 3
 Pattern 4
 Pattern 5

Secondary (Worst Remaining) Gleason Pattern[#]

- Pattern 1
 Pattern 2
 Pattern 3
 Pattern 4
 Pattern 5

[#] *Note: If 3 patterns present, use most predominant pattern and worst pattern of remaining 2. If only 2 patterns are present, Gleason score is the sum of the primary and secondary grades.*

Total Gleason Score: _____

Grade Group (Note D)

- Grade group 1
 Grade group 2

+ Data elements preceded by this symbol are not required for accreditation purposes. These optional elements may be clinically important but are not yet validated or regularly used in patient management.

- Grade group 3
- Grade group 4
- Grade group 5

Percentage of Pattern 4 in Gleason Score 3+4=7 Cancer (only if applicable)

Specify: _____%

+ Percentage Gleason Patterns 4 and 5 (applicable to Gleason score ≥ 7) (Note E)

- + Percentage pattern 4: _____%
- + Percentage pattern 5: _____%

+ Intraductal Carcinoma (IDC) (Note F)

- + Not identified
- + Present

Tumor Quantitation (Note G)For TURP Specimens

- Estimated percentage of prostatic tissue involved by tumor: _____%
- + Number of positive chips: _____
- + Total number of chips: _____

For Enucleation and Other Specimens

- Estimated percentage of prostatic tissue involved by tumor: _____%
- + Tumor size (dominant nodule, if present):
 - + Greatest dimension (millimeters): _____ mm
 - + Additional dimensions (millimeters): _____ x _____ mm

Periprostatic Fat Invasion (required only if identified in specimen) (Note H)

- + Not identified
- Present

Seminal Vesicle Invasion (required only if identified in specimen) (Note H)

- + Not identified
- Present

+ Lymphovascular Invasion

- + Not identified
- + Present
- + Cannot be determined

+ Perineural Invasion (Note I)

- + Not identified
- + Present

+ Additional Pathologic Findings (select all that apply)

- + None identified
- + High-grade prostatic intraepithelial neoplasia (PIN) (Note J)
- + Atypical adenomatous hyperplasia (adenosis)
- + Nodular prostatic hyperplasia
- + Inflammation (specify type): _____
- + Other (specify): _____

+ Comment(s)

+ Data elements preceded by this symbol are not required for accreditation purposes. These optional elements may be clinically important but are not yet validated or regularly used in patient management.

Surgical Pathology Cancer Case Summary

Protocol posting date: June 2017

PROSTATE GLAND: Radical Prostatectomy**Select a single response unless otherwise indicated.****Procedure (Note K)**

- Radical prostatectomy
 Other (specify): _____
 Not specified

+Prostate Size (Note K)

- + Weight: ___ g
 + Size (centimeters): ___ x ___ x ___ cm

Histologic Type (select all that apply) (Note B)

- Acinar adenocarcinoma
 Ductal adenocarcinoma
 Small-cell neuroendocrine carcinoma
 Other histologic type not listed (specify): _____

Histologic Grade (select all that apply) (Note C)Gleason Pattern

- Not applicable
 Cannot be assessed

Gleason Pattern, Score and Grade Group (required only if applicable and if Gleason pattern can be assessed)*Note: Gleason patterns and score may be reported on a single line.*Primary Gleason Pattern

- Pattern 1
 Pattern 2
 Pattern 3
 Pattern 4
 Pattern 5

Secondary Gleason Pattern

- Pattern 1
 Pattern 2
 Pattern 3
 Pattern 4
 Pattern 5

Tertiary Gleason Pattern[#]

- Pattern 3
 Pattern 4
 Pattern 5
 Not applicable

[#] Note: If 3 patterns are present, record the most predominant and second most common patterns; the tertiary pattern should be recorded if higher than the primary and secondary patterns but it is not incorporated into the Gleason score if <5%. If the tertiary pattern 5 comprises >5% of the tumor, some pathologists incorporate it into the Gleason score as secondary pattern.

Total Gleason Score: ____

Grade Group (Note D)

- ___ Grade group 1
- ___ Grade group 2
- ___ Grade group 3
- ___ Grade group 4
- ___ Grade group 5

+ Percentage of Gleason Patterns 4 and 5 (applicable to Gleason score ≥7) (Note E)

- + Percentage of pattern 4: ____%
- + Percentage of pattern 5: ____%

+ **Intraductal Carcinoma (IDC) (Note F)**

- + ___ Not identified
- + ___ Present

Tumor Quantitation (Note G)

- + Estimated percentage of prostate involved by tumor: ____%
- and/or
- + Tumor size (dominant nodule, if present):
 - + Greatest dimension (millimeters): ____ mm
 - + Additional dimensions (millimeters): ____ x ____ mm
 - + Location of dominant nodule _____

Extraprostatic Extension (EPE) (Note L)

- ___ Not identified
- ___ Present, focal
- ___ Present, nonfocal
- ___ Cannot be determined

+ Location of Extraprostatic Extension (select all that apply)

- + ___ Right apical
- + ___ Right bladder neck
- + ___ Right anterior
- + ___ Right lateral
- + ___ Right postero-lateral (neurovascular bundle)
- + ___ Right posterior
- + ___ Left apical
- + ___ Left bladder neck
- + ___ Left anterior
- + ___ Left lateral
- + ___ Left postero-lateral (neurovascular bundle)
- + ___ Left posterior
- + ___ Other(s) (specify): _____

Urinary Bladder Neck Invasion (Note M)

- ___ Not identified
- ___ Present

+ Data elements preceded by this symbol are not required for accreditation purposes. These optional elements may be clinically important but are not yet validated or regularly used in patient management.

Seminal Vesicle Invasion (Note N)

- Not identified
- Present
 - + Right
 - + Left
 - + Bilateral
- No seminal vesicle present

Margins (Note O)

- Cannot be assessed
- Uninvolved by invasive carcinoma
 - + Benign prostate glands present at surgical margin
- Involved by invasive carcinoma
 - Limited (<3 mm)
 - Non-limited (≥3 mm)
- + Linear length of positive margin(s) (millimeters): _____ mm
- + Focality
 - + Unifocal
 - + Multifocal

Location of Positive Margin(s) (select all that apply)

- Right apical
- Right bladder neck
- Right anterior
- Right lateral
- Right postero-lateral (neurovascular bundle)
- Right posterior
- Left apical
- Left bladder neck
- Left anterior
- Left lateral
- Left postero-lateral (neurovascular bundle)
- Left posterior
- Other(s) (specify): _____

+ Margin Positivity in Area of Extraprostatic Extension (EPE)

- + Not identified
- + Present
 - + Specify location(s): _____

+ Gleason Pattern at Positive Margin(s) (Note O)

- + Pattern 3
- + Pattern 4 or 5

Treatment Effect (select all that apply)

- No known presurgical therapy
- Not identified
- Radiation therapy effect present
- Hormonal therapy effect present
- Other therapy effect(s) present (specify): _____
- Cannot be determined

+ Lymphovascular Invasion

- + Not identified

+ Data elements preceded by this symbol are not required for accreditation purposes. These optional elements may be clinically important but are not yet validated or regularly used in patient management.

- + ___ Present
- + ___ Cannot be determined

+ Perineural Invasion (Note I)

- + ___ Not identified
- + ___ Present

Regional Lymph Nodes

___ No lymph nodes submitted or found

Lymph Node Examination (required only if lymph nodes are present in the specimen)

Number of Lymph Nodes Involved: _____

___ Number cannot be determined (explain): _____

+ Specify Site(s): _____ #

Note: Sites may include hypogastric, obturator, internal iliac, external iliac, iliac NOS, lateral sacral, presacral, promontory, sacral NOS, or other lymph nodes.

Number of Lymph Nodes Examined: _____

___ Number cannot be determined (explain): _____

+ Size of Largest Metastatic Deposit (centimeters): ___ cm

+ Specify Site: _____

+ Size of Largest Lymph Node Involved (centimeters): ___ cm

+ Specify Site: _____

+ Extranodal Extension

- + ___ Not identified
- + ___ Present
- + ___ Cannot be determined

Pathologic Stage Classification (pTNM, AJCC 8th Edition) (Note P)

Note: Reporting of pT, pN, and (when applicable) pM categories is based on information available to the pathologist at the time the report is issued. Only the applicable T, N, or M category is required for reporting; their definitions need not be included in the report. The categories (with modifiers when applicable) can be listed on 1 line or more than 1 line.

TNM Descriptors (required only if applicable) (select all that apply)

- ___ m (multiple)
- ___ r (recurrent)
- ___ y (posttreatment)

Primary Tumor (pT)[#]

- ___ pT2: Organ confined
- ___ pT3: Extraprostatic extension
- ___ pT3a: Extraprostatic extension (unilateral or bilateral) or microscopic invasion of bladder neck
- ___ pT3b: Tumor invades seminal vesicle(s)
- ___ pT4: Tumor is fixed or invades adjacent structures other than seminal vesicles such as external sphincter, rectum, bladder, levator muscles, and/or pelvic wall

Note: There is no pathologic T1 classification.

Note: Positive surgical margin should be indicated by an R1 descriptor, indicating residual microscopic disease.

+ Data elements preceded by this symbol are not required for accreditation purposes. These optional elements may be clinically important but are not yet validated or regularly used in patient management.

Regional Lymph Nodes (pN)

- pNX: Regional lymph nodes cannot be assessed
 pN0: No positive regional nodes
 pN1: Metastases in regional node(s)

Distant Metastasis (pM) (required only if confirmed pathologically in this case)[#]

- pM1: Distant metastasis
 pM1a: Nonregional lymph nodes(s)
 pM1b: Bone(s)
 pM1c: Other site(s) with or without bone disease

Specify site(s), if known: _____

[#] Note: When more than one site of metastasis is present, the most advanced category is used. M1c is most advanced.

+ Additional Pathologic Findings (select all that apply)

- + None identified
 + High-grade prostatic intraepithelial neoplasia (PIN) (Note F)
 + Inflammation (specify type): _____
 + Atypical adenomatous hyperplasia (adenosis)
 + Nodular prostatic hyperplasia
 + Other (specify): _____

+ Ancillary Studies

- + Specify: _____
 + Not performed

+ Comment(s): _____

Explanatory Notes

A. Level of Biopsy Reporting (Core, Specimen, Case)

In a prostate biopsy case, 10 to 14 cores are generally received; however, in some protocols, 15 or more cores are provided. In the situation, for example, where 12 cores are submitted, they may be received in 12 separate site-specific labeled containers, 6 containers each with 2 cores with typical sextant designations, or 6 cores in each of 2 containers labeled left and right. In addition to systematic biopsies, MRI-guided biopsies of focal abnormalities are increasingly used, especially in patients being considered for active surveillance. With respect to technical quality, single-core site-specific labeled submission is ideal but 2 core submission is acceptable.¹ When more than 2 cores are submitted in a single container, there is an increased likelihood of fragmentation.

The reporting of prostate biopsies may be done at core, specimen, and case level. The International Society of Urological Pathology (ISUP) recommended in 2005 that Gleason grading be done at the core level, *if the cores are separately identified*.² This approach has been endorsed in the 2016 World Health Organization (WHO) classification.³ For single cores in individual containers, this recommendation is not a problem. When there is more than 1 core in a container, individual core reporting is recommended if the cores are separately labeled as to their specific location with colored inks. In the situation where there are multiple unidentified intact cores submitted in 1 specimen container and each shows cancer, individual reporting may be done; however, some pathologists may choose to report aggregated measurements for each specimen. For the purpose of this protocol, the minimum required reporting is at the specimen level, and more granular reporting would be considered optional. This approach is important as it takes into account workload considerations. In workload measurement systems (at least those based on the CPT system), the units of work are the specimens and not the individual pieces or fragments that constitute a single specimen.

For the purpose of this protocol, two biopsy case summaries are provided. One is a *specimen-level summary*,₁ which would be used for each positive specimen. In a case where 6 of 12 specimens show prostate cancer, 6 specimen summaries would be used. An optional *case-level summary* is also provided, which can be used in conjunction with the specimen level summaries or on its own. In the latter situation, a simple diagnosis documenting the Gleason grades, score, extent measurements, and other relevant observations should be provided for each positive specimen. When 2 or more sites (containers) contain cancer of the same Gleason score, the case-level protocol may be used for the summary of tumor quantification.

B. Histologic Type

This protocol applies only to invasive adenocarcinomas of the prostate gland, as shown below. Carcinomas other than adenocarcinoma are exceptionally uncommon, accounting for less than 0.5% of prostatic tumors. The protocol does not apply to pure squamous cell carcinoma, basal cell carcinoma, urothelial carcinoma, small cell neuroendocrine carcinoma, and large cell neuroendocrine carcinoma. If these rare subtypes of carcinoma, however, are mixed with acinar type adenocarcinoma, the protocol may be used.

Classification of Invasive Adenocarcinoma of Prostate (2016 WHO classification³)

Acinar adenocarcinoma

- Atrophic
- Pseudohyperplastic
- Microcystic
- Foamy gland
- Mucinous (colloid)
- Signet ring-like cell
- Pleomorphic giant cell
- Sarcomatoid

Ductal adenocarcinoma

- Cribriform
- Papillary
- Solid

Neuroendocrine tumors

Adenocarcinoma with neuroendocrine differentiation

Well-differentiated neuroendocrine tumor
 Small-cell neuroendocrine carcinoma
 Large cell neuroendocrine carcinoma

C. Gleason Score

The Gleason grading system is recommended for use in all prostatic specimens containing adenocarcinoma, with the exception of those showing treatment effects, usually in the setting of androgen withdrawal and radiation therapy.^{3,4} The Gleason score is an important parameter used in nomograms, such as the Kattan nomograms,^{5,6} and the Partin tables,⁷ which guide individual treatment decisions. Readers are referred to the recommendations of 2 ISUP consensus conferences dealing with the contemporary usage of the Gleason system (also see Figure 1).^{2,8} The Gleason score is the sum of the primary (most predominant in terms of surface area of involvement) Gleason grade and the secondary (second most predominant) Gleason grade. Where no secondary Gleason grade exists, the primary Gleason grade is doubled to arrive at a Gleason score. The primary and secondary grades should be reported in addition to the Gleason score, that is, Gleason score 7(3+4) or 7(4+3). In needle biopsy specimens, Gleason score is the sum of the primary (most predominant) Gleason grade and highest Gleason grade.

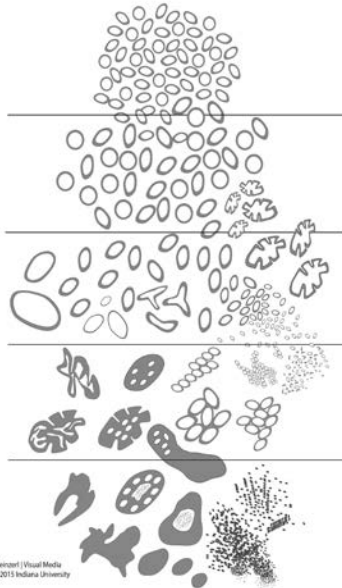


Figure 1. 2015 modified ISUP Gleason schematic diagram.⁸

In needle biopsy specimens, it is recommended that Gleason scores be assigned for each separately identified core (see Note A). If multiple cores in a specimen container are not separately identified, a Gleason score can be assigned to each positive core, provided they are intact; however, some pathologists may choose to report an overall Gleason score for that specimen. The highest Gleason score should be provided in the summary. It is optional to provide a composite Gleason score that takes into account the topographic distribution of tumor and the relative percentage of the different Gleason patterns in all positive cores using the method illustrated in a recent study by Arias-Stella et al.⁹

In needle biopsy specimens where there is a minor secondary component (<5% of tumor) and where the secondary component is of higher grade, the latter should be reported. For instance, a case showing more than 95% Gleason pattern 3 and less than 5% Gleason pattern 4 should be reported as Gleason score 7(3+4). Conversely, if a minor secondary pattern is of lower grade, it need not be reported. For instance, where there is greater than 95% Gleason pattern 4 and less than 5% Gleason pattern 3, the score should be reported as Gleason score 8(4+4).

In needle biopsy specimens where more than 2 patterns are present, and the worst grade is neither the predominant nor the secondary grade, the predominant and highest grade should be chosen to arrive at a score (eg, 75% pattern 3, 20-25% pattern 4, <5% pattern 5 is scored as 3+5=8). This approach has been validated in a large clinical series.¹⁰ The above rules apply to both specimen-level and case-level reporting.

For transurethral resection and enucleation (simple prostatectomy) specimens, the above grading principles also apply.

Tertiary Gleason patterns are common in radical prostatectomy specimens. When Gleason pattern 5 is present as a tertiary pattern, its presence should be recognized in the report.² For instance, in a situation where the primary Gleason pattern is 3, the secondary pattern is 4, and there is less than 5% Gleason pattern 5, the report should indicate a Gleason score of 7(3+4) with tertiary Gleason pattern 5. If Gleason pattern 5 is >5% and constitutes the third most common pattern, some pathologists include it as the secondary pattern, rather than as the tertiary pattern. It is also recommended to document the % of pattern 5 in these cases for future studies.

For radical prostatectomy specimens, Gleason score should be assigned to the dominant nodule(s), if present.² In some cases, a dominant nodule is not identified and the grading is based on all carcinomatous areas. Where more than one separate tumor is clearly identified, the Gleason scores of individual tumors can be recorded separately, or, at the very least, a Gleason score of the dominant or most significant lesion (highest Gleason score or pT category, if not the largest) should be recorded. For instance, if there is a large Gleason score 4(2+2) transition zone tumor and a separate smaller Gleason score 8(4+4) peripheral zone cancer, both scores should be reported, or, at the very least, the latter score should be reported rather than these scores being averaged.

D. Grade Group

The 9 Gleason scores (2-10) have been variably lumped into different groups for prognosis and patient management purposes. Epstein and associates proposed grouping scores into 5 prognostic categories, grade groups 1-5.¹¹ This grade grouping, shown below in the table, strongly correlate with biochemical recurrence and have been incorporated into the new Partin tables.¹¹⁻¹³ At the 2014 ISUP Consensus Conference, details of this prognostic system were clarified and it was recommended for usage together with the Gleason system.⁸ This grade grouping has also been subsequently validated by other independent studies in surgical and radiation cohorts show significant correlation with survival.¹⁴⁻¹⁶ The new grade grouping has been endorsed in the 2016 WHO classification.³

The grade grouping has also been endorsed by ISUP and is referred to as ISUP grade in some publications. Like Gleason scoring in needle biopsies, the grade group can be applied at core, specimen, or case levels.

Table: Grade Groups

Grade Group	Gleason Score	Definition
1	≤6	Only individual discrete well-formed glands
2	3+4=7	Predominantly well-formed glands with lesser component of poorly formed/fused/cribriform glands
3	4+3=7	Predominantly poorly formed/fused/cribriform glands with lesser component (#) of well-formed glands
4	4+4=8	Only poorly formed/fused/cribriform glands
	3+5=8	Predominantly well-formed glands and lesser component (##) lacking glands (or with necrosis)
	5+3=8	Predominantly lacking glands (or with necrosis) and lesser component (##) of well-formed glands
5	9-10	Lack gland formation (or with necrosis) with or without poorly formed/fused/cribriform glands (#)

For cases with >95% poorly formed/fused/cribriform glands on a core or at radical prostatectomy, the component of <5% well-formed glands is not factored into the grade; should therefore be graded as grade group 4.

Poorly formed/fused/cribriform glands can be a more minor component.

E. Percentage Gleason patterns 4+5 (Applicable to Gleason Scores ≥7)

Another recommendation from the 2014 ISUP consensus conference endorsed in the 2016 WHO classification is that the percentage of pattern 4 should be recorded in all Gleason score 7(3+4, 4+3) cases.³ This measurement further stratifies Gleason score 7 and allows identification of cases with limited pattern 4 (eg, <10%) or extensive pattern 4 (eg, >75%).¹⁷ This has practical importance since selected patients with Gleason score 7(3+4) but small amounts of pattern 4 (≤ 10%) may be eligible for active surveillance.^{18,19}

In tumors with Gleason scores >7, the percentage of patterns 4 and 5 has been shown to be of prognostic significance¹⁷ and may be included in the report. Currently there is no consensus on how the percentage of pattern 4+5 should be recorded although it may be captured in 10% intervals or other stratifications such as <5%, 5-10%, 10-25%, 25-50%, 50-75%, >75%.

F. Intraductal Carcinoma (IDC)

The presence of intraductal carcinoma (IDC) is important to record since it has independent prognostic significance. Intraductal carcinoma is uncommon in needle biopsies and when present is usually found within invasive tumor.²⁰⁻²² Pure intraductal carcinoma is rare in needle biopsies and in such situations the CAP protocol is not applicable. It is important to distinguish IDC from high-grade prostatic intraepithelial neoplasia. The differential diagnosis of IDC is beyond the scope of this protocol.

Intraductal carcinoma may also be recorded in transurethral resection, enucleation specimens, and radical prostatectomies. IDC is strongly associated with high Gleason score and high volume tumor in radical prostatectomies and with metastatic disease.²²⁻²⁴ At the 2014 ISUP consensus conference, it was agreed that Gleason scores or grade groups (ISUP grades) should not be assigned to IDC.⁸

G. Quantitation of Tumor

Studies have shown prostate cancer volume is a prognostic factor, although the data are conflicting as to its independent prognostic significance. There are many methods of estimating the amount of tumor in prostatic specimens.²⁵⁻²⁷ For needle core biopsy specimens, the number of positive cores out of the total number of cores should always be reported, except in situations where fragmentation precludes accurate counting. The estimated percentage of prostatic tissue involved by tumor and/or the linear millimeters of the tumor should also be reported. Reporting of the positive core with the greatest percentage of tumor is an option since in some active surveillance (AS) protocols, the presence of any cores with >50% involvement is an exclusion criterion.²⁸ It is not uncommon that a core is discontinuously involved by cancer foci. One practical consideration is how to record discontinuous areas of tumor involvement. For instance, in a 20-mm core with 5% involvement at each end, the amount may be recorded as 5% + 5% = 10% involvement or 100% involvement in a discontinuous fashion even though there is only 2 mm of actual tumor length. The pattern of reporting may actually exclude a patient from an AS protocol. In such situations, it may be worthwhile reporting discontinuous involvement by both including and subtracting the intervening tissue; for example, in the 20-mm core, there are discontinuous foci of adenocarcinoma spanning a distance of 20 mm (100% linear extent) and measuring 1+1=2 mm (10% linear extent). Most studies have also shown that recording the cancer length from one end to the other correlates better with radical prostatectomy findings and prognostic outcomes than subtracting the intervening benign prostate tissue.^{30,31} These findings are supported by recent studies that showed that 75% to 80% of discontinuous cancer foci in prostate biopsy cores may represent the same tumor focus.^{29,30}

The designation of the percentage of cancer tissue in transurethral samples is important. When prostate cancer is discovered incidentally (ie, discovered in specimens submitted for clinically benign disease, usually benign prostatic hyperplasia [BPH]), the percentage involvement is used to determine the clinical T1 substage, with ≤5% involvement being T1a and >5% being T1b. In subtotal and radical prostatectomy specimens, the percentage of tissue involved by tumor can also be “eyeballed” by simple visual inspection.³² Additionally, in these latter specimens, it may be possible to measure a dominant tumor nodule in at least 2 dimensions³³ and/or to indicate the number of blocks involved by tumor out of the total number of prostatic blocks submitted.

H. Local Invasion in Needle Biopsies

Occasionally in needle biopsies, periprostatic fat is involved by tumor.^{26,27} This observation should be noted since it indicates that the tumor is at least pT3a in the TNM system. Furthermore, if seminal vesicle tissue is present (either unintentionally or intentionally, as in a directed biopsy) and involved by tumor, this should be reported since it suggests that the tumor may be pT3b (if the involved seminal vesicle is extraprostatic). Seminal vesicle invasion is defined by involvement of the muscular wall.^{26,27,34} At times, especially in needle biopsy specimens, it is difficult to distinguish between seminal vesicle and ejaculatory duct tissue. It is important not to overinterpret the ejaculatory duct as seminal vesicle since involvement of the former by tumor does not constitute locally advanced disease.

I. Perineural Invasion

Perineural invasion in core needle biopsies has been associated with extraprostatic extension in some correlative radical prostatectomy studies, although its exact prognostic significance remains unclear.^{25-27,35} Perineural invasion has been found to be an independent risk factor, in some studies, for predicting an adverse outcome in patients treated with external beam radiation,³⁶ but not for patients treated with brachytherapy or radical prostatectomy.³⁷ The value of perineural invasion as an independent prognostic factor has been questioned in a multivariate analysis.³⁵

J. Prostatic Intraepithelial Neoplasia

The diagnostic term *prostatic intraepithelial neoplasia* (PIN), unless qualified, refers to high-grade PIN. Low-grade PIN is not reported. The presence of an isolated PIN (PIN in the absence of carcinoma) should be reported in biopsy specimens, especially if more than 1 site is involved.²⁶ The reporting of PIN in biopsies with carcinoma is considered optional. High-grade PIN in a biopsy without evidence of carcinoma has in the past been a risk factor

for the presence of carcinoma on subsequent biopsies, but the magnitude of the risk has diminished, and, in some studies, high-grade PIN was not a risk factor at all.^{38,39} More recent data suggests that if high-grade PIN is present in 2 or more sites, there is an increased risk of detecting carcinoma in subsequent biopsies.^{40,41} The reporting of high-grade PIN in prostatectomy specimens is optional.

K. Submission of Tissue for Microscopic Evaluation in Transurethral Resection and Radical Prostatectomy Specimens

Transurethral resection specimens that weigh 12 g or less should be submitted in their entirety, usually in 6 to 8 cassettes.⁴² For specimens that weigh more than 12 g, the initial 12 g are submitted (6-8 cassettes), and 1 cassette may be submitted for every additional 5 g of remaining tissue.⁴³

In general, random chips are submitted; however, if some chips are firmer or have a yellow or orange-yellow appearance, they should be submitted preferentially.

If an unsuspected carcinoma is found in tissue submitted, and it involves 5% or less of the tissue examined, the remaining tissue may be submitted for microscopic examination, especially in younger patients.

It is not mandatory but recommended to report the size and weight of the prostate gland as several studies have shown that men with smaller prostates had more high-grade cancers and more advanced disease and were at greater risk of progression after RP. Therefore, they may be an important prognostic variables postoperatively to predict biochemical progression. A radical prostatectomy specimen may be submitted in its entirety or partially sampled in a systematic fashion.^{27,45-47} For partial sampling in the setting of a grossly visible tumor, the tumor and associated periprostatic tissue and margins, along with the entire apical and bladder neck margins and the junction of each seminal vesicle with prostate proper, should be submitted. If there is no grossly visible tumor, a number of systematic sampling strategies may be used. One that yields excellent prognostic information involves submitting the posterior aspect of each transverse slice along with a mid anterior block from each side.⁴⁶ The anterior sampling detects the T1c cases arising in the transition zone and extending anteriorly. The entire apical and bladder neck margins and the junction of each seminal vesicle with the prostate should also be submitted.

L. Extraprostatic Extension

Extraprostatic extension (EPE) is the preferred term for the presence of tumor beyond the confines of the prostate gland.^{27,45,48-50} Tumor admixed with fat constitutes extraprostatic extension. Tumor involving loose connective tissue in the plane of fat or beyond, even in the absence of direct contact between the tumor and the adipocytes, indicates EPE. Extraprostatic extension may also be reported when the tumor involves perineural spaces in the neurovascular bundles, even in the absence of periprostatic fat involvement. In certain locations, such as the anterior and apical prostate and bladder neck regions, there is a paucity of fat, and in these locations, EPE is determined when the tumor extends beyond the confines of the normal glandular prostate. In the distal apical perpendicular margin section, it is often difficult to identify EPE. Sometimes there is a distinct bulging tumor nodule, which may be associated with a desmoplastic stromal reaction. The specific location(s) and the number of sites (blocks) of EPE are useful to report. Descriptors of EPE (focal versus nonfocal) should be used.^{27,45,50} Focal EPE equates with only a few neoplastic glands being outside the prostate or a tumor involving less than 1 high-power field in 1 or 2 sections; nonfocal EPE is more extensively spread beyond the prostatic edge.

M. Urinary Bladder Neck Invasion

Invasion of the urinary bladder neck is identified when neoplastic glands involve the thick intersecting smooth muscle bundles characteristic of the bladder neck region in the absence of associated benign prostate tissue.⁵⁰⁻⁵² Microscopic bladder neck involvement is a significant predictor of prostate-specific antigen (PSA) recurrence, at least in univariate analysis⁵²⁻⁵⁴ and is considered as a criterion for category pT3a disease (AJCC 7th edition).⁵⁵

N. Seminal Vesicle Invasion

Seminal vesicle invasion is a significant adverse prognostic factor associated with increased risk of PSA recurrence.⁵⁶ There are different mechanisms of seminal vesicle invasion including: (1) direct invasion of the seminal vesicle from the base of the prostate; (2) extraprostatic extension prostate with subsequent invasion of seminal vesicle walls; (3) involvement along the ejaculatory duct into the seminal vesicle; and (4) discontinuous involvement, the latter which likely represents vascular spread.³⁴ Seminal vesicle involvement is defined as a tumor invasion of the muscular wall of seminal vesicle. Only extraprostatic seminal vesicle invasion is included in

the definition of seminal vesicle involvement.⁵⁶ Intraprostatic seminal vesicle and ejaculatory duct can be difficult to separate from one another, and involvement of these structures is not considered pT3b disease.

O. Margins

Margin positivity is a significant adverse prognostic factor.⁵⁷ To properly evaluate surgical margins, the entire surface of the prostate should be inked.^{27,45,47} The apex should be carefully examined because it is a common site of margin positivity.²⁸⁻³⁴ At the apex, tumor admixed with skeletal muscle elements does not constitute extraprostatic extension. The apical and bladder neck surgical margins should be submitted entirely, preferably with a perpendicular sectioning technique.^{27,45,47} Usually, surgical margins should be designated as “negative” if tumor is not present at the inked margin and as “positive” if tumor cells touch the ink at the margin. When tumor is located very close to an inked surface but is not actually in contact with the ink, the margin is considered negative. Positive surgical margins should not be interpreted as extraprostatic extension. Intraprostatic margins are positive in the setting of intraprostatic or capsular incision (so-called pT2+ disease; Figure 2).^{45,57} If the surgical margin finding is positive, the pathologist should state that explicitly, although this finding is not relied upon for pathologic staging. The specific locations of the positive margins should be reported. There should be some indication of the extent of margin positivity. At the 2009 International Society of Urological Pathology Consensus Conference on Handling and Staging of Radical Prostatectomy Specimens, it was recommended that the extent of a positive margin should be reported as millimeters of involvement.⁵⁷

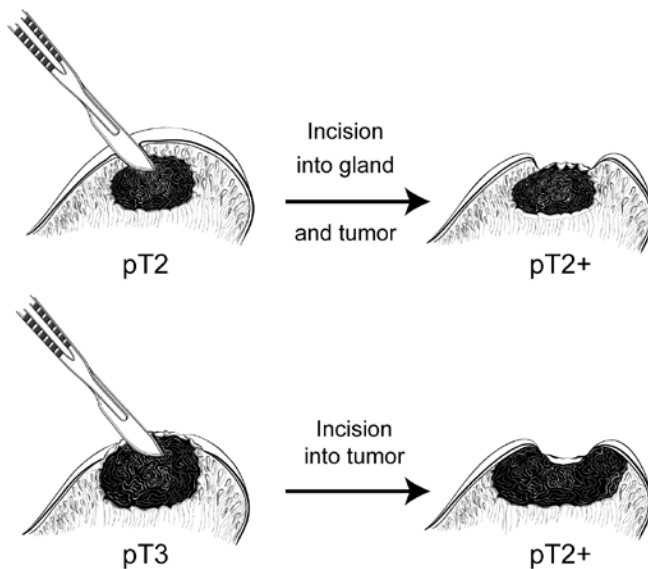


Figure 2. Surgical incision can create stage pT2+ from either pT2 or pT3 disease.

It is also important to indicate whether the positive margin is incisional or in an area of EPE. The latter has more adverse prognostic significance than the former.⁵⁷

Recent studies suggest that the Gleason grade or score at a site of margin positivity is correlated with biochemical recurrence.⁵⁸⁻⁶¹ The presence of any pattern 4 or 5 in tumor at a margin doubled the risk of PSA recurrence compared to only Gleason pattern 3 at margin.⁵⁸ From a practical perspective the documentation of the highest pattern present at a positive surgical margin is reasonable,

P. TNM and Stage Groupings

The protocol recommends the use of the TNM Staging System for carcinoma of the prostate of the American Joint Committee on Cancer (AJCC).⁶²

By AJCC convention, the designation “T” refers to a primary tumor that has not been previously treated. The symbol “p” refers to the pathologic classification of the TNM, as opposed to the clinical classification, and is based on gross and microscopic examination. pT entails a resection of the primary tumor or biopsy adequate to evaluate the highest pT category, pN entails removal of nodes adequate to validate lymph node metastasis, and pM

implies microscopic examination of distant lesions. Clinical classification (cTNM) is usually carried out by the referring physician before treatment during initial evaluation of the patient or when pathologic classification is not possible.

Pathologic staging is usually performed after surgical resection of the primary tumor. Pathologic staging depends on pathologic documentation of the anatomic extent of disease, whether or not the primary tumor has been completely removed. If a biopsied tumor is not resected for any reason (eg, when technically unfeasible), and if the highest T and N categories or the M1 category of the tumor can be confirmed microscopically, the criteria for pathologic classification and staging have been satisfied without total removal of the primary cancer. Tumor confined to the prostate gland irrespective of amount and distribution is considered pT2. pT3a and pT3b are illustrated in Figures 3 and 4.⁶²

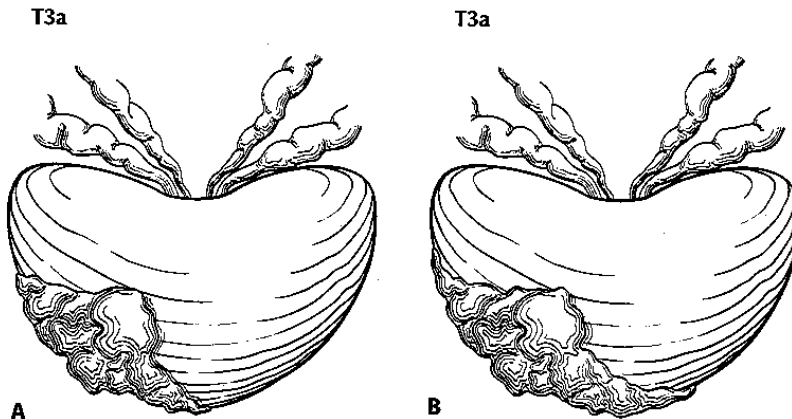


Figure 3. T3a is defined as a tumor with unilateral extraprostatic extension, as shown in A, or with bilateral extension, as shown in B. Microscopic extension into the bladder neck is also pT3a. Used with permission of the American Joint Committee on Cancer (AJCC), Chicago, Ill. The original source for this material is the *AJCC Cancer Staging Atlas* (2006) edited by Greene et al⁶² and published by Springer Science and Business Media, LLC, www.springerlink.com.

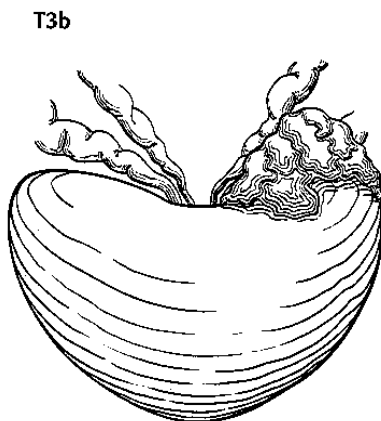


Figure 4. T3b tumor invading the seminal vesicle. Used with permission of the American Joint Committee on Cancer (AJCC), Chicago, Ill. The original source for this material is the *AJCC Cancer Staging Atlas* (2006) edited by Greene et al⁶² and published by Springer Science and Business Media, LLC, www.springerlink.com.

Regional and Distant Lymph Nodes

Regional Lymph Nodes

The regional lymph nodes are the nodes of the true pelvis, which essentially are the pelvic nodes below the bifurcation of the common iliac arteries. They include the following groups:

- Pelvic, NOS
- Hypogastric
- Obturator

- Iliac (internal, external, or NOS)
- Sacral (lateral, presacral, promontory [Gerota's], or NOS)

Laterality does not affect the N classification.

Distant Lymph Nodes

Distant lymph nodes lie outside the confines of the true pelvis. They can be imaged using ultrasound, computed tomography, magnetic resonance imaging, or lymphangiography. Although enlarged lymph nodes can occasionally be visualized on radiographic imaging, fewer patients are initially discovered with clinically evident metastatic disease. In lower risk patients, imaging tests have proven unhelpful. In lieu of imaging, risk tables are many times used to determine individual patient risk of nodal involvement prior to therapy. Involvement of distant lymph nodes is classified as M1a. The distant lymph nodes include the following:

- Aortic (paraortic lumbar)
- Common iliac
- Inguinal, deep
- Superficial inguinal (femoral)
- Supraclavicular
- Cervical
- Scalene
- Retroperitoneal, NOS

TNM Descriptors

For identification of special cases of TNM or pTNM classifications, the “m” suffix and the “y,” “r,” and “a” prefixes are used. Although they do not affect the stage grouping, they indicate cases needing separate analysis.

The “m” suffix indicates the presence of multiple primary tumors in a single site and is recorded in parentheses: pT(m)NM.

The “y” prefix indicates those cases in which classification is performed during or following initial multimodality therapy (ie, neoadjuvant chemotherapy, radiation therapy, or both chemotherapy and radiation therapy). The cTNM or pTNM category is identified by a “y” prefix. The ycTNM or ypTNM categorizes the extent of tumor actually present at the time of that examination. The “y” categorization is not an estimate of tumor prior to multimodality therapy (ie, before initiation of neoadjuvant therapy).

The “r” prefix indicates a recurrent tumor when staged after a documented disease-free interval, and is identified by the “r” prefix: rTNM.

The “a” prefix designates the stage determined at autopsy: aTNM.

Additional Descriptors

Residual Tumor (R)

Tumor remaining in a patient after therapy with curative intent (eg, surgical resection for cure) is categorized by a system known as R classification, shown below.

RX	Presence of residual tumor cannot be assessed
R0	No residual tumor
R1	Microscopic residual tumor
R2	Macroscopic residual tumor

For the surgeon, the R classification may be useful to indicate the known or assumed status of the completeness of a surgical excision. For the pathologist, the R classification is relevant to the status of the margins of a surgical resection specimen. That is, tumor involving the resection margin on pathologic examination may be assumed to correspond to residual tumor in the patient and may be classified as macroscopic or microscopic according to the findings at the specimen margin(s).

Lymphovascular Invasion

Lymphovascular invasion (LVI) indicates whether microscopic lymph-vascular invasion is identified. LVI includes lymphatic invasion, vascular invasion, or lymphovascular invasion. By AJCC convention, LVI does not affect the T category indicating local extent of tumor unless specifically included in the definition of a T category.

References

1. Srigley JR, Delahunt B, Egevad L, Samaratunga H, Evans AJ. Optimising pre-analytical factors affecting quality of prostate biopsies: the case for site specific labelling and single core submission. *Pathology*. 2014;46(7):579-580.
2. Epstein JI, Allsbrook Jr WC, Amin MB, Egevad L, ISUP Grading Committee. The 2005 International Society of Urological Pathology (ISUP) Consensus Conference on Gleason Grading of Prostatic Carcinoma. *Am J Surg Pathol*. 2005;29:1228-1242.
3. Humphrey P, Amin MB, Berney D, Billis A, et al. Acinar adenocarcinoma. In: Moch H, Humphrey PA, Ulbright T, Reuter VE, eds. *Pathology and Genetics: Tumors of the Urinary System and Male Genital Organs*. 4th edition. WHO Classification of Tumors. Zurich, Switzerland: WHO Press; 2015:3-28.
4. Gleason DR, Mellinger GT, the Veterans Administration Cooperative Urological Research Group. Prediction of prognosis for prostate adenocarcinoma by combined histological grading and clinical staging. *J Urol*. 1974;111:58-64.
5. Stephenson AJ, Scardino PT, Eastham JA, et al. Preoperative nomogram predicting the 10-year probability of prostate cancer recurrence after radical prostatectomy. *J Natl Cancer Inst*. 2006;98:715-717.
6. Stephenson AJ, Scardino PT, Eastham JA, et al. Postoperative nomogram predicting the 10-year probability of prostate cancer recurrence after radical prostatectomy. *J Clin Oncol*. 2005;23:7005-7012.
7. Makarov DV, Trock BJ, Humphreys EB, et al. Updated nomogram to predict pathologic stage of prostate cancer given prostate-specific antigen level, clinical stage, and biopsy Gleason score (Partin tables) based on cases from 2000 to 2005. *Urology*. 2007;69:1095-1101.
8. Epstein JI, Egevad L, Amin MB, Delahunt B, Srigley JR, Humphrey PA; and the Grading Committee The 2014 International Society of Urological Pathology (ISUP) Consensus Conference on Gleason Grading of Prostatic Carcinoma: definition of grading patterns and proposal for a new grading system. *Am J Surg Pathol*. 2016; 40: 244-252.
9. Arias-Stella JA 3rd, Shah AB, Montoya-Cerrillo D, Williamson SR, Gupta NS. Prostate biopsy and radical prostatectomy Gleason score correlation in heterogenous tumors: proposal for a composite Gleason score. *Am J Surg Pathol*. 2015;39(9):1213-1218
10. Patel AA, Chen M-H, Renshaw AA, D'Amico AV. PSA failure following definitive treatment of prostate cancer having biopsy Gleason score 7 with tertiary grade 5. *JAMA*. 2007;298:1533-1538.
11. Pierorazio PM, Walsh PC, Partin AW, Epstein JI. Prognostic Gleason grade grouping: data based on the modified Gleason scoring system. *BJU Int*. 2013;111:753-760.
12. Eifler JB, Feng Z, Lin BM, Partin MT, Humphreys EB, Han M, et al. An updated prostate cancer staging nomogram (Partin tables) based on cases from 2006 to 2011. *BJU Int*. 2013;111:22-29.
13. Epstein JI, Zelefsky MJ, Sjoberg DD, et al. A contemporary prostate cancer grading system: a validated alternative to the Gleason score. *Eur Urol*. 2016;69:428-435.
14. Delahunt B, Egevad L, Srigley JR, et al. Validation of International Society of Urological Pathology (ISUP) grading for prostatic adenocarcinoma in thin core biopsies using TROG 03.04 'RADAR' trial clinical data. *Pathology*. 2015;47:520-525.
15. Samaratunga H, Delahunt B, Gianduzzo T, et al. The prognostic significance of the 2014 International Society of Urological Pathology (ISUP) grading system for prostate cancer. *Pathology*. 2015;47:515-519.
16. Berney DM, Beltran L, Fisher G, et al. Validation of a contemporary prostate cancer grading system using prostate cancer death as outcome. *Br J Cancer*. 2016;114(10):1078-1083.
17. Sauter G, Steurer S, Clauditz TS, et al. Clinical Utility of Quantitative Gleason Grading in Prostate Biopsies and Prostatectomy Specimens. *Eur Urol*. 2016;69:592-598.
18. Morash C, Tey R, Agbassi C, Klotz L, McGowan T, Srigley A, Evans A. Active surveillance for the management of localized prostate cancer: guideline recommendations. *Can Urol J Assoc*. 2015;9(5-6):171-178.
19. Chen RC, Rumble RB, Loblaw DA, et al. Active surveillance for the management of localized prostate cancer (Cancer Care Ontario Guideline): American Society of Clinical Oncology practice guideline endorsement. *J Clin Oncol*. 2016;34(18):2182-2190.

20. Guo CC and Epstein JI. Intraductal carcinoma of the prostate on needle biopsy: Histologic features and clinical significance. *Mod Pathol.* 2006;19(12):1528-1535.
21. Cohen RJ, Wheeler TM, Bonkhoff H and Rubin MA. A proposal on the identification, histologic reporting, and implications of intraductal prostatic carcinoma. *Arch Pathol Lab Med.* 2007;131(7):1103-1109.
22. Zhou M. Intraductal carcinoma of the prostate: the whole story. *Pathology.* 2013;45(6):533-539.
23. Zhao T, Liao B, Yao J, et al. Is there any prognostic impact of intraductal carcinoma of prostate in initial diagnosed aggressively metastatic prostate cancer? *Prostate.* 2015;75(3):225-232.
24. Van der Kwast T, Al Daoud N, Collette L, et al. Biopsy diagnosis of intraductal carcinoma is prognostic in intermediate and high risk prostate cancer patients treated by radiotherapy. *Eur J Cancer.* 2012;48(9):1318-1325.
25. Bismar TA, Lewis JS, JR, Vollmer RT, Humphrey PA. Multiple measures of carcinoma extent versus perineural invasion in prostate needle biopsy tissue in prediction of pathologic stage in a screening population. *Am J Surg Pathol.* 2003;27:432-440.
26. Amin M, Boccon-Gibod L, Egevad L, et al. Prognostic and predictive factors and reporting of prostate carcinoma in prostate needle biopsy specimens. (2004 WHO-sponsored International Consultation Consensus). *Scand J Urol Nephrol.* 2004;39(216 suppl):20-33.
27. Paner GP, Magi-Galluzzi C, Amin MB, Srigley JR: Adenocarcinoma of the prostate. In: Amin MB, Grignon DJ, Srigley JR, Eble JN, eds. *Urological Pathology.* Philadelphia, PA: Lippincott William & Wilkins; 2014:559-673.
28. Amin MB, Lin DW, Gore JL, et al. The critical role of the pathologist in determining eligibility for active surveillance as a management option in patients with prostate cancer: consensus statement with recommendations supported by The College of American Pathologists, International Society of Urological Pathology, Association of Directors of Anatomical and Surgical Pathology, The New Zealand Society of Pathologists and the Prostate Cancer Foundation. *Arch Pathol Lab Med.* 2014;138:1387-1405.
29. Fontugne J, Davis K, Palanisamy N, et al. Clonal evaluation of prostate cancer foci in biopsies with discontinuous tumor involvement by dual ERG/SPINK1 immunohistochemistry. *Mod Pathol.* 2016;29(2):157-165.
30. Arias-Stella JA 3rd, Varma KR, Montoya-Cerrillo D, Gupta NS, Williamson SR. Does discontinuous involvement of a prostatic needle biopsy core by adenocarcinoma correlate with a large tumor focus at radical prostatectomy? *Am J Surg Pathol.* 2015;39(2):281-286.
31. Karram S, Trock BJ, Netto GJ, Epstein JI. Should intervening benign tissue be included in the measurement of discontinuous foci of cancer on prostate needle biopsy? Correlation with radical prostatectomy findings. *Am J Surg Pathol.* 2011;35(9):1351-1355.
32. van der Kwast T, Amin M, Billis A, Epstein J, et al; The ISUP prostate consensus group. International Society of Urological Pathology (ISUP) Consensus Conference on Handling of Radical Prostatectomy Specimens: working group 2: T2 substaging and prostate cancer volume. *Mod Pathol.* 2011;24:16-25.
33. Renshaw AA, Richie JP, Loughlin KR, Jiroutek M, Chung A, D'Amico AV. Maximum diameter of prostatic carcinoma is a simple, inexpensive, and independent predictor of prostate-specific antigen failure in radical prostatectomy specimens: validation in a cohort of 434 patients. *Am J Clin Pathol.* 1999;111:641-644.
34. Otori M, Scardino PT, Lapin SL, Seale-Hawkins C, Link J, Wheeler TM. The mechanisms and prognostic significance of seminal vesicle involvement by prostate cancer. *Am J Surg Pathol.* 1993;17:1252-1261.
35. Harnden P, Shelley MD, Clements H, et al. The prognostic significance of perineural invasion in prostatic carcinoma biopsies: a systematic review. *Cancer.* 2007;109:13-24.
36. Yu HH, Song DY, Tsai YY, Thompson T, Frassica DA, DeWeese TL. Perineural invasion affects biochemical recurrence-free survival in patients with prostate cancer treated with definitive external beam radiotherapy. *Urology.* 2007;70:111-116.
37. O'Malley KJ, Pound CR, Walsh PC, Epstein JI, Partin AW. Influence of biopsy perineural invasion on long-term biochemical disease-free survival after radical prostatectomy. *Urology.* 2002;59:85-90.
38. Gokden N, Roehl KA, Catalona WJ, Humphrey PA. High-grade prostatic intraepithelial neoplasia in needle biopsy as risk factor for detection of adenocarcinoma: current level of risk in screening population. *Urology.* 2005;65:538-542.
39. Epstein JI, Herawi M. Prostate needle biopsies containing prostatic intraepithelial neoplasia or atypical foci suspicious for carcinoma: implications for patient care. *J Urol.* 2006;175:820-834.
40. Merrimen JL, Jones G, Walker D, Leung CS, Kapusta LR, Srigley JR. Multifocal high grade prostatic intraepithelial neoplasia is a significant risk factor for prostatic adenocarcinoma. *J Urol.* 2009;182:485-490.

41. Merrimen JL, Jones G, Srigley JR. Is high grade prostatic intraepithelial neoplasia still a risk factor for adenocarcinoma in the era of extended biopsy sampling? *Pathology*. 2010;42(4):325-329.
42. Humphrey PA, Walther PJ. Adenocarcinoma of the prostate, I: sampling considerations. *Am J Clin Pathol*. 1993;99:746-759.
43. Trpkov K, Thompson J, Kulaga A, Yilmaz A. How much tissue sampling is required when minimal prostate carcinoma is identified on transurethral resection? *Arch Pathol Lab Med*. 2008;132(8):1313-1316.
44. Freedland SJ, Isaacs WB, Platz ES, et al. Prostate Size and Risk of High-Grade, Advanced Prostate Cancer and Biochemical Progression After Radical Prostatectomy: A Search Database Study. *J Clin Oncol*. 23:7546-7554.
45. Srigley JR. Key issues in handling and reporting radical prostatectomy specimens. *Arch Pathol Lab Med*. 2006;30:303-317.
46. Sehdev AE, Pan CC, Epstein JI. Comparative analysis of sampling methods for grossing radical prostatectomy specimens performed for nonpalpable (stage T1c) prostatic adenocarcinoma. *Hum Pathol*. 2001;32:494-499.
47. Samarantunga H, Montironi R, True L, et al; The ISUP prostate consensus group. International Society of Urological Pathology (ISUP) Consensus Conference on Handling and Staging of Radical Prostatectomy Specimens: Working group 1: handling of the specimen. *Mod Pathol*. 2011;24:6-15.
48. Ohori M, Kattan M, Scardino PT, Wheeler TM. Radical prostatectomy for carcinoma of the prostate. *Mod Pathol*. 2004;17:349-359.
49. Epstein JI, Amin M, Boccon-Gibod L, et al. Prognostic factors and reporting of prostate carcinoma in radical prostatectomy and pelvic lymphadenectomy specimens. *Scand J Urol Nephrol*. 2005;216(suppl):34-63.
50. Magi-Galluzzi C, Evans A, Epstein J, et al; The ISUP prostate consensus group. International Society of Urological Pathology (ISUP) Consensus Conference on Handling and Staging of Radical Prostatectomy Specimens: Working group 3: extraprostatic extension lymphovascular invasion and locally advanced disease. *Mod Pathol*. 2011;24:26-38.
51. Pierorazio PM, Epstein JI, Humphreys E, Han M, Walsh PC and Partin AW. The significance of a positive bladder neck margin after radical prostatectomy: the American Joint Committee on Cancer Pathological Stage T4 designation is not warranted. *J Urol*. 2010;183:151-157.
52. Zhou M, Reuther AM, Levin HS, Falzarano SM, Kodjoe E, Myles J, Klein E and Magi-Galluzzi C. Microscopic bladder neck involvement by prostate carcinoma in radical prostatectomy specimens is not a significant independent prognostic factor. *Mod Pathol*. 2009;22(3):385-392.
53. Dash A, Sanda MG, Yu M, Taylor JM, Fecko A, Rubin MA. Prostate cancer involving the bladder neck: recurrence-free survival and implications for AJCC staging modification. *American Joint Committee on Cancer. Urology*. 2002;60(2):276-280.
54. Yossepowitch O, Engelstein D, Konichezky M, Sella A, Livne PM and Baniel J. Bladder neck involvement at radical prostatectomy: positive margins or advanced T4 disease? *Urology*. 2000;56(3):448-452.
55. Edge SE, Byrd DR, Compton CC, Fritz AG, Greene FL, Trotti A, eds. *AJCC Cancer Staging Manual*. 7th ed. New York, NY: Springer; 2010.
56. Berney D, Wheeler T, Grignon D, et al; The ISUP prostate consensus group. International Society of Urological Pathology (ISUP) Consensus Conference on Handling and Staging of Radical Prostatectomy Specimens: Working group 4: seminal vesicles and lymph nodes. *Mod Pathol*. 2011;24:39-47.
57. Tan, PH, Cheng L, Srigley J, et al; The ISUP prostate consensus group. International Society of Urological Pathology (ISUP) Consensus Conference on Handling and Staging of Radical Prostatectomy Specimens: Working Group 5: Surgical margins. *Mod Pathol*. 2011;24:48-57.
58. Savdie R, Horvath LG, Benito RP, et al. High Gleason grade carcinoma at a positive surgical margin predicts biochemical failure after radical prostatectomy and may guide adjuvant radiotherapy. *BJU Int*. 2010;109:1794-1800.
59. Brimo F, Partin AW and Epstein JI. Tumor grade at margins of resection in radical prostatectomy specimens is an independent predictor of prognosis. *Urology*. 2010;76:1206-1209.
60. Cao D, Kibel AS, Gao F, Tao Y and Humphrey PA. The Gleason score of tumor at the margin in radical prostatectomy specimens is predictive of biochemical recurrence. *Am J Surg Pathol*. 2010;34:994-1001.
61. Kates M, Sopko NA, Han M, Partin AW and Epstein JI. Importance of reporting the Gleason score at the positive surgical margin site: an analysis of 4,082 consecutive radical prostatectomy cases. *J Urol*. 2015.
62. Amin MB, Edge SB, Greene FL, et al, eds. *AJCC Cancer Staging Manual*. 8th ed. New York, NY: Springer; 2017.