



# Protocol for the Examination of Biopsy Specimens From Patients With Melanoma of the Skin

Version: Melanoma Biopsy 4.1.0.0

Protocol Posting Date: August 2019

## Accreditation Requirements

The use of this protocol is recommended for clinical care purposes but is not required for accreditation purposes.

## This protocol may be used for the following procedures AND tumor types:

Procedure	Description
Biopsy	
Tumor Type	Description
Invasive melanoma	Limited to melanoma of cutaneous surfaces only

## The following should NOT be reported using this protocol:

Procedure
Excision (consider Skin Melanoma Excision protocol)
Cytologic specimens
Tumor Type
Melanoma in situ without invasive melanoma

## Authors

Wonwoo Shon, DO\*; David P. Frishberg, MD;\* Jeffrey E. Gershenwald, MD;\* Pavandeep Gill, MD\*; Jeffrey North, MD\*; Victor G. Prieto, MD, PhD\*; Richard A. Scolyer, BMedSci, MBBS, MD\*; Bonnie L. Balzer, MD, PhD; Thomas J. Flotte, MD; Timothy H. McCalmont, MD; Bruce Robert Smoller, MD

With guidance from the CAP Cancer and CAP Pathology Electronic Reporting Committees.

\* Denotes primary author. All other contributing authors are listed alphabetically.

## Summary of Changes

---

### v4.1.0.0

Resection and biopsy case summaries separated into discrete cancer protocols

### The following was modified:

Specimen Laterality  
Tumor Site  
Histologic Type  
Ulceration  
Margins

### The following was removed:

Macroscopic Satellite Nodules

**Surgical Pathology Cancer Case Summary**

---

Protocol posting date: August 2019

**MELANOMA OF THE SKIN: Biopsy****Notes:****This case summary is recommended for reporting biopsy specimens but is not required for accreditation purposes. Core data elements are bolded to help identify routinely reported elements.****Select a single response unless otherwise indicated.****Procedure (Note A)**

- Biopsy, shave  
 Biopsy, punch  
 Biopsy, incisional  
 Other (specify): \_\_\_\_\_  
 Not specified

## Specimen Laterality

- Right  
 Left  
 Midline  
 Not specified

Tumor Site (Note B): \_\_\_\_\_

- Not specified

**Histologic Type (Note C)**Invasive Melanoma

- Superficial spreading melanoma (low-cumulative sun damage (CSD) melanoma)  
 Lentigo maligna melanoma  
 Desmoplastic melanoma  
      Pure desmoplastic melanoma  
      Mixed desmoplastic melanoma  
 Acral melanoma  
 Melanoma arising in a blue nevus (blue nevus-like melanoma)  
 Melanoma arising in a giant congenital nevus  
 Spitz melanoma (malignant Spitz tumor)  
 Nodular melanoma  
 Nevoid melanoma  
 Melanoma, not otherwise classified  
 Other histologic type not listed (specify): \_\_\_\_\_

Melanoma In Situ (anatomic level I)#

- Melanoma in situ, superficial spreading type (low-cumulative sun damage (CSD) melanoma in situ)  
 Melanoma in situ, lentigo maligna type  
 Acral melanoma in situ  
 Melanoma in situ arising in a giant congenital nevus  
 Melanoma in situ, not otherwise classified  
 Other histologic type not listed (specify): \_\_\_\_\_

*# Note: For melanoma in situ, elements that assess the invasive component are not applicable and should not be reported.*

**Maximum Tumor (Breslow) Thickness (Note D) (applicable to invasive tumor only)**

Specify (millimeters): \_\_\_ mm

or

At least (millimeters): \_\_\_ mm (explain): \_\_\_\_\_

\_\_\_ Cannot be determined (explain): \_\_\_\_\_

**Ulceration (required for invasive tumor only) (Note E)**

\_\_\_ Not identified

\_\_\_ Present

Extent of ulceration (millimeters): \_\_\_\_\_ mm

\_\_\_ Cannot be determined

**Microsatellite(s) (applicable to invasive tumor only) (Note F)**

\_\_\_ Not identified

\_\_\_ Present

\_\_\_ Cannot be determined

**Margins (select all that apply) (Note G)**

**Peripheral Margins#**

\_\_\_ Negative for invasive melanoma

Distance of invasive melanoma from closest peripheral margin (millimeters):

\_\_\_ Specify \_\_\_ mm

\_\_\_ Less than \_\_\_ mm

\_\_\_ Greater than \_\_\_ mm

\_\_\_ Cannot be determined (explain): \_\_\_\_\_

Specify location(s), if possible: \_\_\_\_\_

\_\_\_ Invasive melanoma present at margin

Specify location(s) if possible: \_\_\_\_\_

\_\_\_ Negative for melanoma in situ

Distance of invasive melanoma from closest peripheral margin (millimeters):

\_\_\_ Specify \_\_\_ mm

\_\_\_ Less than \_\_\_ mm

\_\_\_ Greater than \_\_\_ mm

\_\_\_ Cannot be determined (explain): \_\_\_\_\_

Specify location(s), if possible: \_\_\_\_\_

\_\_\_ Melanoma in situ present at margin

Specify location(s), if possible: \_\_\_\_\_

\_\_\_ Cannot be assessed

**Deep Margin#**

\_\_\_ Negative for invasive melanoma

Distance of invasive melanoma from deep margin (millimeters):

\_\_\_ Specify \_\_\_ mm

\_\_\_ Less than \_\_\_ mm

\_\_\_ Greater than \_\_\_ mm

\_\_\_ Cannot be determined (explain): \_\_\_\_\_

\_\_\_ Invasive melanoma present at margin

\_\_\_ Negative for melanoma in situ

\_\_\_ Melanoma in situ present at margin

\_\_\_ Cannot be assessed

*#Note: Margin involvement by melanoma in situ should be recorded if in situ disease is present in the specimen, and if margins are uninvolved by invasive melanoma.*

**Mitotic Rate (applicable to invasive tumor only) (Note H)**

- None identified  
 Specify (mitoses/mm<sup>2</sup>): \_\_\_\_\_ mitoses/mm<sup>2</sup>  
 Cannot be determined

**Anatomic (Clark) Level (applicable to invasive tumor only) (Note D)**

- At least level \_\_\_\_\_  
(explain): \_\_\_\_\_  
 II (melanoma present in but does not fill and expand papillary dermis)  
 III (melanoma fills and expands papillary dermis)  
 IV (melanoma invades reticular dermis)  
 V (melanoma invades subcutis)  
 Cannot be determined

**Lymphovascular Invasion (applicable to invasive tumor only) (Note I)**

- Not identified  
 Present  
 Cannot be determined

**Neurotropism (applicable to invasive tumor only) (Note J)**

- Not identified  
 Present  
 Cannot be determined

**Tumor-Infiltrating Lymphocytes (applicable to invasive tumor only) (Note K)**

- Not identified  
 Present, nonbrisk  
 Present, brisk  
 Cannot be determined

**Tumor Regression (Note L)**

- Not identified  
 Present  
 Cannot be determined

**Pathologic Stage Classification (pTNM, AJCC 8<sup>th</sup> Edition) (Note M)**TNM Descriptors (required only if applicable) (select all that apply)

- m (multiple)  
 r (recurrent)  
 y (posttreatment or posttherapy)

**Primary Tumor (pT)**

- pTX: Primary tumor thickness cannot be assessed (eg, diagnosis by curettage)  
(explain): \_\_\_\_\_  
 pT0: No evidence of primary tumor (eg, unknown primary or completely regressed melanoma)  
 pTis: Melanoma in situ (ie, not an invasive tumor: anatomic level I)  
 pT1: Melanoma 1.0 mm or less in thickness, ulceration status unknown or unspecified (see Note D)  
 pT1a: Melanoma <0.8 mm in thickness, no ulceration  
 pT1b: Melanoma <0.8 mm in thickness with ulceration, or melanoma 0.8 to 1.0 mm in thickness with or without ulceration  
 pT2: Melanoma >1.0 to 2.0 mm in thickness, ulceration status unknown or unspecified  
 pT2a: Melanoma >1.0 to 2.0 mm in thickness, no ulceration  
 pT2b: Melanoma >1.0 to 2.0 mm in thickness, with ulceration  
 pT3: Melanoma >2.0 to 4.0 mm in thickness, ulceration status unknown or unspecified  
 pT3a: Melanoma >2.0 to 4.0 mm in thickness, no ulceration

**CAP Approved**

**Skin • Melanoma 4.1.0.0  
Biopsy**

- pT3b: Melanoma >2.0 to 4.0 mm in thickness, with ulceration
- pT4: Melanoma >4.0 mm in thickness, ulceration status unknown or unspecified
- pT4a: Melanoma >4.0 mm in thickness, no ulceration
- pT4b: Melanoma >4.0 mm in thickness, with ulceration

Additional Pathologic Findings (select all that apply)

- Associated nevus (specify type)
- Other (specify): \_\_\_\_\_

Ancillary Studies

*Note: For molecular genetic reporting, the CAP Melanoma Biomarker Template should be used. Pending biomarker studies should be listed in the Comments section of this report.*

Comment(s)

## Explanatory Notes

---

### A. Procedure

Optimal pathologic evaluation of melanocytic lesions requires complete excision that incorporates the full thickness of the lesion removed intact.<sup>1</sup> "Shave" procedures that do not include the intact base of the lesion are suboptimal for pathologic evaluation and should be avoided unless clinically indicated. Similarly, "punch" procedures may not include intact peripheral borders of the lesion thereby limiting assessment of symmetry and lateral circumscription, which can be essential for distinction of melanoma from melanocytic nevus.<sup>2,3</sup> Partial biopsies of melanocytic tumors are associated with an increased risk of misdiagnosis with possible consequent adverse clinical outcomes.<sup>4</sup> Nevertheless, clinical factors are also important in determining the most appropriate biopsy technique for any lesion. For example, an excision biopsy of a large lesion on a cosmetically or functionally sensitive site may cause cosmetic disfigurement or alter reconstructive options.

The use of frozen sections for evaluation of biopsy or excision of melanocytic lesions is strongly discouraged.<sup>5,6</sup> Optimal histologic evaluation of cutaneous melanoma requires well-cut, well-stained hematoxylin-and-eosin (H&E) sections prepared from formalin-fixed paraffin-embedded tissue. Frozen sections of sentinel lymph nodes are similarly discouraged, because the manipulation required for intraoperative handling may decrease the sensitivity of the procedure.<sup>7</sup>

#### References

1. Sober AJ, Chuang TY, Duvic M, et al. Guidelines of care for primary cutaneous melanoma. *J Am Acad Dermatol.* 2001;45(4):579-586.
2. Stell VH, Norton HJ, Smith KS, Salo JC, White RL, Jr. Method of biopsy and incidence of positive margins in primary melanoma. *Ann Surg Oncol.* 2007;14(2):893-898.
3. Sober AJ, Balch CM. Method of biopsy and incidence of positive margins in primary melanoma. *Ann Surg Oncol.* 2007;14(2):274-275.
4. Ng JC, Swain S, Dowling JP, Wolfe R, Simpson P, Kelly JW. The impact of partial biopsy on histopathologic diagnosis of cutaneous melanoma: experience of an Australian tertiary referral service. *Arch Dermatol.* 2010;146(3):234-239.
5. Smith-Zagone MJ, Schwartz MR. Frozen section of skin specimens. *Arch Pathol Lab Med.* 2005;129(12):1536-1543.
6. Prieto VG, Argenyi ZB, Barnhill RL, et al. Are en face frozen sections accurate for diagnosing margin status in melanocytic lesions? *Am J Clin Pathol.* 2003;120(2):203-208.
7. Scolyer RA, Thompson JF, McCarthy SW, Gershenwald JE, Ross MI, Cochran AJ. Intraoperative frozen-section evaluation can reduce accuracy of pathologic assessment of sentinel nodes in melanoma patients. *J Am Coll Surg.* 2005;201(5):821-823; author reply 823-824.

### B. Anatomic Site

For cutaneous melanoma, prognosis may be affected by primary anatomic site.<sup>1,2</sup>

#### References

1. Balch CM, Soong SJ, Gershenwald JE, et al. Prognostic factors analysis of 17,600 melanoma patients: validation of the American Joint Committee on Cancer melanoma staging system. *J Clin Oncol.* 2001;19(16):3622-3634.
2. Elder DE, Massi D, Scolyer RA, Willemze R. eds. *WHO Classification of Skin Tumors. World Health Organization of Tumors, 4<sup>th</sup> ed Volume 11.* Lyon France; 2018, ISBN-13 978-92-832-2440-2.

### C. Melanoma Subtypes

- Superficial spreading melanoma (low cumulative sun damage (CSD) melanoma)
- Lentigo maligna melanoma
- Desmoplastic melanoma (pure and mixed)
- Acral melanoma
- Melanoma arising in a blue nevus (blue nevus-like melanoma)
- Melanoma arising in a giant congenital nevus

Spitz melanoma (malignant Spitz tumor)  
Nodular melanoma  
Nevoid melanoma  
Melanoma, not otherwise classified

The recent WHO 2018 classification introduced multidimensional pathway classification of melanocytic tumors based on the extent of ultraviolet (UV) radiation damage, the cell of origin, and characteristic genomic findings (Table 1).

Table 1. Classification of melanoma

Extent of UV radiation damage	Subtypes
Melanomas found in skin with low cumulative sun damage (low-CSD)	Superficial spreading melanoma (low cumulative sun damage (CSD) melanoma)
Melanomas found in skin with high cumulative sun damage (high-CSD)	Lentigo maligna melanoma
	Desmoplastic melanoma
Melanomas on site with no sun exposure or without known etiological associations with sun exposure	Malignant Spitz tumor (Spitz melanoma)
	Acral melanoma
	Mucosal melanoma
	Melanoma arising in congenital nevus
	Melanoma arising in a blue nevus
	Uveal melanoma
Various sun exposure	Nodular melanoma
	Nevoid melanoma

#### References

1. Elder DE, Massi D, Scolyer RA, Willemze R. eds. WHO Classification of Skin Tumors. World Health Organization of Tumors, 4th ed Volume 11. Lyon France; 2018, ISBN-13 978-92-832-2440-2.

#### D. Primary Tumor (Breslow) Thickness) and Anatomic (Clark) Levels

Maximum tumor thickness is measured with a calibrated ocular micrometer at a right angle to the adjacent normal skin. The upper point of reference is the upper edge of the granular layer of the epidermis of the overlying skin or, if the lesion is ulcerated overlying the entire dermal component, the base of the ulcer. The lower reference point is the deepest point of tumor invasion (ie, the leading edge of a single mass or an isolated group of cells deep to the main mass).

If the tumor is transected by the deep margin of the specimen, the depth may be indicated as “at least \_\_\_ mm” with a comment explaining the limitation of thickness assessment. For example, “The maximum tumor thickness cannot be determined in this specimen because the deep plane of the biopsy transects the tumor.” Tumor thickness measurements should not be based on periadnexal extension (either periadnexal adventitial or extra-adventitial extension), except when it is the only focus of invasion. In that circumstance, Breslow thickness may be measured from the inner layer of the outer root sheath epithelium or inner luminal surface of sweat glands, to the furthest extent of infiltration into the periadnexal dermis. Microsatellites or foci of neurotropism or lymphovascular invasion should not be included in tumor thickness measurements.

In the 8<sup>th</sup> edition of the AJCC melanoma staging system,<sup>1</sup> it is recommended that tumor thickness measurements be recorded to the nearest 0.1 mm, not the nearest 0.01 mm, because of the impracticality and imprecision of measurements, particularly for tumors greater than 1 mm thick. Tumors less than or equal to 1 mm thick may be measured to the nearest 0.01 mm if practical, but should be reported to the nearest 0.1mm (eg, melanomas measured to be in the range of 0.75 mm to 0.84 mm are reported as 0.8 mm in thickness and hence T1b, and tumors 1.01 to 1.04 mm in thickness are reported as 1.0 mm).

While the principal T category tumor thickness ranges have been maintained in the AJCC 8<sup>th</sup> edition, T1 is now subcategorized by tumor thickness strata at a 0.8 mm threshold. Tumor mitotic rate as a dichotomous variable is no longer used as a staging category criterion for T1 tumors. T1a melanomas are now defined as non-ulcerated

and less than 0.8 mm in thickness. T1b melanomas are defined as 0.8-1.0mm in thickness or ulcerated melanomas less than 0.8 mm in thickness.

Anatomic (Clark) levels are defined as follows:

- I Intraepidermal tumor only (ie, melanoma in situ)
- II Tumor present in but does not fill and expand papillary dermis
- III Tumor fills and expands papillary dermis
- IV Tumor invades into reticular dermis
- V Tumor invades subcutis

Anatomic (Clark) level of invasion remains an independent predictor of outcome and is recommended by the AJCC to be reported as a primary tumor characteristic.<sup>1</sup> However, assessment of Clark levels is less reproducible among pathologists than is tumor thickness, and Clark levels are not used in the AJCC staging system for pT status. Accordingly, Clark levels are included in this checklist as an optional data item.

#### References

1. Gershenwald JE, Scolyer RA, Hess KR, et al. Melanoma of the skin, In: Amin MB, Edge SB, Greene FL, et al. eds. *AJCC Cancer Staging Manual*. 8th ed. New York, NY: Springer; 2017.

#### E. Ulceration

Primary tumor ulceration has been shown to be a dominant independent prognostic factor in invasive cutaneous melanoma,<sup>1,2</sup> and if present, changes the pT stage from T1a to T1b, T2a to T2b, etc., depending on the thickness of the tumor. The presence or absence of ulceration must be confirmed on microscopic examination.<sup>2</sup> Melanoma ulceration is defined as the combination of the following features: full-thickness epidermal defect (including absence of stratum corneum and basement membrane); evidence of reactive changes (ie, fibrin deposition, neutrophils); and thinning, effacement, or reactive hyperplasia of the surrounding epidermis in the absence of trauma or a recent surgical procedure. Ulcerated melanomas typically show invasion through the epidermis, whereas nonulcerated melanomas tend to lift the overlying epidermis.

Only nontraumatic (“tumorigenic”) ulceration should be recorded as ulceration. If ulceration is present related to a prior biopsy, the tumor should not be recorded as ulcerated for staging purposes. If a lesion has been recently biopsied or there is only focal loss of the epidermis, assessment of ulceration may be difficult or impossible; in this instance it may be difficult to determine whether the epidermal deficiency is due to true ulceration or to sectioning artifact.<sup>2</sup> Absence of fibrin, neutrophils, or granulation tissue from putative areas of ulceration would be clues that the apparent ulceration is actually due to sectioning of only part of the epidermis and this should not be designated as ulceration. If non-traumatic (“tumorigenic”) ulceration is present in either an initial partial biopsy or a re-excision specimen, then for staging purposes, the tumor should be recorded as ulcerated.

Ulceration may be present in an in situ melanoma but does not affect the staging.

A number of studies have demonstrated that the extent of ulceration (measured either as a percentage of the width of the dermal invasive component of the tumor or as a diameter) more accurately predicts outcome than the presence or absence of ulceration alone.<sup>3,4</sup>

#### References

1. Gershenwald JE, Scolyer RA, Hess KR, Sondak VK, Long GV, Ross MI et al. Melanoma staging: Evidence-based changes in the American Joint Committee on Cancer eighth edition cancer staging manual. *CA Cancer J Clin*. 2017;67(6):472-92.
2. Gershenwald JE, Scolyer RA, Hess KR, et al. Melanoma of the skin, In: Amin MB, Edge SB, Greene FL, et al. eds. *AJCC Cancer Staging Manual*. 8th ed. New York, NY: Springer; 2017.
3. Hout FE, Haydu LE, Murali R, Bonenkamp JJ, Thompson JF, Scolyer RA. Prognostic importance of the extent of ulceration in patients with clinically localized cutaneous melanoma. *Ann Surg*. 2012;255(6):1165-1170.
4. Namikawa K, Aung PP, Gershenwald JE, Milton DR, Prieto VG. Clinical impact of ulceration width, lymphovascular invasion, microscopic satellitosis, perineural invasion, and mitotic rate in patients undergoing



sentinel lymph node biopsy for cutaneous melanoma: a retrospective observational study at a comprehensive cancer center. *Cancer Med.* 2018;7(3):583-593.

### F. Microsatellite(s)

A microsatellite(s) is defined as the presence of a microscopic cutaneous metastasis found adjacent or deep to a primary melanoma on pathological examination of the primary tumor site.<sup>1</sup> The metastatic tumor cells must be discontinuous from the primary tumor. If the tissue between the apparently separate nodule and the primary tumor is only fibrous scarring and/or inflammation, this does not indicate a microsatellite, because the aforementioned changes may represent regression of the intervening tumor (but not separated only by fibrosis or inflammation because the features could signify regression of the intervening tumor). There is no minimum size threshold or distance from the primary tumor to define a microsatellite. Before diagnosing the presence of a microsatellite, it is generally recommended that multiple sections from the same tissue block being examined to verify that the microsatellite is indeed discontinuous from the primary tumor. For example, periadnexal extension of tumor or the irregular shape of the peripheral or deep extent of the tumor may result in tumor that is contiguous with the primary tumor appear discontinuous on single sections.

### References

1. Gershenwald JE, Scolyer RA, Hess KR, et al. Melanoma of the skin, In: Amin MB, Edge SB, Greene FL, et al. eds. *AJCC Cancer Staging Manual*. 8th ed. New York, NY: Springer; 2017.

### G. Margins

Microscopically measured distances between tumor and labeled peripheral (lateral) or deep margins are appropriately recorded for melanoma excision specimens, whenever possible. If a margin is involved by tumor, it should be stated whether the tumor is in situ or invasive.

### H. Mitotic Rate

Tumor mitotic rate (of the invasive component of a melanoma) is a strong independent predictor of outcome across its dynamic range in all thickness categories and should be assessed and recorded in all primary melanomas including in both initial and excision biopsies (the highest value in any specimen should be used for prognostic purposes). Although tumor mitotic rate is no longer used as a T1-category criterion in the 8<sup>th</sup> edition of the AJCC melanoma staging system (due to the more significant prognostic significance of the new tumor thickness strata within T1 melanoma), mitotic rate will likely be an important parameter in prognostic models developed in the future that will provide personalized prediction of prognosis for individual patients<sup>1</sup>. The method recommended for enumerating the tumor mitotic rate in the 8<sup>th</sup> edition of the AJCC staging system is provided below:

“The recommended approach to enumerating mitoses is to first find the regions in the dermis containing the most mitotic figures, the so-called “hot spot” or “dermal hot spot.” After counting the mitoses in the initial high-power field, the count is extended to immediately adjacent nonoverlapping fields until an area of tissue corresponding to 1 mm<sup>2</sup> is assessed. If no hot spot is found and mitoses are sparse and/or randomly scattered throughout the lesion, then a representative mitosis is chosen and, beginning with that field, the count is then extended to immediately adjacent nonoverlapping fields until an area corresponding to 1 mm<sup>2</sup> of tissue is assessed. The count then is expressed as the (whole) number of mitoses/mm<sup>2</sup>. If the invasive component of the tumor involves an area less than 1 mm<sup>2</sup>, the number of mitoses should be assessed and recorded as if they were found within square millimeter. For example, if the entire dermal component of a tumor occupies 0.5 mm<sup>2</sup> and only one mitosis is identified, the mitotic rate should be recorded as 1/mm<sup>2</sup> (not 2/mm<sup>2</sup>). The number of mitoses should be listed as a whole number per square millimeter. If no mitoses are identified, the mitotic rate may be recorded as “none identified” or “0/mm<sup>2</sup>.” Only mitotic figures in *invasive* melanoma cells should be counted. This methodology for determining the mitotic rate of a melanoma has been shown to have excellent interobserver reproducibility, including among pathologists with widely differing experience in the assessment of melanocytic tumors.<sup>2</sup>

To obtain accurate measurement, calibration of individual microscopes is recommended using a stage micrometer to determine the number of high-power fields that equates to a square millimeter.

The data that demonstrated the strong prognostic significance of mitotic rate were obtained from the melanoma pathology reports of routinely assessed H&E stained sections. It therefore is recommended that no additional

sections be cut and examined in excess of those that would normally be used to report and diagnose the melanoma to determine the mitotic count (ie, no additional sections should be cut and examined for the sole purpose of determining the mitotic rate, including in situations in which no mitoses are identified on the initial, routinely examined sections). Immunohistochemical stains for identifying mitoses are not used for determining mitotic rate for staging and/ or reporting purposes. A possible exception is the use to dual immunohistochemistry (eg, MART1 and pHH3) to determine if a cell in mitosis is a melanocyte or not (macrophage, endothelial cell, etc).<sup>3</sup>

Although the AJCC recommends reporting “0” rather than “none identified” or “less than 1,” for the purposes of cancer registry reporting all of these terms should be considered equivalent.

#### References

1. Gershenwald JE, Scolyer RA, Hess KR, et al. Melanoma of the skin, In: Amin MB, Edge SB, Greene FL, et al. eds. *AJCC Cancer Staging Manual*. 8th ed. New York, NY: Springer; 2017.
2. Scolyer RA, Shaw HM, Thompson JF, et al. Interobserver reproducibility of histopathologic prognostic variables in primary cutaneous melanomas. *Am J Surg Pathol*. 2003;27(12):1571-1576.
3. Tetzlaff MT, Curry JL, Ivan D, et al. Immunodetection of phosphohistone H3 as a surrogate of mitotic figure count and clinical outcome in cutaneous melanoma. *Mod Pathol*. 2013;26(9):1153-1160.

### I. Lymphovascular Invasion

Lymphovascular invasion is identified by the demonstration of melanoma cells within the lumina of blood vessels or lymphatics, or both.<sup>1</sup> Immunohistochemistry for vascular endothelial cell markers CD31, CD34 or ERG or the lymphatic marker D2-40 may assist in the identification of the presence of intravascular or intralymphatic tumor by highlighting vascular lumina. Vascular invasion by melanoma correlates independently with worsened overall survival.<sup>2</sup> The detection of LVI is increased in primary melanomas when double labeling of tumor cells and lymphatic endothelium is applied.<sup>3</sup>

#### References

1. Gershenwald JE, Scolyer RA, Hess KR, et al. Melanoma of the skin, In: Amin MB, Edge SB, Greene FL, et al. eds. *AJCC Cancer Staging Manual*. 8th ed. New York, NY: Springer; 2017.
2. Petersson F, Diwan AH, Ivan D, Gershenwald JE, Johnson MM, Harrell R, Prieto VG. Immunohistochemical detection of lymphovascular invasion with D2-40 in melanoma correlates with sentinel lymph node status, metastasis and survival. *J Cutan Pathol*. 2009;36(11):1157-1163.
3. Feldmeyer L, Tetzlaff M, Fox P, et al. Prognostic Implication of Lymphovascular Invasion Detected by Double Immunostaining for D2-40 and MITF1 in Primary Cutaneous Melanoma. *Am J Dermatopathol*. 2016;38(7):484-491.

### J. Neurotropism

Neurotropism is defined as the presence of melanoma cells abutting nerve sheaths usually circumferentially (perineural invasion) or within nerves (intra-neural invasion).<sup>1</sup> Occasionally, the tumor itself may form neuroid structures (termed ‘neural transformation’ and this is also regarded as neurotropism). Neurotropism is best identified at the periphery of the tumor; the presence of melanoma cells around nerves in the main tumor mass caused by “entrapment” of nerves in the expanding tumor does not represent neurotropism.

Neurotropism is most commonly identified in desmoplastic melanomas (sometimes termed desmoplastic neurotropic melanoma) but may occur in any melanoma subtype.<sup>2</sup> Neurotropism may correlate with an increased risk for local recurrence.

#### References

1. Gershenwald JE, Scolyer RA, Hess KR, et al. Melanoma of the skin, In: Amin MB, Edge SB, Greene FL, et al. eds. *AJCC Cancer Staging Manual*. 8th ed. New York, NY: Springer; 2017.
2. Elder DE, Massi D, Scolyer RA, Willemze R. eds. *WHO Classification of Skin Tumors*. World Health Organization of Tumors, 4th ed Volume 11. Lyon France; 2018, ISBN-13 978-92-832-2440-2.

**K. Tumor-Infiltrating Lymphocytes**

A paucity of tumor-infiltrating lymphocytes (TILs) is an adverse prognostic factor for cutaneous melanoma.<sup>1</sup> Tumor-infiltrating lymphocytes may be assessed in a semiquantitative way, as defined below. To qualify as TILs, lymphocytes need to surround and disrupt tumor cells of the invasive component of the tumor.

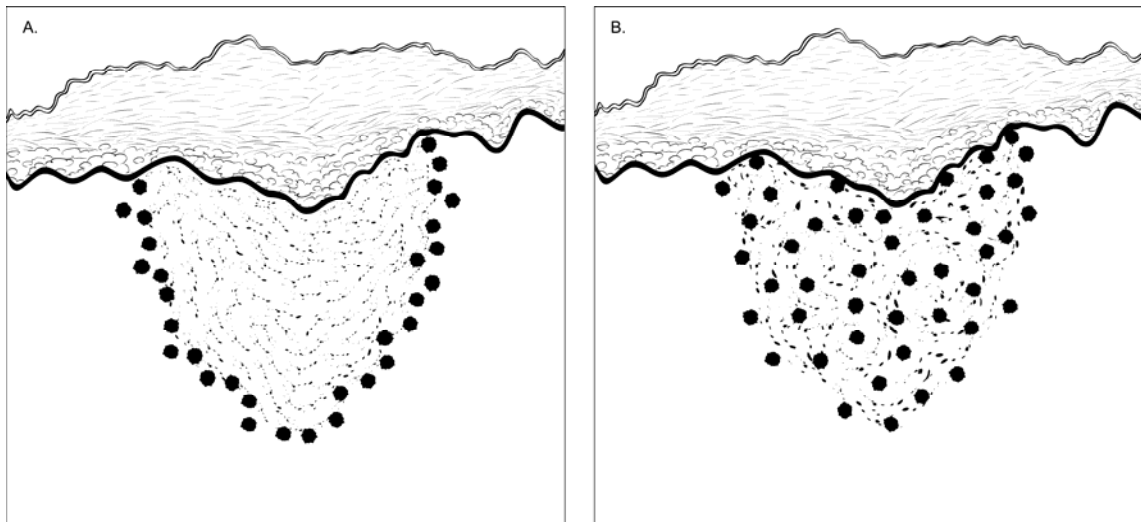
TILs Not Identified: No lymphocytes present, or lymphocytes present but do not infiltrate tumor at all.

TILs Nonbrisk: Lymphocytes infiltrate melanoma only focally or not along the entire base of the invasive tumor.

TILs Brisk: Lymphocytes diffusely infiltrate the entire base of the invasive tumor (Figure 1, A) or show diffuse permeation of the invasive tumor (Figure 1, B).

**References**

1. Crowson AN, Magro CM, Mihm MC. Prognosticators of melanoma, the melanoma report, and the sentinel lymph node. *Mod Pathol.* 2006;19(Suppl 2):S71-87.



**Figure 1.** Brisk tumor-infiltrating lymphocytes. A. Lymphocytes diffusely infiltrate the entire base of the invasive tumor. B. Lymphocytes diffusely infiltrate the entire invasive component of the melanoma.

**L. Tumor Regression**

Characteristic features of regression include replacement of tumor cells by lymphocytic inflammation, as well as attenuation of the epidermis and nonlaminated dermal fibrosis with inflammatory cells, melanophagocytosis, and telangiectasia.

**M. Regional Lymph Nodes**

Removal of sentinel lymph nodes may be performed for patients with clinically localized primary cutaneous melanomas with a thickness of 1 mm or greater, or in selected patients with thinner tumors with other adverse prognostic features.<sup>1,2</sup> Frozen section analysis of sentinel lymph nodes is not advised.<sup>1</sup> Review of the H&E-stained slides from multiple levels through serially sliced sentinel lymph nodes increases the sensitivity of detecting microscopic melanoma metastasis; routine analysis (H&E-stained sections of the cut surfaces of a simply bisected lymph node) may lead to a false-negative rate of 10%-15%. The use of immunohistochemical stains (eg, for HMB-45 or MART-1) further increases the sensitivity of detection of microscopic melanoma metastases and should also be considered in the examination of sentinel lymph nodes. Although immunohistochemical staining should be used in conjunction with and not in place of standard H&E histologic examination, immunohistochemically identified micrometastases are accepted as representing greater than N0 disease by the 8<sup>th</sup> edition of the AJCC staging system (as in the 7<sup>th</sup> edition), ie, a lymph node in which any metastatic tumor cells are identified, irrespective of the number of cells or whether they were identified on H&E or immunostained sections, should be designated as a tumor-positive node.<sup>2</sup>

For histologic examination, whether for sentinel node analysis or for routine regional lymph node evaluation, the entire node, except tissue collected for consented research protocols, should be submitted. For routine evaluation, large lymph nodes may be bisected or sliced at 2-3 mm intervals, whereas smaller nodes (less than 5 mm) may be submitted whole.

Data from multiple studies<sup>3-5</sup> indicated that the sentinel lymph node tumor burden and/or the microanatomical region/compartments of the sentinel node occupied by the metastasis may be useful in predicting patients who have additional disease in nonsentinel nodes as well as disease outcome. Because sentinel node tumor burden is considered a regional disease prognostic factor, it should be reported in all patients with a positive sentinel node but it is not used to determine N-category groupings in the 8<sup>th</sup> edition of the AJCC staging system. The current National Comprehensive Cancer Network (NCCN) guidelines<sup>6</sup> also recommend recording the size and location of tumor present in a positive sentinel node.

#### References

1. Scolyer RA, Thompson JF, McCarthy SW, Gershenwald JE, Ross MI, Cochran AJ. Intraoperative frozen-section evaluation can reduce accuracy of pathologic assessment of sentinel nodes in melanoma patients. *J Am Coll Surg.* 2005;201(5):821-823; author reply 823-824.
2. Gershenwald JE, Scolyer RA, Hess KR, et al. Melanoma of the skin, In: Amin MB, Edge SB, Greene FL, et al. eds. *AJCC Cancer Staging Manual.* 8th ed. New York, NY: Springer; 2017.
3. Gershenwald JE, Andtbacka RH, Prieto VG, et al. Microscopic tumor burden in sentinel lymph nodes predicts synchronous nonsentinel lymph node involvement in patients with melanoma. *J Clin Oncol.* 2008;26(26):4296-4303.
4. van Akkooi AC, Nowecki ZI, Voit C, et al. Sentinel node tumor burden according to the Rotterdam criteria is the most important prognostic factor for survival in melanoma patients: a multicenter study in 388 patients with positive sentinel nodes. *Ann Surg.* 2008;248(6):949-955.
5. Dewar DJ, Newell B, Green MA, Topping AP, Powell BW, Cook MG. The microanatomic location of metastatic melanoma in sentinel lymph nodes predicts nonsentinel lymph node involvement. *J Clin Oncol.* 2004;22(16):3345-3349.
6. Coit DG, Andtbacka R, Bichakjian CK, et al. Melanoma. *J Natl Compr Canc Netw.* 2009;7(3):250-275.

#### N. Pathologic Stage Classification

Changes in the 8<sup>th</sup> edition *AJCC Cancer Staging Manual*<sup>1</sup> of importance to practicing pathologists include:

- T1a melanoma now defined as non-ulcerated melanomas less than 0.8mm thick
- T1b melanomas now defined as melanoma between 0.8mm and 1.0mm in thickness OR ulcerated melanomas less than 0.8mm thick
- Tumor mitotic rate no longer used as a T category criterion but remains an important prognostic factor and should be reported in all invasive primary melanomas
- Recommendation to record tumor thickness to the nearest 0.1mm (not the nearest 0.01mm)
- Regarding regional lymph node metastasis, the previously empirically defined terms “microscopic” and “macroscopic” replaced with “clinically occult” (ie, detected by sentinel node biopsy) and “clinically detected”
- Non-nodal regional metastatic disease (ie, microsattellites, satellites and in transit metastases) now formally stratified by N category according to the number of tumor-involved nodes
- Gross extranodal extension no longer used as an N-category criterion (but presence of “matted nodes” retained)
- M1 now defined by both anatomic site of distant metastasis and serum LDH levels for all anatomic subsite categories of metastasis
- New M1d designation added for distant metastasis to central nervous system
- pT1bN0M0 is now pathologic stage IA in contrast to cT1N0M0 which remains clinical stage IB disease
- N category now defines four stage subgroups and takes into account both T category elements and N category elements

Pathologic staging includes microstaging of the primary melanoma and pathologic information about the regional lymph nodes after partial or complete lymphadenectomy.

In virtually all studies of cutaneous melanoma, tumor thickness has been shown to be a dominant prognostic factor, and it forms the basis for the stratification of pT. Although anatomic (Clark) levels are also commonly used to indicate depth of invasion of the primary tumor, they are less predictive of clinical outcome than mitotic activity or ulceration.<sup>1,2,3</sup>

By AJCC convention, the designation “T” refers to a primary tumor that has not been previously treated. Similarly by convention, clinical staging is performed after biopsy of the primary melanoma (including utilizing pathologic information on microstaging of the primary melanoma) with clinical or biopsy assessment of regional lymph nodes and distant sites. Pathologic staging uses information gained from pathologic evaluation of both the primary melanoma after biopsy *and* wide excision as well as pathological evaluation of the regional node basin after SLN biopsy (required for N categorization of all greater than T1 melanomas) and/or complete regional lymphadenectomy.<sup>1,2</sup> In addition, for pathological staging, if information from any prior biopsy is known and is relevant for staging, this should be documented in the pathology report (in the staging section) and used for assigning T, N and M categories and staging purposes.

### T Category Considerations

Pathologic (microscopic) assessment of the primary tumor is required for accurate staging. Therefore, excision of the primary tumor, rather than incisional biopsy, is advised. The T classification of melanoma is based on the thickness of the primary tumor and presence or absence of ulceration (see also Notes D, and E).

### References

1. Gershenwald JE, Scolyer RA, Hess KR, et al. Melanoma of the skin, In: Amin MB, Edge SB, Greene FL, et al. eds. *AJCC Cancer Staging Manual*. 8th ed. New York, NY: Springer; 2017.
2. Gershenwald JE, Scolyer RA, Hess KR, Sondak VK, Long GV, Ross MI et al. Melanoma staging: Evidence-based changes in the American Joint Committee on Cancer eighth edition cancer staging manual. *CA Cancer J Clin*. 2017;67(6):472-92.
3. Elder DE, Massi D, Scolyer RA, Willemze R. eds. *WHO Classification of Skin Tumors*. World Health Organization of Tumors, 4th ed Volume 11. Lyon France; 2018, ISBN-13 978-92-832-2440-2.