



cap

Protocol for the Examination of Specimens From Patients With Carcinoma of the Small Intestine

Protocol applies to all invasive carcinomas of the small intestine, including those with focal endocrine differentiation. Tumors arising in the ampulla of Vater and well-differentiated neuroendocrine tumors (carcinoid tumors) are not included.

Based on AJCC/UICC TNM, 7th edition

Protocol web posting date: June 2012

Procedures

- Segmental Resection
- Pancreaticoduodenectomy, Partial or Complete, with or without Partial Gastrectomy (Whipple Resection)

Authors

Kay Washington, MD, PhD, FCAP*

Department of Pathology, Vanderbilt University Medical Center, Nashville, TN

Jordan Berlin, MD

Department of Medicine, Vanderbilt University Medical Center, Nashville, TN

Philip Branton, MD, FCAP

Department of Pathology, Inova Fairfax Hospital, Falls Church, VA

Lawrence J. Burgart, MD, FCAP

Allina Laboratories, Abbott Northwestern Hospital, Minneapolis, MN

David K. Carter, MD, FCAP

Department of Pathology, St. Mary's/Duluth Clinic Health System, Duluth, MN

Patrick Fitzgibbons, MD, FCAP

Department of Pathology, St. Jude Medical Center, Fullerton, CA

Wendy L. Frankel, MD, FCAP

Department of Pathology, Ohio State University Medical Center, Columbus, OH

Kevin C. Halling, MD, PhD, FCAP

Department of Laboratory Medicine and Pathology, Mayo Clinic, Rochester, MN

John Jessup, MD

Division of Cancer Treatment and Diagnosis, National Cancer Institute, Bethesda, MD

Sanjay Kakar, MD, FCAP

Department of Pathology, University of California San Francisco and the Veterans Affairs Medical Center, San Francisco, CA

Bruce Minsky, MD

Department of Radiation Oncology, University of Chicago, Chicago, IL

Raouf Nakhleh, MD, FCAP

Department of Pathology, Mayo Clinic, Jacksonville, FL

Laura H. Tang, MD, PhD, FCAP

Department of Pathology, Memorial Sloan-Kettering Cancer Center, New York, NY

Carolyn C. Compton, MD, PhD, FCAP†

Critical Path Institute, Tucson, AZ

For the Members of the Cancer Committee, College of American Pathologists

* Denotes primary author. † Denotes senior author. All other contributing authors are listed alphabetically.

Previous contributors: Stephen G. Ruby, MD; Gregorio Chejfec, MD; John A. Payne, MD; Jerome B. Taxy, MD; Kay Washington, MD; Christopher Willett, MD; James Williams, MD

© 2012 College of American Pathologists (CAP). All rights reserved.

The College does not permit reproduction of any substantial portion of these protocols without its written authorization. The College hereby authorizes use of these protocols by physicians and other health care providers in reporting on surgical specimens, in teaching, and in carrying out medical research for nonprofit purposes. This authorization does not extend to reproduction or other use of any substantial portion of these protocols for commercial purposes without the written consent of the College.

The CAP also authorizes physicians and other health care practitioners to make modified versions of the Protocols solely for their individual use in reporting on surgical specimens for individual patients, teaching, and carrying out medical research for non-profit purposes.

The CAP further authorizes the following uses by physicians and other health care practitioners, in reporting on surgical specimens for individual patients, in teaching, and in carrying out medical research for non-profit purposes: (1) **Dictation** from the original or modified protocols for the purposes of creating a text-based patient record on paper, or in a word processing document; (2) **Copying** from the original or modified protocols into a text-based patient record on paper, or in a word processing document; (3) The use of a **computerized system** for items (1) and (2), provided that the Protocol data is stored intact as a single text-based document, and is not stored as multiple discrete data fields.

Other than uses (1), (2), and (3) above, the CAP does not authorize any use of the Protocols in electronic medical records systems, pathology informatics systems, cancer registry computer systems, computerized databases, mappings between coding works, or any computerized system without a written license from CAP. Applications for such a license should be addressed to the SNOMED Terminology Solutions division of the CAP.

Any public dissemination of the original or modified Protocols is prohibited without a written license from the CAP.

The College of American Pathologists offers these protocols to assist pathologists in providing clinically useful and relevant information when reporting results of surgical specimen examinations of surgical specimens. The College regards the reporting elements in the "Surgical Pathology Cancer Case Summary" portion of the protocols as essential elements of the pathology report. However, the manner in which these elements are reported is at the discretion of each specific pathologist, taking into account clinician preferences, institutional policies, and individual practice.

The College developed these protocols as an educational tool to assist pathologists in the useful reporting of relevant information. It did not issue the protocols for use in litigation, reimbursement, or other contexts. Nevertheless, the College recognizes that the protocols might be used by hospitals, attorneys, payers, and others. Indeed, effective January 1, 2004, the Commission on Cancer of the American College of Surgeons mandated the use of the required data elements of the protocols as part of its Cancer Program Standards for Approved Cancer Programs. Therefore, it becomes even more important for pathologists to familiarize themselves with these documents. At the same time, the College cautions that use of the protocols other than for their intended educational purpose may involve additional considerations that are beyond the scope of this document.

The inclusion of a product name or service in a CAP publication should not be construed as an endorsement of such product or service, nor is failure to include the name of a product or service to be construed as disapproval.

CAP Small Intestine Protocol Revision History

Version Code

The definition of the version code can be found at www.cap.org/cancerprotocols.

Version: SmallIntestine 3.1.0.2

Summary of Changes

The following changes have been made since the February 2011 release.

Segmental Resection, Pancreaticoduodenectomy (Whipple Resection)

Histologic Type

The term "Mixed carcinoid-adenocarcinoma" was changed to "Mixed adenoneuroendocrine carcinoma."

"Small cell carcinoma" was replaced with the following:

- High-grade neuroendocrine carcinoma
- Large cell neuroendocrine carcinoma
- Small cell neuroendocrine carcinoma

Margins

For "If all margins uninvolved..." "Specify margin (if possible)" was changed from optional to required.

The following was added:

Other Margin(s) (required only if applicable)

Specify margin(s): _____

- Cannot be assessed
- Uninvolved by invasive carcinoma
- Involved by invasive carcinoma

Explanatory Notes

Histologic Type: Histologic types were updated, as detailed above.

T Category Considerations

The captions for Figures 6 and 7 have been swapped.

References

Reference #4 was updated.

Surgical Pathology Cancer Case Summary

Protocol web posting date: June 2012

SMALL INTESTINE: Segmental Resection, Pancreaticoduodenectomy (Whipple Resection)**Select a single response unless otherwise indicated.****Specimen (select all that apply)**

- Duodenum
 Small intestine, other than duodenum
 + Jejunum
 + Ileum

Other organs received:

- Stomach
 Head of pancreas
 Ampulla
 Common bile duct
 Gallbladder
 Colon
 Other (specify): _____
 Not specified

Procedure

- Segmental resection
 Pancreaticoduodenectomy (Whipple resection)
 Other (specify): _____
 Not specified

Tumor Site (Note A)

- Duodenum
 Small intestine, other than duodenum
 + Jejunum
 + Ileum
 Other (specify): _____
 Not specified

Tumor Size

- Greatest dimension: ___ cm
 + Additional dimensions: ___ x ___ cm
 Cannot be determined (see Comment)

Macroscopic Tumor Perforation

- Present
 Not identified
 Cannot be determined

Histologic Type (Note B)

- Adenocarcinoma (not otherwise characterized)
- Mucinous adenocarcinoma (greater than 50% mucinous)
- Signet-ring cell carcinoma (greater than 50% signet-ring cells)
- High-grade neuroendocrine carcinoma
 - Large cell neuroendocrine carcinoma
 - Small cell neuroendocrine carcinoma
- Squamous cell carcinoma
- Adenosquamous carcinoma
- Medullary carcinoma
- Undifferentiated carcinoma
- Mixed adenoneuroendocrine carcinoma
- Other (specify): _____

Histologic Grade (Note C)

- Not applicable
- GX: Cannot be assessed
- G1: Well differentiated
- G2: Moderately differentiated
- G3: Poorly differentiated
- G4: Undifferentiated
- Other (specify): _____

Microscopic Tumor Extension

- Cannot be assessed
- No evidence of primary tumor
- Tumor invades lamina propria
- Tumor invades submucosa
- Tumor invades muscularis propria
- Tumor invades through the muscularis propria into the subserosal adipose tissue or the nonperitonealized peri-intestinal soft tissues but does not extend to the serosal surface
- Tumor microscopically involves the serosal surface (visceral peritoneum)
- Tumor directly invades adjacent structures (specify: _____)
- Tumor penetrates to the surface of the visceral peritoneum (serosa) and directly invades adjacent structures (specify: _____)

Margins (select all that apply) (Note D)

If all margins uninvolved by invasive carcinoma:

Distance of invasive carcinoma from closest margin: ___ mm or ___ cm

Specify margin (if possible): _____

Segmental Resection or Pancreaticoduodenectomy (Whipple)*Proximal Margin*

- Cannot be assessed
- Uninvolved by invasive carcinoma
- Involved by invasive carcinoma
- Intramucosal carcinoma/adenoma not identified at proximal margin
- Intramucosal carcinoma/adenoma present at proximal margin

Distal Margin

- Cannot be assessed
- Uninvolved by invasive carcinoma
- Involved by invasive carcinoma
- Intramucosal carcinoma/adenoma not identified at distal margin
- Intramucosal carcinoma /adenoma present at distal margin

Circumferential (Radial) or Mesenteric Margin

- Not applicable
- Cannot be assessed
- Uninvolved by invasive carcinoma
- Involved by invasive carcinoma (tumor present 0-1 mm from margin)

Other Margin(s) (required only if applicable)

Specify margin(s): _____

- Cannot be assessed
- Uninvolved by invasive carcinoma
- Involved by invasive carcinoma

Pancreaticoduodenectomy (Whipple)

Bile Duct Margin

- Not applicable
- Cannot be assessed
- Margin uninvolved by invasive carcinoma
- Margin involved by invasive carcinoma

Pancreatic Margin

- Not applicable
- Cannot be assessed
- Margin uninvolved by invasive carcinoma
- Margin involved by invasive carcinoma

Lymph-Vascular Invasion

- Not identified
- Present
- Indeterminate

Pathologic Staging (pTNM) (Note E)

TNM Descriptors (required only if applicable) (select all that apply)

- m (multiple primary tumors)
- r (recurrent)
- y (posttreatment)

+ Data elements preceded by this symbol are not required. However, these elements may be clinically important but are not yet validated or regularly used in patient management.

Primary Tumor (pT)

- pTX: Cannot be assessed
- pT0: No evidence of primary tumor
- pTis: Carcinoma in situ
- pT1a: Tumor invades lamina propria
- pT1b: Tumor invades submucosa
- pT2: Tumor invades muscularis propria
- pT3: Tumor invades through the muscularis propria into the subserosa or into the nonperitonealized perimuscular tissue (mesentery or retroperitoneum) with extension 2 cm or less
- pT4: Tumor perforates the visceral peritoneum or directly invades other organs or structures (includes other loops of small intestine, mesentery, or retroperitoneum more than 2 cm, and abdominal wall by way of serosa; for duodenum only, invasion of pancreas or bile duct)

Regional Lymph Nodes (pN)

- pNX: Cannot be assessed
- pN0: No regional lymph node metastasis
- pN1: Metastasis in 1 to 3 regional lymph nodes
- pN2: Metastasis in 4 or more regional lymph nodes

No nodes submitted or found

Number of Lymph Nodes Examined

Specify:

Number cannot be determined (explain): _____

Number of Lymph Nodes Involved

Specify:

Number cannot be determined (explain): _____

Distant Metastasis (pM)

Not applicable

pM1: Distant metastasis
+ Specify site(s), if known: _____

+ Additional Pathologic Findings (select all that apply) (Note F)

- + None identified
- + Adenoma(s)
- + Crohn's disease
- + Celiac disease
- + Other polyps (type[s]): _____
- + Other (specify): _____

+ Ancillary Studies (select all that apply) (Note G)

- + Microsatellite instability (specify testing method): _____
 - + Stable
 - + Low
 - + High

+ Data elements preceded by this symbol are not required. However, these elements may be clinically important but are not yet validated or regularly used in patient management.

+ Immunohistochemistry Studies For Mismatch Repair Proteins

- + MLH1
 - + Immunoreactive tumor cells present (nuclear positivity)
 - + No immunoreactive tumor cells present
 - + Pending
 - + Other (specify): _____
- + MSH2
 - + Immunoreactive tumor cells present (nuclear positivity)
 - + No immunoreactive tumor cells present
 - + Pending
 - + Other (specify): _____
- + MSH6
 - + Immunoreactive tumor cells present (nuclear positivity)
 - + No immunoreactive tumor cells present
 - + Pending
 - + Other (specify): _____
- + PMS2
 - + Immunoreactive tumor cells present (nuclear positivity)
 - + No immunoreactive tumor cells present
 - + Pending
 - + Other (specify): _____

+ Other (specify): _____

+ **Clinical History (select all that apply) (Note F)**

- + Familial adenomatous polyposis coli
- + Hereditary nonpolyposis colon cancer
- + Other polyposis syndrome (specify): _____
- + Crohn's disease
- + Celiac disease
- + Other (specify): _____
- + Not known

+ **Comment(s)**

Explanatory Notes

A. Tumor Site

The majority of small intestinal carcinomas arise in the duodenum (64%),¹ most commonly around the ampulla of Vater (Figure 1). Approximately 20% arise in the jejunum and 15% in the ileum. Duodenal location has been implicated as a risk factor for poorer outcome.²

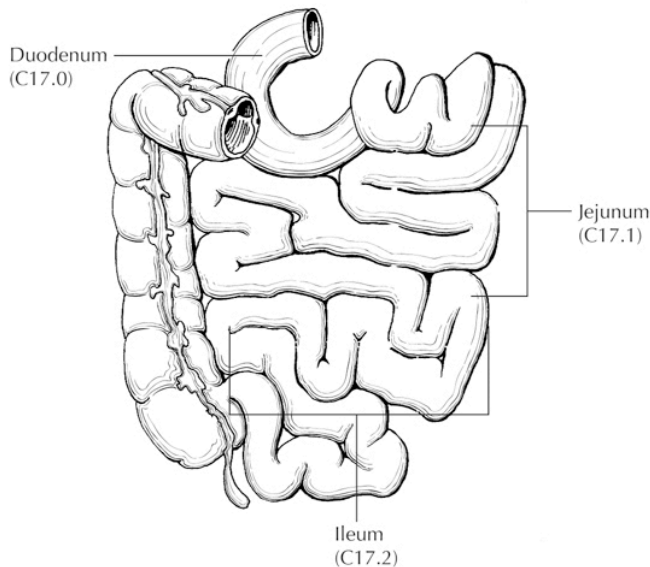


Figure 1. Anatomical sites of the small intestine. From: Greene FL et al.¹⁸ Used with permission of the American Joint Committee on Cancer (AJCC), Chicago, Illinois. The original source for this material is the *AJCC Cancer Staging Atlas* (2006) published by Springer Science and Business Media LLC, www.springerlink.com.

B. Histologic Type

The most common tumor types arising in the small intestine are adenocarcinomas (24% to 44%), low-grade neuroendocrine tumors (20% to 42%), gastrointestinal stromal tumors (7% to 9%), and lymphoma (12% to 27%).³

For tumors of the small intestine, the protocol recommends the histologic classification published by the World Health Organization (WHO),⁴ as shown below.

WHO Classification of Small Intestinal Carcinoma

Adenocarcinoma

Mucinous adenocarcinoma (greater than 50% mucinous)

Signet-ring cell carcinoma (greater than 50% signet-ring cells)[#]

High-grade neuroendocrine carcinoma

 Large cell neuroendocrine carcinoma

 Small cell neuroendocrine carcinoma^{##}

Squamous cell carcinoma

Adenosquamous carcinoma

Medullary carcinoma

Undifferentiated carcinoma^{##}

Mixed adenoneuroendocrine carcinoma

Other (specify)

#By convention, signet-ring cell carcinoma is always assigned grade 3 (see Note C).

##By convention, small cell carcinoma and undifferentiated carcinoma are assigned grade 4 (see Note C).

The term "carcinoma, NOS (not otherwise specified)" is not part of the WHO classification.

C. Histologic Grade

A histologic grading system for adenocarcinomas based on the extent of glandular formation in the tumor is recommended, as shown below.

Grade X	Grade cannot be assessed
Grade 1	Well differentiated (more than 95% of tumor composed of glands)
Grade 2	Moderately differentiated (50% to 95% of tumor composed of glands)
Grade 3	Poorly differentiated (less than 50% of tumor composed of glands)

Grade 4 is reserved for small cell carcinoma and undifferentiated carcinoma (WHO classification).

Most small bowel carcinomas are moderately differentiated, followed by poorly differentiated; a minority are well differentiated. Grade does not appear to be a strong predictor of outcome.^{1,2}

D. Margins

For segmental small bowel resections, margins include the proximal, distal, and mesenteric margins of resection. For all small bowel segments, except the duodenum, the mesenteric resection margin is the only pertinent radial margin (Figure 2). For pancreaticoduodenectomy specimens of carcinomas of the duodenum, the nonperitonealized surface constitutes a deep radial (nonperitonealized soft tissue) margin. In such specimens, the proximal margin of stomach or duodenum (pylorus-sparing Whipple resection) and the distal resection margin of duodenum are more biologically relevant than in pancreaticoduodenectomy procedures performed for pancreatic carcinoma and should always be sampled.

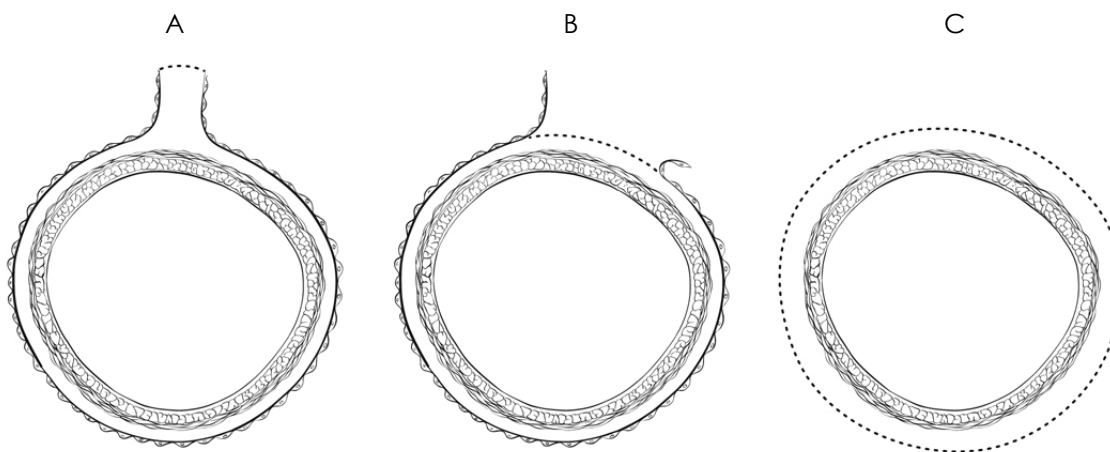


Figure 2. A, Mesenteric margin in small intestine completely encased by peritoneum (dotted line). B, Circumferential margin (dotted line) in portion of proximal duodenum incompletely encased by peritoneum. C, Circumferential margin (dotted line) in retroperitoneal portion of duodenum completely unencased by peritoneum.

E. TNM and Anatomic Stage/Prognostic Groupings

Surgical resection is the most effective therapy for small intestinal carcinoma,² and the best estimation of prognosis is related to the anatomic extent (stage) of disease at the time of resection.

The protocol recommends the TNM staging system of the American Joint Committee on Cancer (AJCC)⁵ and the International Union Against Cancer (UICC)⁶ but does not preclude the use of other staging systems.

According to AJCC/UICC convention, the designation "T" refers to a primary tumor that has not been previously treated. The symbol "p" refers to the pathologic classification of the TNM, as opposed to the clinical classification, and is based on gross and microscopic examination. pT entails a resection of the primary tumor or biopsy adequate to evaluate the highest pT category, pN entails removal of nodes adequate to validate lymph node metastasis, and pM implies microscopic examination of distant lesions. Clinical classification (cTNM) is usually carried out by the referring physician before treatment during initial evaluation of the patient or when pathologic classification is not possible.

Pathologic staging is usually performed after surgical resection of the primary tumor. Pathologic staging depends on pathologic documentation of the anatomic extent of disease, whether or not the primary tumor has been completely removed. If a biopsied tumor is not resected for any reason (eg, when technically infeasible) and if the highest T and N categories or the M1 category of the tumor can be confirmed microscopically, the criteria for pathologic classification and staging have been satisfied without total removal of the primary cancer.

TNM Descriptors

For identification of special cases of TNM or pTNM classifications, the "m" suffix and "y" and "r" prefixes are used. Although they do not affect the stage grouping, they indicate cases needing separate analysis.

The "m" suffix indicates the presence of multiple primary tumors in a single site and is recorded in parentheses: pT(m)NM.

The "y" prefix indicates those cases in which classification is performed during or after initial multimodality therapy (ie, neoadjuvant chemotherapy, radiation therapy, or both chemotherapy and radiation therapy). The cTNM or pTNM category is identified by a "y" prefix. The ycTNM or ypTNM categorizes the extent of tumor actually present at the time of that examination. The "y" categorization is not an estimate of tumor before multimodality therapy (ie, before initiation of neoadjuvant therapy).

The "r" prefix indicates a recurrent tumor when staged after a documented disease-free interval and is identified by the "r" prefix: rTNM.

T Category Considerations

pTis. For small intestinal carcinomas, "carcinoma in situ" (pTis) as a staging term includes cancer cells confined within the glandular basement membrane (high-grade dysplasia). The term "carcinoma in situ" is not widely applied to glandular neoplastic lesions in the gastrointestinal tract but is retained for tumor registry reporting purposes as specified by law in many states. Tumor invasive into the mucosal lamina propria, up to but not through the muscularis mucosae (intramucosal carcinoma), is classified as pT1a. This designation differs from that for colon, in which tumor extension into the lamina propria is regarded as in situ carcinoma, because of the rich lymphatic network in small intestinal mucosa. Tumor extension through the muscularis mucosae into the submucosa is classified as T1b (Figure 3). T2 tumors invade the muscularis propria (Figure 4), and T3 tumors invade subserosal tissues without extension to the peritoneal (serosal) surface or invasion of adjacent organs (Figure 5).

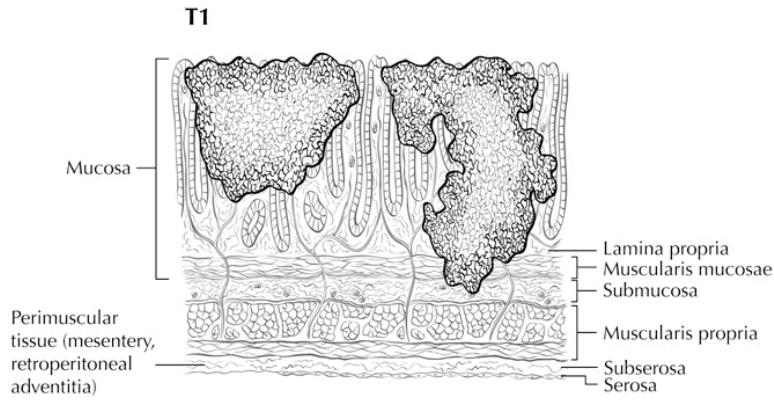


Figure 3. T1a (left side) with tumor invasion of lamina propria; T1b (right side) with tumor invasion of submucosa. From: Greene FL et al.¹⁸ Used with permission of the American Joint Committee on Cancer (AJCC), Chicago, Illinois. The original source for this material is the *AJCC Cancer Staging Atlas* (2006) published by Springer Science and Business Media LLC, www.springerlink.com.

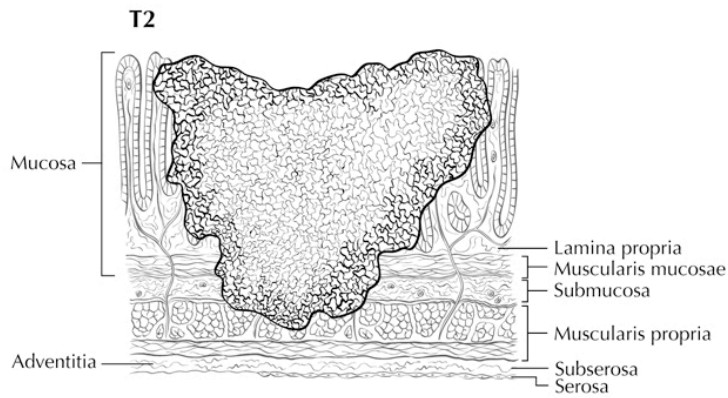


Figure 4. T2 is defined as tumor invading muscularis propria. From: Greene FL et al.¹⁸ Used with permission of the American Joint Committee on Cancer (AJCC), Chicago, Illinois. The original source for this material is the *AJCC Cancer Staging Atlas* (2006) published by Springer Science and Business Media LLC, www.springerlink.com.

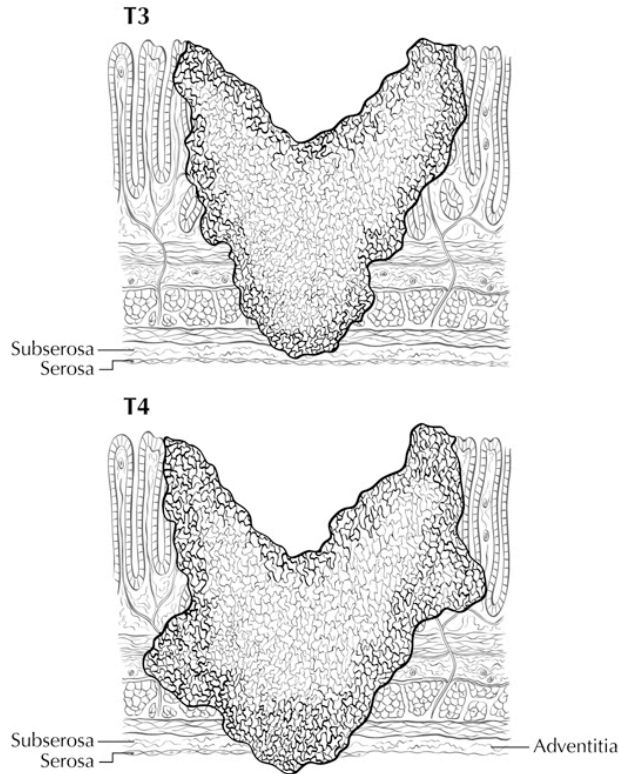


Figure 5. T3 tumors invade through muscularis propria into subserosal adipose tissue; T4a is defined as tumor extension to the peritoneal (serosal) surface. From: Greene FL et al.¹⁸ Used with permission of the American Joint Committee on Cancer (AJCC), Chicago, Illinois. The original source for this material is the *AJCC Cancer Staging Atlas* (2006) published by Springer Science and Business Media LLC, www.springerlink.com.

pT4. Direct invasion of other organs (Figure 6) or structures, including invasion of other segments of small intestine by way of the serosa or mesentery, is classified as pT4b (Figure 7). In such a case, both an adjacent organ and the visceral peritoneum are penetrated by tumor. Intramural extension of tumor from the terminal ileum into the cecum does not affect the pT classification.⁴

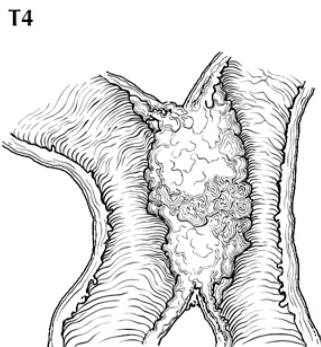


Figure 6. T4b is defined as direct invasion of other organs or structures, including other loops of small intestine. From: Greene FL et al.¹⁸ Used with permission of the American Joint Committee on Cancer (AJCC), Chicago, Illinois. The original source for this material is the *AJCC Cancer Staging Atlas* (2006) published by Springer Science and Business Media LLC, www.springerlink.com.

T4

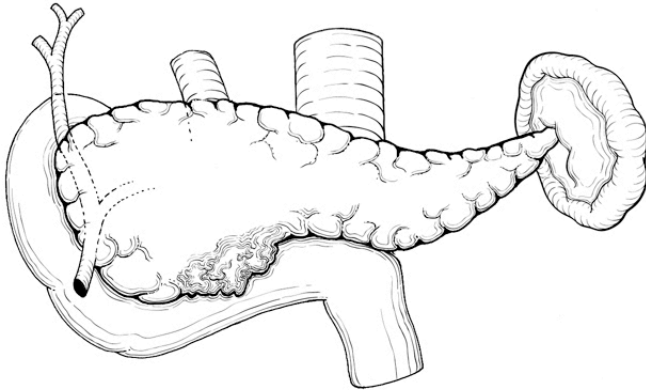


Figure 7. T4b tumor of the duodenum invading the pancreas. From: Greene FL et al.¹⁸ Used with permission of the American Joint Committee on Cancer (AJCC), Chicago, Illinois. The original source for this material is the *AJCC Cancer Staging Atlas* (2006) published by Springer Science and Business Media LLC, www.springerlink.com.

Tumor that is adherent to other organs or structures macroscopically is classified as T4. However, if no tumor is found within the adhesion microscopically, the tumor should be assigned T3.

Tumor in veins or lymphatics does not affect the pT classification.

Subdivision of T4 into T4a and T4b. The T4a and T4b subcategories for small intestine are identical to those for colorectal carcinomas. Although data are mostly lacking for small intestinal carcinomas, serosal involvement by tumor cells (pT4a) in colorectal carcinoma has been demonstrated by multivariate analysis to have a negative impact on prognosis.⁷ The absence of standard guidelines for assessing peritoneal involvement may contribute to underdiagnosis.

N Category Considerations

The regional lymph nodes for the anatomical subsites of the small intestine are as follows:⁵

Duodenum: duodenal, hepatic, pancreaticoduodenal, infrapyloric, gastroduodenal, pyloric, superior mesenteric, pericholedochal
 Ileum and jejunum: posterior cecal (terminal ileum only), ileocolic (terminal ileum only), superior mesenteric, mesenteric, NOS.

Submission of lymph nodes for microscopic examination. All grossly negative or equivocal lymph nodes are to be submitted entirely. Grossly positive lymph nodes may be partially submitted for microscopic confirmation of metastasis.

The minimum number of lymph nodes that predicts regional node negativity has not been defined for small intestinal cancers. The pathology report should clearly state the total number of lymph nodes examined and the total number involved by metastases. Data are insufficient to recommend routine use of tissue levels or special/ancillary techniques to detect micrometastases or isolated tumor cells.

Nonregional lymph nodes. For microscopic examination of lymph nodes in large resection specimens, lymph nodes must be designated as regional versus nonregional, according to the anatomic location of the tumor. Metastasis to nonregional lymph nodes is classified as distant metastasis and designated as M1.

Primary Tumor (T)

TX	Cannot be assessed
T0	No evidence of primary tumor
Tis	Carcinoma in situ
T1a	Tumor invades lamina propria
T1b	Tumor invades submucosa
T2	Tumor invades muscularis propria
T3	Tumor invades through the muscularis propria into the subserosa or the nonperitonealized perimuscular tissue (mesentery or retroperitoneum) with extension 2 cm or less
T4	Tumor perforates the visceral peritoneum or directly invades other organs or structures (includes other loops of small intestine, mesentery, or retroperitoneum more than 2 cm, and abdominal wall by way of serosa; for duodenum only, invasion of pancreas or bile duct)

Regional Lymph Nodes (pN)

NX	Cannot be assessed
N0	No regional lymph node metastasis
N1	Metastasis in 1 to 3 regional lymph nodes
N2	Metastasis in 4 or more regional lymph nodes

Distant Metastasis (M)

M0	No distant metastasis
M1	Distant metastasis

Stage Groupings

Stage 0	Tis	N0	M0
Stage I	T1	N0	M0
	T2	N0	M0
Stage IIA	T3	N0	M0
Stage IIB	T4	N0	M0
Stage IIIA	T1,T2	N1	M0
Stage IIIB	T3,T4	N1	M0
Stage IIIC	Any T	N2	M0
Stage IV	Any T	Any N	M1

Additional DescriptorsLymph-Vascular Invasion

Lymph-vascular invasion (LVI) indicates whether microscopic lymph-vascular invasion is identified in the pathology report. LVI includes lymphatic invasion, vascular invasion, or lymph-vascular invasion. By AJCC/UICC convention, LVI does not affect the T category indicating local extent of tumor unless specifically included in the definition of a T category.

F. Relevant History

Conditions that predispose to small bowel malignancy include Crohn's disease, celiac disease, and inherited polyposis syndromes (including familial adenomatous polyposis, hereditary nonpolyposis colon cancer [HNPCC], and Peutz-Jeghers syndrome).

Small intestinal adenocarcinomas in Crohn's disease arise in the setting of long-standing ileal inflammation; cumulative risk increases after 10 years of Crohn's disease, although absolute risk (2.2% at 25 years) remains low.⁸ Signet-ring cell carcinomas appear to be more common in Crohn's disease than as de novo small intestinal carcinomas.⁹

Small intestinal carcinomas are more frequent in polyposis syndromes, most notably in familial adenomatous polyposis, in which approximately 2.3% of patients developed a duodenal adenocarcinoma;¹⁰ most tumors in these patients develop in the periampullary region, and the duodenum may be carpeted with adenomas. Peutz-Jeghers syndrome¹¹ is also associated with higher risk of small intestinal carcinoma.

Patients with HNPCC have an approximately 4% lifetime risk of developing a small bowel carcinoma; this risk exceeds that of the normal population by 100-fold. Duodenum and jejunum are the most common primary sites, and the small bowel is the first site of cancer in approximately one-fourth of HNPCC patients who develop small bowel tumors.¹² Histopathologic features of HNPCC-associated small intestinal carcinomas are similar to those of colorectal carcinomas arising in this setting; mucinous carcinomas are overrepresented, and tumors often show a high number of intratumoral lymphocytes.¹³

G. Ancillary Procedures

Special procedures may include immunohistochemical studies, histochemical stains, electron microscopy, flow cytometry, and cytogenetic studies. If such studies are performed in different laboratories, either interinstitutional or intrainstitutional, the responsible laboratory should be stated.

Testing for defects in mismatch repair in small intestinal carcinomas is important for detection of Lynch syndrome (a subset of HNPCC that accounts for approximately 2% of all colorectal carcinomas). Examination of the tissue for defective DNA mismatch repair should be considered in small intestinal carcinomas regardless of the patient's age,¹⁴ if other predisposing conditions such as familial adenomatous polyposis coli are absent. In addition, emerging data suggest that the frequency of microsatellite instability (MSI, see below; 18%) in small intestinal carcinomas is approximately equal to that of colon cancer¹⁵ and may be associated with better survival.¹⁶ However, this latter indication for testing is not clearly established and has not been accepted as standard of care.

Microsatellite Instability (MSI) Testing

Scientific rationale: The vast majority of tumors from patients with HNPCC exhibit high level microsatellite instability (MSI-H) due to defective DNA mismatch repair. Patients whose tumors do not exhibit an MSI-H phenotype are very unlikely to have HNPCC. MSI testing has high sensitivity but not necessarily high specificity for HNPCC because an MSI-H phenotype can be observed in sporadic small intestinal carcinomas. The specificity of MSI testing for HNPCC can be increased by using primarily at risk populations such as patients with a strong family history of HNPCC-associated tumors (eg, colorectal, endometrial, gastric, or upper urinary tract urothelial carcinoma).¹⁴

Clinical rationale: MSI testing can be used to cost effectively screen patients with small intestinal cancer who are at risk for possible HNPCC. Patients with an MSI-H phenotype may have a germline mutation in 1 of several DNA mismatch repair (MMR) genes (eg, *MLH1*, *MSH2*, *MSH6*, or *PMS2*) and after appropriate genetic counseling may want to consider having such testing. Follow-up germline testing for HNPCC may help in making a definitive diagnosis of the disorder and aid in the presymptomatic detection of carriers among at-risk individuals. Presymptomatic detection of carriers could lead to increased surveillance and potentially reduce morbidity and mortality.

Best method: MSI testing is generally performed with at least 5 microsatellite markers, generally mononucleotide or dinucleotide repeat markers. In 1998, a National Institutes of Health consensus panel proposed that laboratories use a 5-marker panel consisting of 3 dinucleotide and 3 mononucleotide repeats for MSI testing.¹⁷ Recent data suggest that dinucleotide repeats may have lower sensitivity and specificity for identifying tumors with an MSI-H phenotype. As a consequence, there has been a move toward including more mononucleotides and fewer dinucleotides in MSI testing

panels. Many laboratories now use a commercially available kit for MSI testing that utilizes 5 mononucleotide markers.

Quality assurance: The detection of MSI in a tumor by microsatellite analysis requires that the DNA used for the analysis be extracted from a portion of the tumor that contains approximately $\geq 40\%$ tumor cells. Thus, pathologists should help identify areas of the tumor for DNA isolation that have at least this minimum content of tumor cells. MSI testing is frequently done in conjunction with immunohistochemical (IHC) testing for DNA MMR protein expression (ie, MLH1, MSH2, MSH6, and PMS2 expression). If the results of DNA MMR IHC and MSI testing are discordant (eg, MSI-H phenotype with normal IHC or abnormal IHC with MSS phenotype), then the laboratory should make sure that the same sample was used for MSI and IHC testing and that there was no sample mix-up. College of American Pathologists proficiency testing is available through the CAP Molecular Oncology Resource committee.

Reporting guidelines: Ideally, the results of DNA MMR IHC and MSI testing should be incorporated into the surgical pathology report for the small intestinal cancer case and an interpretation of the clinical significance of these findings should be provided. If DNA MMR IHC has not been performed, this testing should be recommended for any cases that show an MSI-H phenotype because this information will help identify the gene that is most likely to have a germline mutation (eg, a patient whose tumor shows loss of MSH2 and MSH6 expression but retention of MLH1 and PMS2 expression is likely to have an MSH2 germline mutation).

Examination of expression of MLH1, MSH2, MSH6, and PMS2 is the most common IHC testing method used for suspected MSI-H cases; antibodies to these mismatch repair proteins are commercially available. Any positive reaction in the nuclei of tumor cells is considered as intact expression (normal), and it is common for intact staining to be somewhat patchy. An interpretation of expression loss should be made only if positive reaction is seen in internal control cells, such as the nuclei of stromal, inflammatory, or nonneoplastic epithelial cells. Intact expression of all 4 proteins indicates that mismatch repair enzymes tested are intact but does not entirely exclude Lynch syndrome, because approximately 5% of families may have a missense mutation (especially in *MLH1*) that can lead to a nonfunctional protein with retained antigenicity. Defects in lesser-known mismatch repair enzymes may also lead to a similar result, but this situation is rare. Loss of expression of MLH1 may be due to Lynch syndrome or methylation of the promoter region (as occurs in sporadic MSI colorectal carcinoma). Genetic testing is ultimately required for this distinction, although a specific *BRAF* mutation is present in many sporadic cases but not in familial cancers. Loss of MSH2 expression essentially always implies Lynch syndrome. PMS2 loss is often associated with loss of MLH1 and is only independently meaningful if MLH1 is intact. MSH6 is similarly related to MSH2.

References

1. Howe JR, Karnell LH, Menck HR, Scott-Conner C. Adenocarcinoma of the small bowel: review of the National Cancer Data Base, 1985-1995. *Cancer*. 1999;86:2693-2706.
2. Dabaja BS, Suki D, Pro B, Bonnen M, Ajani J. Adenocarcinoma of the small bowel: presentation, prognostic factors, and outcome of 217 patients. *Cancer*. 2004;101:518-526.
3. Zeh HJ. Cancer of the small intestine. In: DeVita VT, Hellman S, Rosenberg SA, eds. *Cancer: Principles and Practice of Oncology*. 7th ed. Philadelphia, PA: Lippincott Williams & Wilkins; 2005.
4. Bosman FT, Carneiro F, Hruban RH, Theise ND, eds. *WHO Classification of Tumours of the Digestive System*. Geneva, Switzerland: WHO Press; 2010.
5. Edge SB, Byrd DR, Carducci MA, Compton CC, eds. *AJCC Cancer Staging Manual*. 7th ed. New York, NY: Springer; 2009.
6. Sobin LH, Wittekind C. *UICC TNM Classification of Malignant Tumours*. 6th ed. New York, NY: Wiley-Liss; 2002.
7. Shepherd NA, Baxter KJ, Love SB. The prognostic importance of peritoneal involvement in colonic cancer: a prospective evaluation. *Gastroenterology*. 1997;112:1096-1102.

8. Friedman S. Cancer in Crohn's disease. [Review] [102 refs]. *Gastroenterol Clin North Am*. 2006;35:621-639.
9. Palascak-Juif V, Bouvier AM, Cosnes J, et al. Small bowel adenocarcinoma in patients with Crohn's disease compared with small bowel adenocarcinoma de novo. *Inflamm Bowel Dis*. 2005;11:828-832.
10. Jagelman DG, DeCosse JJ, Bussey HJ. Upper gastrointestinal cancer in familial adenomatous polyposis. *Lancet*. 1988;1:1149-1151.
11. Hearle N, Schumacher V, Menko FH, et al. Frequency and spectrum of cancers in the Peutz-Jeghers syndrome. *Clin Cancer Res*. 2006;12:3209-3215.
12. Rodriguez-Bigas MA, Vasen HF, Lynch HT, et al. Characteristics of small bowel carcinoma in hereditary nonpolyposis colorectal carcinoma. International Collaborative Group on HNPCC. *Cancer*. 1998;83:240-244.
13. Schulmann K, Brasch FE, Kunstmann E, et al. HNPCC-associated small bowel cancer: clinical and molecular characteristics. *Gastroenterology*. 2005;128:590-599.
14. Umar A, Boland R, Terdiman JP, et al. Revised Bethesda guidelines for hereditary nonpolyposis colorectal cancer (Lynch syndrome) and microsatellite instability. *J Nat Cancer Inst*. 2004;96:261-268.
15. Planck M, Ericson K, Piotrowska Z, Halvarsson B, Rambech E, Nilbert M. Microsatellite instability and expression of MLH1 and MSH2 in carcinomas of the small intestine. *Cancer*. 2003;97:1551-1557.
16. Brueckl WM, Heinze E, Milsmann C, et al. Prognostic significance of microsatellite instability in curatively resected adenocarcinoma of the small intestine. *Cancer Letters*. 2004;203:181-190.
17. Boland CR, Thibodeau SN, Hamilton SR, et al. A National Cancer Institute Workshop on Microsatellite Instability for cancer detection and familial predisposition: development of international criteria for the determination of microsatellite instability in colorectal cancer. *Cancer Research*. 1998;58:5248-5257.
18. Greene FL, Compton, CC, Fritz AG, et al, eds. *AJCC Cancer Staging Atlas*. New York: Springer; 2006.