



Protocol for the Examination of Specimens From Patients With Carcinoma of the Urinary Bladder

Version: UrinaryBladder 4.0.1.0

Protocol Posting Date: June 2017

Includes pTNM requirements from the 8th Edition, AJCC Staging Manual

For accreditation purposes, this protocol should be used for the following procedures AND tumor types:

Procedure	Description
Cystectomy	Includes specimens designated partial, total or radical cystectomy, radical cystoprostatectomy (for bladder cancer), and anterior exenterations
Tumor Type	Description
Carcinomas	Includes invasive carcinomas of the urinary tract, including urothelial carcinoma and its morphological variants (squamous cell carcinoma, adenocarcinoma, Müllerian carcinoma, neuroendocrine carcinoma, and sarcomatoid carcinoma) [#]

This protocol is recommended for reporting noninvasive urothelial tumors (papillary and flat), but it is not required for accreditation purposes.

This protocol is NOT required for accreditation purposes for the following:

Procedure
Biopsy, transurethral resection of the bladder tumor (TURBT), [#] or enucleations
Primary resection specimen with no residual cancer (eg, following neoadjuvant therapy)
Cytologic specimens

Transurethral resection of a bladder tumor is NOT considered to be the definitive resection specimen, even though the entire cancer may be removed. This protocol is recommended for reporting TURBT specimens for clinical care purposes, but it is not required for accreditation purposes.

The following tumor types should NOT be reported using this protocol:

Tumor Type
Urachal Carcinoma
Lymphoma (consider the Hodgkin or non-Hodgkin Lymphoma protocols)
Sarcoma (consider the Soft Tissue protocol)

Authors

Ming Zhou, MD, PhD*; John R. Srigley, MD*; Mahul B. Amin, MD; Robert Allan, MD; Brett Delahunt, MD; Bernard H. Bochner, MD; Jonathan I. Epstein, MD; David J. Grignon, MD; Peter A. Humphrey, MD, PhD; Rodolfo Montironi, MD; Gladell P. Paner, MD; Jason Pettus, MD; Victor E. Reuter, MD

With guidance from the CAP Cancer and CAP Pathology Electronic Reporting Committees.

** Denotes primary author. All other contributing authors are listed alphabetically.*

Accreditation Requirements

This protocol can be utilized for a variety of procedures and tumor types for clinical care purposes. For accreditation purposes, only the definitive primary cancer resection specimen is required to have the core and conditional data elements reported in a synoptic format.

- Core data elements are required in reports to adequately describe appropriate malignancies. For accreditation purposes, essential data elements must be reported in all instances, even if the response is “not applicable” or “cannot be determined.”
- Conditional data elements are only required to be reported if applicable as delineated in the protocol. For instance, the total number of lymph nodes examined must be reported, but only if nodes are present in the specimen.
- Optional data elements are identified with “+” and although not required for CAP accreditation purposes, may be considered for reporting as determined by local practice standards.

The use of this protocol is not required for recurrent tumors or for metastatic tumors that are resected at a different time than the primary tumor. Use of this protocol is also not required for pathology reviews performed at a second institution (ie, secondary consultation, second opinion, or review of outside case at second institution).

Synoptic Reporting

All core and conditionally required data elements outlined on the surgical case summary from this cancer protocol must be displayed in synoptic report format. Synoptic format is defined as:

- Data element: followed by its answer (response), outline format without the paired "Data element: Response" format is NOT considered synoptic.
- The data element must be represented in the report as it is listed in the case summary. The response for any data element may be modified from those listed in the case summary, including “Cannot be determined” if appropriate.
- Each diagnostic parameter pair (Data element: Response) is listed on a separate line or in a tabular format to achieve visual separation. The following exceptions are allowed to be listed on one line:
 - Anatomic site or specimen, laterality, and procedure
 - Pathologic Stage Classification (pTNM) elements
 - Negative margins, as long as all negative margins are specifically enumerated where applicable
- The synoptic portion of the report can appear in the diagnosis section of the pathology report, at the end of the report or in a separate section, but all Data element: Responses must be listed together in one location

Organizations and pathologists may choose to list the required elements in any order, use additional methods in order to enhance or achieve visual separation, or add optional items within the synoptic report. The report may have required elements in a summary format elsewhere in the report IN ADDITION TO but not as replacement for the synoptic report i.e. all required elements must be in the synoptic portion of the report in the format defined above.

CAP Laboratory Accreditation Program Protocol Required Use Date: March 2018*

* Beginning January 1, 2018, the 8th edition AJCC Staging Manual should be used for reporting pTNM.

CAP Urinary Bladder Protocol Summary of Changes

Version 4.1.0.0 errata:

Size of Largest Metastatic Deposit

- **MODIFIED** Unit of measure from millimeters to centimeters

Version 4.0.0.0:

The following data elements were modified:

Pathologic Stage Classification (pTNM, AJCC 8th Edition)

Surgical Pathology Cancer Case Summary

Protocol posting date: June 2017

URINARY BLADDER: Biopsy and Transurethral Resection of Bladder Tumor (TURBT)

Note: This case summary is recommended for reporting biopsy and TURBT specimens, but is not required for accreditation purposes.

Select a single response unless otherwise indicated.

Procedure (Note A)

- Biopsy
 TURBT
 Other (specify): _____
 Not specified

Tumor Site (select all that apply)

- Trigone
 Right lateral wall
 Left lateral wall
 Anterior wall
 Posterior wall
 Dome
 Other (specify): _____
 Not specified

Histologic Type (select all that apply) (Note B)

Urothelial

- Papillary urothelial carcinoma, noninvasive
 Papillary urothelial carcinoma, invasive
 Urothelial carcinoma in situ
 Urothelial carcinoma, invasive
 Urothelial carcinoma, nested (including large nested) variant
 Urothelial carcinoma, microcystic variant
 Urothelial carcinoma, micropapillary variant
 Urothelial carcinoma, lymphoepithelioma-like variant
 Urothelial carcinoma, plasmacytoid / signet ring / diffuse variant
 Urothelial carcinoma, sarcomatoid variant
 Urothelial carcinoma, giant cell variant
 Urothelial carcinoma, poorly differentiated variant
 Urothelial carcinoma, lipid-rich variant
 Urothelial carcinoma, clear cell variant
 Urothelial carcinoma with squamous differentiation
 + Specify percentage of squamous differentiation: _____%
 Urothelial carcinoma with glandular differentiation
 + Specify percentage of glandular differentiation: _____%
 Urothelial carcinoma with trophoblastic differentiation
 + Specify percentage of trophoblastic differentiation: _____%
 Urothelial carcinoma with Müllerian differentiation
 + Specify percentage of Müllerian differentiation: _____%

+ Data elements preceded by this symbol are not required for accreditation purposes. These optional elements may be clinically important but are not yet validated or regularly used in patient management.

Squamous

- Pure squamous cell carcinoma
 Verrucous carcinoma
 Squamous cell carcinoma in situ (no invasive carcinoma identified)

Glandular

- Adenocarcinoma
 Adenocarcinoma, enteric
 Adenocarcinoma, mucinous
 Adenocarcinoma, mixed
 Adenocarcinoma in situ (no invasive carcinoma identified)

Tumors of Müllerian Type

- Clear cell carcinoma
 Endometrioid carcinoma

Neuroendocrine Tumors

- Small cell neuroendocrine carcinoma
 + Specify percentage of small cell neuroendocrine component: _____ %
 Large cell neuroendocrine carcinoma
 + Specify percentage of large cell neuroendocrine component: _____ %
 Well-differentiated neuroendocrine carcinoma
 + Specify percentage of well-differentiated neuroendocrine component: _____ %
 Other histologic type not listed (specify): _____

+ Associated Epithelial Lesions (select all that apply) (Note C)

- + None identified
 + Urothelial papilloma
 + Urothelial papilloma, inverted type
 + Papillary urothelial neoplasm, low malignant potential (PUNLMP)
 + Urothelial dysplasia
 + Urothelial proliferation of uncertain malignant potential
 + Cannot be determined

Histologic Grade (Note C)

For urothelial carcinoma, other variants, or divergent differentiation

- Low-grade
 High-grade
 Other (specify): _____

For squamous cell carcinoma or adenocarcinoma

- G1: Well-differentiated
 G2: Moderately differentiated
 G3: Poorly differentiated
 GX: Cannot be assessed
 Other (specify): _____
 Not applicable
 Cannot be assessed

+ Tumor Configuration (select all that apply)

- + Papillary
- + Solid/nodule
- + Flat
- + Ulcerated
- + Cannot be determined
- + Other (specify): _____

Muscularis Propria Presence (Note D)

- No muscularis propria (detrusor muscle) identified
- Muscularis propria (detrusor muscle) present
- Cannot be determined (explain): _____

Lymphovascular Invasion (Note E)

- Not identified
- Present
- Cannot be determined

Tumor Extension (select all that apply) (Note F)

- Noninvasive papillary carcinoma
- Flat carcinoma in situ
- Tumor invades lamina propria (subepithelial connective tissue)
- Tumor invades muscularis propria
- Urothelial carcinoma involving prostatic urethra in prostatic chips sampled by TURBT
- Urothelial carcinoma involving prostatic ducts and acini in prostatic chips sampled by TURBT
- Urothelial carcinoma invasive into prostatic stroma in prostatic chips sampled by TURBT
- Cannot be assessed

+ Additional Pathologic Findings (select all that apply)

- + Urothelial carcinoma in situ
- + Urothelial dysplasia, low-grade
- + Inflammation/regenerative changes
- + Therapy-related changes
- + Cautery artifact
- + Cystitis cystica et glandularis
- + Keratinizing squamous metaplasia
- + Intestinal metaplasia
- + Other (specify): _____

+ Comment(s)

Surgical Pathology Cancer Case Summary

Protocol posting date: June 2017

URINARY BLADDER: Cystectomy and Anterior Exenteration

Select a single response unless otherwise indicated.

Procedure (Note G)

- Partial cystectomy
 Total cystectomy
 Radical cystectomy
 Radical cystoprostatectomy
 Anterior exenteration
 Other (specify): _____
 Cannot be determined

Tumor Site (select all that apply)

- Trigone
 Right lateral wall
 Left lateral wall
 Anterior wall
 Posterior wall
 Dome
 Other (specify): _____
 Cannot be determined

Tumor Size

- Greatest dimension (centimeters): ____ cm
 + Additional dimensions (centimeters): ____ x ____ cm
 Cannot be determined (explain): _____

Histologic Type (select all that apply) (Note B)Urothelial

- Papillary urothelial carcinoma, noninvasive
 Papillary urothelial carcinoma, invasive
 Urothelial carcinoma in situ
 Urothelial carcinoma, invasive
 Urothelial carcinoma, nested (including large nested) variant
 Urothelial carcinoma, microcystic variant
 Urothelial carcinoma, micropapillary variant
 Urothelial carcinoma, lymphoepithelioma-like variant
 Urothelial carcinoma, plasmacytoid / signet ring / diffuse variant
 Urothelial carcinoma, sarcomatoid variant
 Urothelial carcinoma, giant cell variant
 Urothelial carcinoma, poorly differentiated variant
 Urothelial carcinoma, lipid-rich variant
 Urothelial carcinoma, clear cell variant
 Urothelial carcinoma with squamous differentiation
 + Specify percentage of squamous differentiation: _____%
 Urothelial carcinoma with glandular differentiation
 + Specify percentage of glandular differentiation: _____%
 Urothelial carcinoma with trophoblastic differentiation
 + Specify percentage of trophoblastic differentiation: _____%

+ Data elements preceded by this symbol are not required for accreditation purposes. These optional elements may be clinically important but are not yet validated or regularly used in patient management.

___ Urothelial carcinoma with Müllerian differentiation
+ Specify percentage of Müllerian differentiation: _____%

Squamous

___ Pure squamous cell carcinoma
___ Verrucous carcinoma
___ Squamous cell carcinoma in situ (no invasive carcinoma identified)

Glandular

___ Adenocarcinoma
___ Adenocarcinoma, enteric
___ Adenocarcinoma, mucinous
___ Adenocarcinoma, mixed
___ Adenocarcinoma in situ (no invasive carcinoma identified)

Tumors of Müllerian Type

___ Clear cell carcinoma
___ Endometrioid carcinoma

Neuroendocrine Tumors

___ Small cell neuroendocrine carcinoma
+ Specify percentage of small cell neuroendocrine component: _____%
___ Large cell neuroendocrine carcinoma
+ Specify percentage of large cell neuroendocrine component: _____%
___ Well-differentiated neuroendocrine carcinoma
+ Specify percentage of well-differentiated neuroendocrine component: _____%

___ Other histologic type not listed (specify): _____

+ Associated Epithelial Lesions (select all that apply) (Note C)

+ ___ None identified
+ ___ Urothelial papilloma
+ ___ Urothelial papilloma, inverted type
+ ___ Papillary urothelial neoplasm, low malignant potential (PUNLMP)
+ ___ Urothelial proliferation of uncertain malignant potential
+ ___ Urothelial dysplasia
+ ___ Cannot be determined

Histologic Grade (Note C)

For urothelial carcinoma, other variants, or divergent differentiation

___ Low grade
___ High grade
___ Other (specify): _____

For squamous cell carcinoma or adenocarcinoma

___ G1: Well differentiated
___ G2: Moderately differentiated
___ G3: Poorly differentiated
___ GX: Cannot be assessed

___ Other (specify): _____
___ Not applicable
___ Cannot be assessed

+ Data elements preceded by this symbol are not required for accreditation purposes. These optional elements may be clinically important but are not yet validated or regularly used in patient management.

+ Tumor Configuration (select all that apply)

- + Papillary
- + Solid/nodule
- + Flat
- + Ulcerated
- + Cannot be determined
- + Other (specify): _____

Tumor Extension (select all that apply) (Note D)

- No evidence of primary tumor
- Noninvasive papillary carcinoma
- Urothelial carcinoma in situ, "flat tumor"
- Tumor invades lamina propria (subepithelial connective tissue)
- Tumor invades muscularis propria
 - Tumor invades superficial muscularis propria (inner half)
 - Tumor invades deep muscularis propria (outer half)
- Tumor invades perivesical tissue
 - Microscopically
 - Macroscopically (extravesical mass)
- Tumor invades adjacent structures[#]
 - Male*
 - Prostate (transmural invasion from the bladder tumor)^{##}
 - Seminal vesicles
 - Female*
 - Uterus
 - Vagina
 - Adnexae
 - Male/Female*
 - Pelvis wall
 - Abdominal wall
 - Rectum
 - Other (specify): _____
- Cannot be assessed

[#] Note: Use the Urethral protocol for tumors that involve the urethral mucosa without invasion, tumors that involve the urethral mucosa with invasion of subepithelial connective tissue/prostate stroma, or tumors that involve prostatic ducts and acini with or without stromal invasion.

^{##} See Note D, Figure 1.

Margins (select all that apply) (Note G)

- Cannot be assessed
- Uninvolved by invasive carcinoma and carcinoma in situ/ noninvasive urothelial carcinoma
- Uninvolved by invasive carcinoma
- Involved by invasive carcinoma
 - Right ureteral margin
 - Left ureteral margin
 - Urethral margin
 - Soft tissue margin
 - Other margin(s) (specify)[#]: _____
- Involved by carcinoma in situ/noninvasive high-grade urothelial carcinoma
 - Right ureteral margin
 - Left ureteral margin
 - Urethral margin
 - Soft tissue margin
 - Other margin(s) (specify)[#]: _____
- Involved by noninvasive low-grade urothelial carcinoma/urothelial dysplasia

+ Data elements preceded by this symbol are not required for accreditation purposes. These optional elements may be clinically important but are not yet validated or regularly used in patient management.

- Right ureteral margin
- Left ureteral margin
- Urethral margin
- Soft tissue margin
- Other margin(s) (specify)[#]: _____

[#] Note: For partial cystectomies, if the specimen is received unoriented precluding identification of specific margins, it should be denoted here.

Lymphovascular Invasion (Note E)

- Not identified
- Present
- Cannot be determined

Regional Lymph Nodes

- No lymph nodes submitted or found

Lymph Node Examination (required only if lymph nodes are present in the specimen)

- Number of Lymph Nodes Involved: _____
- Number cannot be determined (explain): _____

- Number of Lymph Nodes Examined: _____
- Number cannot be determined (explain): _____

- + Size of Largest Metastatic Deposit (centimeters): ____ cm
- + Specify Site: _____

- + Size of Largest Lymph Node Involved (centimeters): ____ cm
- + Specify Site: _____

+ Extranodal Extension

- + Not identified
- + Present
- + Cannot be determined

Pathologic Stage Classification (pTNM, AJCC 8th Edition) (Note F)

Note: Reporting of pT, pN, and (when applicable) pM categories is based on information available to the pathologist at the time the report is issued. Only the applicable T, N, or M category is required for reporting; their definitions need not be included in the report. The categories (with modifiers when applicable) can be listed on 1 line or more than 1 line.

TNM Descriptors (required only if applicable) (select all that apply)

- m (multiple primary tumors)
- r (recurrent)
- y (posttreatment)

Primary Tumor (pT)

- pTX: Primary tumor cannot be assessed
- pT0: No evidence of primary tumor
- pTa: Noninvasive papillary carcinoma
- pTis: Urothelial carcinoma *in situ*: "flat tumor"
- pT1: Tumor invades lamina propria (subepithelial connective tissue)
- pT2: Tumor invades muscularis propria
- pT2a: Tumor invades superficial muscularis propria (inner half)
- pT2b: Tumor invades deep muscularis propria (outer half)
- pT3: Tumor invades perivesical soft tissue

+ Data elements preceded by this symbol are not required for accreditation purposes. These optional elements may be clinically important but are not yet validated or regularly used in patient management.

- pT3a: Tumor invades perivesical soft tissue microscopically
- pT3b: Tumor invades perivesical soft tissue macroscopically (extravesical mass)
- pT4: Extravesical tumor directly invades any of the following: prostatic stroma, seminal vesicles, uterus, vagina, pelvic wall, abdominal wall
- pT4a: Extravesical tumor invades directly into prostatic stroma, seminal vesicles, uterus, or vagina
- pT4b: Extravesical tumor invades pelvic wall, abdominal wall

Regional Lymph Nodes (pN)

- pNX: Lymph nodes cannot be assessed
- pN0: No lymph node metastasis
- pN1: Single regional lymph node metastasis in the true pelvis (perivesical, obturator, internal and external iliac or sacral lymph node)
- pN2: Multiple regional lymph node metastasis in the true pelvis (perivesical, obturator, internal and external iliac or sacral lymph node metastasis)
- pN3: Lymph node metastasis to the common iliac lymph nodes

Distant Metastasis (pM) (required only if confirmed pathologically in this case)

- pM1: Distant metastasis
- pM1a: Distant metastasis limited to lymph nodes beyond the common iliacs
- pM1b: Non-lymph node distant metastases

Specify site(s), if known: _____

+ Additional Pathologic Findings (select all that apply)

- + Urothelial carcinoma in situ
- + Urothelial dysplasia, low-grade
- + Adenocarcinoma of prostate (use protocol for carcinoma of prostate)
- + Inflammation/regenerative changes
- + Therapy-related changes (specify): _____
- + Cystitis cystica et glandularis
- + Keratinizing squamous metaplasia
- + Intestinal metaplasia
- + Other (specify): _____

+ Comment(s)

Explanatory Notes

A. History

A relevant history is important for interpretation of all bladder specimens.¹⁻⁴ Cystoscopic visualization findings hold useful information on the nature and extent of bladder lesions in biopsy and TURBT specimens. A history of renal stones, recent urinary tract procedures, infections, or obstruction may influence the interpretation of random biopsies obtained on patients with hematuria. Any neoplasms previously diagnosed should be specified, including the histologic type, primary site, and histologic grade. If prior therapy has been given, it should be described (systemic or intravesical chemotherapy, immunotherapy, radiation, etc). The method of collection and date also should be specified in urine cytology specimens.

B. Histologic Type

The vast majority (more than 95%) of carcinomas of the urinary bladder, renal pelvis, and ureter are urothelial cell in origin. The most recent 2016 World Health Organization (WHO) classification of tumors of the urothelial tract, including urethra, urinary bladder, ureter, and renal pelvis, is provided in this note. Benign tumors are included in this classification because, within the same patient, a spectrum of differentiation from benign to malignant tumors may be seen in the bladder, either at the same time or over the clinical course of the disease. Also, clinicians stage most tumors irrespective of histologic grade.⁵⁻¹³ The distinction between a urothelial carcinoma with divergent squamous, glandular, or Müllerian differentiation and a pure squamous cell carcinoma, adenocarcinoma or Müllerian is rather arbitrary. Most authorities, including the 2016 WHO classification, require a pure histology of squamous cell carcinoma, adenocarcinoma or Müllerian to designate a tumor as such, all others with recognizable papillary, invasive, or flat carcinoma in situ (CIS) urothelial component being considered as urothelial carcinoma with divergent differentiation. A malignant neoplasm with small cell neuroendocrine carcinoma component arising in the urinary tract is designated as small cell carcinoma.

2016 WHO Classification of Tumors of the Urothelial Tract

Urothelial tumors

Infiltrating urothelial carcinoma

- Nested, including large nested
- Microcystic
- Micropapillary
- Lymphoepithelioma-like
- Plasmacytoid/signet ring cell/diffuse
- Sarcomatoid
- Giant cell
- Poorly differentiated

Noninvasive urothelial lesions

- Urothelial carcinoma in situ
- Noninvasive papillary urothelial carcinoma, low grade
- Noninvasive papillary urothelial carcinoma, high grade
- Papillary urothelial neoplasm of low malignant potential
- Urothelial papilloma
- Inverted urothelial papilloma
- Urothelial proliferation of uncertain malignant potential
- Urothelial dysplasia

Squamous cell neoplasms

- Pure squamous cell carcinoma
- Verrucous carcinoma
- Squamous cell papilloma

Glandular neoplasms

- Adenocarcinoma, NOS
- Enteric

Mucinous
Mixed
Villous adenoma

Urachal carcinomaTumors of Mullerian type

Clear cell carcinoma
Endometrioid carcinoma

Neuroendocrine tumors

Small cell neuroendocrine carcinoma
Large cell neuroendocrine carcinoma
Well-differentiated neuroendocrine tumor
Paraganglioma

C. Histologic Grade

Flat intraepithelial lesions and papillary and invasive lesions are graded separately.¹⁰⁻¹⁷ There has been significant controversy in the classification of these lesions. Flat lesions were graded as mild, moderate, and severe dysplasia and carcinoma in situ; or atypical hyperplasia and carcinoma in situ; or dysplasia and carcinoma in situ.^{5,7} Papillary lesions were classified as papillomas (grade 0) and transitional cell carcinomas, grades I, II and III; or as papillomas, low-grade and high-grade transitional cell carcinomas.¹³⁻¹⁵ Due to variable classification systems and the need for a universally acceptable system, the World Health Organization/International Society of Urological Pathology (WHO/ISUP) consensus classification was proposed.¹³ This system is adopted in the WHO 2004 classification¹⁰ and 2004 Armed Forces Institute of Pathology (AFIP) fascicle,¹² and has been validated by many studies to be prognostically significant. The 2016 WHO system used essentially the same classification with minor modification.¹¹ Other systems (that were being used previously) may still be used according to institutional preference. Tumor grade according to both the WHO/ISUP (1998)¹³ / WHO (2004)¹⁰ system and the older WHO (1973)¹⁵ system may be concurrently used.

2004 WHO / ISUP Consensus Classification for Urothelial Lesions

Normal
 Normal[#]
Hyperplasia
 Flat hyperplasia
 Papillary hyperplasia
Flat Lesions with Atypia
 Reactive (inflammatory) atypia
 Atypia of unknown significance
 Dysplasia (low-grade intraurothelial neoplasia)[#]
 Carcinoma in situ (high-grade intraurothelial neoplasia)^{###}
Papillary Neoplasms
 Papilloma
 Inverted papilloma
 Papillary neoplasm of low malignant potential
 Papillary carcinoma, low-grade
 Papillary carcinoma, high-grade^{####}
Invasive Neoplasms
 Lamina propria invasion
 Muscularis propria (detrusor muscle) invasion

[#] May include cases formerly diagnosed as "mild dysplasia."

^{###} Includes cases with "severe dysplasia."

^{####} Option exists to add comment as to the presence of marked anaplasia.

Flat and papillary urothelial hyperplasia has been renamed as “urothelial proliferation of uncertain malignant potential” in the 2016 WHO classification.

Squamous carcinomas and adenocarcinomas may be graded as well-differentiated, moderately differentiated, and poorly differentiated.

D. Extent of Invasion

A critical role of the surgical pathologist is to diagnose the depth and extent of invasion into the subepithelial connective tissue/lamina propria/submucosa (pT1), muscularis propria (pT2), or beyond (pT3 or pT4).¹⁸⁻²⁰ In papillary tumors, invasion occurs most often at the base of the tumor and very infrequently in the stalk. In the urinary bladder, a tumor infiltrating the lamina propria (pT1) is sometimes overdiagnosed as vascular invasion; hence, caution should be exercised when diagnosing this feature, which in some cases may be supported by performing immunohistochemical studies for endothelial markers.²¹ Depth of invasion is a critical prognostic determinant in invasive urothelial carcinoma. In T1 disease, several substaging methods have been proposed but have been difficult to adopt due in part to the inherent lack of orientation of the specimen.^{10,13} Pathologists are, however, encouraged to provide some assessment as to the extent of lamina propria invasion (ie, maximum dimension of invasive focus, or depth in millimeters, or by level – above, at, or below muscularis mucosae). Designation of a tumor as merely muscle invasive is inappropriate, but the type of muscle invasion, ie, muscularis mucosae (pT1 tumors) versus muscularis propria (pT2 tumors) invasion, needs to be clearly stated.^{22,23} Descriptive terminology, such as “urothelial carcinoma with muscle invasion, indeterminate for type of muscle invasion,” may be used when it is not possible to be certain whether the type of muscle invaded by the tumor is hypertrophic muscularis mucosae or muscularis propria. A comment on thermocoagulation effect may be made, especially if its presence impedes diagnostic evaluation.²⁴ In TURBT specimens invasive into muscularis propria, no attempt should be made to substage the depth of muscularis propria invasion. Since fat may be present in the lamina propria and muscularis propria, the presence of tumor in adipose tissue is not necessarily diagnostic of extravesical spread; this determination is reserved for cystectomy specimens.^{23,25}

Involvement of the prostate gland may occur in several different patterns. Tumors (flat carcinoma in situ, papillary or invasive carcinoma) can first spread along the prostatic urethral mucosa and prostate glands and subsequently invade prostatic stroma (transurethral mucosal route) (Figure 1, B). Tumors may also invade through the bladder wall and the base of the prostate directly into the prostate gland (Figure 1, A, straight arrow).²⁶ Tumors can also invade into extravesical fat and then extend back into the prostate gland (Figure 1, B, curved arrow). The latter two routes are considered direct transmural invasion. The American Joint Committee on Cancer (AJCC) 8th edition staging manual defines direct extension of urinary bladder cancer into the prostate gland as T4 disease and excludes transurethral mucosal prostatic stroma invasion from the pT4a staging status. However, there is limited data on the best methodology to stage urothelial carcinoma that concurrently involves the urinary bladder and the prostatic urethra. In patients who have a large urinary bladder carcinoma that has invaded through the full thickness of the bladder wall and thereby secondarily involves the prostatic stroma, a T4 stage should be assigned per urinary bladder staging. In other circumstances in which involvement by urothelial carcinoma is seen in both sites, separate urinary bladder and prostatic urethral staging should be assigned.

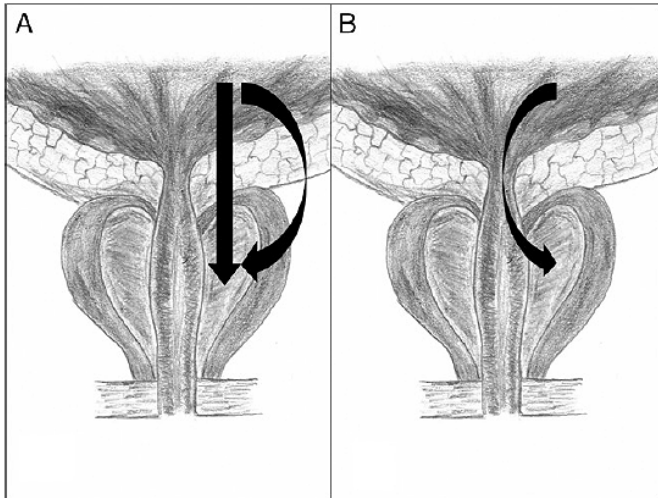


Figure 1. Prostatic invasion from urinary bladder cancer via direct transmural and extravesical route (A) and transurethral invasion (B). From: Patel AR, Cohn JA, El Latif AA, et al. Validation of new AJCC exclusion criteria for subepithelial prostatic stroma invasion from pT4a bladder urothelial carcinoma. *J Urol.* 2013;189:53-58. Reproduced with permission.

E. Lymphovascular Invasion

Urothelial carcinoma may invade blood vessels or lymphatic channels. Lymphovascular invasion has been shown to be an independent predictor of recurrence and decreased overall survival.²⁷ Presence of lymph-vascular invasion in TURBT specimens is associated with higher nodal metastasis.²⁸ In suspicious cases, blood vessels can be highlighted by immunohistochemical staining for factor VIII-related antigen, CD31 or CD34. Staining will not resolve the problem of differentiating lymphatic versus artifactual space entrapment by tumor cells, and as mentioned, this is frequently seen in urothelial tumors invading the lamina propria. Retraction artifact is also prominent in the “micropapillary variant” of urothelial carcinoma.⁷

F. TNM and Stage Groupings

The TNM Staging System for carcinomas of the urinary bladder of the AJCC is recommended.¹⁸ A cystoprostatectomy specimen may contain three separate primaries: carcinoma of the urinary bladder, carcinoma of the prostate and carcinoma of the urethra. Depending on the pathology in a given case, the number of protocols to be used in a cystoprostatectomy specimen will vary.

By AJCC convention, the designation “T” refers to a primary tumor that has not been previously treated. The symbol “p” refers to the pathologic classification of the TNM, as opposed to the clinical classification, and is based on gross and microscopic examination. pT entails a resection of the primary tumor or biopsy adequate to evaluate the highest pT category, pN entails removal of nodes adequate to validate lymph node metastasis, and pM implies microscopic examination of distant lesions. Clinical classification (cTNM) is usually carried out by the referring physician before treatment during initial evaluation of the patient or when pathologic classification is not possible.

Pathologic staging is usually performed after surgical resection of the primary tumor. Pathologic staging depends on pathologic documentation of the anatomic extent of disease, whether or not the primary tumor has been completely removed. If a biopsied tumor is not resected for any reason (eg, when technically unfeasible) and if the highest T and N categories or the M1 category of the tumor can be confirmed microscopically, the criteria for pathologic classification and staging have been satisfied without total removal of the primary cancer.

Primary Tumor (T) (Figure 2)

The suffix “m” should be added to the appropriate T category to indicate multiple tumors. The suffix “is” may be added to any T to indicate the presence of associated carcinoma in situ.

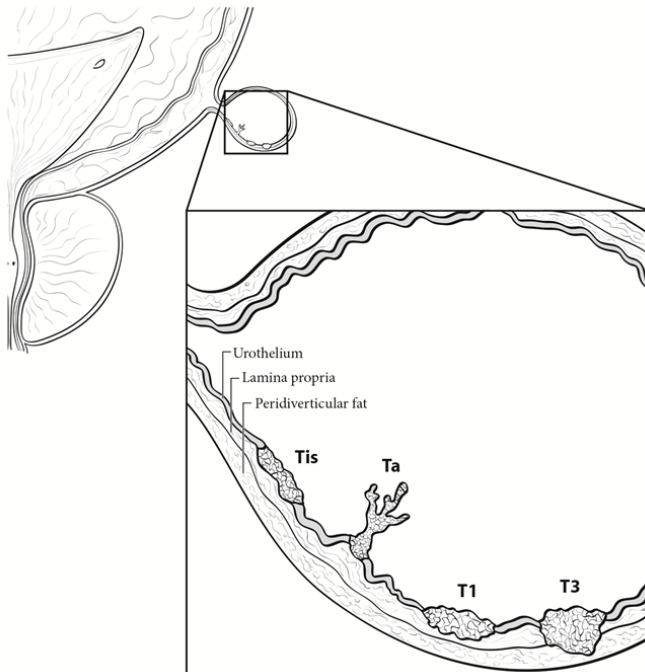


Figure 2. Extent of Tis, Ta, T1, and T3. From: Amin MB, Edge SB, Greene FL, et al, eds. *AJCC Cancer Staging Manual*. 8th ed. New York, NY: Springer; 2017. Reproduced with permission.

TNM Stage Groupings

Stage 0a	Ta	N0	M0 [#]
Stage 0is	Tis	N0	M0
Stage I	T1	N0	M0
Stage II	T2a	N0	M0
	T2b	N0	M0
Stage IIIA	T3a, 3b, 4a	N0	M0
Stage IIIB	T1-4a	N1	M0
Stage IIIB	T1-4a	N2, 3	M0
Stage IVA	T4b	N0	M0
Stage IVA	Any T	Any N	M1a
Stage IVB	Any T	Any N	M1b

[#] M0 is defined as no distant metastasis.

TNM Descriptors

For identification of special cases of TNM or pTNM classifications, the “m” suffix and “y” and “r” prefixes are used. Although they do not affect the stage grouping, they indicate cases needing separate analysis.

The “m” suffix indicates the presence of multiple primary tumors in a single site and is recorded in parentheses: pT(m)NM.

The “y” prefix indicates those cases in which classification is performed during or following initial multimodality therapy (ie, neoadjuvant chemotherapy, radiation therapy, or both chemotherapy and radiation therapy). The cTNM or pTNM category is identified by a “y” prefix. The ycTNM or ypTNM categorizes the extent of tumor actually present at the time of that examination. The “y” categorization is not an estimate of tumor prior to multimodality therapy (ie, before initiation of neoadjuvant therapy).

The “r” prefix indicates a recurrent tumor when staged after a documented disease-free interval, and is identified by the “r” prefix: rTNM.

Additional Descriptors**Residual Tumor (R)**

Tumor remaining in a patient after therapy with curative intent (eg, surgical resection for cure) is categorized by a system known as R classification, shown below.

RX	Presence of residual tumor cannot be assessed
R0	No residual tumor
R1	Microscopic residual tumor
R2	Macroscopic residual tumor

For the surgeon, the R classification may be useful to indicate the known or assumed status of the completeness of a surgical excision. For the pathologist, the R classification is relevant to the status of the margins of a surgical resection specimen. That is, tumor involving the resection margin on pathologic examination may be assumed to correspond to residual tumor in the patient and may be classified as macroscopic or microscopic according to the findings at the specimen margin(s).

G. Sections for Microscopic Evaluation**Bladder**

Sections of bladder for microscopic evaluation are as follows. In TURBT specimens, submit one section per centimeter of tumor diameter (up to 10 cassettes). If the tumor is noninvasive by the initial sampling, additional submission of tissue (including possibly submitting all tissue) is necessary to diagnose or rule out the presence of invasion. If tumor is invasive into lamina propria in the initial sampling, additional sections (including possibly submitting the entire specimen) may be necessary to diagnose or rule out the possibility of muscularis propria invasion. In cystectomy specimens, several representative sections of the tumor, including the macroscopically deepest penetration, should be sampled. Submit several sections of the mucosa remote from the carcinoma, especially if abnormal, including the lateral wall(s), dome, and trigone. Submit one section of ureteral margin, unless submitted separately as frozen section specimens, and 1 section of urethral margin. If a long segment of the ureter(s) is present, then additional sections from the mid-portion may be necessary, as urothelial cancer often is multifocal.

Prostate and Prostatic Urethra

Prostatic urethral involvement should be carefully investigated in cystectomy specimens. Sections should include the prostatic urethra, including at the margin and with the surrounding prostatic parenchyma. Representative sections of the peripheral zone, central zone, and seminal vesicles should be included. Close gross examination may help target sampling of selective abnormal-appearing areas.

Lymph Nodes

Submit one section from each grossly positive lymph node. All other lymph nodes should be entirely submitted, as presence of nodal disease may be used as an indication for adjuvant therapy. Lymph nodes may be grossly or microscopically detected in the perivesical fat.

Other Tissues

Submit one or more sections of uterus (as indicated) and one or more sections of vagina, seminal vesicles, and other organs (as indicated). If the tumor grossly appears to invade the prostate, uterus, or vagina, sections should be targeted, such that the relationship of the infiltrating tumor in the bladder wall and the adjacent viscus is clearly demonstrable.

H. Margins

Resection margins, including those mentioned in Note G, should be carefully specified. Statements about deep soft tissue margins should specify whether peritoneal surfaces are involved by tumor. In cases of urachal adenocarcinoma in which partial cystectomy with excision of the urachal tract and umbilicus is performed, the margins of the urachal tract, ie, the soft tissue surrounding the urachus and the skin around the umbilical margin, should be specified. In renal pelvis, ureter, and nephroureterectomy specimens, the margins may include radial hilar soft tissue margin; bladder cuff; and ureteral, renal parenchymal, and Gerota's fascia margins, depending on the type of surgical specimen.

References

1. Murphy WM. Diseases of the urinary bladder, urethra, ureters and renal pelvis. In: Murphy WM, ed. *Urological Pathology*. 2nd ed. Philadelphia, PA: WB Saunders Co; 1997.
2. Ro JY, Staerckel GA, Ayala AG. Cytologic and histologic features of superficial bladder cancer. *Urol Clin North Am*. 1992;19:435-453.
3. Grignon DJ. Neoplasms of the urinary bladder. In: Bostwick DG, Eble JN, eds. *Urologic Surgical Pathology*. St. Louis, MO: Mosby Year Book, Inc; 1997.
4. Hughes JH, Raab SS, Cohen MB. The cytologic diagnosis of low-grade transitional cell carcinoma. *Am J Clin Pathol*. 2000;114(supp1):559-567.
5. Amin MB, Murphy WM, Reuter VE, et al. Controversies in the pathology of transitional cell carcinoma of the urinary bladder. In: Rosen PP, Fechner RE, eds. *Reviews of Pathology*. Vol. 1. Chicago, IL: ASCP Press; 1996.
6. Reuter VE. The urothelial tract: renal pelvis, ureter, urinary bladder, and urethra. In: Mills Se, Carter D, Greenson JK, Oberman HA, Reuter V, Stoler MH, eds. *Sternberg's Diagnostic Surgical Pathology*. 4th ed. Philadelphia, PA: Lippincott Williams and Wilkins; 2004.
7. Amin MB, Young RH. Intraepithelial lesions of the urinary bladder with a discussion of the histogenesis of urothelial neoplasia. *Semin Diagn Pathol*. 1997;14(2):84-97.
8. Eble JN, Young RH. Carcinoma of the urinary bladder: a review of its diverse morphology. *Semin Diagn Pathol*. 1997;14(2):98-108.
9. Mostofi FK, Davis CJ, Sesterhenn IA. Histologic typing of urinary bladder tumors. In: *World Health Organization International Histologic Classification of Tumours*. 2nd ed. Heidelberg, Germany: Springer-Verlag, Berlin; 1999.
10. Eble JN, Sauter G, Epstein JI, Sesterhenn IA. Tumors of the urinary system. In: *World Health Organization Classification of Tumours: Pathology and Genetics of Tumours of the Urinary System and Male Genital Organs*. Lyon, France: IARC Press; 2004.
11. Moch H, Humphrey PA, Ulbright TM, Reuter VE. *WHO Classification of Tumours of the Urinary System and Male Genital Organs*. Geneva, Switzerland: WHO Press; 2016.
12. Murphy WM, Grignon DJ, Perlman EJ. Tumors of the urinary bladder. In: *Tumors of the Kidney, Bladder, and Related Urinary Structures*. AFIP Atlas of Tumor Pathology Series 4. Washington, DC: American Registry of Pathology; 2004.
13. Epstein JI, Amin MB, Reuter VR, Mostofi FK, the Bladder Consensus Conference Committee. The World Health Organization/ International Society of Urological Pathology Consensus classification of urothelial (transitional cell) neoplasms of the urinary bladder. *Am J Surg Pathol*. 1998;22:1435-1448.
14. Murphy WM, Beckwith JB, Farrow GM. Tumors of the kidney, bladder, and related urinary structures. In: *Atlas of Tumor Pathology*. 3rd series. Fascicle 11. Washington, DC: Armed Forces Institute of Pathology; 1994.
15. Mostofi FK. Histological typing of urinary bladder tumours. In: *WHO Histological Classification of Tumours*. No. 10. Geneva, Switzerland: World Health Organization; 1973.
16. Bergkvist A, Ljungqvist A, Moberger G. Classification of bladder tumors based on the cellular pattern. *Acta Chir Scand*. 1965;130:371-378.
17. Friedell GH, Bell JR, Burney SW, Soto EA, Tiltman AJ. Histopathology and classification of urinary bladder carcinoma. *Urol Clin North Am*. 1976;3:265-227.
18. Amin MB, Edge SB, Greene FL, et al, eds. *AJCC Cancer Staging Manual*. 8th Ed. New York: Springer; 2017.
19. Brierley JD, Gospodarowicz MK, Wittekind C, et al, eds. *TNM Classification of Malignant Tumours*. 8th ed. Oxford, UK: Wiley; 2016.
20. Jimenez RE, Keane TE, Hardy HT, Amin MB. pT1 urothelial carcinoma of the bladder: criteria for diagnosis, pitfalls, and clinical implications. *Adv Anat Pathol*. 2000;7(1):13-25.
21. Amin MB, Murphy WM, Reuter VE, et al. Controversies in the pathology of transitional cell carcinoma of the urinary bladder. Part II, Chapter 5. In: Rosen PP, Fechner RE, eds. *Reviews of Pathology*. Vol. 2. Chicago, IL: ASCP Press; 1997:71-110.
22. Ro JY, Ayala AG, El-Naggar A. Muscularis mucosa of urinary bladder: importance for staging and treatment. *Am J Surg Pathol*. 1983;136:265-271.
23. Paner GP, Ro JY, Wojcik EM, Venkataraman G, Data MW, Amin MB. Further characterization of the muscle layers and lamina propria of the urinary bladder by systematic histologic mapping: implications for pathologic staging of invasive urothelial carcinoma. *Am J Surg Pathol*. 2007;31:1420-1429.

24. Murphy WM. ASCP survey on pathology examination of the urinary bladder. *Am J Clin Pathol.* 1994;102:715-723.
25. Philip AT, Amin MB, Tamboli P, Lee TJ, Hill CE, Ro JY. Intravesical adipose tissue: a quantitative study of its presence and location with implications for therapy and prognosis. *Am J Surg Pathol.* 2000;24:1286-1290.
26. Patel AR, Cohn JA, El Latif AA, et al. Validation of new AJCC exclusion criteria for subepithelial prostatic stroma invasion from pT4a bladder urothelial carcinoma. *J Urol.* 2013; 189:53-58.
27. Lotan Y, Gupta A, Shariat SF, et al. Lymphovascular invasion is independently associated with overall survival, cause-specific survival, and local and distant recurrence in patients with negative lymph nodes at radical cystectomy. *J Clin Oncol.* 2005;23:6533-6539.
28. Kunju LP, You L, Zhang Y, Daignault S, Montie JE, Lee CT. Lymphovascular invasion of urothelial cancer in matched transurethral bladder tumor resection and radical cystectomy specimens. *J Urol.* 2008;18:1928-1932.